

**Comparison of Male and Female Rib Sternal Ends
and the Effects of Aging using Elliptical Fourier
Analysis**

A Thesis Presented for the
Master of Arts
Degree
The University of Tennessee, Knoxville

Marta M. Paulson
May 2023

ACKNOWLEDGEMENTS

First and foremost, I would like to thank my advisor Dr. Lee Meadows Jantz for her support and insightful feedback throughout my Master's study and research.

I would also like to thank my other committee members, Dr. Dawnie W.

Steadman for her insightful and difficult questions and Dr. Benjamin M Auerbach for assistance on all of the code used for this thesis. I would also like to thank my committee as a whole for their time and support in helping to shape my thesis into what it is today

I would like to express my gratitude to the University of Tennessee's Forensic Anthropology Center for allowing me to use the UTK Donated Skeletal collection for my research.

Thank you to the Donors and their families for their invaluable gift of donation.

This project would not have been possible otherwise.

I would also like to thank my mom, dad, and two sisters for all their support and encouragement throughout this process.

ABSTRACT

Sex and age make up two of the main tenets of the biological profile. Most anthropologists would argue that sex is one of the most important aspects of the profile. When creating a biological profile, the first step is to estimate sex of the individual because this can affect age estimation using the os coxa or estimations of stature. Past studies have noted that even though ribs carry out the same function in males and females there are morphological differences that can affect age estimation using the ribs. This study uses Elliptical Fourier analysis to compare differences in overall shape of the male and female sternal rib end. It also explores how the shape of the sternal end of the rib is affected by skeletal aging processes. As other studies have noted the rate and pattern of costal cartilage ossification seem to exhibit trends based on sex and age of the individuals. For this reason, the amount or rate of ossification and ossification patterning were also explored. The results showed that for all features analyzed, age and sex were found to be key influencers with varying degrees. In the case of costal cartilage ossification this study found that rate of ossification was based more on age while sex was more of an influence for differences in ossification patterning on the sternal end of the rib. Further analysis also revealed that the degree that sex or age influenced the shape of the sternal was dependent on which rib was used, e.g., rib 1 or rib 5.

TABLE OF CONTENTS

CHAPTER ONE: INTRODUCTION AND GENERAL INFORMATION	1
CHAPTER TWO: LITERATURE REVIEW	7
Growth and development of the rib cage.....	7
Effects of biological sex on ribs	8
Age Estimation	9
Age Estimation of the Ribs	13
Sex Estimation	15
Sex Estimation of the Ribs	17
Radiographs	17
Osteometrics.....	23
Other Studies.....	29
Geometric Morphometrics	30
Elliptical Fourier Analysis	31
CHAPTER THREE: MATERIALS AND METHODS	35
Methods	35
Sample	35
Digitizing	36
Data Analysis Methods.....	40
Elliptical Fourier Analysis	40
Statistics	40
CHAPTER FOUR: RESULTS	41
CHAPTER FIVE: DISCUSSION.....	52
CHAPTER SIX: CONCLUSION AND RECOMMENDATIONS	56
LIST OF REFERENCES.....	58
APPENDIX.....	67
Appendix A.....	67
VITA.....	76

LIST OF TABLES

Table 1: Age distribution of Female and Male Sample.....	42
Table 2: ANOVA results for comparisons of first principal components for elliptic Fourier analyses between all rib groups. Bold text indicates significant p -values.	43
Table 3: ANOVA results for comparisons of first principal components for elliptic Fourier analyses for rib group 1. Bold text indicates significant p -values. ..	43
Table 4: ANOVA results for comparisons of first principal components for elliptic Fourier analyses for rib group 2. Bold text indicates significant p -values. ..	43
Table 5: ANOVA results for comparisons of second principal components for elliptic Fourier analyses for rib group 2. Bold text indicates significant p -values.	43
Table 6: ANOVA results for comparisons of first principal components for elliptic Fourier analyses for rib group 3. Bold text indicates significant p -values. ..	44
Table 7: ANOVA results for comparisons of sternal end depths between all rib groups. Bold text indicates significant p -values.	46
Table 8: ANOVA results for comparisons of sternal end depths for rib group 1. Bold text indicates significant p -values.	46
Table 9: ANOVA results for comparisons of sternal end depths for rib group 2. Bold text indicates significant p -values.	46
Table 10: ANOVA results for comparisons of sternal end depths for rib group 3. Bold text indicates significant p -values.	46
Table 11: Repeated measures ANOVA results for comparison of amount of ossification between all rib groups. Bold text indicates significant p -values.	47
Table 12: Repeated measures ANOVA results for comparison of amount of ossification for rib group 1. Bold text indicates significant p -values.	47
Table 13: Repeated measures ANOVA results for comparison of amount of ossification for rib group 2. Bold text indicates significant p -values.	47
Table 14: Repeated measures ANOVA results for comparison of amount of ossification for rib group 3. Bold text indicates significant p -values.	48
Table 15: Ossification patterns observed 0= no different, L=low, H=high	50
Table 16: ANOVA results for comparisons of ossification pattern frequencies between all rib groups. Bold text indicates significant p -values	50
Table 17: ANOVA results for comparisons of ossification pattern frequencies for rib group 1. Bold text indicates significant p -values.....	51
Table 18: ANOVA results for comparisons of ossification pattern frequencies for rib group 2. Bold text indicates significant p -values.....	51
Table 19: ANOVA results for comparisons of ossification pattern frequencies for rib group 3. Bold text indicates significant p -values.....	51

LIST OF FIGURES

Figure 1: Illustration of the pump handle motion observed in the upper ribs. (Starr and Dalton 2011:198)	4
Figure 2: Illustration of the bucket handle motion observed in the lower ribs. (Starr and Dalton 2011:198)	4
Figure 3: Ossification types A-H as described by McCormick et al. 1985	19
Figure 4: Rib orientation and clamping system	37
Figure 5: Medial view of sternal end displaying digitizing path around the margin of the sternal end. A) location of sternal depth measurement.....	37
Figure 6: Diagram of landmarks: superior (A), anterior (B), inferior (C), posterior (D).....	38
Figure 7: Example of EFA sternal end output (Rib from rib group 1)	42
Figure 8: Example of EFA sternal end output (Rib from rib group 2)	42
Figure 9: PCA Plot for all rib groups based on Sex. 1=Female 2=Male	67
Figure 10: PCA Plot for All rib groups based on Age	67
Figure 11: PCA Plot for Rib Group 1 based on Sex. 1=Female 2=Male	68
Figure 12: PCA Plot for Rib Group 1 based on Age.....	68
Figure 13: PCA Plot for Rib Group 2 based on Sex 1=Female 2=Male	69
Figure 14: PCA Plot for Rib Group 2 based on Age.....	69
Figure 15: PCA Plot for Rib Group 3 based on Sex. 1=Female 2=Male	70
Figure 16: PCA Plot for Rib Group 3 based on Age.....	70
Figure 17: Example of extreme ossification preventing sternal depth measurement.....	71
Figure 18: Example of dried costal cartilage preventing sternal depth measurement.....	71
Figure 19: Example of Pattern 0. Anterior view with inferior point on the left.	72
Figure 20: Example of Pattern 9 (LLHL). Anterior view with inferior point on the left.....	72
Figure 21: Example of Pattern 12 (LLHH). Anterior view with inferior point on the left.....	73
Figure 22: Example of Pattern 10 (HLHL). Anterior view with inferior point on the left.....	73
Figure 23: Example of Pattern 4 (LHHH). Anterior view with inferior point on the left.....	74
Figure 24: Example of Pattern 5 (HHHL). Anterior view with inferior point on the left.....	74
Figure 25: Example of Pattern 3 (HHLL). Anterior view with inferior point on the left.....	75

CHAPTER ONE: INTRODUCTION AND GENERAL INFORMATION

Age estimation and sex estimation make up two of the main tenets of the biological profile used in forensic anthropology cases. One of the most widespread techniques developed to estimate age was created by İşcan et al. (1984) which used the morphology of the sternal ends of ribs. This technique was developed as an alternative to cranial suture age estimation and age estimation using the pubic symphysis. Their first study contained a reference sample of white males. In 1985 they published a new study that used a reference sample of white females. Later studies found that age estimation using rib sternal ends was found to be more accurate than age estimation using the pubic symphysis (Loth and İşcan 1988, Loth et al. 1990). Today when using the İşcan et al. (1984, 1985) aging method anthropologists usually estimate the sex of the individual first to determine which set of casts and descriptions to use for age estimation. This is due to changes that occur at and after puberty that affect the morphology of certain areas of the skeleton used for age estimation, e.g., public symphysis (Todd 1920 and 1921). These morphological changes or different rates of aging are attributed to differences in hormones and biomechanical function between males and females. While this is a crucial step when using the pubic symphysis as the site of age estimation, due to the morphological and functional differences between male and female pelvises, it is not as clear whether sex estimation is necessary before utilizing the sternal ends of ribs as the site of age estimation. Both İşcan and colleagues (1984, 1985) and

Hartnett (2010) state that the sex of the individual does affect the some of the morphology and ossification patterning of the sternal end and therefore separate descriptions and casts are needed for age estimation using sternal rib ends.

The goal for this study is to explore the extent of morphological differences between male and female sternal rib ends and how the sex of an individual can affect the degree of aging that is observed on the sternal rib ends. This information could be pertinent to cases where sex cannot be determined, either due to the necessary elements not being present or severely damaged or the morphology of the individual falling into the 'intermediate' or 'indeterminate' category. This study looks at whether anthropologists can still accurately estimate the age of an individual if the sex¹ of the individual is unknown or indeterminate. One way that this study does this is through the use of Elliptical Fourier analysis. This allows me to explore the differences in morphological shape between the sexes as well as examine whether age has an impact on the morphology.

One consideration before beginning this study is the biomechanics behind the rib cage. The thorax makes up a large unit in the body that consists of many elements, ribs, sternum, and thoracic vertebrae. Each assist with movement, protection and most importantly respiration of the body. Respiration requires a series of movements within the thorax. During this process the movement of

¹ For this specific study, the term 'sex' is referring to the biological sex that consists of the anatomy and physiology of an individual. This is not to be confused with 'gender' which refers the social construct that divides individuals into different cultural roles and social experiences (Johnson and Repta, 2011).

each rib is dependent upon their location within the rib cage (Starr and Dalton 2011). The first rib moves the least. It articulates with the manubrium of the sternum through a thick cartilaginous synchondrosis which is immediately inferior to the sternoclavicular joint. This prevents movement of the first rib at its sternal end. At the vertebral head the first rib articulates with a single facet which allows more mobility. As result, during inhalation the first rib is elevated through a superior and posterior movement of the costovertebral joint (Starr and Dalton 2011). In contrast ribs 2 through 5 articulate to the sternum directly through synovial joints which allow for a greater range of motion. As the length of the ribs increase so does the mobility. In the upper ribs, ribs 2 through 7, the ribs increase in length as they progress caudally, rib 7 is usually the longest (Starr and Dalton 2011). During inhalation the upper ribs help to increase the anterior to posterior diameter of the thorax by moving the sternum superiorly and anteriorly. This creates what is described as a “pump handle” movement of the upper ribs, anterior and superior motion of the sternal end (Figure 1). Ribs 8 through 10 indirectly articulate to the sternum through costal cartilage that combines with the cartilage of the previous rib to create an interchondral joint. They are also angled downward more than the upper ribs. These factors result in a more lateral elevation movement of ribs 8 through 10 during inhalation. This movement has been described as a “bucket handle” motion, which increases the transverse diameter of the thorax (Figure 2). Differences in biomechanics could

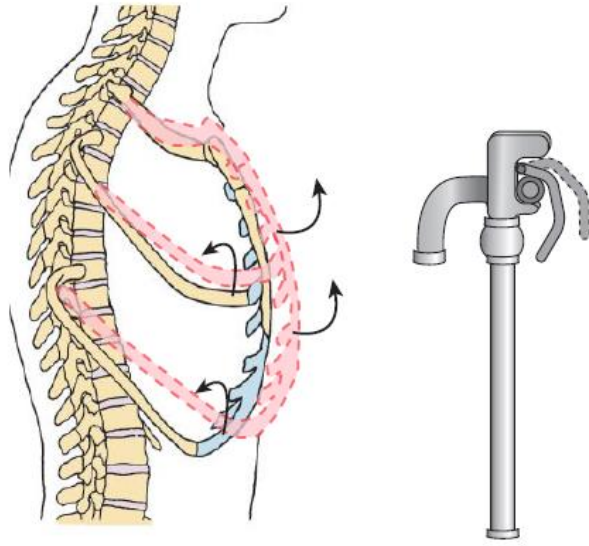


Figure 1: Illustration of the pump handle motion observed in the upper ribs. (Starr and Dalton 2011:198)

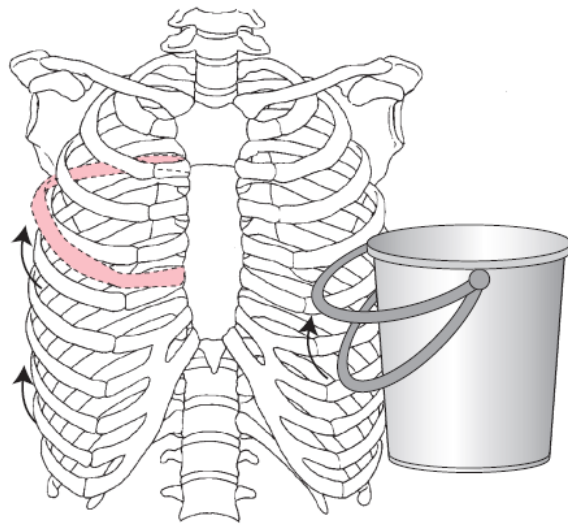


Figure 2: Illustration of the bucket handle motion observed in the lower ribs. (Starr and Dalton 2011:198)

result in differences in costal cartilage ossification and morphology of rib sternal end. For this reason, it is crucial to consider the location of ribs within the thorax when comparing rib morphology.

For this study I will be exploring two questions. The first is whether there is a significant difference in sternal rib end morphology between males and females. Many studies have been done that show that there are sexual dimorphic differences in size (Íşcan 1985, Koçak et al. 2003, Muñoz et al. 2018), and McCormick et al. (1985) and Middleham et al. (2015) showed that radiographically there are significant differences between male and female costal cartilage ossification. However, few studies have used elliptical Fourier analysis to look at the morphology of the sternal end as an indicator of sex, though many studies have noted some morphological differences (Íşcan and Loth 1986a, 1986b, Hartnett 2010b). My hypothesis for this question is the following:

- As in previous studies I expect to observe that the sternal ends of male ribs are overall larger than those of females. I also expect the corresponding sternal rib ends of males and females to have distinct shapes, e.g., male fourth rib to female fourth rib. Upon removing size as a factor, I do not expect that these shapes will vary significantly between male and female since ribs carry out similar functions in males and females, e.g., provide stability for muscles of the head, neck, spine, and

upper extremities, protection for heart, lungs, and viscera, and assist with respiration (Starr and Dalton 2011).

The second question focuses on whether males and females age at similar rates to the extent that sex would not significantly affect the overall result of age estimation. Can the sex of a set of remains affect age estimation for that set of remains? İşcan et al.'s (1984) original study was made up of only males and then followed by a study on only females (İşcan et al. 1984, 1985, 1986a, 1986b). As a result, there are separate sets of casts for each sex. I am interested in exploring whether it is necessary to have separate guidelines for each sex or is it possible to create a method of age estimation that could be used to for both male and female. My hypotheses for this question are as follows:

- I expect that males and females will exhibit similar aging processes.

However, when taking in account costal cartilage ossification as an aging process I would expect females to exhibit changes earlier than males, but males will exhibit ossification of costal cartilage at a greater degree than females particularly later in life.

CHAPTER TWO: LITERATURE REVIEW

Growth and development of the rib cage

Ribs are classified as flat bones and consist of a vertebral head which articulates with the body of one or two thoracic vertebrae, a costal neck, costal tubercle, which articulates with the transverse process of a thoracic vertebra, a costal shaft, and a sternal end, which articulates directly or indirectly by means of costal cartilage to the sternum. They begin forming during the embryonic stage of development. They originate from the somites which give rise to the axial skeleton of the embryo (Huang et al. 2000). As the embryo develops the ribs lengthen and extend anteriorly. The rib cage can be divided into two regions each of which have distinctive development patterns. The upper region is made up of ribs one through seven. These are usually referred to as “true ribs” because they attach directly to the sternum. As true ribs lengthen and develop, they converge medially to assist with development of the sternum. Ribs 8 through 12 make up the “false ribs”. Ribs 8 through 10 attach to the sternum indirectly through the costal cartilage of the previous rib and ribs 11 and 12, also referred to as “floating ribs”, do not articulate with the sternum at all.

Development of false ribs consist of lengthening caudally possibly due to the development of the rectus abdominis muscle (Okuno et al. 2019). Ribs first develop as cartilage but during the embryotic stage which is slowly replaced with bone beginning in the fetal stage. During the postnatal period the ribs continue to develop and ossify. The sternal end of the ribs extent caudally so that the

posterior or vertebral end is superior to the anterior or sternal end. Resulting in the ovoid thorax shape observed in adults. Around puberty secondary ossification centers develop close to the articular tubercles. The rib cage usually finishes developing in middle adolescence (Bastir et al. 2013). Many researchers have noted an increase in costal cartilage ossification as individuals age (Semine and Damon 1970, Navani et al 1970, Fischer 1955, Elkeles 1966, Sanders 1966, McCormick 1980). One early idea for the presence of ossified costal cartilage was that it was the result of a disease, particularly if observed in individuals younger than 30 years old (Rhomberg and Schuster 2014). Premature costal cartilage ossification has been tied to some endocrine disorders such as hyperthyroidism. However, beyond the age of 30, costal cartilage ossification seems to be a part of the degradation process of the sternocostal joint. As an individual ages collagen fibrils encroach on the degrading chondrocytes, cartilage cells, and increase mineralization (Dearden et al. 1974).

Effects of biological sex on ribs

In addition to age researchers have noted that costal cartilage ossification seems to differ between males and females. McCormick (1980) noted that males tended to have a higher degree of ossification than women. There has been some speculation that hormones might play a role in costal cartilage ossification differences between males and females. Differences in bone density between males and females have been attributed to the presence of estrogen. Estrogen which is found in both males and females has been linked to regulation of bone

metabolism (Khosla et al. 2012). It inhibits the osteoclasts from resorbing too much bone during bone remodeling. With the onset of menopause estrogen levels in females drop resulting in a decrease in bone density over time, which can lead to osteoporosis in older females (Khosla et al. 2012). In contrast male estrogen levels fluctuate very little and they are able to maintain a steady bone density. Based on these trends estrogen could be a possible cause for differences in costal cartilage ossification rates between males and females.

Males are, on average, 10% larger than females. This in turn could lead to differences in biomechanical stresses in the rib cage between males and females. In a study looking at lung volume between individuals of similar height it was found that females trended to have smaller lung volume as well as rib cage volume (Bellemare et al. 2006). However, when rib lengths were compared between males and females, no significant differences were found. When the ratio of rib length to body length were compared between the sexes it was found that females had a significantly greater rib length to body length ratio than males (Bellemare et al. 2006). One possible explanation for longer ribs in females could be to assist with abdominal volume displacement during pregnancy. The next few sections will explore the development of age estimation and sex estimation methods within the field of anthropology.

Age Estimation

One of the main tasks for forensic anthropologists when they receive a new forensic case is to develop a biological profile for the individual which

includes age, sex, stature, and ancestry. One of the most important aspects of the biological profile is age estimation. For age estimation there are two different processes that anthropologists look at, developmental and degenerative. The developmental phase of human skeleton usually ends around 30 years with the fusion of the epiphysis of the sternal end of the clavicle (White et al. 2012). Age of adolescents are usually estimated using epiphyseal fusion, dental development and eruption, and, in the case of infants, length of the long bones before epiphyseal fusion (Scheuer and Black 2000). While extremes in environment can affect the timing of skeletal development, the estimate intervals are small compared to age estimation intervals for adults (Scheuer and Blank 2000, Garvin et al. 2012).

Once the skeleton has fully developed, it starts to remodel and break down due to use and age. These degenerative and remodeling processes are what assist anthropologists in estimating age in adults. Over time joints break down, which can result in osteoarthritis. Bones lose density and cartilage ossifies. Cartilaginous joints that were pristine early in life remodel and break down (White et al. 2012). While anthropologists know that these processes take place later in life, the variability between individuals make it difficult to say exactly when they start to appear. When estimating the age of an adult skeleton there are a few sites of the skeleton that anthropologists use. The pelvis and ribs are two of the main sites of interest. However, this was not always the case.

Early anthropologists relied on cranial suture closure and obliteration. Sutures are fibrous, interlocking joints that connect cranial bones (White et al. 2012). Over time, sutures can “close” and in some cases disappear or obliterate. In 1924 Todd and Lyon published a study to explore the relationship of endocranial suture closure and age (Todd and Lyon 1924). In 1985 Meindl and Lovejoy added onto the original study by including a scoring system and a list of 10 specific ectocranial suture sites for observation (Meindl and Lovejoy 1985). Both of these studies concluded that while this technique might be helpful in conjunction with other aging techniques, suture closure is too variable to use for age estimation (Todd and Lyon 1924, Meindl and Lovejoy 1985).

One element that is used frequently for age estimation is the os coxa. One of the most reliable and frequently used sites in the os coxa is the pubic symphysis. This cartilaginous joint is located on the anterior portion of the bone and is where the left os coxa articulates with the right. This joint is fibrocartilaginous and only allows for one to three degrees of movement (White et al. 2012). Therefore, it does not suffer the variable wear and tear that is observed at synovial joints. This means that the wear observed at the pubic symphysis is more likely to age consistently across a population. Todd (1920) was one of the first to note the progression of pubic symphysis morphology with age. He created ten phases with accompanying age ranges based on the changes in morphology. In 1957, McKern and Stewart suggested the use of a three-component method for age estimation of the pubic symphysis which was

later expanded upon by Gilbert and McKern in 1973 (McKern and Stewart 1957, Gilbert and McKern 1973). However, Brooks and Suchey (1990) rejected the three-component method based on the argument that the three components did not vary independently of one another. They returned to Todd's (1920) phase method which they modified, by reducing the ten phases down to six and adding more sex specific age ranges (Brooks and Suchey 1990). In 2010, the method underwent a second revision where a seventh phase was added, and bone quality was included as a determining factor (Hartnett 2010a).

The auricular surface of the os coxa, the articulation point between the os coxae and the sacrum, has also been used for age estimation. Since the auricular surface was one of the more protected and durable joints of the human body that seemed to vary less between sexes and ancestral groups it seemed to be a promising site to use for age estimation. In 1985, Lovejoy and colleagues proposed a phase method for age estimation using the auricular surface. Their method consisted of eight phases and age ranges for each range (Lovejoy et al. 1985). As many researchers have pointed out the age ranges for the first seven phases were very narrow, 5 years for each, and the last phase is very large in comparison, 60 years and older (Garvin et al. 2012). This has caused issues with using the method for forensic cases. In 2002 a new component method was introduced by Buckberry and Chamberlain with varying results (Buckberry and Chamberlain 2002).

Age Estimation of the Ribs

Before 1980, anthropologists and pathologists were limited in which elements they could use for age estimation. This was before methods for the auricular surface had been developed so the two areas of focus were the pubic symphysis of the os coxa and cranial sutures. Understanding the need for more options for age estimation, McCormick (1980) conducted a preliminary study of the chest plate, consisting of sternum, costal cartilage, and 2-5 cm of the sternal end of the ribs. This study was geared toward pathologists who had very little experience with dry bone and used x-rays. The sample for this study consisted of 210 individuals whose ages ranged from three months to 86 years. McCormick noted that costal cartilage did not start to calcify until after puberty and that it was more delayed in females. Moderate ossification of costal cartilage was noted as unusual before the age of 40 but normal after the age of 60. McCormick (1980) concluded that ossification of the costal cartilage could be related to normal aging processes and therefore indicative of age.

Drawing inspiration from Todd's (1920) phase method for the pubic symphysis, İşcan and colleagues conducted several studies to create an age estimation phase method for the sternal ends of the ribs (İşcan et al. 1984, 1985, İşcan and Loth 1986a, 1986b). The first study consisted of 118 white, male right fourth ribs. İşcan and colleagues (1984) assigned ribs to nine phases (0-8) based on the changing morphology, texture, and overall quality of the rib. Individuals who were younger than 17 years old were placed in phase 0 since changes in morphology, with the exception of size do not occur until at least the

age of 16. İşcan et al. (1984) noted that over time an indentation would form and deepen in the medial articular surface of the rib. This indentation would slowly change in shape, v-shape to u-shape, and the walls of the pits would become thinner. They also noted that the rim surrounding the indentation would become more irregular as age progressed. The creation of the indentation in the medial articular surface and the changes in morphology of the rim around the indentation were the main areas of focus for categorizing ribs into phases.

In 1985 a second study was conducted using a white female sample (İşcan et al. 1985). The sample consisted of 86 white female right fourth ribs. The process to create phase groups was similar to the first study. However, in females the creation of the indentation began earlier than in males. Consistent with the male study the first four phases were where the authors note the most change in sternal end morphology.

Due to concerns of the original studies using an older, less contemporary sample, Hartnett applied the method to a modern sample in 2010. Her sample consisted of 419 males and 211 females with an age range of 18 to 99 years old (Hartnett 2010). When assigning phases to the modern sample Hartnett noted that the age ranges of the phases, based on the sample, should have been older. Revised age ranges as well as slight revisions to phase descriptions were suggested (Hartnett 2010). As opposed to the original 9 phases (0-8) listed in İşcan et al.'s (1984, 1985) studies, Hartnett suggests 8 phases (0-7) with a variant for males that addressed significant ossification of the costal cartilage.

Hartnett (2010) also argued that more emphasis should be put on the weight and quality of the bone in determining the phase for an individual (Hartnett 2010).

Sex Estimation

Another important aspect of the biological profile is sex estimation. Early sex estimation methods relied on comparison of os coxa morphology (Phenice 1969). Due to the role that childbirth has in females the morphology of the os coxa can vary between males and females. In 1969, T.W. Phenice developed a morphological method that used three morphological criteria on the pelvis to estimate sex for skeletal remains: ventral arc, subpubic concavity, and ischio-pubic ramus. These features were either scored as absent or present. Since this method only noted whether a feature was absent or present it failed to account for variation in degree of expression for each feature. Klales and colleagues addressed this in their 2012 article by adding an ordinal scale for degree of feature expression and a logistic regression that assists in calculating posterior probabilities for male and female.

Another skeletal area of interest for sex estimation is the skull. In an early study, Giles and Elliot (1963) explored sex estimation of the skull using cranial measurements and multivariate linear function. The results of the study were promising. However, the methods were developed using only American whites and Blacks, which limits the scope of application for other populations. In 2005 these methods were expanded on by Jantz and Ousley to create the discriminant functions program Fordisc 3.0. Which assists anthropologists with estimating

sex, ancestry, and stature of a set of remains through osteometrics. Other studies, such as Walker (2008), focused on the morphology of the skull for sex estimation. A total of five features were scored on an ordinal scale for degree of expression: nuchal crest, mastoid process, supraorbital margin, glabella, and mental eminence. The scores obtained for these features could then be applied to a multivariate discrimination function which would assist in calculating the probability that the skull is either male or female.

When the os coxa is unavailable for a case most anthropologists would reach for the skull as the second-best choice. However, some anthropologists have argued that this is not necessarily the case (France 1998, Spradley and Jantz 2011). Spradley and Jantz (2011) conducted a study that applied univariate and multivariate methods to cranial and postcranial measurements (Spradley and Jantz 2011). The authors were interested in whether the skull was a better indicator of sex than postcranial elements. They found that multiple postcranial elements, mostly long bones, were better estimators of sex than the crania. They also noted that the effectiveness of elements varied between ancestry groups. For American Blacks the best elements to use for sex estimation were humerus, clavicle, scapula and femur. In addition to those elements the radius, ulna and tibia did better than the crania at estimating sex in American Whites (Spradley and Jantz 2011). If the sternal ends of the ribs follow a similar trend then maintaining separate age estimation methods for male and female ribs would be essential.

Sex Estimation of the Ribs

Radiographs

Early radiographic studies of the rib cage noted that the amount of ossified costal cartilage present increased as the age of the individual increased (Semine and Damon 1970). However, these early studies focused more on possible diseases that cause costal cartilage ossification than its connection to skeletal aging processes (Semine and Damon 1970, Navani et al 1970). Many early studies noted small differences in ossification patterns between males and females (Fischer 1955, Elkeles 1966, Sanders 1966). Fischer (1955) and Navani et al. (1970) noted that over time males developed two ossified projections along the rim while females developed a single ossified projection in the pit of the sternal end. Both of these observations were later used by İşcan et al. (1984, 1985) to describe later phases in his age estimation method. However, it was not until 1985 that an extensive study of the sexual differences of the chest plate were carried out by McCormick and colleagues (1985). They conducted a study to compare ossification patterns of costal cartilage in males and females using roentgenograms. Their study, which consisted of chest plate roentgenograms from 1133 adult autopsies (698 males and 435 females with a range of ancestral backgrounds), looked at four measurements (sternal length, fourth rib width, width of the sternal body between incisurae costales II and III, and area of the sternum) and costal cartilage patterns to estimate sex. All of the measurements were taken directly from the roentgenograms and not the actual skeleton (McCormick et al. 1985).

For costal cartilage patterns the authors assigned each of the roentgenograms to one of seven ossification types, A-H (figure 3). Types A, B, C, and D were indicative of ossification traits common in females and types E, F, G, and H were indicative of traits found in males. In female patterns, the authors described the ossification as “pyramidal-shaped” and originating from the center of the pit (McCormick et al. 1985, 179). They also noted a crab claw morphology on the sternal end (shown in type B) in extreme cases of ossification of costal cartilage within females. The most common of the male ossification pattern types is Type E which consists of extensive ossification of the superior and inferior costal margins, creating a claw shape. Later studies would argue that the claw morphology is more indicative of males because it is observed across age groups within males and only with extreme ossification in females (Íşcan et al. 1984, 1985, Íşcan and Loth 1986a, 1986b). The authors also included an indeterminate pattern which was usually a combination of type B and C with type E and H. A null pattern was also included for individuals who exhibited little to no costal ossification. These usually consisted of younger individuals (McCormick et al. 1985).

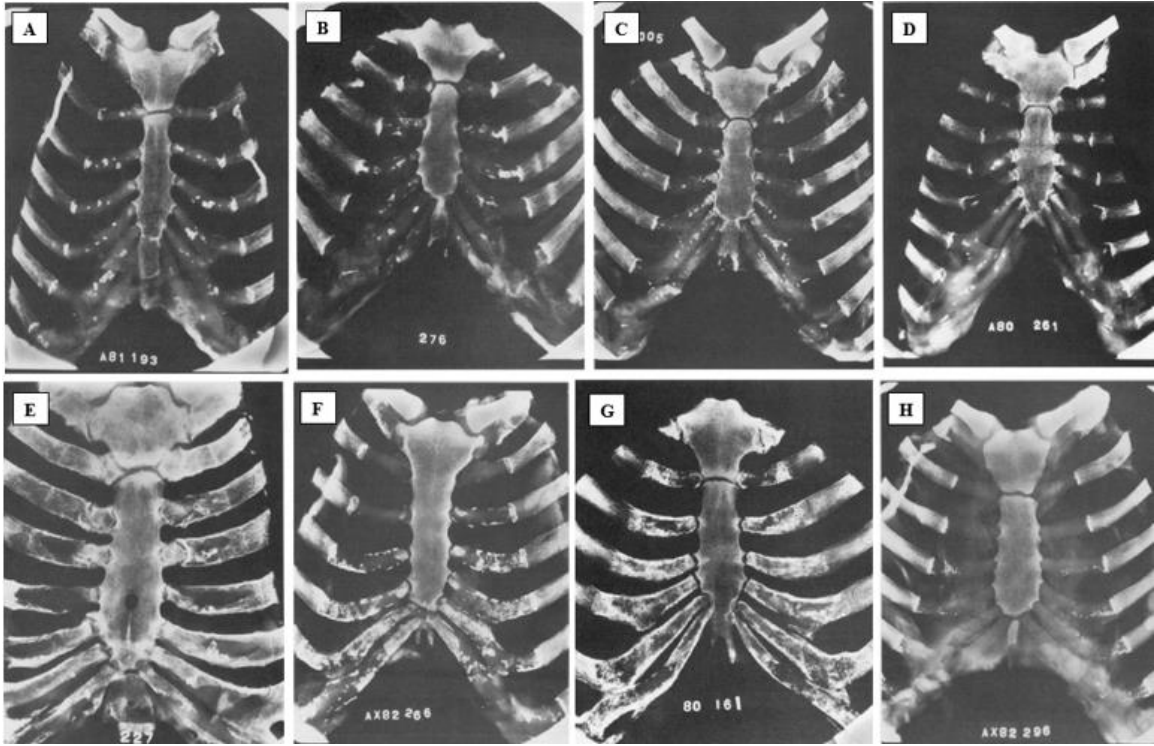


Figure 3: Ossification types A-H as described by McCormick et al. 1985

The authors created a simple algorithm to assist in age estimation. Roentgenograms were assigned values of +1, +2, +3 based on magnitude of a feature for each of the five characteristics (sternal length, fourth rib width, width of the sternal body between incisurae costales II and III which are the articulation points for ribs two and three to the sternum, area of the sternum and costal cartilage ossification patterns) (McCormick et al. 1985). For example, ossification patterns A, F and G were given a value of +3 because they were distinctively feminine or masculine respectively. Other ossification patterns required scores from one of the other characteristics before it could be determined whether they were more feminine or masculine. A weighted algorithm was used to combine the five features into a sex estimation. The sum of the weighted scores for all the features would determine if the roentgenogram was estimated as feminine or masculine. A negative score indicated a likely female and a positive score a likely male. Femininity and masculinity for the four different measurements of the thorax were based around cutoffs, where measurements larger than a certain point would be considered masculine and below that cutoff as feminine. However, the authors acknowledged that there is a gray area around the cutoff point which could make estimating sex difficult (McCormick et al. 1985).

Distinct, sex specific costal cartilage patterns were noted in 72% (825) of the 1133 study cases. Of those 825 individuals, sex was estimated correctly for 92% (McCormick et al. 1985). The authors found that length of the sternum and

width of the fourth rib were strong indicators for sex especially when used in conjunction with costal cartilage patterns. Overall McCormick et al. (1985) found that costal ossification patterns when used in conjunction with the four measurements taken of the chest plate could produce an average accuracy of 97%.

In 2004 Rejtarová et al. created a method focusing solely on costal cartilage ossification observed on chest and abdominal radiograms. Their method consisted of grouping radiographs into four groups: Type I peripheral pattern (costal cartilage ossification at the superior and inferior margin), Type II central pattern (initial ossification in the center of the sternal face, Type III mixed (a combination of types I and II), and Type IV indifferent pattern (no distinct pattern). Rejtarová and colleagues (2004) found that there were possible sexual dimorphic differences in costal cartilage ossification patterns that could help with sex estimation of unidentified individuals.

A more recent study in Scotland explored McCormick et al.'s (1985) original work. The authors were interested in testing how accurate McCormick et al.'s (1985) method, Rejtarová et al.'s (2004) method, and their own methods would be on a Scottish population (Middleham et al. 2015). Middleham et al.'s (2015) sample consisted of chest plates of 41 individuals, 22 males and 19 females, from the laboratory of Human Anatomy, University of Glasgow. Each chest plate was radiographed and then two of the authors estimated sex from each of the radiographs using the three different methods (McCormick et al.

1985, Rejtarová et al. 2004, and Middleham et al. 2015). When developing their own method, they found the two earlier works lacking in descriptions of texture or different degrees of radio-opaqueness for the patterns. Middleham et al. argue that patterns tended to be a combination of bony trabecular appearance, less radio-opaque and displaying ossification patterns similar to the structure of trabecular bone, and dense radio-opaque calcified deposits. They were interested in whether the calcification observed was predominantly the bony trabecular pattern or the calcified deposits pattern. They suggested males tended to have more of a calcified trabecular bone pattern while females had more of a calcified deposit pattern

Of the three methods used for sex estimation, Middleham and colleagues (2015) found that Rejtarová et al. (2004) provided the least accurate results. Out of the 41 individuals examined, 22 classified as sex indeterminate and of the remaining 19, 8 individuals, were misclassified as female. The McCormick et al. (1985) proved to be more accurate with classifying only seven individuals as indeterminate. Of the remaining 34 individuals 38% were misclassified (Middleham et al. 2015). The authors found that Type A and Type E were the most reliable of the patterns described by McCormick et al. (1985). For their own method they classified 10 individuals as indeterminate due to minimal or no calcification. Of the remaining 31 individuals, 10% were misclassified. Middleham and colleagues (2015) noted that for individuals older than 50 years,

age did not seem to be a factor in the proportion of calcified deposits patterning to trabecular bone patterning observed.

Osteometrics

While McCormick and colleagues were examining the morphology of costal cartilage ossification as a means of sex estimation, other scientists turned to osteometric approaches to explore the sexual dimorphism of the ribs. Íşcan (1985) conducted one such study. Unlike earlier studies that focused on measurements and observations taken from radiographs, Íşcan (1985) decided to take direct measurements and observations of the bones. His sample consisted of fourth ribs taken from autopsy of forensic cases with known age, sex, and ancestry. For 230 individuals, 144 males and 86 females, Íşcan compared the maximum superior to inferior height, maximum anterior to posterior breadth and the maximum pit depth of the male ribs to the female ribs. He also divided the samples into different age groups, young, old, and combined which consisted of all age groups. The young group contained individual ribs who fell into Íşcan et al. (1984, 1985) Phases 1-4 with mean ages of 14 to 28. The old group covered Íşcan et al. (1984, 1985) Phases 4-7 with mean ages of 28 to 65 and the combined group covered Phases 1-7. Ribs that fell into Phase 0 or 8 were excluded from this because those ribs had not completely developed or were too deteriorated to use. A stepwise discriminate function was calculated for each group for statistical analysis.

Overall, Íşcan found that males typically had larger dimensions and that there appeared to be significant differences between males and females, particularly for maximum superior to inferior height (Íşcan 1985). The coefficients from the stepwise discriminate function suggested that most of the differences between the sexes were mostly dependent on size. While that average classification accuracy was high for both the young and old groups, 82% and 89% respectively, Íşcan (1985) noted that females were more accurately classified in the young and combined age group than males. When a test was run to see if the functions created for the old group could be applied to the young group, Íşcan found that 67.6% to 73.5% of the young males were misclassified as female. When the opposite test was applied, the function for the young group to the old group, 33.3% of the females were misclassified as male. He further noted that age seemed to influence the sexual differences because all three measurements were significant in the old group but for the younger and combined group only maximum superior to inferior height and maximum anterior to posterior breadth were significant (Íşcan 1985).

More recent studies have followed this osteometric approach to sex estimation. Íşcan and colleagues (1987) noted that ancestry made a difference in age estimation using the sternal ribs, particularly in older individuals. Later studies were interested in exploring whether the same was true for sex estimation of the sternal end of the ribs. Wiredu et al. (1999) attempted Íşcan's study with a contemporary West African Black reference sample. Like Íşcan

(1985), they used the right fourth rib. Their sample consisted of coroner cases of 346 individuals, 221 males and 125 females. The sample was split into three groups: younger than 30 years, older than 30 years, and a combined group of the young and old group. They measured the maximum superior to inferior height and maximum antero-posterior thickness of the sternal end. Wiredu et al. (1999) were interested in creating their own discriminate functions for sex estimation as well as testing İşcan's original discriminant functions on a non-white population. To test the reliability of the discriminant functions developed during this study, a separate 'test sample' of 74 Ghanaians was used.

While the authors found that there were significant differences between males and females, which is consistent with İşcan's 1985 study, the discriminant function created by İşcan misclassified a majority of the males in the West African sample as female. The authors argue that this suggests that the discriminant functions are population specific (Wiredu et al. 1999), something that İşcan discussed briefly at the end of his 1985 study. When developing their own stepwise discriminant function, they found that the maximum superior to inferior height contributed the most, at least 84%, to the discriminant function. This is consistent with the findings of İşcan's (1985) study. Overall, the superior to inferior height proved the best for discriminating between the sexes for all three groups. The antero-posterior thickness worked for distinguishing male from female in the older and combined groups but due to lower average measurements in younger males antero-posterior thickness was less accurate in

the younger group (Wiredu et al. 1999). The average correct classification rates ranged from 74 to 90% for the test sample which revealed that the discriminant functions developed during the study were reliable and effective for estimating sex in a West African reference sample (Wiredu et al. 1999).

A similar study in Turkey reached results that were consistent with Íşcan's 1985 and Wiredu et al.'s (1999) results. In 1998, Çölođlu et al. conducted a study to create a discriminant function technique, similar to Íşcan's (1985) discriminate function, that would assist in the estimation of sex in a Turkish reference sample (Çölođlu et al.1998). Their sample consisted of right fourth ribs of 294 individuals from Istanbul, 150 males and 144 females, taken from forensic cases of known age and sex. The two measurements that they used for their discriminant function were maximum superior-inferior height (SI) and maximum anterior-posterior breadth (AP). To control for age, they divided their sample into three groups: "young", 17-29 years and Íşcan et al. (1984, 1985) Phases 1-4, "old", 30-63 years and Phases 4-7, and "total", 17-63 years and Phases 1-7 (Çölođlu et al.1998). Discriminant functions were created for each group and then the function for the young group and old group were cross validated with each other.

Of the two measurements used, superior-inferior height was found to be the more discriminating of the two, contributing 72% or more to the function (Çölođlu et al. 1998). The average accuracy of the function for the young group was 85.5%. For the old and total groups, the average accuracy was 89.5% and

88% respectively. The authors noted that for all three groups females were more accurately classified than males. In the cross-validation of the young and old discriminate functions they found that the old function misclassified more of the males in the young group, 38.1%, as female than for the young function. For the young function, the opposite was observed where more of the females were misclassified as male (22.2%) (Çöloğlu et al. 1998). When the original discriminant function from İşcan's (1985) study, a study that used only a White American reference sample, was applied to the Turkish sample the authors found that nearly half of the males were misclassified as females, but almost all of the females were classified correctly. The authors concluded that this was due to the differences in body size between North American Whites and Turkish individuals (Çöloğlu et al. 1998).

In response to this study, another study on sex estimation using the sternal end of the ribs in a different Turkish population was conducted in 2003 (Koçak et al.). They use a sample of 251 Turks from Izmir, 173 males and 78 females, and applied İşcan's (1985) method, creating their own stepwise discriminant function (Koçak et al. 2003). Their sample was split into three groups: young, 15 to 32 years old which covered İşcan et al.'s (1984, 1985) Phases 1-4, old, 33-89 years old Phases 5-8, and total, 15 to 89 years old Phases 1-8. Similar to the study conducted by Çöloğlu et al. (1998), Koçak et al. (2003) used the measurements superior to inferior height (SIH), anterior-posterior breadth (APB). However, they added in a third measurement that had

been used in İřcan's 1985 study, medial pit depth (MPD). Out of the three measurements, SIH was the most effective predictor of sex which is consistent with earlier studies (İřcan 1985, Wiredu et al. 1999, ölođlu et al. 1998). However, medial pit depth was found to be ineffective in all three groups (Koak et al. 2003).

Macaluso et al. (2012) explored sexual dimorphism of the sternal end of the fourth rib in a Southwestern Spanish reference sample to develop better methods to estimate sex. Their sample consisted of right fourth ribs from 117 individuals, 60 males and 57 females, taken from forensic cases in southwestern Spain. Like previous studies the authors looked at superior-inferior height (SIH) and anterior-posterior breadth (APB). They divided their sample into three age categories: younger, 18 to 39 years, older, 40 to 89 years, and combined, 18 to 89 years. However, after running an ANOVA test comparing the means of the different age groups for male and female, which gave p-values > 0.05, the authors concluded that sexual dimorphism was independent of age and that different age groups were not necessary for the statistical analysis (Macaluso et al. 2012).

The authors noted significant differences between males and females for the SIH and APB measurements, which was consistent with earlier studies. With their population specific discriminant function Macaluso et al. (2012) were able to achieve an accuracy 83.8% and 76.9 when using discriminant functions for SIH or APB respectively. When used in combination the accuracy rose to 86.3%. In

a comparison with other populations (North American Whites, Turks, and West Africans), the Spanish reference sample was found to be most similar to the North American White reference sample. The North American reference sample had slightly larger SIH than the Spanish reference sample. However, the Spanish had the largest APB out of all of the reference samples. When the discriminant functions for the North American White reference sample were applied to the Southwestern Spanish reference sample it classified 86% of the females correctly. However, 23.3% of the males were misclassified as female (Macaluso et al. 2012).

Other Studies

Other studies that explore age estimation of the ribs have noted differences between male and female ribs. A recent study in Japan using 3D postmortem images to examine changes in the degree of costal cartilage ossification for age estimation noted significant differences between male and female ossification rates of the first costal cartilage (Monum et al. 2020). These sexual dimorphic differences are what led İşcan and colleagues (1984, 1985) to create two different age estimation methods for males and females. İşcan (1985) and other authors (Semine and Damon 1975, İşcan et al. 1985) have all suggested that differences in morphology between male and female could be due to differences in hormonal production. Semine and Damon (1975) note in their study of ribs from five different reference samples that ossification of costal cartilage in females increases into the 20s and then slows down until 40s and

50s. Whereas in males they saw a steady increase of ossification into the 40s and then a slowed increase until 70 years and older. Overall, this means that males have greater ossification than females. Most of these studies have shown that males are overall larger in size. Semine and Damon (1975) suggest that because males are larger it can result in greater biomechanical stimulus for chest expansion during inhalation. This in turn, contributes to a higher degree of costal cartilage ossification particularly in the lower ribs.

Geometric Morphometrics

The study of shape and shape change of organisms has played a large role in the fields of biology and anthropology. Early studies consisted of observations of shapes and recoding of metric observations as a means to understand shape variation within and between groups of organisms (Richtsmeier et al. 2002). Early on there was a push for quantitative biological research and with it came the introduction of modern statistical methods such as multivariate statistics and significance testing to the field of biology (Richtsmeier et al. 2002). Such statistical analyses have become commonplace and, in most cases, required for published analyses of biological data (Richtsmeier et al. 2002). However, in the latter half of the 20th century there was a shift from multivariate studies back to the geometry of biological shapes. This movement and the methods developed became what we know as the field of geometric morphometrics, which is defined by its fusion of geometry and biology to describe shapes in 2-dimensional and 3-dimensional space without compromising the

integrity of the shape by reducing it to a set of lines and angles, which lack geometric relationships of the whole (Richtsmeier et al. 2002, Bookstein 1982).

Elliptical Fourier Analysis

One example of morphometric analyses used today is Elliptical Fourier Analysis (EFA). This method was developed as an extension of the original Fourier analysis developed by Jean Baptiste Joseph Fourier (1768-1830), which described periodic or oscillating functions, e.g., repeating patterns along an axis of time (Caple et al. 2017). Fourier's main interest was in heat transfer. However, Cosgriff (1966) found that Fourier's method was applicable to closed contours in that they could also be treated as repeating patterns. Fourier Analysis transforms geometric data from a spatial domain into a frequency domain by reducing the complex form to simple sine and cosine waves (Caple et al. 2017). The summation of these simple waves is used to create complex waves that encode both sets of data, e.g. x and y coordinates. In the case of a simple circle the x and y coordinates can be plotted along a time series (t -axis) with the y -coordinate creating a sine wave and the x -coordinate creating a cosine wave. The formula for the complex wave of the circle would be as follows:

$$y = \cos(t) + \sin(t)$$

In the case of more complex shapes, additional orders of sine and cosine terms, denoted harmonics, are required. This is represented by:

$$y = f(t) = A_0 + \sum_{n=1}^k A_n \cos(nt) + \sum_{n=1}^k B_n \sin(nt)$$

where:

y is the wave amplitude (dependent variable)

A_0 is the constant

A_n and B_n are the harmonic coefficients of the n th order

t represents the points sampled from the t -axis given by the period 2π

The shape of an object can be defined by an infinite number of harmonics and as the number of harmonics increases so does the level of detail captured by Fourier terms (Caple et al. 2017).

Whereas Fourier analysis encodes shapes as a single 1D signature function, Elliptical Fourier analysis, as defined by Kuhl and Giardina (1982), uses two signature functions (one for x -coordinates and one for y -coordinates) to create a chain of ellipses that move in time and around one another. Since it uses two signature functions, EFA has four coefficients per harmonic (a_n, b_n, c_n, d_n) which defines the harmonic as an ellipse. Therefore, the parametric functions for x and y would be the following:

$$x(t) = A_0 + \sum_{n=1}^k (a_n \cos nt_n + b_n \sin nt_{n-1})$$

$$y(t) = C_0 + \sum_{n=1}^k (c_n \cos nt_n + d_n \sin nt_{n-1})$$

where:

t is the collective chord length of the outline points, scaled from 0 to 2π

a_n, b_n, c_n, d_n are the Fourier coefficients defining each harmonic

k is the maximum number of harmonics used

A_0 and C_0 are the constants that represent the weighted x and y coordinates of the center of the form (Kuhl and Giardina 1982).

The Fourier coefficients (a_n, b_n, c_n, d_n) are used as the basis for statistical analysis of shape for EFA. Because ellipses are used EFA is optimal for replicating curves and natural shapes, such as the contour of bones, but has issues with straight lines and sharp angles (Caple et al. 2017).

One of the first applications of EFA was identifying the silhouette of aircrafts from radar images. However, in recent years EFA has picked up traction in the field of forensic anthropology (Caple et al. 2017, Tanaka et al. 2000). Elliptical Fourier analysis has shown great promise in sex estimation and identification studies (Tanaka et al. 2000, Lestrel et al. 2011, Christensen 2004 and 2005). In the case of sex estimation, not only can researchers compare size differences, but with the assistance of EFA's size normalizing feature, researchers can isolate shape-based features. An example of this is Tanaka and colleague's (2000) study of sexual dimorphism of the proximal humerus in Japanese adults. They found that after they size-normalized their sample that males tended to have a more pronounced lesser tubercle and less pronounced greater tubercle than their female counter parts.

While EFA has shown quite a bit of success in the area of sex estimation it has also been useful in identification studies. Using EFA, Christensen (2004, 2005) was able to trace and compare the outlines of the frontal sinuses on

radiographs. She found through the use of log likelihood ratios she could correctly match an individual radiograph based on the frontal sinus outline and 20 harmonics with an odds of 10^{21} to 1. This suggested that frontal sinus could be used as a plausible identifier since it has a high individuating power. A study in 2015 found that the patella held promise as an individuating factor when using EFA to compare the lateral outline of patellae from radiographs to rotated shadowgrams of 3D scans (Niespodziewanski et al. 2016). A total of 40 harmonics were used to generate Fourier descriptors for each image. Pairwise comparisons of the Fourier coefficients were used to rank the shadowgrams with the radiographs. For 20 of the 22 specimens the top five ranked images contained the correct match and for 16 of the 22 the top ranked image was the correct match (Niespodziewanski et al. 2016).

CHAPTER THREE: MATERIALS AND METHODS

Methods

Sample

This study examined whether there are significant differences between male and female sternal rib end morphology as individuals age. The sample consisted of white males and females from the UTK Donated Skeletal Collection at the University of Tennessee. To control for aging processes, samples were divided into five age ranges (40-49 years, 50-59 years, 60-69 years, 70-79 years, 80+ years). Older age ranges were chosen due to the higher incidences of autopsies in younger individuals in the collection which could result in separation or loss of the sternal ends of the ribs. This was also to avoid developmental changes since this study focuses on changes between males and females due to aging or degradation of bone which occurs after the ribs are fully developed. A power analysis was carried out using the original İşcan (1985) study and a sample size of 25 individuals for both sexes in each age group was found to be sufficient for the current study. Therefore, 25 males and 25 females were used for each age range, which brought the total number of individuals to 250. Multiple studies have noted significant differences in ossification patterns between the different classes of ribs (Monum et al. 2020, Yoder et al. 2001, Semine and Damon 1975), for this reason three rib groups were analyzed for each individual. They consist of the following: rib group 1 (first and second rib), rib group 2 (rib 4 and 5) and rib group 3 (rib 8 and 9). One rib from each group was selected for each individual resulting in a total of 750 ribs. To identify the ribs needed for this

study the rib siding and sequencing technique as described by Mann (1993) was applied. For consistency left ribs were predominantly used. However, there were several individuals in which the preservation on the right side was better than the left, therefore the right side was analyzed. Autopsied individuals were excluded from the sample where the autopsy process extended to the removal of sternal rib ends. Individuals with trauma to the thorax were also excluded from this study due to the fragmentary nature of the ribs unless the sternal end could easily be identified, refitted and sequenced.

Digitizing

Each of the ribs was held in place using a vice clamping system with the sternal end of the rib oriented superiorly (Figure 4). For each rib, the external surface of the bone at the termination of the rib was plotted using a MicroScribe 3D Digitizer. The shape of the sternal end was captured using continuous landmarks 5 millimeters (mm) apart, along the margin of the sternal end (Figure 5). In most cases there was a clear line between the rib margin and any ossified costal cartilage. In cases where the margin was unclear the point on the margin with the least ossification was used as the reference point for digitizing the continuous landmarks. Four landmarks (most anterior, posterior, superior, and inferior points) were marked to keep the plotting of the continuous landmarks consistent and in a straight line with no more than 3mm difference on the z axis (Figure 6). The contour was traced starting at the inferior point,



Figure 4: Rib orientation and clamping system




Figure 5: Medial view of sternal end displaying digitizing path around the margin of the sternal end. A) location of sternal depth measurement.

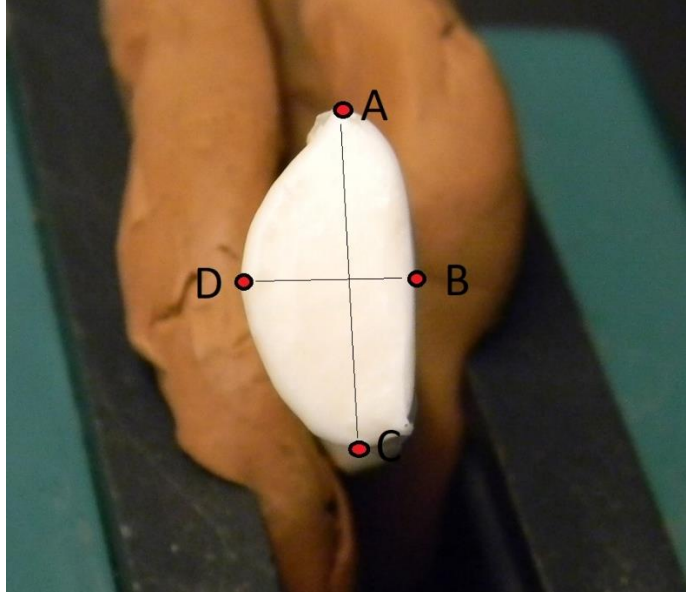


Figure 6: Diagram of landmarks: superior (A), anterior (B), inferior (C), posterior (D)

moving next to the anterior point then superior and posterior until it ended at the inferior point. This sequence was used for both left and right ribs. The four landmarks were located by taking the most anterior point and drawing a straight line to the most posterior point. The superior and inferior landmarks were located on a line perpendicular to the anterior-posterior line. These points were used to measure the thickness of the ribs and walls of the sternal end. At each of these landmarks, measurements were taken of the amount of ossification beyond the sternal end. Differences in the rate of costal cartilage ossification was analyzed with the help of an ordinal scale. The ordinal scale ranged from 0mm, coded as '0' to 40+mm, coded as '9' and it was used to explore ossification rates between sexes and between age groups. İşcan et al. (1984, 1985) noted changes in the depth of the sternal pit over time, so in addition to the continuous landmarks, a depth measurement was taken to capture the depth of the sternal end. For this, one point was plotted on the sternal end face, avoiding the pit if there is one. This measurement was taken three times and the average taken of those three trials was used. The depth point was compared in reference to the continuous landmarks. The coordinate data were stored in an excel spreadsheet for statistical analysis and comparison of the shape of the sternal ends in R (2022).

Data Analysis Methods

Elliptical Fourier Analysis

The data were converted into a csv file to be used in R (2021). For the Elliptical Fourier Analysis portion of the thesis the package *Momocs* was used. The code consisted of data reorganization, transformation, and the creation of *coo* objects for the eigen-shape analysis.

Statistics

Because the focus is the differences in the shape of rib sternal ends between males and females, a principal component analysis (PCA) was used. For ossification rates a repeated measures analysis of variance (ANOVA) analysis in R (2021) was used to determine if there were significant differences between males and females as well as between age groups. A repeated measures ANOVA was chosen because multiple measurements per rib were being compared. An ANOVA test was also used to compare changes in sternal end depth over time and between males and females. As multiple authors (McCormick et al. 1985, Middleham et al. 2015, İşcan and Loth 1986a, 1986b, Hartnett 2010b) have shown that there are differences in the ossification patterning between male and females, the different sites of ossification were also compared to determine if there was a significance in the patterning of ossification observed in this study. The frequency of each pattern was analyzed, and an ANOVA test was used to determine if sex or age played a significant role in ossification patterning.

CHAPTER FOUR: RESULTS

A total of 250 individuals were used for this study. Four individuals lacked a usable rib for one of the rib groups resulting in a total of 746 ribs. Table 1 shows the age distribution for each age group. Figures 7 and 8 show examples of the outputs from the Elliptical Fourier Analysis for a rib from rib group 1 and a rib from rib group 2. Figures 9 through 16 (Appendix A) show the results for the Principal of Component Analysis. Because the sternal end of ribs are fairly simplistic in shape only one or two harmonics were needed for the analysis. Rib group 2 was the only group that used two harmonics, the rest used one. An ANOVA test was used to explore whether sex or age were significant factors for differences in PC1 and, in the case of rib group 2, PC2. The results can be found in Tables 2-6. When all ribs groups were compared together, both sex and age were found to be significant for PC1. A follow-up test was done to look at whether the interaction between sex and age was also a factor in differences in PC1 and it was found to be significant. Similar trends were seen for PC1 in rib groups 1 and 2 individually. However, the p-value for sex to age interaction was not significant for rib group 2. For rib group 3 sex was found to be the only significant factor. When looking at PC2 for rib group 2 both sex and age came back as significant, but the interaction between the two was not significant.

Table 1: Age distribution of Female and Male Sample

Age Group	Sex					
	Female			Male		
	N	Mean	S.D.	N	Mean	S.D.
40-49 Years	25	45.92	2.4	25	45.8	2.3
50-59 Years	25	54.36	3.4	25	54.84	2.6
60-69 Years	25	64.8	3.2	25	64.4	2.5
70-79 Years	25	73.92	2.8	25	73.36	2.9
80+ Years	25	85.84	4.5	25	85.28	4.3

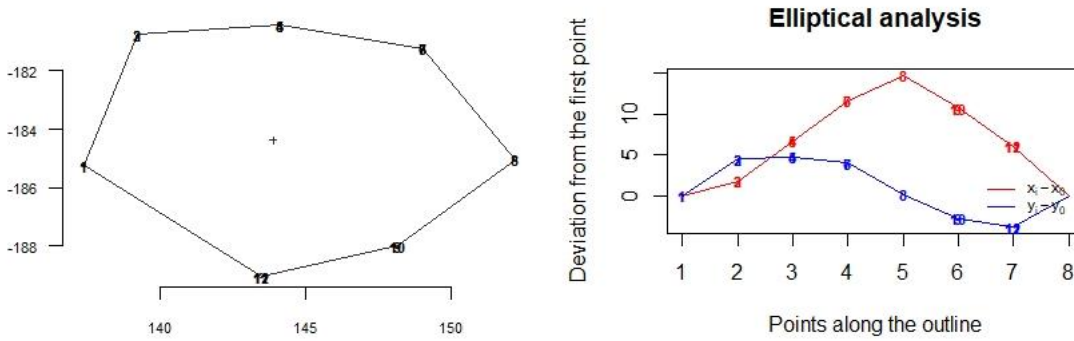


Figure 7: Example of EFA sternal end output (Rib from rib group 1)

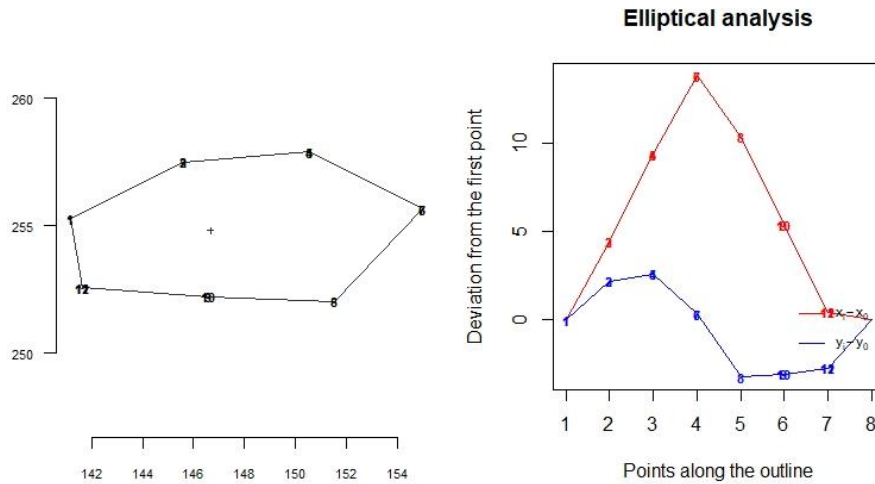


Figure 8: Example of EFA sternal end output (Rib from rib group 2)

Table 2: ANOVA results for comparisons of first principal components for elliptic Fourier analyses between all rib groups. **Bold text** indicates significant p -values.

Factor	Degrees of freedom	Sum of squares	Mean square	F	p -value
Sex	1	2.92	2.92	22.03	<0.05
Age	51	13.16	0.26	1.95	<0.05
Sex * Age	42	8.99	0.21	1.62	<0.05

Table 3: ANOVA results for comparisons of first principal components for elliptic Fourier analyses for rib group 1. **Bold text** indicates significant p -values.

Factor	Degrees of freedom	Sum of squares	Mean square	F	p -value
Sex	1	1.32	1.32	16.75	<0.05
Age	51	7.46	0.15	1.86	<0.05
Sex * Age	42	9.90	0.24	3	<0.05

Table 4: ANOVA results for comparisons of first principal components for elliptic Fourier analyses for rib group 2. **Bold text** indicates significant p -values.

Factor	Degrees of freedom	Sum of squares	Mean square	F	p -value
Sex	1	0.77	0.77	7.05	<0.05
Age	51	11.12	0.22	1.99	<0.05
Sex * Age	42	6.2	0.15	1.35	0.1

Table 5: ANOVA results for comparisons of second principal components for elliptic Fourier analyses for rib group 2. **Bold text** indicates significant p -values.

Factor	Degrees of freedom	Sum of squares	Mean square	F	p -value
Sex	1	0	0	6.06	<0.05
Age	51	0.07	0	1.85	<0.05
Sex * Age	42	0.04	0	1.34	0.1

Table 6: ANOVA results for comparisons of first principal components for elliptic Fourier analyses for rib group 3. **Bold text** indicates significant p -values.

Factor	Degrees of freedom	Sum of squares	Mean square	F	p-value
Sex	1	0.85	0.85	5.46	<0.05
Age	51	10.45	0.2	1.31	0.11
Sex: Age	42	8.32	0.2	1.3	0.13

For sternal depth analysis a total of 729 ribs was used. Due to the extreme amount of ossification or presence of dried costal cartilage (see Figures 17 and 18 in Appendix A) the sternal depth was unattainable on 17 ribs which were excluded from this portion of the study. When a two-way ANOVA test was applied to all rib types at once, both sex and age were found to be statistically significant (Table 7). A follow up test was applied to explore whether the interaction between sex and age was significant, and it was found to be not statistically significant (Table 7). When individual rib types were used sex and age were found to be statistically significant for all three rib groups (Table 8-10).

A two-way repeated measurements ANOVA test was used to test for statistical significance of ossification rates across all age groups and rib types (Tables 11-14). Age was the only factor found to be statistically significant. When the data were split into the individual rib types, age was found to be significant for rib groups one and two but not for three Sex was not found to be statistically significant for any of the rib groups. For pattern analysis the landmarks (anterior, posterior, superior, and inferior) were either scored as 'high' or 'low' based on their relation to the amount of ossification at the other landmarks on each rib. This was to reduce the effect of ossification rate as a confounding variable. A total of 15 patterns were observed. These ranged from no difference in ossification rates across landmarks to marked differences in ossification at one or more landmarks (e.g., greater ossification seen on superior and inferior aspects as opposed to anterior or posterior. A list of the different

Table 7: ANOVA results for comparisons of sternal end depths between all rib groups. **Bold text** indicates significant p -values.

Factor	Degrees of freedom	Sum of squares	Mean square	F	p -value
Sex	1	276.14	276.14	312.49	<0.05
Age	1	48.07	48.07	54.39	<0.05
Sex * Age	1	2.87	2.87	3.25	0.07

Table 8: ANOVA results for comparisons of sternal end depths for rib group 1. **Bold text** indicates significant p -values.

Factor	Degrees of freedom	Sum of squares	Mean square	F	p -value
Sex	1	99.53	99.53	105.12	<0.05
Age	1	15.51	15.51	16.38	<0.05
Sex * Age	1	0.12	0.12	0.13	0.72

Table 9: ANOVA results for comparisons of sternal end depths for rib group 2. **Bold text** indicates significant p -values.

Factor	Degrees of freedom	Sum of squares	Mean square	F	p -value
Sex	1	78.88	78.88	82.97	<0.05
Age	1	12.73	12.73	13.4	<0.05
Sex * Age	1	3.07	3.07	3.22	0.07

Table 10: ANOVA results for comparisons of sternal end depths for rib group 3. **Bold text** indicates significant p -values.

Factor	Degrees of freedom	Sum of squares	Mean square	F	p -value
Sex	1	98.18	98.18	131.47	<0.05
Age	1	20.16	20.16	27	<0.05
Sex * Age	1	2.42	2.42	3.24	0.07

Table 11: Repeated measures ANOVA results for comparison of amount of ossification between all rib groups. **Bold text** indicates significant *p*-values.

Factor	Degrees of freedom	Sum of squares	Mean square	F	<i>p</i>-value
Sex	1	0	0.04	0.02	0.89
Age	1	17	16.86	8.41	<0.05
Rib Group	1	0	0.3	0.15	0.7
Sex * Age	1	0	0.44	0.22	0.64
Sex * Rib Group	1	1	1.33	0.66	0.42
Age * Rib Group	1	0	0.23	0.11	0.74
Sex * Age * Rib group	1	2	2.04	1.02	0.31

Table 12: Repeated measures ANOVA results for comparison of amount of ossification for rib group 1. **Bold text** indicates significant *p*-values.

Factor	Degrees of freedom	Sum of squares	Mean square	F	<i>p</i>-value
Sex	1	2	2	0.95	0.33
Age	1	10	10	4.72	<0.05
Sex * Age	1	0.4	0.41	0.19	0.66

Table 13: Repeated measures ANOVA results for comparison of amount of ossification for rib group 2. **Bold text** indicates significant *p*-values.

Factor	Degrees of freedom	Sum of squares	Mean square	F	<i>p</i>-value
Sex	1	0.5	0.47	0.17	0.68
Age	1	15.5	15.54	5.66	<0.05
Sex * Age	1	6.1	6.14	2.24	0.14

Table 14: Repeated measures ANOVA results for comparison of amount of ossification for rib group 3. **Bold text** indicates significant p -values.

Factor	Degrees of freedom	Sum of squares	Mean square	F	p-value
Sex	1	0.0	0.02	0.02	0.89
Age	1	0.0	0.03	0.03	0.86
Sex * Age	1	0.4	0.42	0.37	0.54

patterns can be found in Table 15 and Figures 19-25 in Appendix A show examples of the most frequent patterns observed in males and females. An ANOVA test was used to explore the statistical significance for sex, age and rib group on differences in patterning (Tables 16-19). When all the ribs were analyzed together, both sex and age were found to be statistically significant. The trend of statistical significance of sex carried over to the individual rib groups. However, age was not found to be statistically significant for any of the individual rib groups.

Table 15: Ossification patterns observed 0= no different, L=low, H=high

OSSIFICATION PATTERN	LANDMARKS			
	Anterior	Posterior	Inferior	Superior
0	0	0	0	0
1	L	H	L	H
2	L	H	H	L
3	H	H	L	L
4	L	H	H	H
5	H	H	H	L
6	L	H	L	L
7	H	H	L	H
8	H	L	L	L
9	L	L	H	L
10	H	L	H	L
11	H	L	H	H
12	L	L	H	H
13	L	L	L	H
14	H	L	L	H

Table 16: ANOVA results for comparisons of ossification pattern frequencies between all rib groups. **Bold text** indicates significant p -values

Factor	Degrees of freedom	Sum of squares	Mean square	F	p -value
Sex	1	868.2	868.17	42.31	<0.05
Age	1	96.7	96.66	4.71	<0.05
Rib Group	1	55.2	55.23	2.69	0.1
Sex * Age	1	5.1	5.11	0.25	0.62
Sex * Rib Group	1	1.4	1.39	0.07	0.8
Age * Rib Group	1	1.0	1.01	0.05	0.82
Sex * Age * Rib Group	1	2.3	2.32	0.11	0.74

Table 17: ANOVA results for comparisons of ossification pattern frequencies for rib group 1. **Bold text** indicates significant p -values

Factor	Degrees of freedom	Sum of squares	Mean square	F	p-value
Sex	1	272.3	272.29	19.99	<0.05
Age	1	42.3	42.32	3.11	0.08
Sex * Age	1	14.6	14.58	1.07	0.3

Table 18: ANOVA results for comparisons of ossification pattern frequencies for rib group 2. **Bold text** indicates significant p -values

Factor	Degrees of freedom	Sum of squares	Mean square	F	p-value
Sex	1	250.7	250.69	10.57	<0.05
Age	1	29.7	29.7	1.25	0.26
Sex * Age	1	35.7	35.68	1.5	0.22

Table 19: ANOVA results for comparisons of ossification pattern frequencies for rib group 3. **Bold text** indicates significant p -values

Factor	Degrees of freedom	Sum of squares	Mean square	F	p-value
Sex	1	341.1	341.06	14.85	<0.05
Age	1	26.6	26.61	1.16	0.28
Sex * Age	1	37.3	37.3	1.62	0.2

CHAPTER FIVE: DISCUSSION

When comparing sternal end shape of males to females we can see that almost all the variation in both can be explained by PC1 or shape. As PC1 is describing the overall roundness of the sternal ends this is not surprising. This can be tied to the first harmonic of the EFA which describes the shape of the ribs as a circle. The exception to this is rib group 2 which used two harmonics for the EFA and therefore displays a small amount variation attributed to PC2. In this case the second harmonic is describing the anterior to posterior distortion of the sternal end round shape. Unlike rib groups 1 and 3, in which the sternal ends are described as round, rib group 2, made up of ribs 4 and 5, have a narrowed aspect anterior to posterior which could explain the use of a second harmonic. This difference in shape can be seen when comparing Figure 6 (EFA output for a rib from rib group 1) to Figure 7 (EFA output for a rib from rib group 2). The difference in roundness or shape of rib group 2 compared to rib groups 1 and 3 could be tied to the biomechanics of the rib cage. As discussed earlier rib 1 moves very little and rib 2 has more movement but is still restricted by direct sternocostal articulation. Rib group 2 includes ribs 4 and 5 which have a range of movement, particularly superiorly and anteriorly. Both of these ribs are part of the "pump handle" movement seen during inhalation (Starr and Dalton 2011). The narrowing of the sternal end for these ribs could be a result of this movement and stabilizing the sternum. In contrast rib group 3 consists of ribs 8 and 9 which are part of the false ribs. These ribs indirectly articulate with the sternum through

costal cartilage and are part of the “bucket handle” movement during inhalation (Starr and Dalton 2011). This lateral rotation of the ribs could facilitate a round shape for the sternal end.

Interesting trends can be seen when looking at the results of the ANOVA test on PC1 and PC2. Except for rib group 3, sex and age were significant factors in the differences in sternal end shape. However, the interaction between sex and age was found to be significant for rib group 1 suggesting that age does not behave the same between each age and across sexes. The shape of rib group 2, ribs four and five, is strongly influenced by age and sex, the shape of rib group 3, made up of ribs eight and nine, is only influenced by sex.

The difference in sternal end depth was found to be significant both between age groups as well as between males and females. This is not surprising in the case of age because part of the aging process on the sternal end of the ribs consists of a breakdown of the sternal surface resulting in the formation of a pit which deepens over time. However, the results for sex are interesting and coincide with Íşcan et al.'s (1984, 1985) results, which found significant differences between males and females sternal rib end depth. As individuals age, particularly females, there is a change in estrogen levels which can result in lower bone density or bone quality (Khosla et al. 2012). A factor that is noted by Hartnett (2010) in her additions to Íşcan et al.'s (1984, 1985) original descriptions for age estimation of the sternal rib ends.

Ossification rates and patterning provide some interesting insight into the differences that have been noted by many authors in the morphology of ossification at the margins of sternal rib ends (İşcan and Loth 1986a, 1986b, Hartnett 2010b). The analysis of ossification rates supports the idea that age is a deciding factor in how much ossification is observed on the sternal end. This, in addition to the deepening of the sternal end depth, provide solid reasoning for the age estimation methods put forth by İşcan et al. (1984, 1985). As individuals live longer, it would be expected that more ossification would occur, with some variance. More interesting is what is seen in the analysis on patterning of ossification at the four landmarks (anterior, posterior, superior and inferior). Sex of the individuals seems to be a large deciding factor for differences in ossification pattern across all three rib types. The patterns with the highest frequency seen in males were patterns 0 (no difference in ossification across landmarks), 9 (inferior landmark has higher ossification than all other landmarks [LLHL]), and 12 (inferior and superior landmarks have higher ossification than anterior and posterior [LLHH]) which are illustrated in Figures 18-20. The exception to this was rib group 1 where patterns 10 (anterior and inferior landmarks were higher than posterior and superior [HLHL]) and 4 (all landmarks are high except for anterior [LHHH]) were present in higher frequencies (Figures 21 and 22). Across these patterns we see an increase in ossification at inferior and superior landmarks over anterior and posterior which is consistent with İşcan et al. (1984, 1985) description of 'crab claw' ossification of sternal ends in males.

In contrast, the patterns that were observed in high frequency in females were 0, 9, and 5 (superior landmark scored as lower and the rest of the landmarks as high [HHHL]) as seen in Figure 23. In rib group 1 a high frequency of pattern 3 (anterior and posterior were higher than inferior and superior [HHLL]) was also observed (Figure 24). It is unclear why rib group 1 seems to differ from the other rib groups in which patterns were observed more frequently, but it might be biomechanical related. Rib 1 close articulation with the manubrium and close proximity with the sternoclavicular joint means that mobility is limited (Starr and Dalton 2011). Because of this lower range of mobility, the costal cartilage of the first rib is more likely to ossify. It is unclear if this trend extends to the second rib. Females show evidence of ossification at the inferior landmark similar to what is seen in males. However, the extension of ossification at both inferior and superior landmarks (pattern 12) is seen at a much lower frequency in females than in males. This suggests that this pattern is more indicative of male but does not completely exclude females which is consistent with McCormick et al.'s (1985) type B. They argue that the claw shape can appear in females with extreme levels of costal cartilage ossification.

CHAPTER SIX: CONCLUSION AND RECOMMENDATIONS

Age and sex estimation are key parts of the biological profile, and one area that is studied when conducting these estimations is the sternal end of the ribs. One limitation of using the ribs can be their delicate nature. While this study was fortunate to be conducted with a donated skeletal collection where curators take care to prevent damage to bone, this is not necessarily what anthropologists would be faced with in the field. There have been many instances where age estimation using rib sternal end is omitted due to the poor preservation or complete absence of these elements. Even during this study individual rib groups had to be excluded for an individual because the ribs for that group, both left and right, were determined as unusable due to poor preservation. This study also used a limited sample with a narrow range for population affinity, all listed as white. Other studies have shown that there is variation of aging rates and morphologies between different ancestral and geographical populations (Çöloğlu et al. 1998, Koçak et al. 2003, Macaluso et al. 2012). One suggestion for a future study would be to extend this study to other reference groups. As mentioned above this study looked at only 6 of the 12 ribs. A future study might involve looking at the remaining ribs (ribs 3, 6,7,10,11,12) and exploring whether the shape trends noted in ribs 1, 2, 4, 5, 8, 9 extend these ribs as well. It would be interesting to see if trends fall more into a continuum between ribs or distinct groups.

This study examined the morphological differences in males and females as well as how age affects morphology. It was found that in terms of ossification rates and the increase in sternal end depth, age played a significant role in both of these processes, and sex was a significant factor for sternal depth. In regard to overall shape of the sternal end age and sex both played a role. Rib group 3 was affected by sex while rib group 2 was affected by age and sex. In contrast, sex was the only significant factor for ossification patterning on the sternal end of the ribs. Similar trends were observed in all rib types with the exception of ossification patterning. The first group differed slightly in both males and females. While it is unclear why this is the case it does raise a question to whether biomechanics could be playing a role in ossification patterning. However, one would then expect to see ossification pattern differences between all three rib groups because each group consists of ribs from different location in the rib cage and experience different biomechanical stresses. As seen throughout this study both age and sex play a role in the morphology of rib sternal end. Through the use of elliptical Fourier analysis size was removed as a factor allowing closer examination of other morphological features and the influence of age and sex on each.

LIST OF REFERENCES

- Bastir M, Martinez DG, Recheis W, Barash A, Coquerelle M, Rios L, Peña-Melián Á, Río FG, O'Higgins P. 2013. Differential growth and development of the upper and lower human thorax. *PLoS ONE*8(9):e75128
- Bellemare F, Fuamba T, Bourgeault A. Sexual dimorphism of human ribs. *Respiratory Physiology & Neurobiology* 150:233-239.
- Bookstein FL. 1982. Foundations of morphometrics. *Annu Rev Ecol Syst* 13:451-470.
- Brooks S, Suchey JM. 1990. Skeletal age determination based on the os pubis: a comparison of the Acsádi-Nemeskéri and Suchey-Brooks methods. *Journal of Human Evolution* 5(3):227-238.
- Buckberry JI, Chamberlain AT. 2002. Age estimation from the auricular surface of the ilium: a revised method. *American Journal of Physical Anthropology* 119:231-239.
- Caple J, Byrd J, Stephan CN. 2017. Elliptical Fourier analysis: fundamentals, applications, and value for forensic anthropology. *Int J Legal Med* 131:1675-1690.
- Christensen AM. 2004. Assessing the variation in individual frontal sinus outline. *American Journal of Physical Anthropology* 127(3):291-295.
- Christensen AM. 2005. Testing the reliability of frontal sinuses in positive identification. *Journal of Forensic Sciences* 50(1):18-22.

- Çöloğlu AS, İşcan MY, Yavuz MF, Sari H. 1998. Sex determination from the ribs of contemporary Turks. *Journal of Forensic Sciences* 43(2):273-276.
- Cosgriff RL. 1966. Identification of shape. Report No. 8220-11 of the Ohio State University Research Foundation.
- Dearden LC, Bonucci E, Cuicchio M. 1974. An investigation of ageing in human costal cartilage. *Cell Tiss. Res.* 152:305-337.
- Elkeles A. 1966. Sex differences in calcification of costal cartilages. *Journal of the American Geriatrics Society* 14(5):456-462.
- Fischer E. 1955. Verkalkungsformen der Rippenknorpel. *Fortschr Rontgenstr* 82:474-481.
- France DL. 1998. Observation and metric analysis of sex in the skeleton. In: Reichs KL, editor. *Forensic osteology: advances in the identification of human remains*. Springfield, IL: Charles C. Thomas. 163-186.
- Garvin HM, Passalacqua NV, Uhl NM, Gipson DR, Overbury RS, Cabo LL. 2012. Developments in forensic anthropology: age at death estimation. In: Dirkmaat DC, editor. *A companion to forensic anthropology*. Oxford: Blackwell Publishing Ltd. 202-223.
- Gilbert BM, McKern TW. 1973. A method of aging the female os pubis. *American Journal of Physical Anthropology* 38:31-38.
- Giles E, Elliot O. 1963. Sex determination by discriminant function analysis of crania. *American Journal of Physical Anthropology* 21:53-68.

- Hartnett KM. 2010a. Analysis of age-at -death estimation using data from a new, modern autopsy sample part I: pubic bone. *Journal of Forensic Sciences* 55(5):1145-1151.
- Hartnett KM. 2010b. Analysis of age-at -death estimation using data from a new, modern autopsy sample part II: sternal end of the fourth rib. *Journal of Forensic Sciences* 55(5):1152-1156.
- Huang R, Zhi Q, Schmidt C, Wilting J, Brand-Saberi B, Christ B. 2000. Sclerotomal origin of the ribs. *Development*.127(3):527-32.
- Íşcan MY. 1985. Osteometric analysis of sexual dimorphism in the sternal end of the rib. *Journal of Forensic Sciences* 30(4):1090-1099.
- Íşcan MY, Loth SR, Wright RK. 1984. Age estimation from the rib by phase analysis: white males. *Journal of Forensic Sciences* 29(4):1094-1104.
- Íşcan MY, Loth SR, Wright RK. 1985. Age estimation from the rib by phase analysis: white females. *Journal of Forensic Sciences* 30(3):853-863.
- Íşcan MY, Loth SR, Wright RK. 1987. Racial variation in the sternal extremity of the rib and its effect on age determination. *Journal of Forensic Sciences* 32(2):452-466.
- Íşcan MY, Loth SR. 1986a. Determination of age from sternal rib in white males: a test of the phase method. *Journal of Forensic Sciences* 31(1):122-132.
- Íşcan MY, Loth SR. 1986b. Determination of age from sternal rib in white females: a test of the phase method. *Journal of Forensic Sciences* 31(3):990-999.

- Jantz RL, Ousley SD. 2005. Fordisc version 3.0. Knoxville, TN: University of Tennessee.
- Johnson JL, Repta R. 2011. Sex and Gender: beyond the binaries. In Oliffe JL, Greaves L, editors. *Designing and Conducting Gender, Sex, and Health Research*. Los Angeles, CA: SAGE Publications, Inc. 17-37.
- Khosla S, Oursler MJ, Monroe DG. 2012. Estrogen and the skeleton. *Trends in Endocrinology and Metabolism* 23(11):576-581.
- Klaes AR, Ousley SD, Vollner J. 2012. A revised method of sexing the human innominate using Phenice's nonmetric traits and statistical methods. *American Journal of Physical Anthropology* 149:104-114.
- Koçak A, Aktas EÖ, Ertürk S, Aktas S, Yemisçigil A. 2003. Sex determination from the sternal end of the rib by osteometric analysis. *Legal Medicine* 5:100-104.
- Kuhl F, Giardina C. 1982. Elliptic Fourier features of a closed contour. *Comput Graphics Image Process* 18:236-258.
- Lestrel P, Kanaza E, Wolfe C. 2011. Sexual dimorphism using elliptical Fourier analysis: shape differences in the craniofacial complex. *Anthropol Sci* 119(3):313-229.
- Loth SR, İşcan MY. 1988. Skeletal aging techniques: the good, the bad, and the equivocal. *American Journal of Physical Anthropology* 75:241.

- Loth SR, Íşcan MY, Scheuerman EH. 1990. A systematic comparison of the accuracy of age estimation from the rib and pubis. *American Journal of Physical Anthropology* 81:260.
- Lovejoy CO, Meindl RS, Pryzbeck TR, Mensforth RP. 1985. Chronological metamorphosis of the auricular surface of the ilium: a new method for the determination of adult skeletal age at death. *American Journal of Physical Anthropology* 68:15-28.
- Macaluso Jr PJ, Rico A, Santos M, Lucena J. 2012. Osteometric sex discrimination from the sternal extremity of the fourth rib in a recent forensic sample from Southwestern Spain. *Forensic Science International* 223:375.e1-375.e5.
- Mann RW. 1993. A method for siding and sequencing human ribs. *Journal of Forensic Sciences* 38:151-155.
- Meindl RS, Lovejoy CO. 1985. Ectocranial suture closure: a revised method for the determination of skeletal age at death based on the lateral anterior sutures. *American Journal of Physical anthropology* 68:57-66.
- McCormick WF. 1980. Mineralization of the costal cartilages as an indicator of age: preliminary observations. *Journal of Forensic Sciences* 25(4):736-741.
- McCormick W, Stewart JH, Langford LA. 1985. Sex determination from chest plate roentgenograms. *American Journal of Physical Anthropology* 68:173-195.

- McKern TW, Stewart TD. 1957. Skeletal age changes in young American males. Natick, MA: Quartermaster Research and Development Command, Technical Report EP.45.
- Middleham HP, Boyd LE, McDonald SW. 2015. Sex determination from calcification of costal cartilages in a Scottish sample. *Clinical Anatomy* 28:888-895.
- Monum T, Makino Y, Prasitwattanaseree S, Yajima D, Chiba F, Torimitsu S, Hoshioka Y, Yoshida M, Urabe S, Oya Y, Iwase H. 2020. Age estimation from ossification of sternum and true ribs using 3D post-mortem CT images in a Japanese population. *Legal Medicine*.
- Muñoz A, Maestro N, Benito A, Sánchez JA, Márquez-Grant N, Trejo D, Ríos L. 2018. Sex and age death estimation from the sternal end of the fourth rib. Does İşcan's method really work? *Legal Medicine* 31:24-29.
- Navani S, Shah JR, Levy PS. 1970. Determination of sex by costal cartilage calcification. *American Journal of Roentgenology, Radium Therapy, and Nuclear Medicine* 108:771-774.
- Niespodziewanski E, Stephan CN, Guyomarc'h P, Fenton TW. 2016. Human identification via lateral patella radiographs: a validation study. *Journal of Forensic Sciences* 61(1):134-140.
- Okuno K, Ishizu K, Matsubayashi J, Fujii S, Sakamoto R, Ishikawa A, Yamada S, Yoneyama A, Takakuwa T. 2019. Rib cage: morphogenesis in the human

- embryo: a detailed three-dimensional analysis. *The Anatomical Record* 302: 2211-2223.
- Phenice TW. 1969. A newly developed visual method for sexing the os pubis. *American Journal of Physical Anthropology* 30:297-302.
- R. 2021. Version 4.1.2. The R Foundation for Statistical Computing Platform.
- Rejtarová O, Slížová D, Šmoranc P, Rejtar P, Bukač J. 2004. Costal cartilages – a clue for determination of sex. *Biomedical papers of the Medical Faculty of the University Palacky, Olomouc Czech Republic* 148(2):241-243.
- Rhomberg W, Schuster A. 2014. Premature calcifications of costal cartilages: a new perspective. *Radiology Research and Practice*. 1-5.
- Richtsmeier JT, DeLeon VB, Lele SR. 2002. The promise of geometric morphometrics. *Yearbook of Physical Anthropology* 45:63-91.
- Sanders CF. Sexing by costal cartilage calcification. *British Journal of Radiology*. 39(459):233.
- Scheuer L, Black S. 2000. *Developmental juvenile osteology*. San Diego, CA: Academic Press.
- Semine AA, Damon A. 1975. Costochondral ossification and aging in five populations. *Human Biology* 47:101-116.
- Spradley M, Jantz R. 2011. Sex estimation in forensic anthropology: skull versus postcranial elements. *Journal of Forensic Sciences* 56(2), 289-296.

- Starr J, Dalton D. 2011. Chapter 5: the thorax and chest wall. In PK Levagie and CC Norkin ed. Joint structure and function: a comprehensive analysis 5th edition. F.A. Davis Company. 192-211.
- Tanaka H, Lestrel P, Uetake T, Susumu K, Ohtsuki F. 2000. Sex differences in proximal humeral outline shape: elliptical Fourier functions. *Journal of Forensic Sciences* 45(2):292-302.
- Todd TW. 1920. Age changes in the pubic bone I the male white pubis, *American Journal of Physical Anthropology* 3:285-334.
- Todd TW. 1921. Age changes in the pubic bone II: the pubis of the male Negro-white hybrid, III: the pubis of the white female IV: the pubis of the Negro-white hybrid. *American Journal of Physical Anthropology* 4:1-170.
- Todd TW, Lyon DW. 1924. Endocranial suture closure, its progress and age relationship: part I. Adult males of the white stock. *American Journal of Physical Anthropology* 7:325-384.
- Walker P. 2008. Sexing skulls using discriminant function analysis of visually assessed traits. *American Journal of Physical Anthropology* 136:39-50.
- White TD, Black MT, Folkens PA. 2012. *Human osteology*. 3rd edition. San Diego, CA: Academic Press.
- Wiredu EK, Kumoji R, Seshadri R, Biritwum RB. 1999. Osteometric analysis of sexual dimorphism in the sternal end of the rib in a West African population. *Journal of Forensic Sciences* 44(5):921-925.

Yoder C, Ubelaker DH, Powell JF. 2001. Examination of variation in sternal rib end morphology relevant to age assessment. *Journal of Forensic Sciences* 46(2):223-227.

APPENDIX

Appendix A

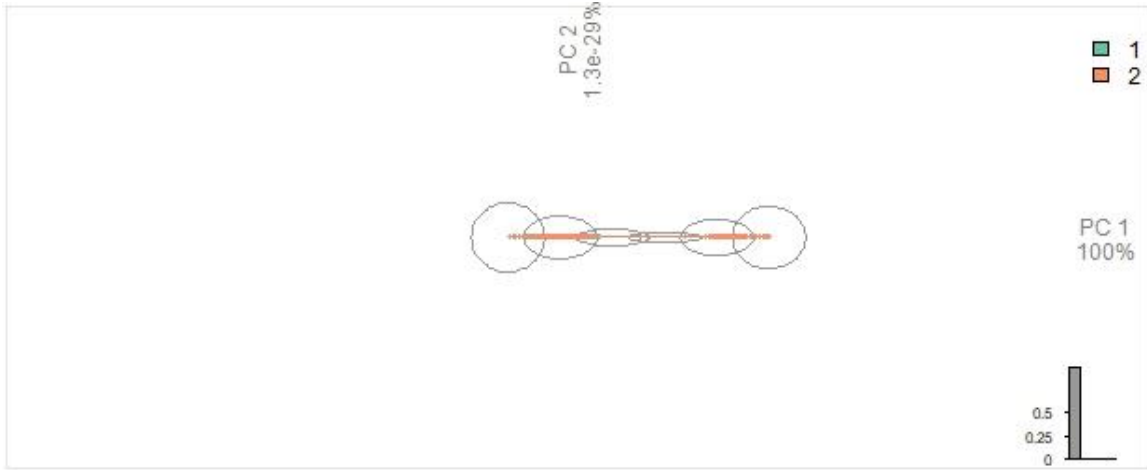


Figure 9: PCA Plot for all rib groups based on Sex. 1=Female 2=Male

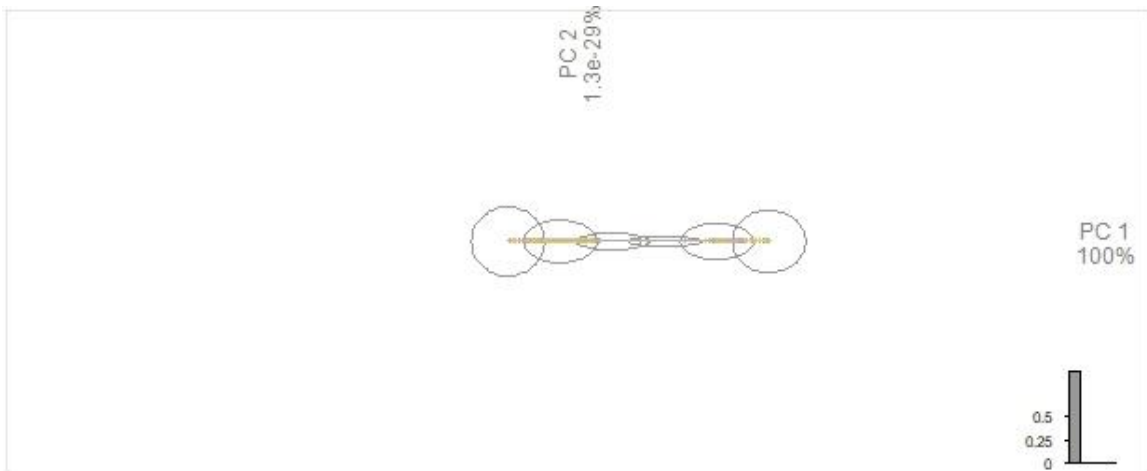


Figure 10: PCA Plot for All rib groups based on Age

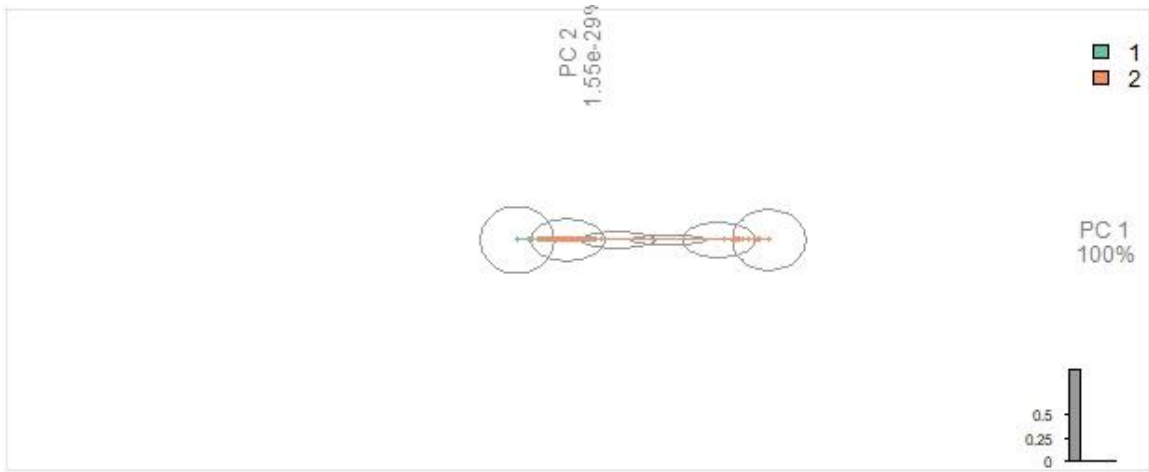


Figure 11: PCA Plot for Rib Group 1 based on Sex. 1=Female 2=Male

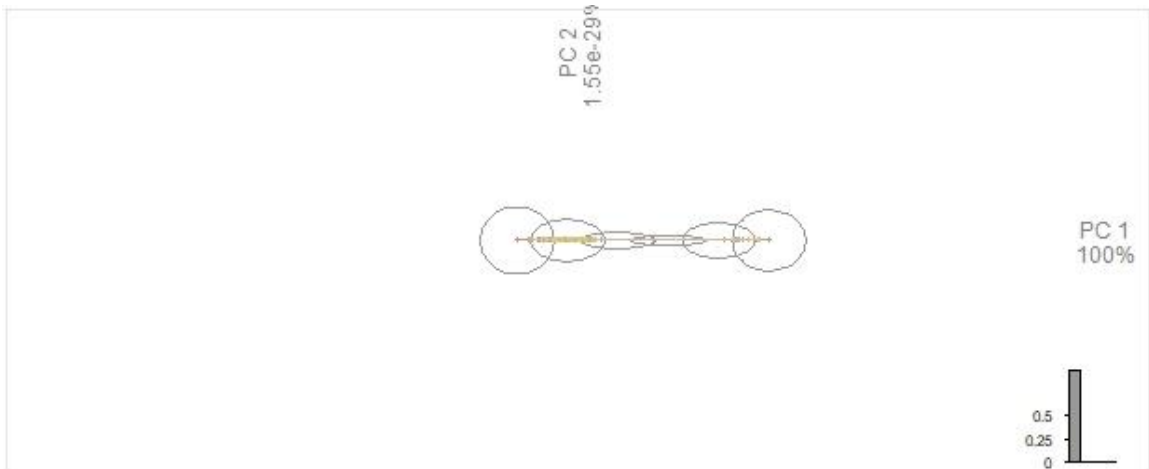


Figure 12: PCA Plot for Rib Group 1 based on Age

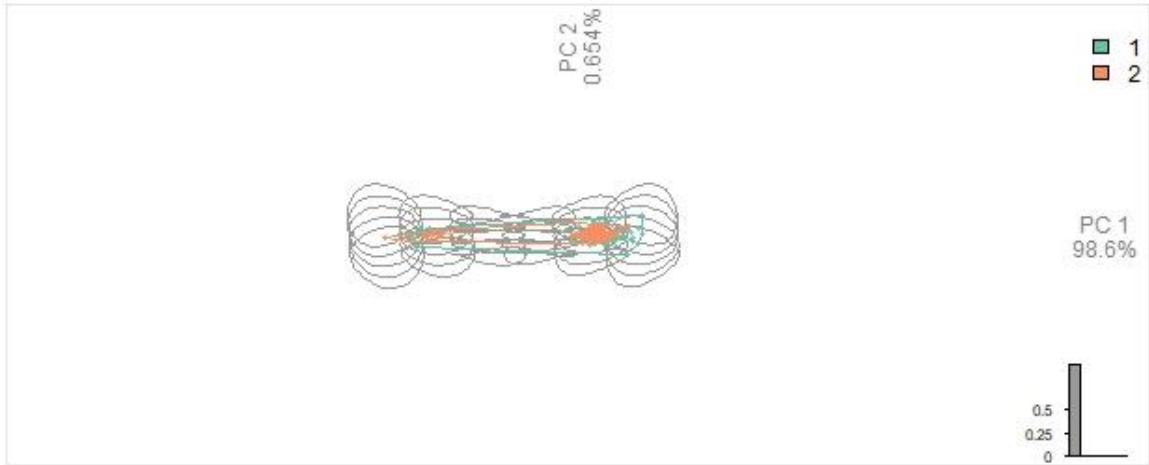


Figure 13: PCA Plot for Rib Group 2 based on Sex 1=Female 2=Male

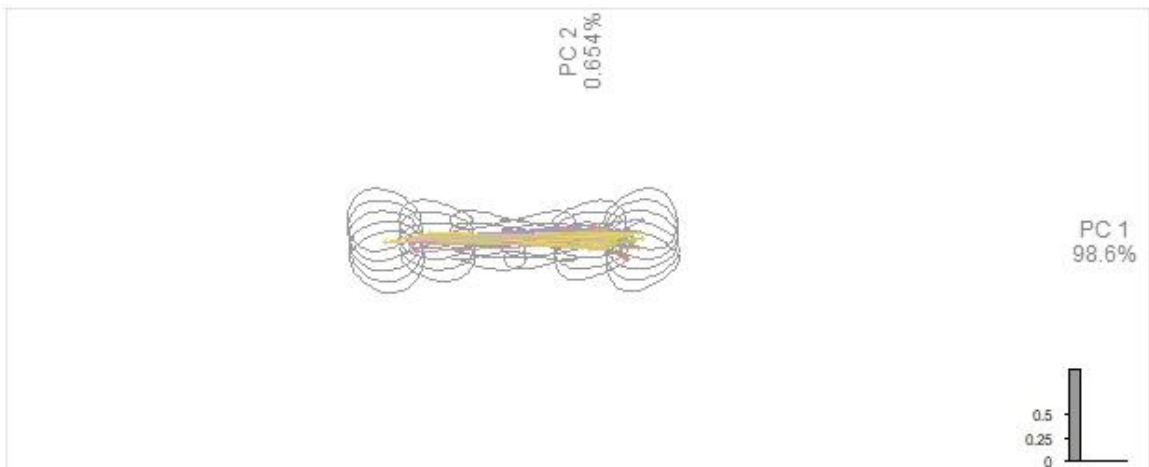


Figure 14: PCA Plot for Rib Group 2 based on Age

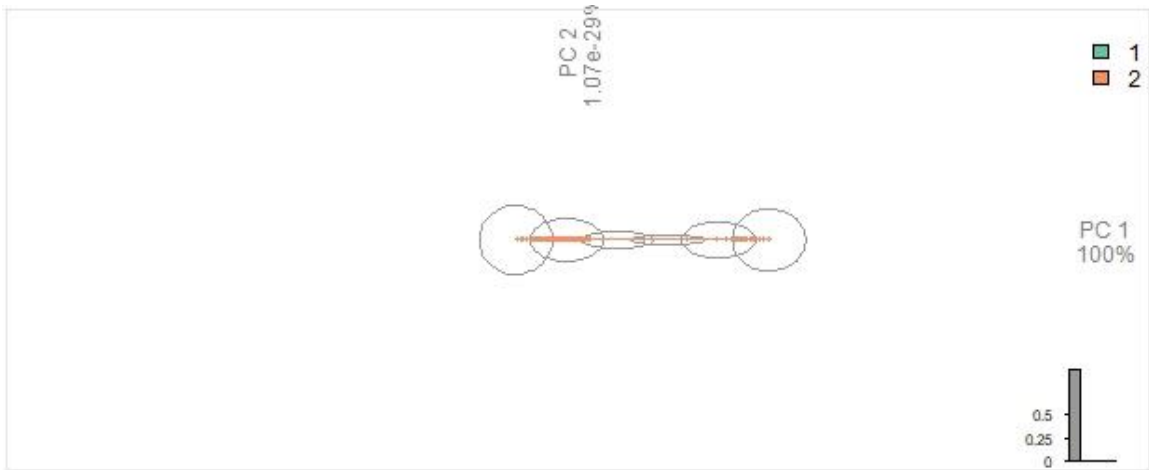


Figure 15: PCA Plot for Rib Group 3 based on Sex. 1=Female 2=Male

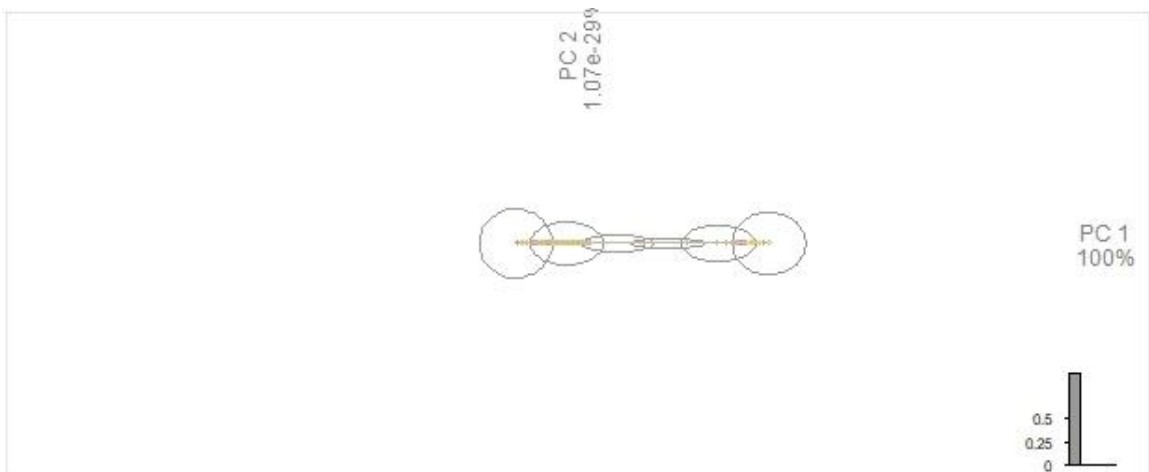


Figure 16: PCA Plot for Rib Group 3 based on Age



Figure 17: Example of extreme ossification preventing sternal depth measurement



Figure 18: Example of dried costal cartilage preventing sternal depth measurement



Figure 19: Example of Pattern 0. Anterior view with inferior point on the left.



Figure 20: Example of Pattern 9 (LLHL). Anterior view with inferior point on the left.

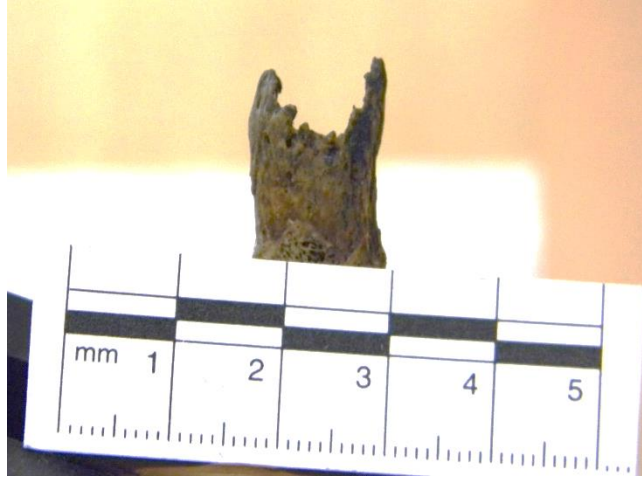

Figure 21: Example of Pattern 12 (LLHH). Anterior view with inferior point on the left



Figure 22: Example of Pattern 10 (HLHL). Anterior view with inferior point on the left



Figure 23: Example of Pattern 4 (LHHH). Anterior view with inferior point on the left



Figure 24: Example of Pattern 5 (HHHL). Anterior view with inferior point on the left



Figure 25: Example of Pattern 3 (HHLL). Anterior view with inferior point on the left

VITA

Marta Paulson was born in Pulaski Virginia. She attended Radford University where she earned her Bachelor of Science Degree in Anthropology with a concentration in Forensic Anthropology and her Bachelor of Arts Degree in Foreign Languages with a concentration in German. She attended the University of Tennessee where she pursued a Master of Arts degree in Biological Anthropology and wrote her thesis on sex comparison of the sternal end of the ribs and the effect of aging using Elliptical Fourier analysis.