University of Tennessee, Knoxville

TRACE: Tennessee Research and Creative Exchange

Senior Thesis Projects, 2003-2006

College Scholars

2004

Postmortem Tooth Loss: Patterns and Indications

Shaun Thompson

Follow this and additional works at: https://trace.tennessee.edu/utk_interstp3

Recommended Citation

Thompson, Shaun, "Postmortem Tooth Loss: Patterns and Indications" (2004). *Senior Thesis Projects, 2003-2006.*
https://trace.tennessee.edu/utk_interstp3/42

This Project is brought to you for free and open access by the College Scholars at TRACE: Tennessee Research and Creative Exchange. It has been accepted for inclusion in Senior Thesis Projects, 2003-2006 by an authorized administrator of TRACE: Tennessee Research and Creative Exchange. For more information, please contact trace@utk.edu.

FORM C
COLLEGE SCHOLARS PROJECT APPROVAL

Shaun Thompson — Scholar

Murray Marks — Mentor

Postmortem Tooth loss: Patterns + Indications — Project Title

COMMITTEE MEMBERS
(Minimum 3 Required)

Name	Signature
Murray K. Marks	Murray K. Marks
Lee Meadows Jantz	Lee Meadows Jantz
JOHN R. KENNEDY	John R. Kennedy

PLEASE ATTACH A COPY OF THE SENIOR PROJECT TO THIS SHEET AND RETURN BOTH TO THE PROGRAM DIRECTOR. THIS PAGE SHOULD BE DATED AND COMPLETED ON THE DATE THAT YOUR DEFENSE IS HELD.

DATE COMPLETED 11/17/04

Postmortem Tooth Loss: Patterns and Indications in Forensic Science

Shaun Anderson Thompson
Undergraduate Honors Thesis
Submitted 11/16/04

Postmortem Tooth Exfoliation: Patterns and Indications in Forensic Science

***Introduction*:**

The discovery of a decomposing human corpse in an outdoor environment presents investigators with an abundance of medicolegal questions. Accurate estimation of time-since-death is of primary importance and in many cases crucial to securing a positive identity of the decedent. Estimation is often imprecise and is a goal complicated by uncontrollable, interrelated variables affecting soft tissue decomposition. Crime scene investigators must rely on previous experience and a small but growing arsenal of qualitative findings on human decomposition to formulate accurate assessments. Efforts to more accurately determine time elapsed since death require specific relationships between observations of soft tissue decomposition and bone appearance used to mark the passage of time.

Increasing frequencies of dismemberment cases have required investigators to develop unconventional methods of time-since-death assessment (Haglund & Reay, 1993). When human remains are scattered, be it criminal activity, animal scavenging (Swindler, 1988) or natural environmental factors (Hill, 1979), time-since-death assessments are urgently needed and can often be complicated by isolated and/or disfigured, partially decomposed remains. Due to the unique nature of the cranium and

its relationship with dental structures, recovery in scattered remains cases is likely and transportation for further analysis is possible (Boaz and Behrensmeyer, 1976). Research of tooth disarticulation rates could be refined to perhaps reveal specific temporal markers in postmortem interval estimation. With the intent of exploring and documenting the process of postmortem tooth loss (PMTL), significant trends in tooth exfoliation were correlated with well documented soft tissue decay rates to extract reliable forensic indications in time-since-death analysis.

Processes of postmortem change lend themselves to the partitioning of a timeline of events. These processes, however, often lack distinct interval boundaries, may potentially overlap, and are context specific. Thus, postmortem interval estimation for human remains necessitates correlation of time dependent decomposition processes with specific temporal markers chosen to measure the passage of time. Intrinsic to marking the events of a particular process is the ability to measure the rate at which the process proceeds and any variables regulating that rate. These variables may include, but are not limited to, ambient temperature, carrion insect activity, micro-environment, size and body weight, inflicted trauma and open wounds, clothing, burial and contact surface. Through qualitative, longitudinal analysis, several of these variables have been documented and defined well enough to make significant forensic contributions (Bass and Jefferson, 2004).

Many of these variables are inextricably interrelated, and are isolated or controlled only at the expense of compromising the validity of forensic research. Accordingly, research of this nature is most effectively executed in an uncontrolled, natural environment on deceased individuals of known sex, age, race, weight and cause

of death. The Anthropological Research Facility in Knoxville, Tennessee has provided such an arena for University faculty and students since 1981.

Seasonal and immediate environmental factors were recognized as primary variables as they appear to have the greatest influence on the microenvironment of the oral cavity and subsequent soft tissue decomposition. Other variables such as body mass, clothing, embalming and contact surface were recorded and considered. The following discussion of the periodontium is derived from the writing of Berkovitz et al., (2000), Avery (2000) and Ten Cate (2000), and will resume with greater histological detail in the discussion.

The functional network of tissues responsible for tooth support mechanisms is collectively known as the periodontium (Figure 1). Intrinsically essential to support mechanisms of the periodontium is the periodontal ligament (Figure 2). This specialized ligament occupies the periodontal space between the root of the tooth and the alveolus as a dense fibrous connective tissue. Derived from the dental follicle, it lies above the alveolar crest contiguous with the connective tissue of the gingiva. At the apical foreman, it is continuous with the dental pulp. The average width of the periodontal space varies between abutting teeth. This space also may vary according to the functional state of the periodontal ligament and tends to narrow slightly with age. Thus, the periodontal space of permanent teeth is narrower than that of deciduous teeth, continuing to narrow with age. Generally, this space is observed as hourglass in shape, narrow at the fulcrum about which the tooth pivots under orthodontic and masticatory loads.

Figure 1-*Periodontium*

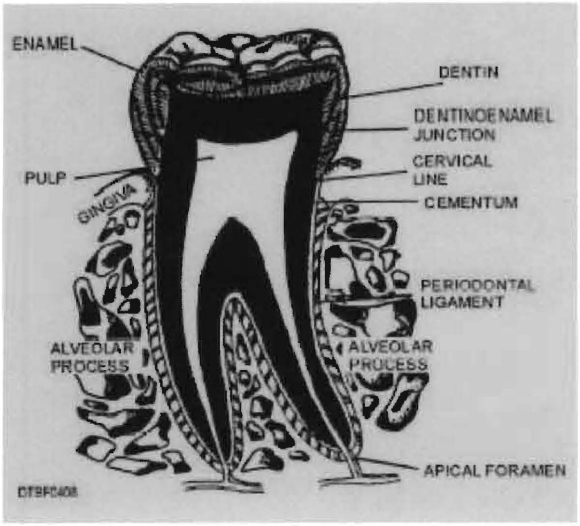

Figure 2-*Periodontal Ligament*

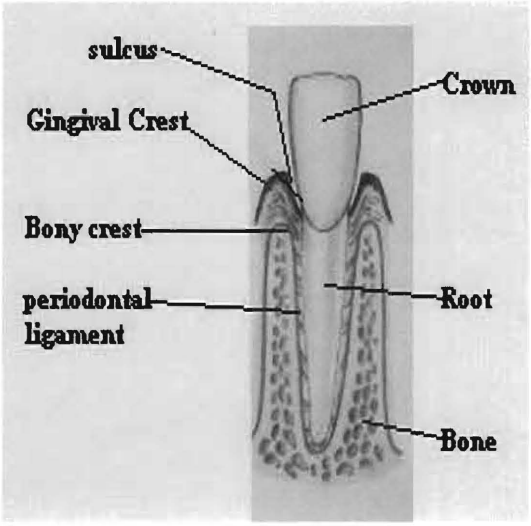

Normative decay processes correspond to and indicate temporal markers in the process of recession, decomposition and loss of the periodontal ligament attachment. This is of primary relevance in decomposition research, as the periodontal ligament is responsible for the mechanisms whereby a tooth attains and maintains its support and functional position. In the jaw, teeth are not in direct contact with the alveolar bone, but are suspended in socket by the collagenous and elastic fibers that comprise the periodontal ligament. Although it is not clear why the periodontal ligament does not calcify, it is known to remain a soft connective tissue despite an external bony envelope and cemental internal border. Therefore, as a soft tissue, the periodontal ligament is subject to normal decay rates and variables in the decomposition process. Previously gathered decomposition rate data contributes to correlation patterns between postmortem tooth exfoliation and other well documented decay processes. Following is relevant data from previous case studies conducted at the facility in Knoxville, Tennessee.

Mann and coworkers (1990) explored variables and observations in case and experimental field studies to assess seasonal factors and found ambient temperature to have the greatest influence on bodily decay and putrefaction rates. Colder or freezing temperatures were found to reduce or completely arrest the decomposition process. Under warmer conditions, bodies were found to partially or even completely skeletonize in two to four weeks. According to Rodriguez and Bass (1983), this increased rate of decomposition during spring and summer months is indicative of increased carrion insect activity on cadavers during these seasons. Many researchers have found insects to be the most significant influence on decomposing animal carrion. (Haglund and Sorg, 1997). Thus, it seems apparent that seasonal factors directly correlate with entomological considerations of the decay process.

Humidity/aridity has also been correlated with fly and maggot activity. In arid environments remains are mummified and show little insect activity. In numerous cases bodies mummified under natural conditions retained skin for periods ranging from two to four years. Fly activity, and ensuing egg-laying, may be reduced or completely arrested in moderate to heavy rainfall. However, rainfall seems to have little or no effect on maggot activity as they continue to feed within the body cavity where they are protected from the elements (Byrd and Castner, 2002).

Body mass is a negligible variable as obese bodies have been found to quickly lose mass due to liquefaction of fatty tissue. Clothing protects the body from sunlight, which maggots will avoid, and subsequently increases the decay process. Additionally, clothing may act as a barrier between body cavities such as the anus and vagina which may induce increased oral cavity activity in the preliminary stages of decomposition. As

expected, embalming retards or completely arrests the decay process and consequently, whether it be directly or indirectly, countless other dependent variables of the decay process. Unembalmed bodies tend to show primitive signs of decay in the facial. In contrast, embalmed bodies usually show first signs of decay in the buttocks and legs (Mann et al., 1990).

Seasonal factors that influence the microenvironment of the oral cavity were related to postmortem tooth exfoliation in a study by McKeown and Bennett (1995). Their findings did not allow accurate estimation of the postmortem interval based solely on patterns in tooth loss. They did concede, however, that these patterns, when used in conjunction with the overall assessment of time-since-death, could supplement estimates.

With the agenda of expanding on the results of McKeown and Bennett, research was conducted using similar procedures. Specific relationships between PMTL and periodontium tissue decay were revealed by aligning collected data with relevant histological and morphological components of the periodontium. Results were analyzed to justify or negate the validity of forensic indications in PMTL patterns.

Research of this nature is imperative to furthering the field of forensic science and essential to improving the accuracy of time-since-death estimates. Human decomposition study has proven to be an incredibly varied process that must overcome substantial obstacles and assess unpredictable variables. Through continued pursuit and acquisition of comparative experimental data, this meticulous science can be methodically forged into an atlas of time-since-death analysis and monumental advancements in the evolving field of forensic science.

Methods and Materials:

Research was conducted at the University of Tennessee's Forensic Anthropology Center Research Facility. This three acre plot of land, surrounded by chain-link fence, is armed with razor wire and inset with a wooden privacy fence. The facility, immortalized as "The Body Farm" by a popular mystery novelist author, began as a single concrete slab in the fall of 1981. It has since grown into a semi-wooded area providing a unique arena for human decomposition studies and an ideal environment for bodies to decompose in a natural setting. Donated bodies are exposed to natural environmental factors to provide unparalleled hands-on research and longitudinal observation of decay processes.

The maxillary and mandibular anterior dentition (canines and incisors) of human cadavers were observed recording data weekly. Canine and incisor root morphology most effectively accommodates accurate correlations between PMTL and time-since-death. Anterior dentitions were observed as the posterior dentitions have divergent multirooted anchoring mechanisms in the alveolar bone and seldom become detached.

A sample consisting of six male and two female (Caucasian and Hispanic) cadavers ranging in age from thirty-four to ninety-one years in age was observed. Data was limited to bodies not embalmed, as this process retards and, in some cases, completely arrests processes of decomposition. Each subject was placed in a supine position with age, race, sex, immediate environment, seasonality of placement and facial positioning recorded (Table 1). Location within the facility, relative to natural flora (trees, undergrowth, etc...) was recorded and considered as well. Subsequent tooth loss was recorded and calculated for comparative purposes. Data was gathered by movements

of the forefinger over each tooth from the neck to occlusal edge to detect separation from the alveolar bone and subsequent loosening.

Table 1—*Demographics and placement variables of cadavers in sample.*

Subject	Age	Race	Sex	Environment	Season of Placement	Facial Position
A	91	White	Female	Open	Spring	Up
B	57	White	Male	Shaded	Spring	Up
C	69	White	Female	Open	Spring	Up
D	34	Caucasian	Male	Shaded	Summer	Up
E	59	Caucasian	Male	Shaded	Summer	UP
F	30s	Hispanic	Male	Body Bag	Summer	Down
G	54	Caucasian	Male	Body Bag	Summer	Down
H	39	Caucasian	Male	Open	Fall	Up

Seasonality (primarily ambient temperature) was documented in Table 2 as a fundamental variable affecting the micro-environment and soft tissue decomposition of the oral cavity. This variable was determined to be dependent upon the immediate environment in which each subject was placed. Immediate environment of each body was categorized in the following manner: open, shaded, or "body bag". This data is depicted in Table 3.

Table 2—*Seasonality and Distribution*

Season	Months Included	Distribution of Subjects Deposited
Winter	Dec., Jan & Feb	0
Spring	Mar., Apr. & May	3 (A, B & C)
Summer	June, July & August	4 (D, E, F & G)
Autumn	Sept., Oct. Nov.	1 (H)

Table 3- *Deposit dates, age and immediate environment of sample subject.*

Subject	Deposit Date	Age	Immediate Environment
A	3/22/04	91	Open
B	4/15/04	57	Shaded
C	4/28/04	69	Open
D	6/14/04	34	Shaded
E	6/24/04	59	Shaded
F	7/27/04	30s	Body Bag
G	8/2/04	54	Body Bag
H	10/1/04	39	Open

Histological and morphological characteristics of soft tissue support structures in the oral cavity were then aligned with collected data. Exploring these components of the periodontium and factors affecting the functional role of supporting structures, established a correlation with well documented decomposition processes.

Entomological activity was also considered and correlated with the aforementioned seasonal factors. Data gathered from previous case studies conducted at the facility in Knoxville was analyzed for available trends and relevant considerations of carrion insect activity in the decomposition process of the oral cavity.

Results:

Subjects showed varying rates of tooth loss and/or significant loosening. Patterns of tooth loss were correlated with respect to season of deposition and micro-environment of the oral cavity. The following discussion of data collected corresponds to the average number of weeks from deposition to first tooth loss in each arch. Calculations for maxillary and mandibular drop time are depicted in Table 4. Significant loosening of

dentition with no tooth loss is marked the symbol (+) with moderate loosening marked by (-). In several instances, subjects retained dentition (as was expected) well beyond the conclusion time parameters for this experiment with little or no loosening, this is depicted by a (*) symbol. Table 4 correlates the number of weeks to disarticulation with seasonality.

Table 4-*Average number of weeks for maxillary and mandibular tooth loss.*
***Note: Maxillary data is listed above mandibular*

	A	B	C	D	E	F	G	H
Spring	*(-) 29(-)	24(+) *(+)	22(-) 24(+)					
Summer				*(+) *(+)	N/A 17(+)	9(+) 10(+)	11(+) 11(+)	
Autumn								*(-) *(+)
Winter								

Legend– ** denotes subjects retaining dentition*
(-) indicates moderate loosening of dentition
(+) indicates significant loosening of dentition
(N/A) indicates edentate arch

Months included in referenced seasons and distribution within are clarified in Table 2. Ages, exact dates of deposition and immediate environment are depicted in Table 3. Comparison showed trends that correspond to general patterns in soft tissue decay. Subjects D, E, F and G were all deposited in summer months. Subjects F and G remained covered by body bags. These subjects lost teeth at rates higher than both D and E. The body bag of Subject F was heavier and darker in color. Predictably, Subject F was skeletonized expeditiously losing maxillary dentition at nine weeks and mandibular at ten (Figure 4). Subject G, lost dentition at eleven weeks. (Figures 5 and 6). Although both

Subjects D and E showed significant loosening, only Subject E lost dentition (Figures 7 and 8 respectively). Subject E was deposited with an edentate maxillary arch, thus only the mandibular dentition was available for reference.

The sample consisted of only one subject deposited in the fall. At the conclusion of research, after six weeks of exposure to direct sunlight and unseasonably warm temperatures, subject H showed significant loosening of dentition but all teeth present upon deposition remained in socket (Figure 9).

Subjects A, B and C were all deposited in the months of spring. Subjects A and C were exposed to direct sunlight while B was relatively shaded. All three individuals lost teeth at varying rates. Upon commencement of research, subject A lost the mandibular right central incisor (Figure 10). Subject B lost the maxillary right central incisor and showed significant loosening throughout the maxilla and mandible although there were no further losses. Upon deposition, Subject B was missing the maxillary left central as well as maxillary right lateral incisors (Figure 11). Subject C lost maxillary left lateral and the mandibular left lateral incisors (Figure 12). The remaining maxillary dentition was held somewhat firmly in socket while the mandibular dentition uniformly loosened.

Summer depositions lost teeth at a higher rate than those deposited in spring which lost teeth more rapidly than those in autumn months. The sample did not consist of any winter deposits. All available subjects deposited in the winter months were missing anterior dentitions and/or edentate.

Discussion:

Decomposition of the soft tissue surrounding the teeth leaves space around the associated root allowing the tooth to loosen and ultimately be displaced from alveolar socket. Duric and coworkers (2004) gathered data indicating that PMTL most frequently affects the central maxillary incisors, followed by the other three groups of incisors. This is due to differences in root morphology. Incisor roots are usually conical, rounded and less frequently tilted distally. This morphology is capable of limited mechanisms for tooth retention and thus, offers the most reliable explanation for this trend. For this reason, only the maxillary and mandibular anterior dentitions were observed for patterns in PMTL.

Processes resulting in PMTL fluctuate in range from several weeks to many years, often dependent upon seasonal and environmental factors. Ambient temperature usually has the most profound influence on soft tissue decay rates. Colder or freezing temperatures slow or arrest the decomposition process which can further be subdivided into autolytic and putrefactive processes. These processes are temperature dependent and capable of completely skeletonizing a body (Haglund and Sorg, 1997). Increased rate of decomposition with warmer temperatures has most directly been linked to increased carrion insect activity on cadavers during these seasons (Rodriguez and Bass, 1983). Thus, data trends in decomposition and subsequent PMTL were correlated with seasonality of cadaver deposition.

The immediate environment of cadavers was classified broadly as open, shaded or "body bag". Various aspects of this research made it quite apparent that the micro-environment of the oral cavity was significantly influenced by the immediate

environment of the body. This was particularly evident in the micro-environments of body bags. Open environments were exposed to direct sunlight while natural flora of the facility created the shaded environments.

The preceding discussion offers explanation of classification rationale for preliminary data analysis. Following preliminary data analysis, soft tissue supporting structures of the periodontium are specifically correlated with PMTL considerations.

Patterns of tooth loss observed were largely consistent with general soft tissue decomposition trends. These trends most clearly correlated with seasonality of deposition. Subjects D, E, F and G were all deposited in summer months. PMTL patterns for subjects E, G and F exhibited the highest rates of tooth loss, increasing respectively. Rodriguez and Bass (1983) attribute this trend to high ambient temperatures and subsequent increased carrion insect activity in summer months. Micro-environment is of particular importance in Subjects F and G, which were underneath body bags. Each showed significantly accelerated rates of tooth loss. The body bag of Subject F was well sealed and darker than that of Subject G which remained partially unzipped and patched with holes that, inevitably, allowed exchanges across micro-environments. This may account for the slightly higher rate of tooth loss in Subject F. The environment within a body bag retains warmth and is conducive to insect/larvae activity. Such an environment accommodates high numbers of voraciously feeding maggots, expeditious soft tissue decomposition (Haskell et al., 1997) and subsequently, an increased rate of PMTL (Figures 4A, 4B, and 13).

Subject E was placed in a shaded environment with an edentate maxillary arch, but full mandibular dentition. The maxillary arch, therefore, did not contribute to PMTL

considerations. However, the mandibular dentition lost teeth at a lower rate than Subjects F and G as expected. The cranium of Subject D appears to have suffered antemortem head trauma. A right portion of the cranial vault (circular, 2 to 3 inches in diameter) had been reassembled with metal connecting pieces (Figure 15). The cranial soft tissue was possibly removed before being deposited within the facility. Presently, Subject D shows significant loosening in both maxillary and mandibular arches, but no tooth disarticulation. The method of soft tissue removal may have influenced decomposition of the supporting soft tissue structures and consequently, PMTL rates.

Subjects deposited during the months of spring (A, B and C) were all partially mummified (Figures 10A-B, 11A-B and 12A-B respectively) and showed lower tooth disarticulation rates than Subjects E, F and G. The reduced rate is likely resultant of cooler temperatures in spring tending to cause soft tissue desiccation that may hinder decomposition of soft oral supporting tissues. The effects of immediate environments on PMTL in Subjects A, B and C were inconsistent, or perhaps, lacking altogether. Subjects A and C were exposed to direct sunlight (open) while Subject B was shaded; however, there was no identifiable PMTL trend (reference Figure 1).

At present, the single subject deposited in autumn (Subject H) shows no tooth loss (Figure 9A-B). This is expected as only six weeks have passed since deposition. There has been significant loosening, however, most likely due to unseasonably warm temperatures in the months of October and November. All subjects deposited at the facility in winter months were lacking the necessary anterior dentitions or completely edentate. Thus, no subjects were available for observation. General trends in PMTL of subjects deposited in winter were recorded by McKeown and Bennett (1995). They

found initial exposure to seasonably cold temperatures of winter months to decelerate the decomposition process, resulting in complete skeletonization with retained dentition. These findings correlate with other well documented human and animal soft tissue decay rates.

Direct relationships have also been established between decay rates of soft tissue and the successional pattern of carrion insect activity (Byrd and Castner, 2000). Application of this relationship may provide explanation for seasonal decay rate variation. Insect activity has been declared "a major factor responsible for decomposition" (Rodriguez & Bass, 1983). In warmer exposed environments, insects feed ravenously and appear before or immediately after the moment of death. Consequently, human decomposition occurs most rapidly during the spring and summer months.

Generally, flies will visit and lay eggs on carcasses in temperatures as low as 40°F-50°F, however, fly eggs will die at temperatures below 32°F (Byrd and Castner, 2000). Expeditious skeletonization is usually resultant of "high numbers of voraciously feeding fly larvae" in correlating high ambient temperatures (Haglund and Sorg, 1997). A significant stage in the metamorphosis of the fly is the migration and pupation of larvae below ground surface. Maggots that migrated away from the body to burrow in the ground to pupate reside there through colder months, awaiting the return of warmer temperatures. Maggots feeding inside body cavities such as the head, chest, abdomen and vagina continue to feed in freezing temperatures accommodated by heat producing capabilities in large populations. Freezing temperatures outside the body are fatal to maggots exposed to such conditions (Mann et al., 1990).

Due to lack of available research regarding insect/maggot activity on the soft tissues of the oral cavity, it is unclear how entomological considerations relate to PMTL. Histological investigation into the components of dental support structures complements morphological exploration of support mechanisms. The discussion that follows pertains to tissues of the periodontium and is a detailed continuation of periodontal ligament considerations found in the introduction (Berkovitz et al., 2002; Avery, 2002; Ten Cate, 2003).

The tissues responsible for support and functional mechanisms of teeth are collectively referred to as the periodontium. These tissues surround each tooth for support, protection and nourishment. This functioning network of tissues includes cementum, alveolar processes of the maxillae and mandible, the periodontal ligament and the gingiva. It is necessary to understand the role of each component in the living oral cavity to effectively relate patterns of decomposition processes to PMTL.

Cementum is the only tissue considered part of the tooth as well as a component of the periodontium. It is a thin, calcified layer of tissue that completely covers the dentine of the tooth root and serves as an area of attachment for the periodontal ligament fibres. The outer surface is juxtaposed to the periodontal ligament with tight adherence to dentine along the inner surface. In this way, cementum facilitates attachment to collagen fibrils of the periodontal ligament, anchoring the tooth in socket. Cementum is a highly responsive mineralized tissue quite similar to bone in chemical composition as well as physical properties; however, it is avascular and has no innervation. Due to the relative softness and cervical thinness, cementum is readily removed by abrasion when

exposed by gingival recession. As a result, dentine is exposed to the environment of the oral cavity and becomes vulnerable to attack.

The alveolar process is the bony portion of the maxilla and mandible in which teeth are embedded for protection and support. An arbitrary boundary demarcates the alveolar process from the body of the mandible/maxilla along the root apices. The alveolar process includes the lingual and facial cortical plates, alveolar crest, trabecular bone and the alveolar bone proper. The alveolar bone and the periodontal ligament cooperate to manage the majority of the support system.

The alveolar bone proper is lined with alveolar sockets in which the roots of the teeth are anchored by the periodontal ligament. These cavities are separated by plates of bone termed interdental septa in the single-rooted anterior dentition and interradicular septa in the multirooted posterior dentition. The compact bone lining of the sockets has been assigned different names, however, it will be referenced as the cribiform plate in this investigation. The cribiform plate varies in thickness (0.1 to 0.5 mm) and contains vascular canals and bundles of Sharpey's fibres that pass between the alveolar bone and periodontal ligament. Maintenance of bone mass is dependent upon functional stimuli thus, the alveolar bone atrophies when function loads decrease, or in the case of fatality, completely cease. In this way, the alveolar bone atrophies as supporting soft tissues of the periodontium decompose, subsequently contributing to post mortem tooth exfoliation.

Periodontal ligament decay is often a fundamental variable in post mortem tooth loss. Therefore, the specialization of this ligament merits specific histological consideration. Comprehensive understanding of periodontal attachment loss during

disease and/or decomposition, is precipitated by exploration into the functional significance and specialization of the periodontal ligament.

The extent of specialization in the periodontal tissue in terms of structure, function and composition has only recently received detailed histological attention. Although it is presently unclear why the periodontal ligament does not calcify, it is known to remain a soft connective tissue despite an external bony envelope and an internal border of cementum. Evidence suggests that the collagen fibres, vasculature and ground substance of the ligament all contribute significantly to the mechanism whereby a tooth attains and maintains its functional position. Therefore, the mechanism of support should not be attributed to a single component of the periodontal ligament, but as a functioning whole. Following is a brief examination of the primary components.

Collagenous fibres comprise well over ninety percent of the connective tissue fibres associated with the periodontal ligament. With a turnover rate between three and twenty-three days, collagen in the periodontal ligament turns over faster than all other connective tissues in the mammalian body. Collagen type I is most abundant, representative of approximately seventy percent of periodontal collagen. This variety of collagen is the major protein component of most bone and skin connective tissues. Type III collagen constitutes almost twenty percent, is not localized to any specific region and links covalently to collagen of type I throughout the tissue. Relatively small amounts of types V and VI collagens have been found as well as evidence of basement membrane collagens IV and VII, associated with epithelial cells and blood vessels. Furthermore, it is believed that the connective tissue architecture is regulated through expression of type XII collagen, a fibril associated collagen with interrupted helices. These fibrils link

various types of collagen in fully functional ligaments. This occurs with a distribution pattern representative of collagen in connective tissue under compression rather than that of connective tissue under tension, such as tendon.

The principal collagen fibres arrange with different orientations in various regions of the periodontal ligament (Figure 3). These configurations include the dentoalveolar crest fibres, horizontal fibres, oblique fibres, apical fibres and interradicular fibres. Each is responsible for specific support functions and serviced by the unique vascular system of the periodontal ligament.

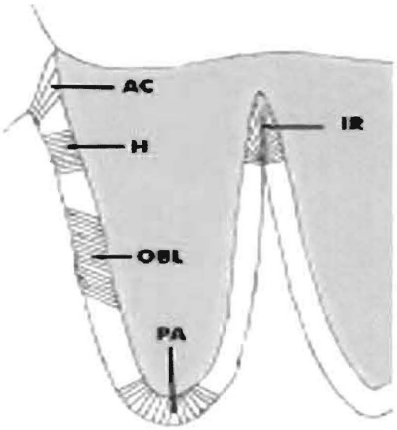

Figure 3— This diagram shows the location of some of the **principal fibers** of the periodontal ligament. **AC:** alveolar crest fibers; **H:** horizontal fibers; **OBL:** oblique fibers; **PA:** periapical fibers; **IR:** Interradicular fibers

The vasculature of the periodontal ligament accommodates a rich blood supply with service from the superior and inferior alveolar arteries as well as appropriate arteries from the gingiva. Major vessels of the ligament are situated between the principal fibre bundles, close to the wall of the alveolus. The vessels anastomose to form a capillary plexus around each tooth beneath the gingival crevice. The complex vasculature in this region is believed to be of particular importance to the dentogingival seal, which is charged with resisting passage of toxic products from bacterial accumulation. Fenestration of capillaries is a specialized feature of the periodontal ligament indicative of the high metabolic requirements. Veins usually do not accompany the arteries, but instead pass throughout the alveolar walls into the intraalveolar venous networks. Despite generalizations that the periodontal ligament consists primarily of collagen, ground substance is in fact the most abundant component of this specialized tissue.

The ground substance of the periodontal ligament is relatively inaccessible and biochemically complex. Consisting of mainly hyaluronate glycosaminoglycans, proteoglycans and glycoproteins, all components are believed to be secreted by fibroblasts. The proteoglycans are compounds of anionic polysacchaides covalently attached to a protein core. The collagen fibre bundles are composed of approximately sixty percent ground substance by volume. This ground substance is believed to have numerous important functions such as ion and water binding and exchange, control of collagen fibrillogensis and fibre orientation. Fluid pressure is high is the tissues of the periodontium (approximately 10mm Hg) which contributes significantly to tooth support mechanisms. This high fluid pressure accommodates several functions of the gingiva.

The gingiva is a tough, insoluble protein mucosa that surrounds each tooth forming a collar at the cervical region. It is composed of mucosa designed for chewing. There are two recognized regions, the main attached component is coronal to the free gingiva.

Attached gingiva is bound to both cementum and alveolar bone. The external surface is normally a masticatory orthokeratinized mucosa, however, as much as seventy-five percent may be parakeratinized. Healthy attached gingiva shows characteristic surface stippling corresponding to the sites of epithelial ridges. Apically, the attached gingiva is differentiated from the alveolar mucosa by the mucogingival junction that lies approximately three to five millimeters below the alveolar crest.

Coronal to the attached gingiva is a narrow rim of mucosa, known as free gingiva. The free gingiva is not bound to underlying hard tissue. The free gingival groove delineates its junction with attached gingiva. The coronal limit of the free gingiva is

marked by the gingival margin, above which is an unattached region known as the gingival sulcus. Underlying connective tissue of the periodontium is sealed from the oral environment by the dentogingival junction. The strength of this seal is dependant upon attachment of the junctional epithelium to the tooth as well as pressure exerted by fibres and tissue fluid of the underlying connective tissue. This seal is relatively weak providing minimal resistance to toxic products of the bacterial accumulations.

Contributions to the support mechanisms of the teeth are also made by regions of the interdental gingiva and the lamina propria of the gingiva (listed with functional significance increasing respectively). The interdental gingiva refers to regions of gingiva between adjacent teeth that conform in shape to each tooth. Support functions of this region are evidenced by its characteristic wedge-shaped appearance when viewed in a buccolingual plane. The lamina propria of the gingiva provides support for free gingiva, aide in binding attached gingiva to the alveolar bone and tooth as well as linkage between teeth. Dense collagen bundles form principal fibre groups classified by orientation and attachments. Their primary function is to provide support for the gingiva against the tooth and alveolar bone surface.

During postmortem soft tissue decomposition, the process of gingival recession seems to be accelerated by carrion insect/maggot activity. This activity was observed in the oral cavity of Subject H (Figures 9A-B). Dependent upon the degree and duration of insect/maggot activity, alveolar bone may quickly become exposed, promoting accelerated atrophy. As a mineralized supporting tissue, this bone serves a fundamental role in tooth support mechanisms. Gingiva/tooth attachment contributes limited support and may influence PMTL; however, atrophy of the alveolar bone compromises all other

support tissues as well. Accordingly, this event powerfully accelerates PMTL. The degree of alveolar bone loss has been shown by Duric and coworkers (2004) to significantly affect the frequency of both antemortem tooth loss (AMTL) as well as PMTL. Thus, exploration and documentation of variables that contribute to alveolar bone loss could provide strong correlation between PMTL and postmortem interval.

All supporting structures of the teeth are compromised by periodontal diseases. These pathological conditions severely damage the anastomosing fashion of supporting structures leading to periodontal attachment loss, alveolar bone loss and ultimately, tooth disarticulation. Bone destruction in periodontal disease is consequential of inflammation spreading from the gingiva into alveolar bone. Bone resorption follows this process causing a thinning of the surrounding bony trabeculae, enlargement of the marrow spaces and reduction in bone height. Porous alveolar bone already damaged by periodontal disease is more sensitive to decay during the post mortem interval.

Chronic inflammatory periodontal disease is one example of conditions affecting support structures. Toxic products released by dental plaque can cause destruction and loss of periodontal ligament as well as adjacent alveolar bone. Such a process often results in a deepening of the periodontal pocket and loss of attachment tissue. Ultimately, this loss of attachment tissue exposes the root of the tooth, increasing tooth mobility and subsequent exfoliation. Statistical analysis, performed by Duric and coworkers (2004), reveals the significance of periodontal disease on both AMTL and PMTL. They showed that periodontal attachment loss is "strongly predictive of tooth loss" and relatively easy to measure. Tooth loss predictions were made based on increases in risk with every

millimeter of attachment loss (promoting AMTL). Increased motility, at the moment of death, begins promoting PMTL. Unfortunately however, PMTL is much harder to assess.

Conclusion:

Comprehensive review of data does not permit postmortem tooth loss to indicate valid postmortem temporal markers. Patterns in PMTL were generally indicative of various seasonal and environmental variables known to influence soft tissue decomposition. However, due to isolated inconsistencies and the relatively short time parameters of this research, circumstantial correlation could not be achieved with complete certainty.

An abundance of circumstantial conditions directly and/or indirectly influence multitudes of inconsistent and unpredictable variables in the decomposition process. Such an environment can make observed trends in decomposing tooth support systems, and subsequent tooth loss, extremely difficult to establish and correlate with temporal markers. Additional complications arise from anatomically restricted access to important oral region, permitting only external observation of decomposing soft tissue without compromising experimental variables. A very limited collection of longitudinal PMTL assessments, offer a relatively weak foundation for qualitative reference. Consequently, a primary informative source in this research was histological literature.

Histological exploration of the fundamental components comprising the periodontium established reasonable explanation for observed morphological changes in oral cavity soft tissue and, consequently, tooth support mechanisms during decomposition. Although these texts proved informative and valuable, several

histological texts, occasionally, offered inconsistent, contradictory or "poorly understood" evidence of structure and function regarding specific components. Divergences in these areas were ultra-specific and considered negligible in PMTL consideration, but are indicative of further research and development.

It seems possible that relationships between teeth and corresponding attachment mechanisms could provide essential data in time-since-death analysis. However, significant development in experimental technique and extended periods of longitudinal observation are necessary to establish defined criterion in the decomposition process. This research should be considered a primitive foundation in collaborative assessment and cooperative efforts to reveal valid forensic indications inherently expressed in postmortem tooth exfoliation.

References

(1) Haglund, W. D. and Reay, D. T., "Problems of Recovering Partial Human Remains at Different Times and Locations: Concerns for Death Investigators," *Journal of Forensic Sciences,* Vol. 38, No. 1, January 1993, pp. 69-80.

(2) Haglund, W. D.., Reay, D. Y., and Swindler, D. R., "Tooth Mark Artifacts and Survival of Bones in Animal Scavenged Human Skeletons," *Journal of Forensic Sciences,* Vol. 33, No. 4, 1988, pp. 985-997.

(3) Hill, A., "Disarticulation and Scattering of Mammal Skeletons". *Paleobiology,* Vol. 5, No. 3, 1979, pp. 261-274.

(4) Boaz, N. T. and Behrensmeyer, A. K., "Hominid Taphonomy: Transport of Human Skeletal Parts in an Artificial Fluviatile Environment," *American Journal of Physical Anthropology,* Vol. 45, 1976, pp53-60.

(5) Bass and Jefferson 2004

(6) Berkovitz, B. K. B., Holland, G. R., and Moxham, B. J., *Oral Anatomy, Histology and Embryology,* Third Edition, Edinburgh, Mosby, 2002, pp. 168-170: 180-206: 232-239.

(7) Avery, James K. *Oral development and histology.* 3rd Edition. Stuttgart, Thieme, 2002.

(8) Ten Cate, A. R. *Ten Cate's oral histology: Development, Structure, and Function.* Sixth Edition. St. Louis, Mo.,Mosby, 2003.

(9) Mann, R. W., Bass, W. M., and Meadows, L., "Time Since Death and Decomposition of the Human Body: Variables and Observations in Case and Experimental Field Studies, *"Journal of Forensic Sciences,"* Vol. 33, No. 1, January 1990, pp. 103-111.

(10) Rodriguez, W. C. and Bass, W. M., "Insect Activity and Its Relationship to Decay Rates of Human Cadavers in East Tennessee," *Journal of Forensic Sciences,* Vol. 28, No. 2, April 1983, pp. 423-432.

(11) Haglund, W. D. and Sorg, M. S., *Forensic Taphonomy: The Postmortem Fate of Human Remains.* CRC Press, Boca Raton, Fl. 1997. pp, 93-98: 151-163: 415-448.

(12) Byrd, J.H. and Castner, J. L., *Forensic Entomology: The Utility of Arthropods in Legal Investigations.* CRC Press, Boca Raton, Fl. 2000. pp. 143-176: 263-286.

(13) McKeown, A. H. and Bennett, J. L., "A Preliminary Investigation of Postmortem Tooth Loss." *Journal of Forensic Sciences,* Vol. 40, No. 5, September 1995, pp. 755-757.

(14) Duric, M., Rakocevic, Z., and Tuller, H., "Factors Affecting Postmortem Tooth Loss." *Journal of Forensic Sciences,* Vol. 49, No. 6, September 2004.

Appendix 1

Photographic Illustrations of Subjects A-H

Figure 4-A:
Subject F
Enclosed in body bag, Subject F lost dentition at the highest rate. Micro-environment conduce to voracious maggot activity Maxillary loss at nine weeks and mandibular at ten weeks.

Figure 4-B:
Subject F
Figure depicts Subject F after maxillary left central incisor loss.

Figure 5:
SubjectG
Subject G after significant maxillary and mandibular dentition loss. .

Appendix 1

Figure 6:
Subject G
Enclosed in a body bag, Subject G surprisingly, retained significant portions of soft tissue. The bag remained unzipped, patched with numerous holes throughout. Evident in the picture, the subject's arm was never completely in the body bag.

Figure 7 A:
Subject D
Subject D retained dentition, however, did show significant loosening. In the picture to the left, the maxilla and mandible are held in this position. The cranium and mandible had completely disarticulated.

Figure 7 B:
Subject D
A poor quality photo of what is most likely antemortem, cranial right head trauma. Soft tissue may have been removed prior to deposition, subsequently affecting PMTL rates. Also evident is complete disarticulation of the cranium and mandible.

Figure 8:
Subject E
Subject E was deposited with an edentate maxillary arch which, therefore, did not contribute to PMTL observations. Photo to the left was taken after mandibular right lateral incisor loss.

Figure 9(A):
Subject H
Subject H was the only deposition in the months of fall. No PMTL was observed, almost certainly due to breadth of time. Subject was deposited six weeks before conclusion of research. There was, however, relatively significant loosening of dentition (primarily mandibular.)

Figure 9(B):
Subject H
This photo was taken seven days after deposition to show insect/maggot activity on soft tissues of the facial region and, more specifically, the oral cavity. Maggots are preset, however, already migrated deeper into the body cavity. This picture is of particular relevance to the discussion of entomological considerations in PMTL.

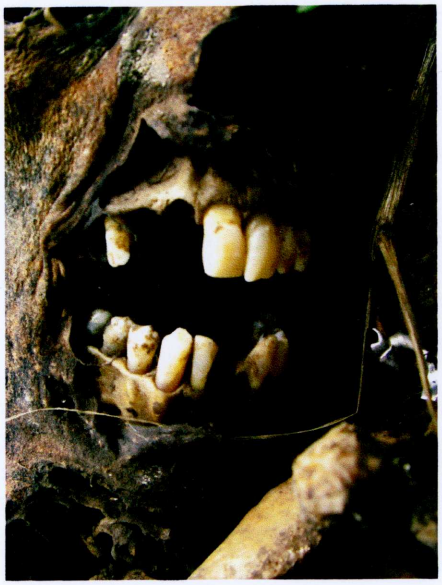

Figure 10(A): Subject A
Subject A was deposited in spring and lost only mandibular dentition. Trends in PMTL observed among all spring depositions were inconsistent and/or non-existent.

Figure 10(B): Subject A
All subjects deposited in spring retained significant amounts of soft tissue (as seen above) in no consistent patterns. This is most likely due to initial exposure to the cooler spring time temperatures which can cause soft tissue to desiccate. Random rates and frequencies of PMTL observed may also be indicative of tissue desiccation.

Figure 11(A): Subject B
Subject B, also deposited in the spring, lost maxillary dentition, but retained mandibular while showing significant loosening uniformly.

Figure 11(B): Subject B
Soft tissue remains, probably desiccated by cooler temperatures of the spring. This was observed in all three spring depositions. This was the only identifiable pattern among the three.

Figure 12(A): Subject C
Subject C was entirely covered with desiccated soft tissue.

Figure 12(B): Subject C
Color enhancement of the oral cavity shows dentition separating from the support structures. The small, odd shaped tooth in the anterior mandible was probably clinically manipulated to accommodate dental appliances..

Figure 13:
Maggot activity in the body bag of Subject F.

Figures 14(above) & 15(left):

Teeth exfoliated in the decomposition process.