To the Graduate Council:

I am submitting herewith a thesis written by David Paulus entitled "Lower Leg Injuries and Personal Watercraft Sports Activities". I have examined the final copy of this thesis for form and content and recommend that it be accepted in partial fulfillment of the requirements for the degree of Master of Science, with a major in Industrial Engineering.

Tyler Kress, Major Professor

We have read this dissertation
and recommend its acceptance:

John Hungerford

Reid Kress

Accepted for the Council:

Vice Provost and
Dean of Graduate Studies

LOWER LEG INJURIES AND PERSONAL WATERCRAFT SPORTS ACTIVITIES

A Thesis
Presented for the
Master of Science
Degree
The University of Tennessee, Knoxville

David Crandall Paulus
August, 2001

ABSTRACT

In this retrospective study, data from personal watercraft (PWC) accidents are examined in order to increase the understanding of lower leg injuries resulting from PWC sports activities. The literature indicates that approximately 33% of all PWC related injuries involve the lower leg, yet studies containing detailed reports of such injuries are scarce. Three major PWC manufacturers provided the data for this study. The data included associated x-rays and medical records from treating physicians, and sometimes witness descriptions of the accidents. The synopsis of each accident can give important details such as demographics of the injured person, make of the PWC(s) involved, and the injuries sustained. The x-rays provide objective data regarding the resulting fracture. Each accident summary is discussed such that the injured parties remain undisclosed. A refined literature review provides summary information as to the anatomy of the leg as well as the injury causing mechanisms. In summary, of the twenty-seven files, sixteen are external rotation injuries. In other words, 59.3% of the injuries are primarily the result of an external rotation movement of the foot. Also, nine out of twenty-seven, or 33.3% are due to one of the bending mechanisms (impact or inertial bending). The 33.3% of injuries primarily due to bending are is broken up into 11.1% pure bending, 7.4% impact, and 14.8% inertial bending. The remaining two, or 7.4% were primarily caused by an axial mechanism. An interesting observation is that the results in this study indicate that the most common motion resulting in ankle fracture is external rotation. This is also sited as the most common motion that results in ankle injury in "Fractures of the Lower Extremity", by J. Charles Taylor, as stated in chapter III's literature review.

TABLE OF CONTENTS

CHAPTER		PAGE
I.	INTRODUCTION	1
	Fracture Mechanisms	2
II.	TERMINOLOGY	3
	Bones of the Lower Leg and Foot	3
	Ankle Terminology	5
	Selected Fracture Terms	6
	Anatomic Orientation Terms	9
	Descriptions of Joint Movements	12
III.	LITERATURE REVIEW	15
	Fractures of the Ankle, II. Combine Experimental Surgical and Experimental-Roentgenologic Investigations, Lauge-Hansen	15
	Fractures and Injuries of the Ankle, Geissler, Tsao, Hughes	20
	Fractures of Lower Extremity, Taylor	26
	Traumatic Disorders of the Ankle, Hamilton	27
	Malleolar Fractures and Soft Tissue Injuries of the Ankle,Carr & Trafton	30
IV.	APPROACH	31
V.	CASE STUDIES	33
VI.	RESULTS AND DISCUSSION	51
	BIBLIOGRAPHY	57
	APPENDIX	60
	VITA	142

LIST OF FIGURES

FIGURE		PAGE
1.1	Survey of CPSC/NEISS Injury Comment Data	69
1.2.	Survey of injury location	71
1.3.	1998 NTSB Injury Data	73
2.1	Bone Basics of the Lower Leg	75
2.2	Ligaments as Seen from the Posterior of the Right Ankle	77
2.3	Terminology Summary of Motions Resulting in Ligament Damage	79
2.4	Fracture Types	81
2.5	Pronation and Supination as Seen from the Posterior of the Right Ankle	83
3.1.	X-rays from file 1AQK	85
3.2.	X-rays from file 1CAB	87
3.3	X-rays from file 2ELB	89
3.4.A.	X-rays from file 2GIK	91
3.4.B	More x-rays from file 2GIK	93
3.5	X-rays from file 3HAK	95
3.6	X-rays from file 1KRY	97
3.7	X-rays from file 3KRB	99
3.8	X-rays from file 4KWB	101
3.9	X-rays from file 4LOK	103

3.10 X-rays from file 5MAK 105

3.11 X-rays from file 6MAK 107

3.12 X-rays from file 7MAK 109

3.13 X-rays from file 8MIK 111

3.14 X-rays from file 2PAY 113

3.15 X-rays from file 5PEB 115

3.16 X-rays from file 3PLY 117

3.17 X-rays from file 6PUB 119

3.18 X-rays from file 7RAB 121

3.19 X-rays from file 4ROY 123

3.20 X-rays from file 9SAK 125

3.21 X-rays from file 10SCK 127

3.22 X-rays from file 8SHB 129

3.23 X-rays from file 5TUY 131

3.24 X-rays from file 11WIK 133

4.0 James Galyon, M.D. Curriculum Vitae 135

5.0 Figure 5.0 AO Ankle Fracture Classification System Taken Directly from"Pocketbook of Orthopaedics and Fractures", by Ronald McRae, Published by Churchill Livingstone in 1999 140

CHAPTER I

INTRODUCTION

The intent of the study was to examine data from personal watercraft (PWC) accidents in order to increase the understanding of lower leg injuries resulting from PWC sports activities.

Estimates indicate that PWC use more than tripled in the United States from 1990 to 1995, yet has decreased somewhat in recent years. In 1998 the National Transportation Safety Board (NTSB) report states that the PWC manufacturers estimate that 200,000 PWCs are sold per year. With the popularity and rapid growth of this activity come inevitable injuries. The study of such injuries is important in order to better understand engineering mechanisms that relate to anatomical consequences (i.e. injuries). Careful assessment of resulting fractures can provide an increase in the understanding of the kinematics of the leg during PWC sports activities.

The use environment for various PWC model configurations include operators who stand, sit, or kneel, and who have varying degrees of skill and experience. PWC operating environments involve a spectrum of visibility levels, weather variations, water traffic density, and other possible obstacles. Characterizing all possible accident scenarios, resulting injuries, and their associated causative factors poses a serious challenge.

The United States Coast Guard estimates that there were over one million PWC users in 1998. Figure 1. 1. in the Appendix shows a survey of CPSC/NEISS injury comment data taken from 1989 to 1992 PWC report injuries. According to the report, 36.2% of the injuries involve the leg. A study involving PWC accidents in New Jersey in 1996 states that 33.6% of all PWC accident injuries and 38.1% non-collision PWC accident injuries involve the lower leg. See a summary figure of the data from this study in Appendix Figure 1.2. A report by the NTSB report states that approximately one-third of PWC injuries involve the lower leg, including the foot and ankle. Figure 1.3 in the Appendix shows a breakdown of the 1998 NTSB injury data. Literature containing detailed reports of lower leg injuries from PWC use is scarce.

Fracture Mechanisms

Generally speaking, axial, external rotation and bending loads are the primary engineering mechanisms or foot movement responsible for lower leg bone fractures. Most often, lower leg and ankle fractures to the PWC occupant involve a combination of these mechanisms because of the dynamics associated with PWC operation and use, e.g. jumping waves or wakes causes vertical loading to the lower leg, turning/upper body kinematics cause external rotation loading, and inertial effects and impact with structures induce bending.

CHAPTER II

TERMINOLOGY

Bones of the Lower Leg and Foot

Following are brief descriptions of the bony structures in the lower leg and foot. Figure 2.1. shows the basic bones of the lower leg.

Calcaneus: the heel bone; also called the os calcis; located rearward on the foot and is somewhat rectangular in shape.

The word "calcaneus" comes from the Latin word calx, meaning limestone. The heel bone looked like a lump of chalk (to someone), and the word "calcium" also comes from calx.

Cuboid: one of five tarsals that articulates with the calcaneus proximally and with the fourth and fifth distally.

Cuneiform bones: three of five tarsals that articulate with the navicular proximally and the first, second, and third metatarsals distally.

Fibula: the smaller of the two long bones in the lower leg (the larger one being the tibia); laterally positioned, it is not weight bearing, and it articulates with the tibia proximally and with the tibia and talus distally.

The word "fibula" comes from the Latin meaning clasp or brooch. The fibula was likened to a clasp attaching it to the tibia to form a brooch. The fibula is sometimes commonly referred to as the calf bone

Metatarsals: five long cylindrical bones; these articulate with the tarsals proximally and with the phalanges distally.

Navicular: one of five tarsals that articulates with the talus proximally and the three cuneiform bones distally.

Phalanges: first labeled as bones of the fingers by Aristotle in 4th century B.C. (and since extended to the bones of the toes) because they were arrayed like Greek soldiers for battle; there are generally three phalanges (distal, middle, proximal) for each toe or digit, except the large toe (or digit 1, which has two phalanges).

Talus: the ankle bone; the ankle joint is formed by the talus and the bottom of the tibia and fibula that rest upon it;

the Latin word "talus" means ankle and in medicine it can refer to the entire ankle, too.

Tibia: the larger of the two long bones in the lower leg (the smaller one being the fibula); medially positioned, with its proximal end as a major knee component and distally providing substantial structure of the ankle mortise.

"Tibia" is a Latin word meaning both shinbone and flute. It is thought that "tibia" refers to both the bone and the musical instrument because flutes were once fashioned from the tibia (of animals).

Ankle Terminology

Ankle: the ankle joint is complex; made up of two joints: the true ankle joint and the subtalar joint:

- **true ankle joint** is composed of 3 bones: the tibia, which forms the medial (inside) portion of the ankle; the fibula which forms the lateral (outside) portion of the ankle; and the talus underneath; the true ankle joint is responsible for the up-and-down motion of the foot.
- **subtalar joint** is under the true ankle joint and consists of the talus on top and calcaneus on the bottom; the subtalar joint is responsible for the side-to-side motion of the foot.

The ends of the bones in the joints of the ankle are covered by cartilage. There are many ligaments that reinforce the bony articulations I the ankle region. The major ligaments of the ankle include the deltoid ligament complex on the inside of the ankle (connecting the tibia to the talus and calcaneus and providing medial stability to the ankle), (deltoid), the anterior talofibular ligament (ATFL), the calcaneofibular ligament (CFL), the posterior

talofibular ligament (PTFL), the anterior tibiofibular ligament (connecting the tibia to the fibula), and the lateral collateral ligaments (attaching the fibula to the calcaneus to give the outside of the ankle stability). The deltoid is located medially and provides resistance to eversion. The ATFC, CFL, and the PTFL are all laterally positioned and restrict inversion. Figure 2.2 shows the ligaments as seen from the posterior of the right ankle.

Malleolus: bony prominence on either side of the ankle; there are three malleoli per ankle, and they are described by their positon, medial, lateral, and posterior. The medial and lateral malleoli are located at the distal end of the tibia and fibula, respectively. The posterior malleolus is a small lip located on the distal posterior surface of the tibia.

Syndesmosis: fastening or ligament.

Selected Fracture Terms

Fracture: a break in the bone or cartilage; usually is a result of trauma; a fracture can, however, be the result of an acquired disease of bone such as osteoporosis or the result of abnormal formation of bone in a congenital disease of bone such as osteogenesis imperfecta ("brittle bone disease").

Fractures are classified by their character and location. Examples of classification include "spiral fracture of the femur," "greenstick fracture of the radius," "impacted fracture of the humerus," "linear fracture of the ulna," "oblique fracture of the metatarsal,"

"compression fracture of the vertebrae," and "depressed fracture of the skull." Figure 2.4 in the Appendix shows selected fracture types.

Fracture, avulsion: a fracture that occurs when a joint capsule, ligament, or muscle insertion of origin is pulled from the bone as a result of a sprain dislocation or strong contracture of the muscle against resistance; as the soft tissue is pulled away from the bone, a fragment or fragments of the bone may come away with it.

Fracture, comminuted: fracture in which bone is broken, splintered or crushed into three or more pieces.

Fracture, compound: fracture in which the bone is sticking through the skin; also called an open fracture.

Fracture, compression: fracture caused by compression, the act of pressing together; compression fractures of the vertebrae are especially common in the elderly.

Fracture, displaced: a fracture removed from the normal location or position.

Fracture, greenstick: fracture in which one side of a bone is broken while the other is bent (like a green stick); usually occurs in children when the bone is more ductile than brittle.

Fracture, impacted: a fracture in which one of the fragments is driven into the cancellous tissue of the other fragment.

Fracture, longitudinal: a fracture involving the bone in the line of its axis.

Fracture, non-displaced: not removed from the normal location or position.

Fracture, oblique: a fracture the line of which runs obliquely to the axis of the bone.

Fracture, open: fracture in which the bone is sticking through the skin; also called a compound fracture.

Fracture, Salter-Harris: traumatic fracture of the physeal and/or epiphyseal growth plate.

Fracture, segmental: a fracture in two parts of the same bone.

Fracture, spiral: fracture, sometimes called a torsion fracture, in which a bone has been twisted apart.

Fracture, stress: fracture caused by repeated input, as may occur in sports, strenuous exercise, or heavy physical labor; common in the metatarsal bones of the foot, particularly in runners; osteoporosis increases the possibility of stress fractures.

Fracture, torsion: fracture, sometimes called a spiral fracture, in which a bone has been twisted apart.

Fracture, torus: fracture in which one side of the bone bends, but does not actually break; torus fractures normally heal on their own within a month with rest and disuse, although they can cause soreness and discomfort.

Fracture, transverse: fracture in which the break is across the bone, at a right angle to the long axis of the bone.

Anatomic Orientation Terms

Anterior: the front, as opposed to the posterior.

Anteroposterior: from front to back, as opposed to posteroanterior.

Coronal Plane: vertical plane passing through standing body from left to right.

Distal: farthest from the head or source, as opposed to proximal.

Dorsal: the back, as opposed to ventral. Pertaining to the back or posterior side of a structure; dorsal comes from the Latin word "dorsum" meaning the back. (Examples include:

The dorsal surface of the hand is the back of the hand, the side opposite the palm.

The dorsal surface of the foot is the back of the foot, the side opposite the sole.)

The opposite of dorsal is ventral which comes from the Latin "venter" meaning belly. Something that is ventral is oriented toward the belly, toward the front of the body.

Horizontal: parallel to the floor, a plane passing through the standing body parallel to the floor.

Inferior: lower or beneath, as opposed to superior.

Lateral: toward the left or right side of the body, as opposed to medial; the side of the body or body part that is farther from the middle or center (median) of the body; typically, lateral refers to the outer side of the body part, but it is also used to refer to the side of a body part. For example, when referring to the knee, lateral would mean the side of the knee that is farthest from the opposite knee. The opposite of lateral is medial. In radiology, "a lateral" is slang for an x-ray taken from the lateral side. It also means toward the left or right side of the body, as opposed to medial. The eyes are lateral to the nose.

Medial: in the middle or inside, as opposed to lateral; the side of the body or body part that is nearer to the middle or center (median) of the body (with reference to moving left-and-right). For example, when referring to the knee, medial would mean the side of the knee that is closest to the other knee. The opposite of medial is lateral.

Plantar: Having to do with the sole of the foot.

Posterior: the back or behind, as opposed to the anterior.

Posteroanterior: from back to front, as opposed to anteroposterior.

Pronation: rotation of the forearm and hand so that the palm is down (and the corresponding movement of the foot and leg with the sole down), as opposed to supination.

Prone: with the front or ventral surface downward (lying face down), as opposed to supine.

Proximal: toward the beginning, as opposed to distal.

Sagittal: vertical plane passing through the standing body from front to back; the mid-saggital, or median plane, splits the body into left and right halves.

Superficial: on the surface or shallow, as opposed to deep.

Superior: above, as opposed to inferior.

Supination: rotation of the forearm and hand so that the palm is upward (and the corresponding movement of the foot and leg), as opposed to pronation.

Supine: with the back or dorsal surface downward (lying face up), as opposed to prone.

Transverse: horizontal plane passing through the standing body parallel to the ground.

Ventral: pertaining to the abdomen, as opposed to dorsal.

Vertical: upright, as opposed to horizontal.

Descriptions of Joint Movements

Figure 2.3 in the Appendix shows selected movements of the ankle. Figure 2.5 shows pronation and supination as seen from the posterior of the right ankle.

Abduction: refers to the movement of a limb sideways away from the midline of the body; abduction of the legs serves to spread the legs.

Adduction: opposite of abduction in this sense is adduction. Adduction of the legs brings the legs together; the word "abduction" comes from the Latin prefix "ab-" meaning "away from" + "ducere" meaning "to draw or lead" = "to draw away from."

Dorsiflexion-plantarflexion: uniaxial hindfoot rotation in the sagittal plane.

Eversion: a turning outward, as of the foot.

External / internal rotation: uniaxial (forefoot rotation relative to the hindfoot about the vertical axis) hindfoot rotation about the long axis of the tibia.

Flexion-extension: uniaxial hindfoot rotation in the sagittal plane; process of bending or the state of being bent by which body segments are brought towards each other. Flexion of the fingers results in a clenched fist. The foot dorsiflexes or plantarflexes. The prefix "dorsi" refers to the back, and "planar" means having to do with the sole of the foot. Flexion-extention have the same meaning as dorsiflexion-plantarflexion, but dorsiflexion-plantarflexion are the preferred terms for describing ankle motion.

Inversion: a turning inward, as of the foot.

Pronation: rotation of the arm or leg inward; in the case of the arm, the palm of the hand will face posteriorly.

Supination: rotation of the arm or leg outward; in the case of the arm, the palm of the hand will face forward.

CHAPTER III

LITERATURE REVIEW

Fractures of the Ankle, II. Combine Experimental Surgical and Experimental-Roentgenologic Investigations, Lauge-Hansen

The first piece of literature that is pertinent to this study is called "Fractures of the Ankle" by N. Lauge-Hansen, M.D. of Randers, Denmark. Using combined experimental-surgical and experimental-roentgenologic investigations, the exact knowledge of the mechanism, pathologic anatomy, genetic roentgenologic diagnosis and genetic reduction of fractures of the ankle is obtained. Lauge-Hansen's work (published in 1950) involved experimentally fracturing ankles to determine the relationships between position and motion and resulting anatomical damage. Also, by dissection the pathologic anatomy was ascertained, and by roentgen examination the genetic roentgenologic diagnosis was established.

Experiments were done on fresh extremities that were amputated at the upper end of the crus or the femur, and they were wrapped up immediately and kept that way until the experiments took place a few hours later.

It is essential that the foot be able to be placed in any position that a normal foot may adopt before the experiment is carried out. That means that there was always free movability of the talocrural joint and the other joints in the foot. The only instruments

that were used in the experiments were a vise and nails used to fix the foot or crus, and all the fractures were produced by hand. The possible movements of the foot and ankle joint first must be explained in order to understand the results of the experimental investigations.

The first primary movements of the foot are dorsiflexion and plantar flexion. Dorsi refers to the back and plantar refers to the sole of the foot. Flexion refers to the process of bending or the state of being bent. These are hinge movements of the foot around a transverse axis through the trochlea of the talus in the talocrural joint.

The second primary movements of the foot to be understood are supination and pronation. The foot rotates internally for supination and externally for pronation around a longitudinal axis through the foot. A combination of the mobility of the articulations between the talus, calcaneous, talus-navicular, calcaneous-cuboid and tarsal-metatarsal bones result in the possible movements of the foot. Adduction and abduction will occur during supination and pronation. Adduction and abduction are the respectively, tibial and fibular flexion of the entire foot particularly in the hindfoot in relation to the crus around a sagittal (vertical through the body) axis. During supination and pronation, inversion and eversion will also occur. Inversion and eversion are referred to respectively as inward and outward rotation, or tibial and fibular turning of the tip of the foot.

Pronation is a combined movement made up of outward rotation, abduction of the hindfoot and eversion of the forefoot. Likewise, supination is a combined movement

made up of inward rotation, adduction of the hindfoot and inversion of the forefoot. Whether the foot is dorsiflexed, plantar flexed, or some position between the two extremes, the supination-pronation movements are always of the same degree. An important factor is that supination and pronation are combined movements. The components, adduction and inversion for supination and abduction and eversion, each will produce its own particular type of ankle fracture when they occur as abnormal forced movements of the foot or as large un-physiological forced movements.

Different ligaments tighten on maximum supination and pronation causing the leg to be completely inflexible and stiff. Whatever position the foot is in at the moment of the forced movement is what produces the fracture. For example, if the foot is maximally pronated and forced abduction or eversion is applied, or if the foot is maximally supinated and forced adduction or eversion is applied, the energy of the forced movements will be transmitted to the malleolar fork due to an abnormal rotation of the talus in relation to the malleoli. This produces abnormal pressure against the malleoli and abnormally vigorous tension in the side ligaments.

Lauge-Hansen observed that injuries occurred in a sequential manner, which are separated into stages. In his system, first the position of the foot at the time of injury is noted. Secondly, the direction of the deforming force is noted. Ninety-five percent of all injuries to the ankle can be placed in one of the following four groups: supination-adduction, supination-eversion, pronation-abduction, and pronation-eversion. Lauge-Hansen uses the terms eversion and inversion; however, they are the same as external

rotation and internal rotation of the foot. Pronation-dorsiflexion was added later as a fifth group in order to account for fractures caused by axial loading. The adduction/abduction forces were induced by nailing the foot to a horizontal surface either supinated or pronated. Then the deforming force was applied by grasping the knee region and moving the crus medially for adduction and laterally for abduction. In order to produce the eversion force, the femur stump was fixed in a vise. Then the operator grasps the anterior part of the foot, which is either pronated or supinated and then forcibly everted, while the other hand supports the heel to maintain supination or pronation.

The classification with their respective stages of injury are listed below in the same summarizing format as found in "Fractures and Injuries of the Ankle" by Geissler, Tsao, and Hughes, page 2216.

Supination-Adduction (SA)

1. Transverse avulsion type fracture of the fibula below the level of the joint or tear of the lateral collateral ligaments
2. Vertical fracture of the medial malleolus

Supination-Eversion (External Rotation) (SER)

1. Disruption of the anterior tibiofibular ligaments
2. Spiral oblique fracture of the distal fibula
3. Disruption of the posterior tibiofibular ligament, or fracture of the posterior malleolus

4. Fracture of the medial malleolus or rupture of the deltoid ligament

Pronation-Abduction (PA)

1. Transverse fracture of the medial malleolus or rupture of the deltoid ligament.
2. Rupture of the syndesmotic ligaments or avulsion fracture of their insertion(s)
3. Short horizontal oblique fracture of the fibula above the level of the joint

Pronation-Eversion (External-Rotation) (PER)

1. Transverse fracture of the medial malleolus or disruption of the deltoid ligament
2. Disruption of the anterior tibiofibular ligament
3. Short oblique fracture of the fibula above the level of the joint
4. Rupture of the posterior tibiofibular ligament or avulsion fracture of the posterolateral tibia

Pronation-Dorsiflexion (PD)

1. Fracture of the medial malleolus
2. Fracture of the anterior margin of tibia
3. Supramalleolar fracture of the fibula
4. Transverse fracture of the posterior tibial surface

The table gives a gross summary of Lauge-Hansen's results from his experimental investigations.

Fractures and Injuries of the Ankle, Geissler, Tsao, Hughes

The second important piece of literature to be reviewed is Chapter 31 "Fractures and Injuries of the Ankle", written by Geissler, Tsao, Hughes in the fourth edition of "Rockwood and Green's Fractures in Adults", Volume 2. The mechanisms of injury are described in detail. Factors that affect the pattern of injury include the quality of the bone, the age of the patient, the position of the foot at the time of injury, and the magnitude, direction, ant rate of the loading forces.

Lauge-Hansen contributed much of the current understanding of the mechanisms of ankle injuries. His emphasis was on the influence that the position of the foot at the time the deforming force acted on the leg in creating the injury pattern. Then the position of the leg was correlated to the direction of the deforming force. The positions of the foot are reiterated as supination and pronation. Plankovich clarified that supination and pronation refer to the position of the foot as it rotates around the axis of the subtalar joint. The common deforming forces that act on the ankle are abduction, adduction, external rotation, and vertical loading. External and internal rotations are rotational movements around the vertical axis of the tibia. The deforming forces adduction and abduction result in rotation of the talus around its longitudinal axis. This is the terminology used in describing the mechanisms of injury.

Supination-Adduction

The lateral structures tighten as the foot supinates. Portions of the lateral collateral ligaments may rupture or be avulsed from their bony attachment sites on the distal fibula if the supination and adduction force is continued, resulting in an ankle sprain. Alternatively, a transverse fracture below the level of the intact syndesmotic ligaments may result from the distal fibula being avulsed. The talus is driven against the medial side of the joint from further adduction. This results in a vertical fracture of the medial malleolus and occasionally an impaction fracture of the medial articular surface of the tibia. An osteochandral or impaction fracture of the talus or injury to its articular surface may also result from these forces.

Supination-External Rotation

The lateral structures and anterior syndesmotic ligaments tighten when the foot is in a supinated position, and it is rotated externally. The same results occur from the leg internally rotating on the planted, supinated foot. A rupture of the ligament or avulsion of its bony insertion(s) usually injures the anterior syndesmosis. A spiral fracture of the fibula running anterioferior to posterosuperior is caused by external rotation. Above, at, or below the attachment site of the anterior tibiofibular ligament on the anterior tubercle of the fibula is where the fracture begins. The most common place for the fracture to begin is at or just above the level of the anterior tubercle. In this case, the anterior syndesmosis is partially or completely disrupted. The anterior tibiofibular ligament remains intact if the fracture begins below the anterior tubercle of the fibula. However, the fracture passes obliquely through the superior articular surface of the fibula. In the

rare occurrence that the supination-external rotation pattern is seen in fibular fractures beginning above the level of the syndesmosis, there is disruption of both the interosseous membrane and the syndesmosis. If the applied force is continued, the talus will rotate and put tension on the posterior syndesmosis. This will cause either rupture of the posterior tibiofibular ligament, or an avulsion of the posterior lateral tubercle. The latter is more common, though. In some cases, the fracture of the fibula may, in effect, decompress these structures. This causes the force of the talus to be directed medially which results in no posterior injury. Lastly, if there is enough force remaining, an avulsion fracture of the medial malleolus or rupture of the deltoid ligament will occur. The talus is free to move laterally in this medial injury.

Pronation-Abduction

The medial structures become tight, and they are the first thing to be injured when the foot is positioned in pronation. The first injury is either the deltoid ligament is ruptured or there is an avulsion fracture of the medial malleolus. The force of the abduction then avulses the bony attachment sites or it ruptures the syndesmotic ligaments. If the force continues laterally from the talus, it will fracture the fibula at or above the level of the syndesmosis. This same force will also rupture the interosseous membrane up to the level of this fracture. A bending mechanism caused this fracture, which means that it is either oblique or partially transverse with butterfly fragments or lateral comminution. An associated medial injury is signaled by such a fibular fracture pattern.

Pronation-External Rotation

The first side to be injured is the medial side. The anterior tibiofibular ligament or its bony insertion is ruptured by the external rotation. Next, the fibula is fractured spirally at or above the syndesmosis. The fracture runs anterosuperior to posteroinferior even though it is a spiral fracture. There is also a rupture of the interosseous membrane up to the level of the fracture on the fibula. The posterior syndesmosis is injured if the rotation continues. The injury is either an avulsion fracture of the posterolateral tibia or a rupture of the ligament. External rotations cause proximal fractures of the fibula (Maisonneuve-type). Fibula fractures vary in pattern, and they reflect a supination-external rotation or pronation-external rotation type of injury. During the injury, it is even possible for the foot to move from relative pronation to supination.

Vertical Loading

The talus is driven into the distal tibia from vertical loading. The pattern of the injury is affected by the rate of loading and the position of the foot. Injury patterns can range from complex, intra-articular fractures of the distal tibia (pilon fractures), to isolated fractures of the posterior or anterior lip of the tibia. This is the end of Lauge-Hansen's system.

Pilon Fractures

Pilon fractures are explosive injuries and can be compared to a hammer striking a nail, where the hammer is the talus and the tibia is the nail. Only seven to ten percent of tibial fractures are pilon fractures. Any shear, bending, or torsion forces as well as the

position of the foot at the time of the impact will affect the fracture pattern configuration. If the foot is dorsiflexed upon impact, it will lead to greater comminutions or anterior lip fragments. On the other hand, if the foot is planarflexed upon impact, it causes an increased tendency for more posterior comminution or larger posterior lip fragments. This is because the compressive forces are directed posteriorly. Fracture patterns may easily defy any classification, however, due to angular and rotational forces. These forces lead to greater metaphyseal extension of fractures with comminution of various degrees either laterally or medially.

Danis-Weber System

Another very useful classification system is the Danis-Weber system. This system is based on the level of the fracture of the fibula. There is a greater risk of injury to the syndesmosis the more proximal the fracture to the fibula. This also makes it more likely that the joint will be unstable. In this classification system there are three types of fractures: type A, B, or C.

If the fracture of the fibula occurs below the level of the tibial plafond, then it is a type A injury. The foot supinates causing this avulsion fracture. It is also possible for there to be an oblique or vertical fracture of the medial malleolus if the force continues. In the Weber system, the type A fracture corresponds to the supination-adduction injury of the Lauge-Hansen system.

External rotation causes an oblique or spiral fracture, which is a type B injury. The fracture begins near or at the level of syndesmosis. It is possible to have an associated injury to the posterior malleolus and the medial side of the ankle. In the Weber system, the type B fracture corresponds to the supination-eversion injury of the Lauge-Hansen system.

A fracture of the fibula above the syndesmosis is a type C fracture. There is a disruption of the syndesmosis, and usually there is an associated injury on the medial side of the ankle. Type C fractures in Weber's classification system are divided into two groups: fractures that involve the diaphysis of the fibula, and fractures that involve the proximal fibula (Maisonneuve type). The Lauge-Hansen classification that corresponds to the Weber "C' is pronation eversion or pronation abduction.

The AO classification further divides the Danis-Weber system into three groups per type. The AO classification of malleolar fractures is described below:

Type A: Fibular Fracture Below Syndesmosis (Infrasyndesmotic)

A1 – isolated

A2 – with fracture of the medial malleolus

A3 – with postmedial fracture

Type B: Fibula Fracture at the Level of Syndesmosis (Transsyndesmotic)

B1 – isolated

B2 – with medial lesion (malleolus or ligament)

B3 – with a medial lesion and fracture of the posterolateral tibia

Type C: Fibula Fracture Above Syndesmosis (Suprasyndesmotic)

C1 – diaphyseal fracture of the fibula simple

C2 – diaphyseal fracture of the fibula complex

C3 – proximal fracture of the fibula

The literature at hand mentions several classification methods, but Ruedi and Allgower's clinically relevant and simple method will be discussed. This method classified pilon fractures as type I, II, or III. Type I fractures are identified as cleavage fractures of the articular surface. There is minimal displacement of the intra-articular fracture fragments. Type II fractures have moderate intra-articular incongruity, but they have significant displacement of the intra-articular fractures without comminution. Lastly, Type III fractures have significant comminution with impaction of the distal tibia and gross incongruity of the articular surface.

Fractures of Lower Extremity, Taylor

In the eighth edition, Volume 2 of "Campbell's Operative Orthopedics", J. Charles Taylor wrote chapter 23 entitled, "Fractures of Lower Extremity". Although fractures of the ankle may be classified along purely anatomic lines as trimalleolar, bimalleolar, or monomalleolar, Lauge-Hansen's classification system related the fracture pattern to the mechanism that caused the injury. This detailed classification method,

which has already been described, is again divided into the four groups, supination-eversion, supination-adduction, pronation-abduction, and pronation-eversion. The term "eversion" in this classification system is a misnomer. It is more correctly termed "external" or "lateral rotation".

Taylor continues to discuss Lauge-Hansen's study. Supination-eversion (supination-external rotation) is the most common mechanism. The feature that identifies this mechanism is a spiral oblique fracture of the distal fibula and a fracture of the medial malleolus or a rupture of the deltoid ligament. The supination-adduction mechanism is identified by a transverse fracture of the distal fibula, and the medial malleoulus has a relatively vertical fracture. Characteristic of the pronation-abduction mechanism is a transverse fracture of the medial malleolus and a short oblique fracture of the fibula. The oblique fracture of the fibula appears relatively horizontal on the lateral roentgenogram. Finally, the identifying feature of the pronation-eversion (pronation-external rotation) is a spiral oblique fracture of the fibula relatively high above the level of the ankle and a deltoid ligament tear or a fracture or a fracture of the medial malleolus. The literature then continues by describing fixation methods of the ankle, which is not of interest in this study.

Traumatic Disorders of the Ankle, Hamilton

Chapter 13 focuses on fractures of the posterior and anterior tibial margins. Fractures of the posterior tibial margin are discussed first. In general, fractures of the

dorsal aspect of the distal tibia occur in association with external rotation or abduction injuries. They also involve the lateral aspect of the dorsal tibia. Although it is less common, sometimes, when the talus has subluxed medially, dorsal fractures are encountered with stage II supination-adduction injures. When this occurs, the fracture tends to involve the medial aspect of the dorsal tibia and occasionally the fragment stays attached to the fractured medial malleolus.

Small dorsolateral fractures are commonly seen. They are the result of an avulsion (via the posterior inferior tibiofibular ligaments) or from pressure directly exerted by the talus and/or lateral malleolus as they subluxate posterolaterally as with abduction or external rotation injuries. Small dorsomedial lesions are the result of either direct pressure exerted on the tibia by the talus subluxating posteromedially, which occurs with supination-adduction injuries, or by an avulsion (via the tibial periosteum). The small dorsomedial lesions are less common, though. Larger lesions that involve a significant amount of the articular surface will result if compression injury is sustained in association with the previously mentioned avulsion and pressure forces.

The terms posterior tibial tubercle, posterior tibial margin, posterior tibial lip, and posterior malleolus are used synonymously in this text.

Isolated fractures of the posterior tibial margin are discussed next. Usually, fractures of the posterior tibial margin occur with other ligament injuries or malleolar fractures. However, there are occasional situations where such a lesion occurs in what

appears to be an entirely isolated phenomenon. Palmer believes that excessive plantar-flexion of the foot cause an anterior capsular tear and subsequent fracture of the posterior tibial margin in isolation. Lauge-Hansen concluded that isolated fractures of the posterior tibial lip do not exist, because he did not encounter any such injury in his experimental or clinical studies. Several other theories supporting the occurrence of such injuries are noted, giving the basis that it is safe to presume that "isolated" posterior tibial lip fractures can occur in the absence of malleolar injury. However, posterior tibial margin fractures do not occur without some degree of associated soft tissue damage such as anterior diastasis – anterior inferior tibiofibular ligament rupture.

Fractures of the posterior tibial margin with articular surface involvement are discussed next. Such fractures usually occur in association with fracture or dislocation of the ankle. It is rarely seen as an apparent "isolated" injury. Fractures of the lateral and medial malleolus in association with articular fractures of the dorsal tibia and posterior subluxation of the talus were originally coined "trimalleolar". However, even minor extracapsular fractures of the posterior tibial margin have been included due to a loosening of the terminology. Next, fixation is discussed, but is not of interest to this study.

Finally, fractures of the anterior tibial margin are discussed. Capsular avulsions occasionally cause small fractures that involve little if any of the articluar surface of the anterior tibial margin. These small fractures occur in association with lateral ankle sprains. The force that causes the injury includes a significant element of plantarflexion

with internal rotation and adduction. It is very rare for a large anterior tibial lip fracture that involves the articular surface to occur as an isolated phenomenon. Such injuries are usually seen in association with fractures of the neck of the talus or with pilon or pronation-dorsiflexion injuries.

Malleolar Fractures and Soft Tissue Injuries of the Ankle, Carr and Trafton

First the anatomy and biomechanics of the ankle are described in great detail. More detail is given than is needed for this study; therefore, the diagrams provided are sufficient in outlining the anatomy of the ankle. Next, evaluation of the injured ankle is discussed beginning with the history and moving to physical examination. Then radiographic imaging is discussed, followed by management of ankle fractures. After that, definitive treatment of malleolar fractures along with their classifications is given a detailed account. This includes the Lauge-Hansen classification system that has already been described, as well as the new AO fracture classification system, which expands that of Danis-Webber. Then, treatment of these injuries is explained followed by a description of soft tissue injuries of the ankle. Since the literature previously reviewed cover similar topics, the details of this piece of literature will be omitted in the name of brevity.

CHAPTER IV

APPROACH

Twenty-seven real PWC accident synopses were written based on associated medical records and x-rays provided by three major PWC manufacturers. There was no pattern to the amount of information provided by the manufactures, and the content of the files varied greatly. The synopses were pieced together by the information provided. The injuries reflect types of leg fractures that occur during the operation of a PWC. Access to medical records of injuries of this type is not readily available inasmuch as they do not occur with enough frequency to be obtained from a random sample of hospital medical records. The nature and location of the injury was identified and documented. In order to classify and understand these types of fractures and their mechanisms, common classification systems were utilized while consulting with an experienced orthopedic surgeon.

A summary of the methodology is as follows:

1. obtained files regarding real PWC accidents from PWC manufacturers,
2. narrowed study to include primarily lower leg fractures,
3. reviewed literature regarding ankle fractures and terminology,
4. summarized relevant accidents into synopses in order to describe scenarios of the accidents and determine the injury diagnoses,

5. characterized and categorized fractures and possible associated fracture mechanisms,
6. consulted with orthopedic surgeon for diagnostic and mechanism assessments,

Chapter V

CASE STUDIES

A unique four or five digit alphanumeric code has been used to identify each case file in order to maintain confidentiality. Figures 3.1 to 3.24 in the Appendix show the x-rays for files 1 through 24. X-rays were not available for files 25 through 27.

File 1: 1AQK. The accident occurred on August 30,1996. It involved a six-year-old female, an eighteen-year-old female, and an eleven-year-old male. The six-year-old was riding in front of the eighteen-year-old on a 750 model PWC. The eleven-year-old male was riding a 650 stand-up model PWC. He struck the females at a right angle on their left side.

The eighteen-year-old sustained a fracture of her left proximal tibia, a fracture through the anterior proximal tibia with a level of tibial tubercle oblique fracture. The six-year-old sustained a comminuted open fracture of her left tibia and fibula with a ten-centimeter laceration of the lateral maleollus.

File 2: 1CAB. This file involves a thirty-four year-old-female. She was riding a PWC on August 3, 1996 on the Delta Waterway in Contra Costa County, California on the day of the accident. A large wake from a passing yacht hit her PWC broadside. In a letter composed on August 26, 1996 by the injured person to the personal watercraft manufacturer she stated her theory that "the footwell is too deep and narrow, which traps

the foot in such a way that any severe jolt puts ones ankle in danger of being broken by the impact of the ankle hitting the adjacent lip of the boat".

The first x-rays post accident reveal a fracture involving the lateral malleolus with only slight displacement of the fracture fragments. The ankle mortise is intact. The impression is a fracture of the lateral malleolus.

On August 6, 1996, a treating orthopedic physician wrote a report of his visit with the injured thirty-four year-old woman. In the report he writes that the x-ray films demonstrate an obliquely-oriented fracture involving the lateral malleolus. The ankle mortise appears satisfactory. There is also a 1.0 to 2.0 millimeter displacement of the fracture fragment. His diagnosis is a fracture of the left lateral malleolus. The mechanism that caused the fracture is from a bending motion

File 3: 2ELB. It involves a thirty-eight year-old male riding a 1994 model of PWC. He was injured in a single vehicle accident on May 15, 1994. His injury consisted of a fracture of the medial tibial plateau on the left side. He also had a fracture of the head of the left fibula.

Medical records from May 15, 1994, state that the injured man was found to have a proximal tibial fracture. In the Emergency Room he was neurovascularly intact in the left lower extemity with obvious swelling of the knee. X-rays show a comminuted tibial plateau fracture. The patient was admitted to a medical center for further assessment and

definitive open reduction and internal fixation. An attending phyician's assessment of the injury is a complex proximal tibial plateau fracture of the left leg.

A radiology report from May 16, 1994, states that a fracture extending from mediolateral tibial plateau extending inferiorly is demonstrated. There are also multiple comminuted osseous fragments present. The fracture extends through all cortices. A depression of tibial spine by approximately one centimeter is demonstrated.

There are also multiple framents depressed on the medial and an avulsion of the tibial spine with fractures into the lateral side. In additon, the head of the fibula is avulsed off.

A physicians's consultation report from May 21, 1994, states that the patient's evaluation has shown that there is an extremely comminuted fracture of the proximal tibia with multiple fragments depressed on the medial side and avulsion of the tibial spine with fractures into the lateral side. He goes on to say that the patient is neurovascularly intact, though there have been some paresthesias in the lateral peroneal distribution and a little numbness.

The patient has a significant past history in that he has been diagnosed as having an 80% tear by arthroscopy on the knee that was injured. The consultation report also says then says that he thinks the patient is unstable on the lateral side and that the head of the fibula is avulsed off. The physician thinks he will need to have lateral ligamentous

complex opened up and a direct repair as necessary. He also thinks that he would then put on an external type of fixture to hold the multiple fragments. The patient will probably need a small medial incision to elevate the tibial plateau and probably will need bone grafting.

Another radiology report from on May 23, 1994, states that there is approximately a one-centimeter lateral offset of the proximal tibia with regard to the tibial shaft, and there is a fracture line extending into the knee joint space itself.

The injured person testified on October 11, 1996, that he was making a hard right turn when he fell off the PWC. He speculates that his leg was trapped and the fracture resulted from the leg hitting the "outside wall" of the personal watercraft.

File 4: 2GIK. The accident involved a thirty-two year-old-male riding an 1100 model PWC. Emergency department's records at Citizens Memorial Hospital state that the patient fell off his personal watercraft on July 19, 1997 sustaining an injury to his right leg in which he could not bear any weight.

An emergency room physician states that the x-rays of the tibia, fibula, and foot were done. The tibia/fibula x-ray shows a spiral fracture of the mid shaft of the fibula. It also shows a fracture/dislocation of the ankle with the tibia displaced laterally. There is also a possible fracture of the talus and fracture of the distal fibula. The foot x-ray did not confirm the talus fracture.

The doctor informed the patient of the x-ray results and the need for immediate orthopedic consultations. He explained the possibility that he may need surgery and/or closed reduction that evening. The patient decided to be transferred to another hospital. The patient was given 25mg of Demerol and went by private vehicle to the other hospital. The lower leg was placed in a sugar tong splint with OCL, and his x-rays were copied and sent.

The clinical impression of the original emergency room physician is a fractured fibula, fractured ankle, and a fractured foot

A radiologist read the x-rays of the right tibia/fibula and states that the AP and lateral views of the right tibia and fibula were submitted. He states that there is a comminuted, very minimally displaced fracture of the right fibular shaft at approximately the level of the mid and distal thirds. There is a mild anteromedial subluxation at the tibiotalar joint. The conclusion is that there is a comminuted fracture of the right fibular shaft, a posterior malleolar fracture, and subluxation of the right tibiotalar joint.

Three views of the right ankle were obtained. He goes on to say that there is a comminuted fracture of the shaft of the right fibula. There is a chip fracture off of the posterior malleolus, the avulsed fragment measuring approximately 1.5 x 1 centimeter. There is partial subluxation anteromedially at the right tibiotalar joint. Additional radiology records of the right ankle conclude that there is a small chip fracture of the

posterior malleolus, an anteromedial subluxation of the right tibiotalar joint, and a right tibial shaft fracture.

Concerning the right foot, the radiologist states that there are fractures of the right fibula, right posterior malleolus and subluxination at the right tibiotalar joint. Otherwise, no bony abnormalities are seen in the bones of the right foot.

At the second hospital, a radiologist wrote a report of the injured man to the attending physician on July 19, 1997. He states that multiple views were obtained of the right ankle and lower one-half of the lower leg. He says that there is a comminuted fracture through the mid-distal junction of the right fibula. The fracture has a minimally displaced oblique component. The longitudinal component of the fracture also seen with its proximal most aspect is not fully delineated on the images.

He continues to say that there is a fracture through the posterior malleolus of the tibia as demonstrated on the lateral view. There also are small avulsion fragments from the tip of the medial malleolus. Small bony densities also project over the medial joint space on one of the AP views. These fracture fragments are neither seen on an additional AP view nor on an internal oblique view. Also, there is widening of the medial joint space in the ankle.

The impression is that there is a comminuted fracture through the mid to distal fibula, a fracture through the posterior malleolus of the tibia, a small avulsion fragment

seen distal to the medial malleolus. He also suspects avulsion fracture fragments in the medial joint space. Lastly, he notes the relative widening of the medial joint space.

File 5: 3HAK. It involved a twenty-six year-old-female. On June 28, 1997, the woman owned and was operating a 1993 750 model of PWC on Lake Shelbyville in Illinois. The final diagnosis by an attending physician is a bimalleolar fracture of the right ankle with displacement. The fracture was likely open, which related to a pinpoint wound overlying the medial malleolus.

The radiology report for the right ankle from three views show that there are fractures of the medial malleolus, the distal fibula, and a nondisplaced fracture of the posterior malleolus. There is a slight lateral subluxation of the talus.

The injured woman's attorney states in a letter that while the woman was operating the personal watercraft on the day of the accident she was, "traveling at a relatively slow speed, she hit a wave and the handlebars on the PWC jerked completely out of both of her hands. The PWC jerked to the left, and her momentum continued to carry her forward."

File 6: 1KRY. The person injured is a thirty-eight year-old female in an accident that occurred on August 18, 1996. She was the passenger behind her fourteen year-old son on a 1995 PWC. A radiology report reviewed the knee from four views. A radiologist describes the injury as a left tibial lateral plateau depressed fracture (depressed

3-4 millimeters). His impression is that there is a left lateral tibial plateau fracture, which appears depressed.

An attending surgeon states that her final diagnosis is a depressed, comminuted displaced lateral tibial plateau fracture of the left knee. The woman also sustained a torn lateral meniscus. According to James Galyon, M.D., this is a valgus strain, which means that a lateral bending moment caused the impaction of the tibial plateau.

File 7: 3KRB. This file involved a forty year-old male. On August 27, 1994, he was riding a 1994 PWC with his eighty-five pound daughter in front of him (as a passenger), and his one hundred-six pound wife behind him (as a passenger). As the three were at an idling speed, a three-foot wake from another boat hit the side of their personal watercraft. The man's left leg snapped as he and the others fell off the personal watercraft on the left side.

The injured forty-year-old male was taken to the emergency room after the accident. The emergency room report states that the A.P. and lateral views of the lower leg were obtained. An acute spiral type fracture is seen extending through the distal shaft of the left tibia. The A.P. view demonstrates mild displacement of the distal fracture fragment in relation to the proximal shaft fragment by approximately thirteen millimeters. The lateral view demonstrates posterior displacement of the distal fracture fragment in relation to the proximal shaft fragment by approximately four millimeters. An acute comminuted fracture is also seen involving the mid shaft of the left fibula.

There is approximately seven millimeters of maximum displacement as seen on the lateral view. The impression is of acute fractures involving the shaft of the left tibia and left fibula.

File 8: 4KWB. The accident occurred on June 24, 1995, involving a thirty-seven year-old-male on a 1994 model PWC. Apparently, the man that was injured was riding with two other men at the time of the accident. He claims that while traveling at approximately twenty-five miles per hour, a three-foot wave hit the personal watercraft sending the PWC to the right as he fell to the left. He claims that his leg was trapped in the footwell causing the breaking of his left leg.

The thirty-seven year-old was taken to a hospital. The radiology report states that there is a spiral fracture of the distal shaft of the left tibia with a lateral and posterior displacement of the distal fracture fragments. There is also a comminuted fracture of the proximal shaft of the fibula.

File 9: 4LOK. On August 20, 1993, the fifty-seven year-old male was riding a PWC when he hit a wake and was thrown upward as the PWC tilted vertically. Then he came down hard landing back on the seat. The patient lost a testicle and had to have plastic surgery performed on his scrotum. An attending orthopedic surgeon's admitting diagnosis was an open left tibial plateau fracture and testicular trauma with a fractured left testicle.

File 10: 5MAK. The file consists of only x-rays, therefore there is no story behind the accident or the injured person. Orthopedic surgeon at St. Francis Hospital in Memphis, TN, James Galyon, M.D., upon reviewing only the x-rays, diagnosed the injury as an oblique spiral fracture of the left distal fibula.

File 11: 6MAK. On June 15, 1996, the twenty-four year-old male was riding his PWC at sixty miles per hour in a straight path. The man hit a wave and lost control, sending him over the handlebars. An attending physician recorded that the patient's injuries consist of a very comminuted fracture of the lateral malleolus and a very thin fairly large post medial butterfly fragment.

File 12: 7MAK. The sixteen year-old male was riding an 1100 model PWC on July 17, 1996. According to a witness, the young man made a very quick turn to the left, throwing him off to the right side of the vessel. A radiologist recorded the injuries to the right tibia and fibula. He stated that there is a Salter IV fracture of the distal tibia. The fracture extends obliquely through the lateral aspect of the distal tibial metaphysis and through the physis as well as the epiphysis. Some posterior and lateral displacement of the fracture fragment is noted. There is an associated oblique displaced fracture of the distal fibular diaphysis. In addition, there is marked soft tissue swelling associated with the fracture.

File 13: 8MIK. It involves a thirty-seven year-old male. He was riding an 1100 model PWC when he made a sudden left turn while travelling between twenty and forty

miles per hour. An attending radiologist states that there is a trimalleolar fracture of the left ankle. There is slight disruption of the ankle mortise, and the talus and calcaneus appear intact.

File 14: 2PAY. It involves a thirty-four year-old male. There is no explanation of the accident on August 10, 1996, but there is an emergency room x-ray report. The injury is described as a trimalleolus fracture/dislocation with posterior displacement of the talus. Furthermore, there is a displaced oblique fracture of the posterior malleolus, a non-displaced transverse fracture of the medial malleolus, and an oblique fracture of the distal fibula with lateral displacement distally.

File 15: 5PEB. It involves a twenty-seven year-old male. The accident occurred on March 3, 1997. According to the injured man, he was having difficulty making turns and fell five to ten times previously. He was going straight while sitting down, and he made a right turn at one-third throttle. Then, he made a 180-degree turn that took three to six seconds. Next he made a left turn. He started to lose the rear end, so he let off the throttle. Then he went to the right at a 90-degree angle. He felt his leg snap, and he recalled his right foot being stuck in the footwell. The injured man landed six to seven feet away from the PWC. He believes that the inside portion of the wall of the footwell is what caused the fracture to the fibula. He was wearing cross-trekker shoes at the time, and he thinks that the rubber itself may actually have held the foot.

A treating surgeon diagnosed the injury as a trimalleolar fracture/subluxation of the right ankle. The radiology report indicates the injury is a transverse fracture of the medial malleolus, a comminuted spiral fracture of the distal fibula, and a small linear bone density adjacent to the dorsal aspect of the talus, which may represent a small avulsion fracture. The physician states in a deposition on September 17, 1998, that this is a very common fracture pattern called a supination external rotation pattern, and it is almost always due to a twisting injury. He also states that axial loading patterns usually fractures the dome of the talus or the tibial plafond, which is the end of the tibia, and is often seen when someone falls or jumps off a roof or ladder. Although these scenarios cause a tremendous axial load injury that is more devastating than what this patient had, the physician states that he cannot rule out some involvement of axial loading.

File 16: 3PLY. James Galyon, M.D., orthopedic surgeon at St. Francis Hospital in Memphis, TN, on viewing the x-ray alone, stated that the injury is a comminuted, spiral fracture of the distal tibia with a fractured proximal fibula.

File 17: 6PUB. The accident involving a thirty-three year-old-male occurred on July 10, 1993, while he was riding a 1993 PWC. A consulting anatomist states in a letter that, "the injury consisted of a tri-malleolar fracture of the left ankle and non-displaced fractures of the metatarsals of the left foot. It was stated by the injured man in his deposition on June 5, 1995, that he was injured as the result of the handle grip coming off, and his losing his balance. He believes that a part of the machine struck his leg to cause the injury."

An attending reported on the injury. The left tibia and fibula x-rays show that a horizontal fracture of the medial malleolus is demonstrated with a three-millimeter separation of fragments. Also a fracture of the fibula is noted proximal to the tibia fibula synostosis. In addition, there is an un-displaced fracture of the posterior malleolus. The ankle mortise is asymmetrical with lateral displacement of the talus. No acute bony abnormality is demonstrated in the proximal tibia and fibula. The x-rays of the left foot reveal that an un-displaced transverse fractures of the base of the second, third, and fourth metatarsals are noted.

File 18: 7RAB. On August 12, 1996, a forty-seven year-old male was injured on a PWC. In relatively calm water, he made a turn to avoid a skier and boat. From the right turn, he fell off the left side of the PWC. According to a radiology the examination reveals an oblique fracture through the distal shaft of the fibula. The position and alignment appears adequate. In addition, the ankle joint mortise is anatomic, and calcification is seen in the distribution of the posterior tibial artery.

File 19: 4ROY. The accident occurred on July 28, 1996, involving a forty-nine year-old male riding a 1996 1100 model PWC. A physician was requested to interview and examine the patient on July 20, 1998 for the purpose of an independent medical examination (IME). The IME explains how the patient described the accident. The patient states that he had just slowed down and throttled off as he was approaching two other boats with skiers nearby. He states that a wave came and pushed him up off the

seat, but he still had his hands on the handlebars and he fell to his right. He states that his left leg came out of the well on the left side, but his right foot jammed in the well (he had tennis shoes on, not dock shoes). He felt a snap as he went over the side.

A radiology report dated July 28, 1996 states that there is a comminuted spiral variant fracture of the distal tibial shaft extending inferiorly through the metaphysis and posterior malleolus. There is marked posterior displacement of the distal segment as seen on the lateral projection. There is diastasis of the posterior malleolar fragment. There is no widening of the ankle mortise. The medial and lateral malleoli are apparently intact. There is a comminuted fibular neck fracture in the near anatomic position and alignment.

A consultant gave a deposition on December 10, 1998. He states that there has to be a high vertical loading for such an injury to occur. He also states that there is clearly rotation between the patient's upper body with the foot plant. A spiral fracture can occur if there is a vertical component that stops the foot from rotating, and it is likely that the body remained still while the craft pivoted.

File 20: 9SAK. According to the history and examination record from a hospital on May 25, 1997, the forty-seven year-old man was riding a PWC when he fell off and injured his right ankle. A closed reduction was performed and splint applied. A surgeon states on the operation record that the injury diagnosis to be a right ankle comminuted, compound, bi-malleolar fracture/dislocation. Orthopedic surgeon James Galyon, M.D. gave more detail upon viewing the x-ray. He said that the injury appears to be a

transverse fracture of the medial and lateral malleolus. He also stated that the injury is an angular deformity produced by pronation-abduction.

File 21: 10SCK. It involves a twenty-four year-old male riding a 1996 1100 model PWC on May 11, 1996. The file includes a deposition of the injured man, which has details of the accident. He stated that the PWC's nose (bow) dipped into the water and turned slightly to the left. He was then propelled over the handlebars when he hit the top of his left foot on the left handle bar. An attending radiologist stated in his report that there is an oblique fracture of the posterior malleolus. There is also a transverse fracture of the base of the third metatarsal, both on the left leg. The injury was referred to as a plantar flexion eversion injury on forms included in the file.

File 22: 8SHB. The accident involves a twenty-four year-old male riding a 1996 PWC on May 17, 1996. According to a patient history report written by an attending physician, the patient was jumping wakes of a boat when he fell off the PWC and landed on his right knee, against a corner of the PWC. In the injured man's deposition on November 24, 1997, he claimed that he has never jumped a boat wake on a personal watercraft. He then goes on to describe the accident. He was making a left turn at an approximate speed of fifteen miles per hour, and the left handle grip came off. He grabbed the right handlebar hard, and in doing so, squeezed the thumb throttle lever causing the PWC to accelerate rapidly out from under him. His right knee hit the boarding platform in the rear of the vessel back by the transom. An attending physician states that the x-rays demonstrate a comminuted fracture of the right patellar.

File 23: 5TUY. The accident involves a forty-one year-old male riding a 1996 PWC. According to an attorney, the man was riding toward shore when he made a sharp left turn in an effort to slow down. While making the turn, he was ejected to the right of the PWC. There are no medical or legal records in this file. Orthopedic surgeon, James Galyon, M.D., upon viewing a positive of the x-rays stated that there is a spiral fracture of the fibula.

File 24: 11WIK. The accident involved a thirty-five year-old male riding a PWC on April 20, 1997. According to an emergency department the man flipped his PWC at least twice, and he was thrown forward, up over the handlebars, catching his leg against the handle bar. An attending physician at the same hospital diagnosed the injury as a spiral mid-shaft fracture of the left femur. The diagnostic imaging report states that a comminuted laterally and posteriorly displaced fracture of the mid-shaft of the left femur is apparent. The fracture is a spiral fracture

File 25: 6ORY. It involves a thirty-seven year-old male riding a PWC on June 13, 1995. According to the man's deposition he hit a six to ten inch wake, and the PWC's nose dipped down. The man was thrown over the front, but he held on with his right hand. The nose of the PWC dipped about a foot. The PWC dipped once or twice before he fell to the right.

The thirty-seven year-old was transported to a hospital where x-rays were taken. An attending physician states in the emergency room record that the man sustained a spiral fracture of the right distal fibula.

File 26: 12SCK. The accident involves a twenty-nine year-old male riding a PWC on May 24, 1997. A clinical history states that the man was riding a PWC when it overturned, and he had an apparent inversion twisting injury to his ankle. The emergency room evaluation revealed a displaced fracture of the left fibula with posterior malleolar fragment of the tibia. The articular surface of the tibia was significantly disrupted. The surgeon's operative record noted a displaced fracture of the lateral and posterior malleolus of the left ankle. The radiology report states that there is a fracture of the lateral and posterior malleolus. The fracture fragments are essentially undisplaced.

File 27: 7GRY. According to the medical records, the twenty-nine year-old female was riding a 700 model PWC on July 16, 1995, when she jumped a wave causing her to fall off. The patient states that the kill switch did not operate appropriately, and the PWC came around and struck her in the right femur. She was taken the hospital and a radiologist examined the right femur in A.P. and lateral projections utilizing a portable imaging apparatus. There is a complete horizontally oriented fracture of the mid shaft of the right femur. There is a lateral displacement of the fracture fragment. Also, there is an approximate one-centimeter area of apposition involving the lateral cortex of the proximal femur and the medial cortex of the distal fracture fragment. A traction device is

identified, and the evaluation of the proximal femur is equivocal as is the evaluation of the right hemipelvis.

CHAPTER VI

RESULTS AND DISCUSSION

James Theodore Galyon, M.D., an orthopedic surgeon at St. Francis Hospital in Memphis, Tennessee, was consulted for review of the x-rays of each case and the medical explanations of each injury. From this he verified the injury with respect to the available diagnoses given in the original medical records of the injured persons. Then he classified the ankle injuries using Lauge-Hansen and AO ankle fracture classifications. Next, he stated the likely fracture mechanism or the movement of the foot that caused the injury. Dr. Galyon's undergraduate degree is from The University of Tennessee College of Medicine, Knoxville, TN, 1948-1950, and he went to medical school at The University of Tennessee College of Medicine, Memphis, Tennessee, 1950-1953, (M.D.-1953). Dr. Galyon's board certification is from the American Board of Orthopedic Surgery, January, 1964. The consultation took place on June 28, 2001 at his office in Memphis, TN where he is currently an orthopedic surgeon. His curriculum vitae in its entirety can be seen in the Appendix as Figure 4.0.

Sixteen of the twenty-seven injuries are primarily result of ankle rotation. The Lauge-Hansen fracture classification system focuses on the position of the foot at the time a deforming force acted on it relative to the lower leg. Dr. Galyon stressed that this fracture classification is used mostly when the foot supinates or pronates while running. Therefore, he stated that the foot underwent external rotation without stating supination

or pronation. However, from the AO classification, the A, B, or C can indicate the position of the foot. For example, the Weber type "B" corresponds to the Lauge-Hansen supination-eversion. The following sixteen files are grouped because the primary relative motion that the foot underwent that caused the fracture for each of them is external rotation.

The individual in file 1CAB sustains the first external rotation injury. The injury corresponds to a Lauge-Hansen supination-eversion (more correctly external rotation) injury and an AO classification of B1.1. The duration of the study will refer to the Lauge-Hansen term "eversion" as "external rotation". Furthermore, when the classification is supination or pronation followed by external rotation or abduction/adduction, it is assumed to be from the Lauge-Hansen system. Moreover, if the classifications that begin with the letters A, B, or C followed by two numbers divided by a period, it is assumed to be of the AO classification system.

The second external rotation injury is from file 2GIK, which falls in the category of a supination-external rotation, B2.2. The third is 3HAK, which is supination-external rotation, B2.2. The file labeled 3KRB is the fourth external rotation injury. It is not an ankle injury, which is why it does not have an ankle fracture classification.

The fifth external rotation injury is 4KWB, which is also not an ankle injury. However, the sixth and seventh are 5MAK and 6MAK, respectively, and they are both categorized as supination-external rotation, B1.1.

The eighth external rotation injury is 8MIK, and it also has an abduction element to it. It is categorized as supination-external rotation, B3.1. Next, the ninth external rotation injury is 5PEB, which is supination-external rotation, B2.2. The tenth and eleventh injuries with an external rotation causation mechanism are 3PLY and 7RAB, respectively, which are both not ankle injuries.

The twelfth external rotation injury, 4ROY, is also partly an inertial bending injury, meaning that there is posterior displacement as if the foot remained fixed while the body continued moving forward. It is also called an inertial injury.

The thirteenth external rotation injury is 5TUY, which is supination-external rotation, B1.2. The fourteenth external rotation injury, 11WIK, involves the femur; therefore, it has been excluded from analysis.

The last two external rotation injuries are 6ORY and 12SCK, and they are categorized as supination-external rotation, B1.2 and B2.3, respectively.

Nine of the injuries resulted from a bending mechanism, which also includes impact and inertial bending. Both of the females injured in file 1AQK's injuries were caused by direct impact from another personal watercraft.

The next injury resulted from a bending mechanism, and it is file 1KRY. This injury is a valgus strain. This means that the outward or lateral bending moment of the leg caused the injury.

The next three bending mechanism injuries are all inertial bending injuries. This means that the foot remained fixed while the body's inertia caused it to continue forward. It causes posterior displacement of the foot relative to the leg. The file labels are 7MAK, 2PAY, and 6PUB. File 2PAY and 6PUB's are ankle injuries with the fracture classification pronation-abduction or external rotation, C1.3. File 6PUB also has three fractured metatarsals that are from direct trauma.

The sixth injury caused by a bending mechanism is file 9SAK. This injury is caused by an inversion of the foot. The seventh file is 10SCK, and it is an inertial bending injury. The eighth injury, 8SHB, is from direct impact of the patella on the personal watercraft. Lastly, the ninth injury, 7GRY, is a bending moment of the right femur. In summary, two file's injuries are due to impact, three file's injuries are due to a true bending mechanism, and four file's injuries are due to inertial bending.

There are two injuries caused by an axial mechanism, 2ELB and 4LOK.

Of the twenty-seven files, twelve of them involve malleoli. Four of the files have trimalleolar fractures, which means that the posterior, medial, and lateral malleoli are all fractured. Four of the files have bimalleolar fractures, with one medial and lateral, one

lateral and posterior, and two medial and posterior. The remaining files involving malleolar fractures are all single malleolar fractures, with two lateral and two posterior malleoloar fractures.

Files containing fractures to the tibia and fibula that are not malleolar fractures are also present. Eleven files have fractures to the tibia, and fifteen have fractures to the fibula. There are also two files with a femur fracture.

In summary, of the twenty-seven files, sixteen are external rotation injuries. In other words, 59.3% of the injuries are primarily the result of an external rotation movement of the foot. Also, nine out of twenty-seven, or 33.3% are due to one of the bending mechanisms (impact or inertial bending). The 33.3% of injuries primarily due to bending are is broken up into 11.1% pure bending, 7.4% impact, and 14.8% inertial bending. The remaining two, or 7.4% were primarily caused by an axial mechanism. An interesting observation is that the results in this study indicate that the most common motion resulting in ankle fracture is external rotation. This is also sited as the most common motion that results in ankle injury in "Fractures of the Lower Extremity", by J. Charles Taylor, as stated in chapter III's literature review.

There are fourteen files that involve ankle fractures. Ten of them, or 71.4%, are the result of an external rotation movement. Three of the ankle fractures, or 21.4%, are caused by an inertial bending. The one remaining file is caused by a pure bending or inversion movement, which makes up 7.4% of the ankle fractures.

Table 1 in the Appendix summarizes the findings by stating the file number and label the age and gender of the injured person, followed by an abbreviated injury description, a mark for the location of the injury, the Lauge-Hansen and AO classification of ankle fractures, and lastly the joint movement or loading mechanism that caused the fracture. Then, Table 2 gives a description of the abbreviations used in the tables of the Appendix. Table 3 in the Appendix groups the files by their fracture mechanism or motion with a brief and abbreviated injury location. After that, Table 4 quantifies the results by the amount of files within various groupings. Finally, Figure 5.0 gives a detailed description and drawings of the AO classification system. The figure is taken from "Pocketbook of Orthopaedics and Fractures" by Ronald McRae FRCS (Eng, Glas) AIMBI.

BIBLIOGRAPHY

BIBLIOGRAPHY

Browner, Bruce D. Jupiter, Jesse B. Levine, Alan M. Trafton, G. 1998. Volume 2. "Skeletal Trauma" (2nd ed.). Malleolar Fractures and Soft Tissue Injuries of the Ankle. Carr, James B. and Trafton, Peter G. pp 2327-2397. Philadelphia. W.B. Saunders Company.

Crenshaw, A.H. 1992. Volume 2. "Campbell's Operative Orthopedics" (8th ed.). Fractures of Lower Extremity. Taylor, Charles J. pp 785-884. St. Louis. Mosby Year Book.

Galyon, James T. M.D. 2001. Personal Consultation. St. Francis Hospital. Memphis, TN. Orthopedic Surgeon.

Greene, Alan M.D. 2000. MedlinePlus Medical Encyclopedia. Fractures. Adam.com. http://www.medlineplus.com. Accessed on July 14,2001.

Gustilo, Ramon B. 1991. The Fracture Classification Manual. pp. 122-127. St. Louis. Mosby Year Book.

Hamilton, William C. 1984. Traumatic Disorders of the Ankle. pp 187-194. New York. Springer-Verlag.

Kozin, Scott H. Berlet, Anthony C. 2000. Handbook of Common Orthopedic Fractures (4th ed.). pp. 142-153. Willow Grove. MSI.

Lauge-Hansen, N. 1950. Archives of Surgery. Volume 60. Fractures of the Ankle. II. Combine Experimental Surgical and Experimental-Roentgenologic Investigations. pp 957-985. Chicago. American Medical Association.

Lundberg, A. Svensson, O. Byland, C. Goldie I. and Selvik, G. 1989. Kinematics of the Ankle/Foot Complex. Part 2: Pronation and Supination. Foot and Ankle. http://www.surefoot.com/orthotics/pronation/pronation.html.

McRae, Ronald. 1999. Pocketbook of Orthopedics and Fractures. pp. 455-459. Edinburgh. Churchill Livingstone.

MedicineNet.com Smart Medicine 1996. Medical Dictionary. http://www.medterms.com. Accessed on May 15, 2001.

National Transportation Safety Board. 1998. Personal Watercraft Safety. Safety Study NTSB/SS-98/01. Washington, DC.

Rockwood, Charles A. Green, David P. Bucholz, Robert W. Heckman, James D. 1996. Volume 2. "Fractures in Adults" (4th ed.). Fractures and Injuries of the Ankle. Geissler, William B. Tsao, Audrey K. and Hughes, James L. pp 2201-2254. Philadelphia. Lippincott-Raven Publishers.

Southern California Orthopedic Institute, 2000. Anatomy of the Ankle. http://www.scoi.com/anklanat.htm. Accessed on 19 June 2001.

Steenwyk Custom Shoes & Orthotics, 1984. Pronation and Supination. http://www.steenwyk.com/pronsup.htm. Accessed on 19 June 2001.

Wheeless, C.R., 1996. Wheeless' Textbook of Orthopedics, http://www.medmedia.com. Accessed on 19 June 2001.

APPENDIX

Table 1. Summary of Results

#	File	Age and Gender	Abbreviated Description of Fracture	Tibia		Fibula		Femur		Malleolus		Other		Ankle Fx Classifications		Comments
				left	right	left	right	left	right	left	right	left	right	L-H	AO	
1a	1AQK	18yof	fx L prox tib, fx thru ant prox tib at level of tib tubercle, oblique fx	x												impact
1b		6yof	comminuted open fx L tib & fib w/ 10cm lacer of lat mall	x		x										
2	1CAB	34yof	obliquely-oriented fx of L lat mall, displaced 1-2 mm							lat x				S-ER	B1 1	external rotation
3	2ELB	38yom	fx extending from L mediolateral tibial plateau extending inferiorly, multiple comminuted osseous frags present, fx extends thru all cortices, tibial spine depressed 1cm, multiple frags depressed on the medial, avulsion of the tib spine w/ fx's into the lat side, fib head avulsed off	x		x										axial
4	2GIK	32yom	small chip fx of the post mall, avulsed frag of med mall, anteromedial subluxationof R tibiotalar joint, R tib shaft fx, fx mid dist fib		x		x				(bi) m&p			S-ER	B2 2	external rotation
5	3HAK	26yof	fx's of R med mall & distal fib, nondisplaced fx of post mall, slight lateral subluxation of the talus, avulsed frag from med mall, comminuted fx mid distal fib				x				(bi) m&p			S-ER	B2 3	external rotation
6	1KRY	38yof	depressed, comminuted displaced lateral tib plateau fx L knee, torn lateral meniscus (valgus strain)	x												bending
7	3KRB	40yom	Acute spiral fx thru distal shaft L tib, mild displacement of distal fx frag in relation to prox shaft frag, acute comminuted fx mid shaft L fib, 7mm displacement	x		x										external rotation
8	4KWB	32yom	spiral fx distal shaft L tib w/ lat & post displacement of the distal fx frags, comminuted fx prox shaft fib	x		x										external rotation
9	4LOK	57yom	open L tib plateau fx& testicular trauma w/ fx L testicle, Comminuted fx prox 1/3 at tib extending into tib plateau	x								testicle				axial
10	5MAK	Unknown	oblique distal L fib fx, spiral			x								S-ER	B1 1	external rotation
11	6MAK	24yom	comminuted fx L lat mall, thin fairly large post medial butterfly frag, spiral fx fib			x				lat x				S-ER	B1 1	external rotation
12	7MAK	16yom	Salter IV fx R distal tib, fx extends obliquely thru lat aspect of distal tib metaphysis & thru physis & epiphysis, some post & lat disp of fx frag, associated oblique disp fx of dist fib diaphysis		x		x									inertial bending
13	8MIK	37yom	L trimalleolar fx, distal fib fx w/ deltoid rupture, fx of post tibia Non-displaced -posterior lip (malleolus)							tri x				S-ER	B3 1	external rotation
14	2PAY	35yom	trimalleolus fx/dislocation w/ post displacement of talus, displaced oblique fx post mall, non-displaced transverse fx med mall, oblique fx distal fib w/ lat displacement distally, fx fib, rupt syndes lig, fx tib								tri x			P-AB	C1 3	inertial bending
15	5PEB	27yom	R trimalleolar fx/subluxation, transverse fx med mall, comminuted spiral fx distal fib, small linear bone density adjacent to the dorsal aspect of the talus, which may represent a small avulsion fracture				x				tri x			S-ER	B2 2	external rotation
16	3PLY	Unknown	comminuted, spiral fracture of the R dist tib w/ associated fx fib		x		x									external rotation
17	6PUB	33yom	L ankle, trans fx med mall w/ 3mm separation of frag, fx of fib prox to tib-fib syndesmosis, an un-displaced fx of post mall, ankle mortise asymmetrical w/ lat disp of talus, L un-displaced transverse fractures of the base of the 2nd, 3rd & 4th metatarsals							tri x		3 meta tarsal		P-AB	C1 3	inertial bending
18	7RAB	47yom	oblique fx thru distal shaft L fib, calcification in distribution of the post tib artery			x										external rotation
19	4ROY	49yom	comminuted spiral variant fx distal tib shaft extending inferiorly thru metaphysis & post mall, marked post displacement of distal segment, diastasis of post mall frag, comminuted fib neck fx in the near anatomic position & alignment		x		x				post x					external rotation
20	9SAK	47yom	open bi-malleolar fx trans fx med mall, comminuted fx lat mall, post tibialis tendon rupture, R ankle, angular deformity from pronation-abduction								(bi) m&l			S-ER	B2 3	inversion, bending
21	10SCK	28yom	oblique fx L post mall, transverse fx base of third metatarsal							post X		3rd metat arsal				inertial bending
22	8SHB	24yom	transverse fx from direct impact, R patella										patella			impact
23	5TUY	41yom	oblique spiral fx fib				x							S-ER	B1 2	external rotation
24	11WIK	35yom	comminuted laterally and posteriorly displaced spiral fx of mid shaft of left femur					x								external rotation
25	6ORY	37yom	spiral fx R distal fib (ER records only, no x-rays available)				x							S-ER	B1 2	external rotation
26	12SCK	29yom	L displaced fx of lat & post mall (no x-rays available)							(bi) l&p				S-ER	B2 3	external rotation
27	7GRY	29yof	complete trans fx mid shaft R femur, lat displacement fx frag, 1cm area apposition involving lat cortex prox femur & med cortex distal fx frag (no x-rays available)						x							bending

Table 2. Description of Abbreviations Used in Tables 1, 3, and 4.

Abreviations used in "Abbreviated Description of Fracture" section		
ABBREVIATIONS		MEANINGS
dist	=	distal
ER	=	emergency room
fib	=	fibula
frags	=	fragments
fx	=	fracture
L	=	left
lat	=	lateral
mall	=	malleolus
med	=	medial
post	=	posterior
prox	=	proximal
R	=	right
thru	=	through
tib	=	tibia
trans	=	transverse
w/	=	with

Abbreviations used under "Malleolus" descriptions in place of x's		
ABBREVIATIONS		MEANINGS
(bi)	=	bimalleolar
l	=	lateral
lat		lateral
m	=	medial
p	=	posterior
post		posterior
tri. X	=	trimalleolar

Abbreviations used in heading		
ABBREVIATIONS		MEANINGS
L-H	=	Lauge-Hansen
AO	=	Weber/AO classification

Table 3. Summarized Injury Locations Grouped by Injury Mechanism or Movement

External Rotation		Injury Location
1	1CAB	lat mall
2	2GIK	m&p
3	3HAK	m&p
4	3KRB	tib, fib
5	4KWB	tib, fib
6	5MAK	fib
7	6MAK	lat mall
8	8MIK	tri
9	5PEB	tri
10	3PLY	tib, fib
11	7RAB	fib
12	4ROY	tib, fib
13	5TUY	fib
14	11WIK	femur
15	6ORY	fib
16	12SCK	l&p

Bending		Category of bending	Injury location
1	1AQK	impact	tib, fib
2	1KRY	pure bend, valgus strain	tib, fib
3	7MAK	inertial bend	tib, fib
4	2PAY	inertial bend	tri
5	6PUB	inertial bend	tri
6	9SAK	pure bend, inversion of foot	bi, m&l
7	10SCK	inertial bend	bi, m&l
8	8SHB	impact	patella
9	7GRY	pure bend moment, femur	X, femur

Axial		Injury location
1	2ELB	tib, fib
2	4LOK	tib, testicle

Table 4. Results Quantified

Bones	Quantity	% of total
med	0	-
lat	2	7.4
post	2	7.4
med & post	2	7.4
lat & post	1	3.7
med & lat	1	3.7
tri	4	14.8
tibia	11	40.7
fibula	15	55.6
femur	2	7.4

Movement / Mechanism	Quantity	% of total
external rotation	16.0	59.3
impact	2.0	7.4
pure bend	3.0	11.1
inert bend	4.0	14.8
axial	2.0	7.4

Malleolar fx's	Quantity	% type mall
singular mall	4	33.3
bi mall	4	33.3
tri mall	4	33.3
total mall	12	

Fx's of ankle	Quantity	% ankle fx
# external rotation	10.0	71.4
# inert bend	3.0	21.4
# pure bend (inversion)	1.0	7.1
total	14	

Figure 1. 1. Survey of CPSC/NEISS Injury Comment Data

Survey of CPSC/NEISS Injury Comment Data

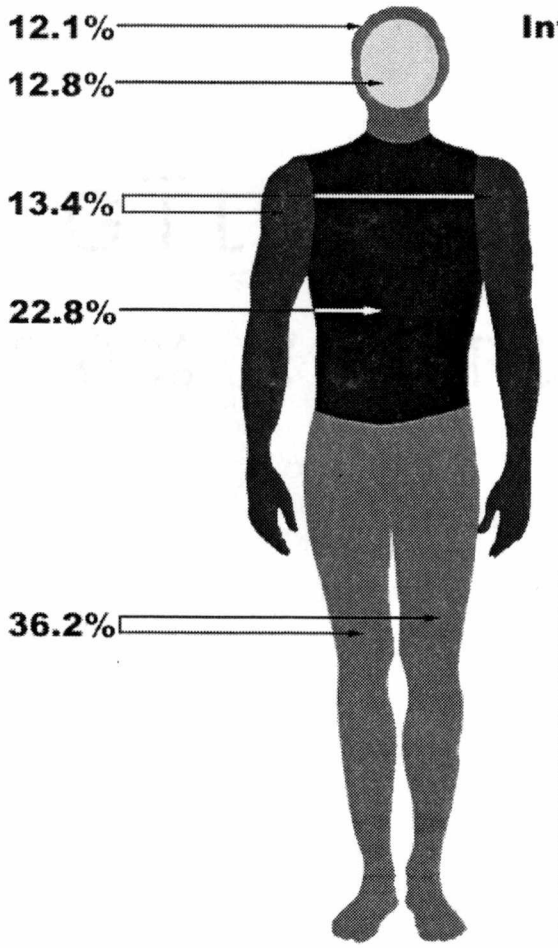

Leg Injury Detail

Contusion	16.7%
Laceration	38.9%
Fracture	7.4%
Toe/Nail	7.4%
Sprain/Twist*	22.2%
Unknown Injury	16.7%

Source: 1989 - 1992 PWC Report Injuries

* Includes 12 Records
(1-tubing, 1-canoe, 1-pontoon, 1-dock/tree)

Figure 1.2. Survey of injury location

Survey of Injury Location

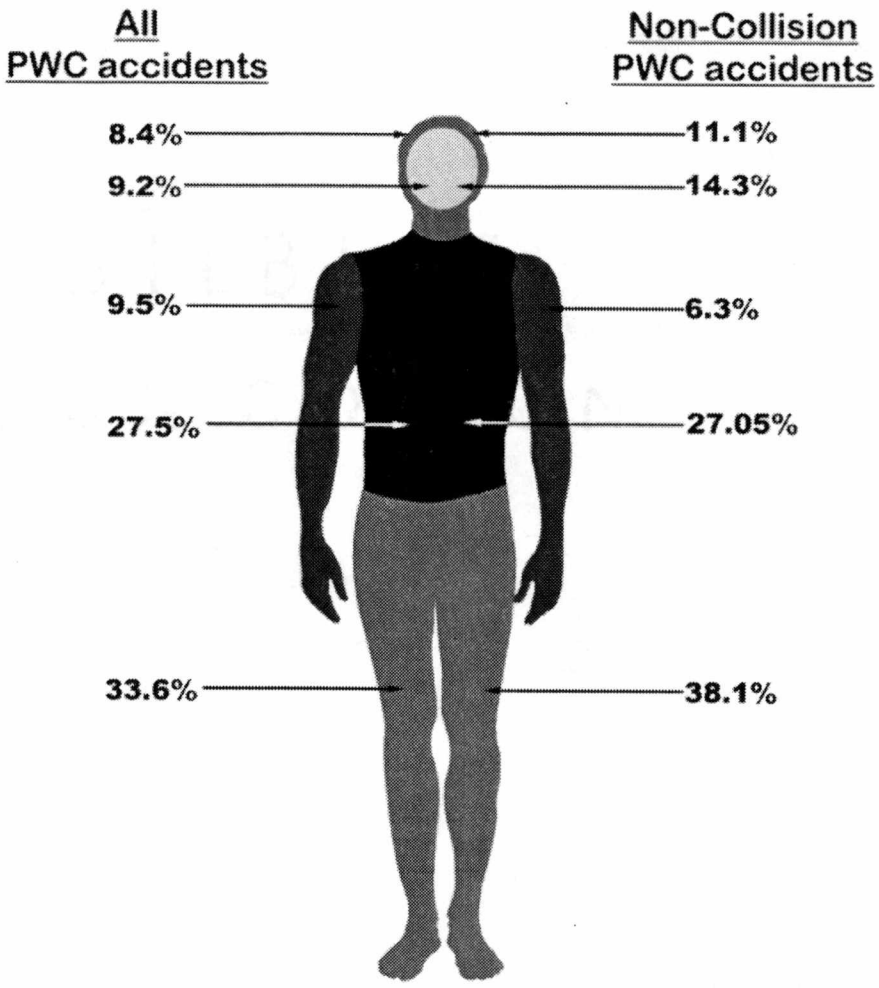

Source: 1996 NJ PWC Accident Reports

Figure 1.3. 1998 NTSB Injury Data

1998 NTSB Injury Data

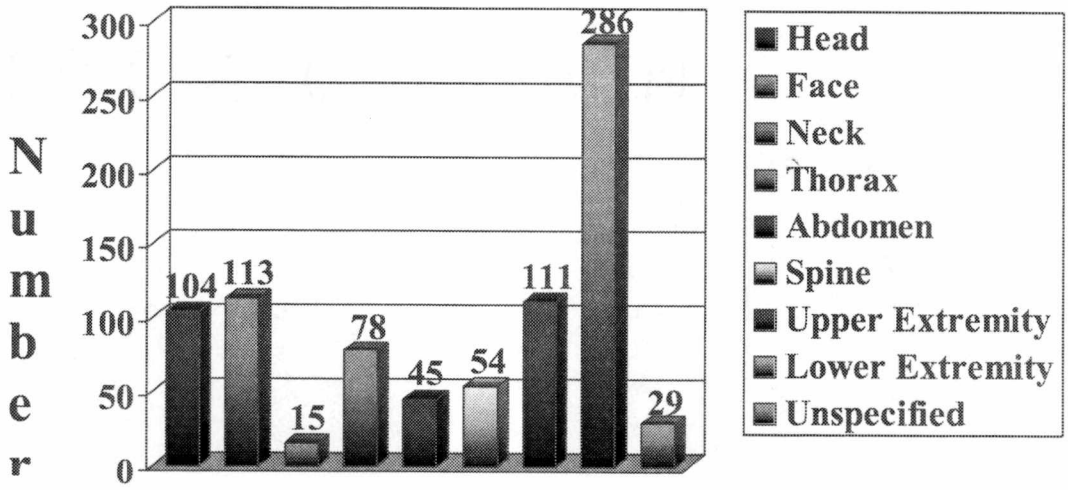

Figure 2.1. Bone Basics of the Lower Leg

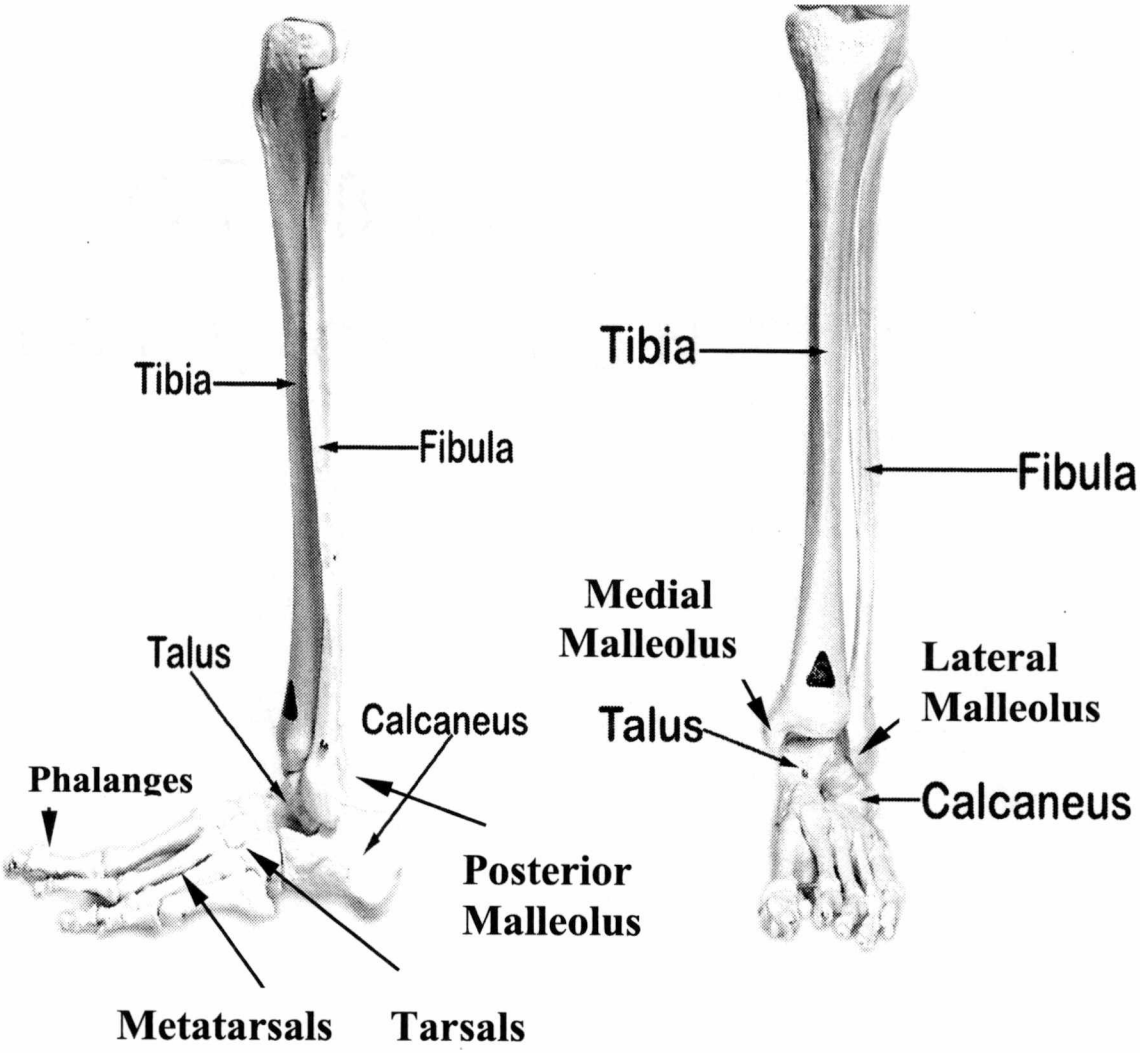
Tibia
Fibula
Talus
Calcaneus
Phalanges
Posterior
Malleolus
Metatarsals
Tarsals
Tibia
Fibula
Medial
Malleolus
Lateral
Malleolus
Talus
Calcaneus

Figure 2.2. Ligaments as Seen from the Posterior of the Right Ankle

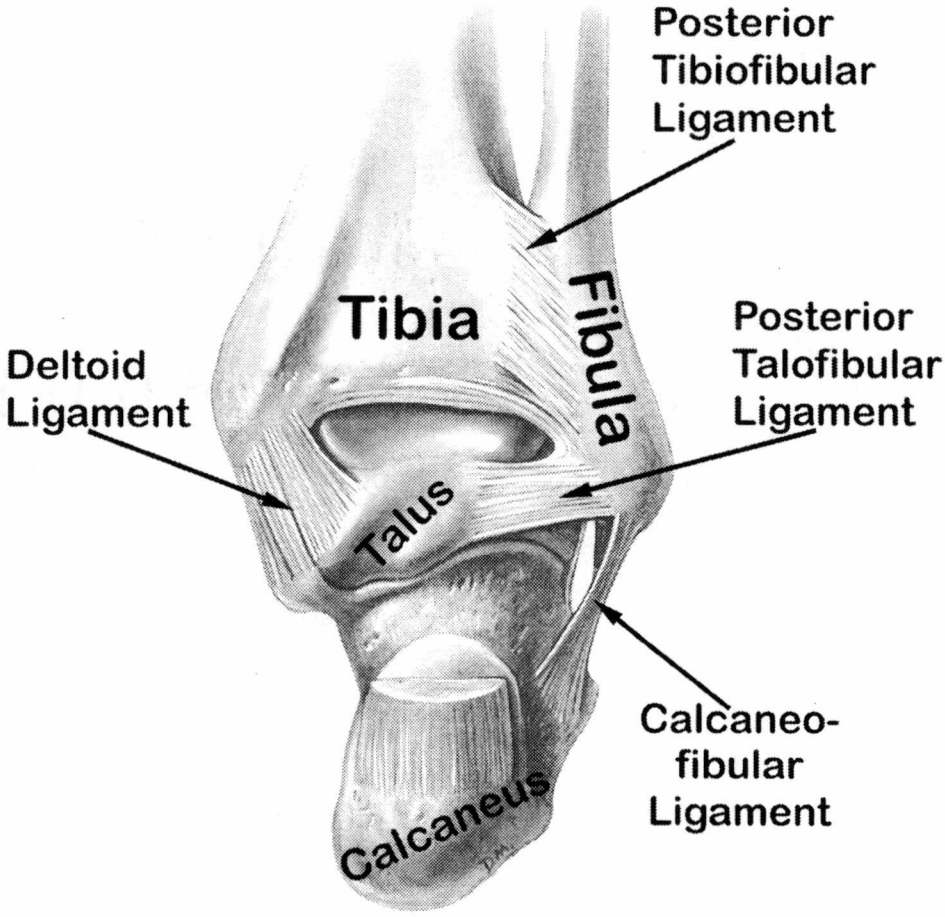
Posterior
Tibiofibular
Ligament
Tibia
Fibula
Deltoid
Ligament
Posterior
Talofibular
Ligament
Talus
Calcaneo-
fibular
Ligament
Calcaneus

Figure 2.3. Terminology Summary of Motions Resulting in Ligament Damage

A. Eversion

B. Abduction

C. Inversion

D. Axial

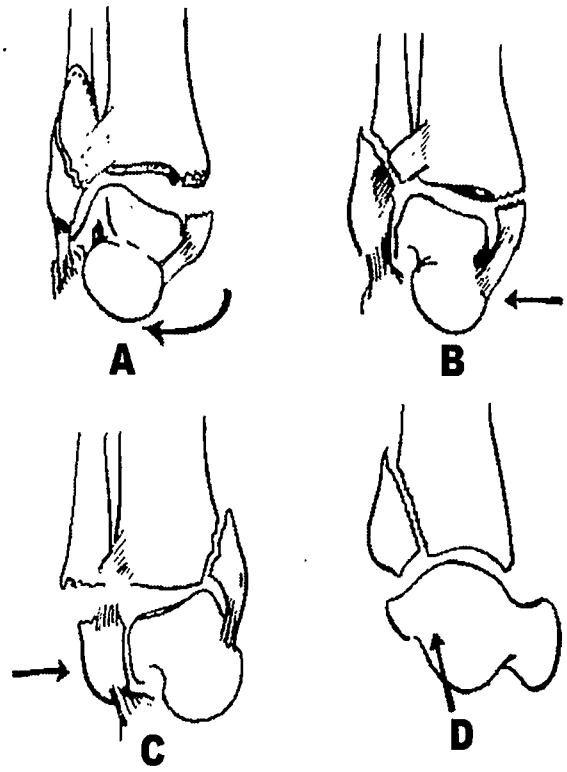

Posterior view of the left Ankle

Figure 2.4. Fracture types

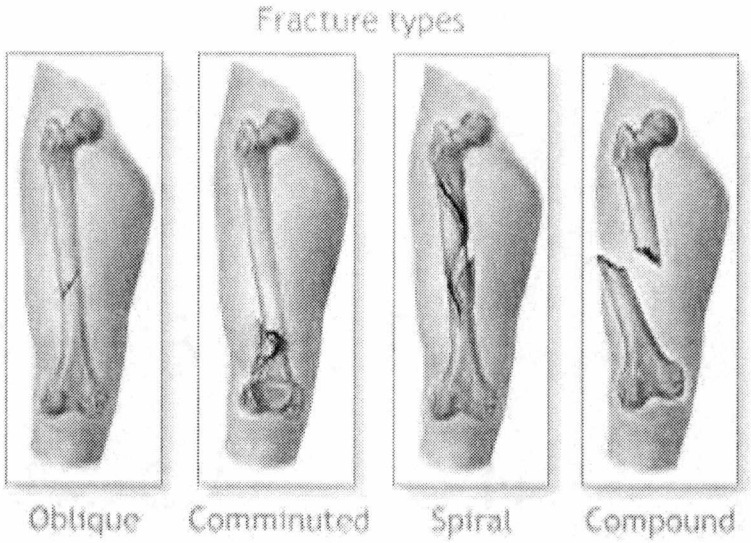

adam.com

Figure 2.5. Pronation and Supination as Seen from the Posterior of the Right Ankle

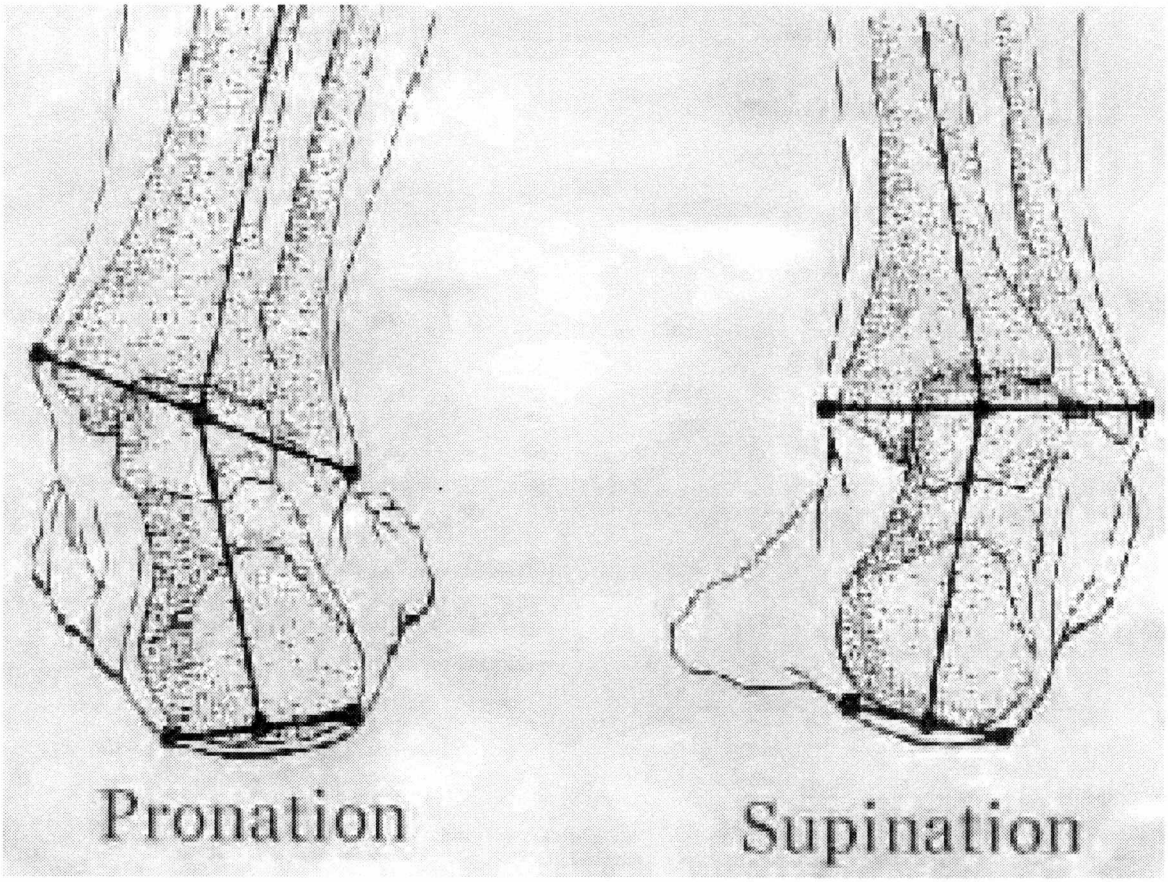
Pronation
Supination

Figure 3.1. X-rays from file 1AQK.

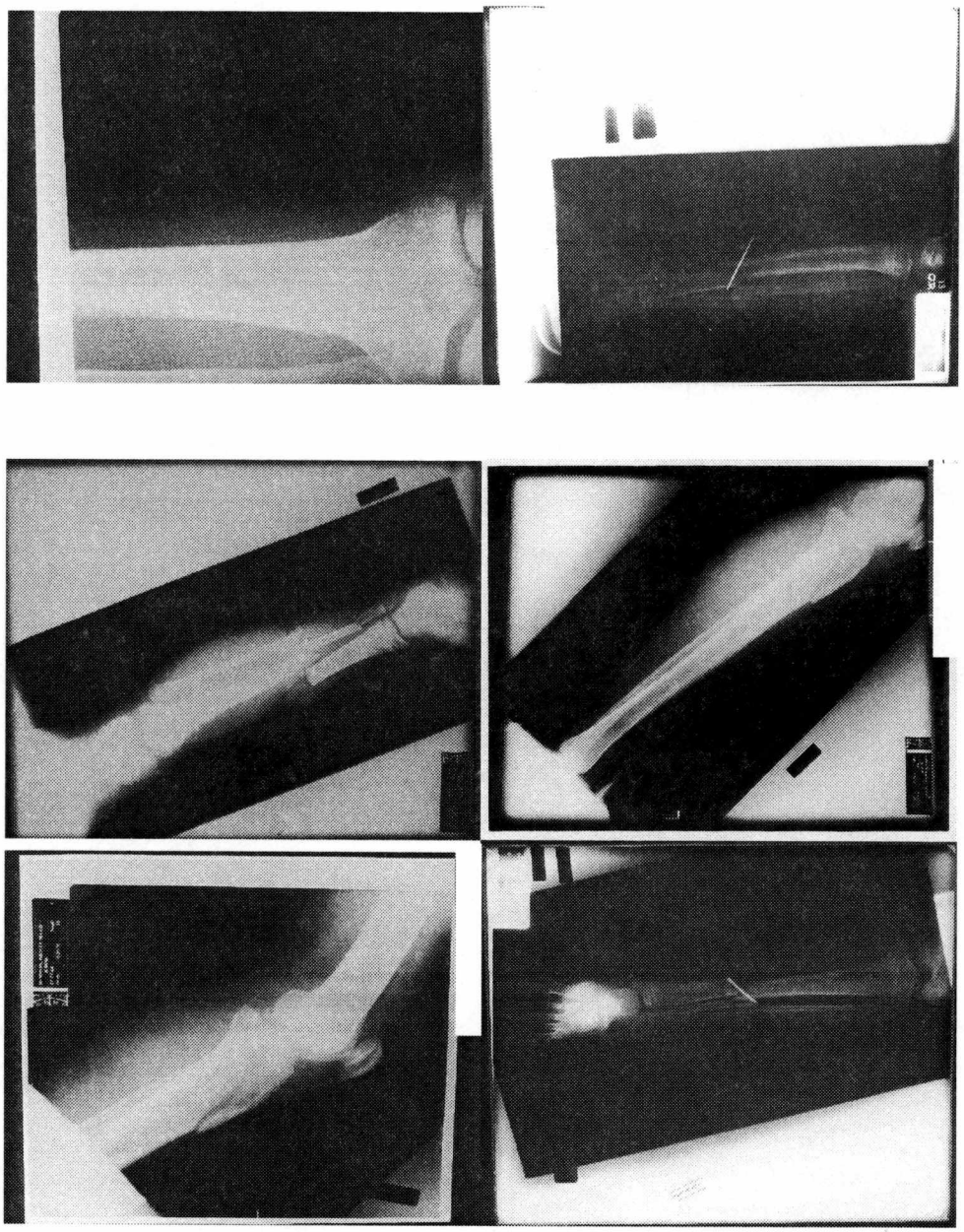

Figure 3.2. X-rays from file 1CAB.

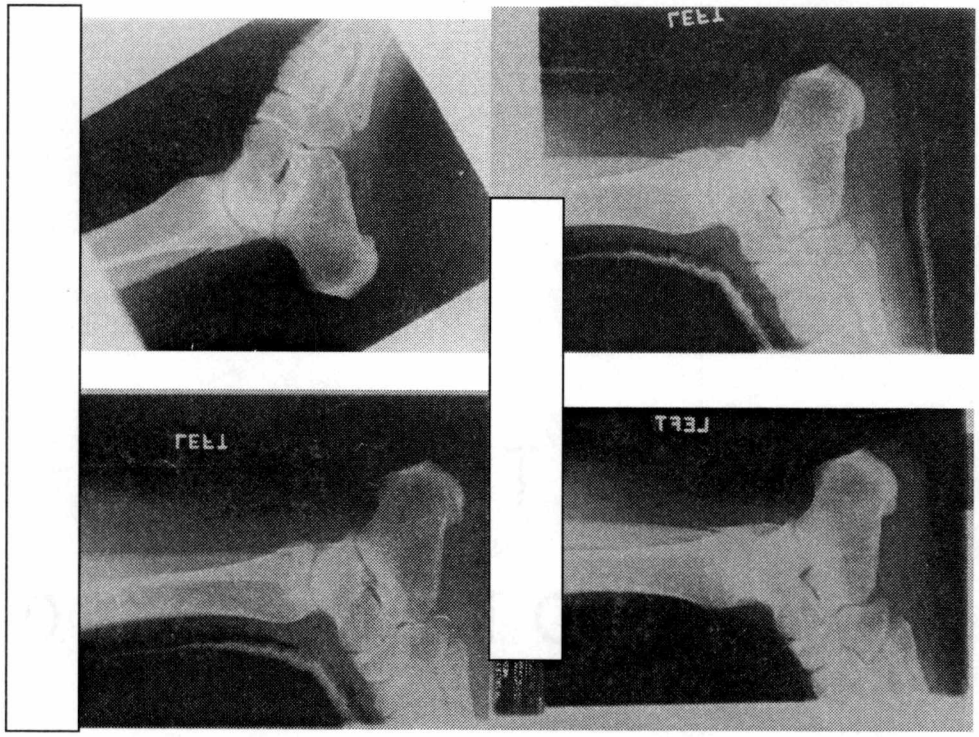
LEFT
LEFT
LEFT
LEFT

Figure 3.3. X-rays from file 2ELB.

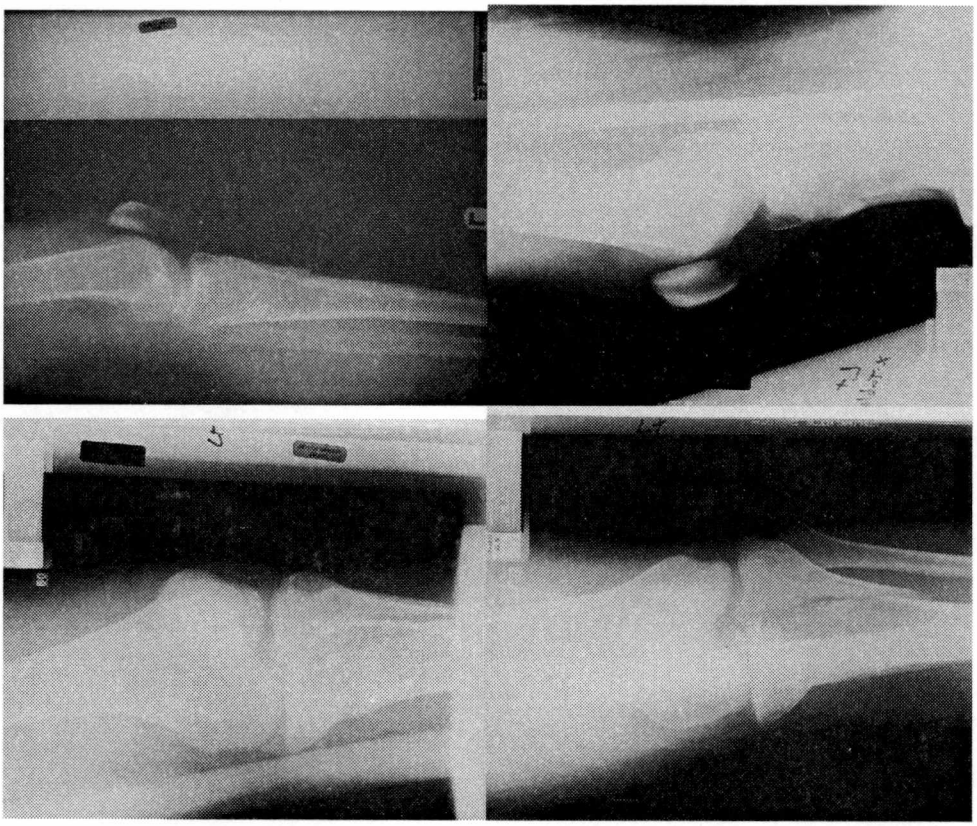

Figure 3.4.A. X-rays from file 2GIK.

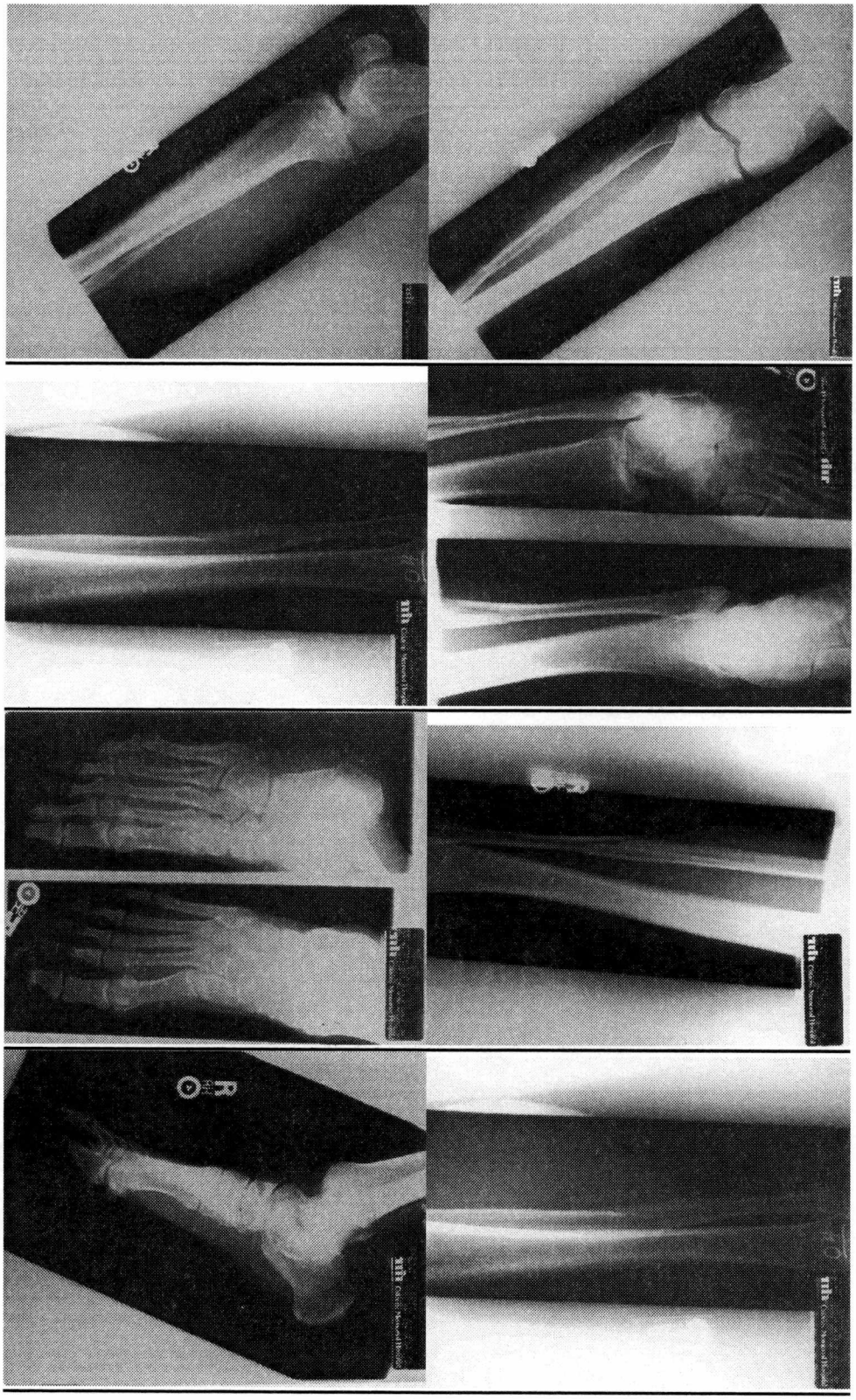

Figure 3.4.B. More x-rays from file 2GIK.

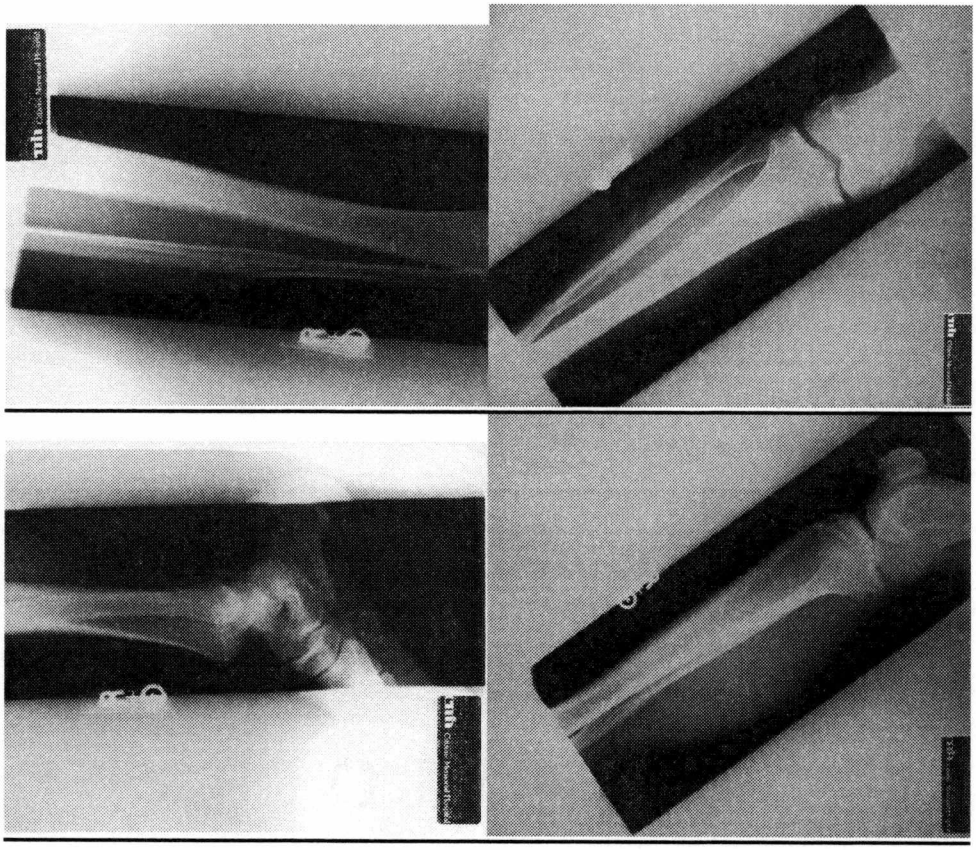

Figure 3.5. X-rays from file 3HAK.

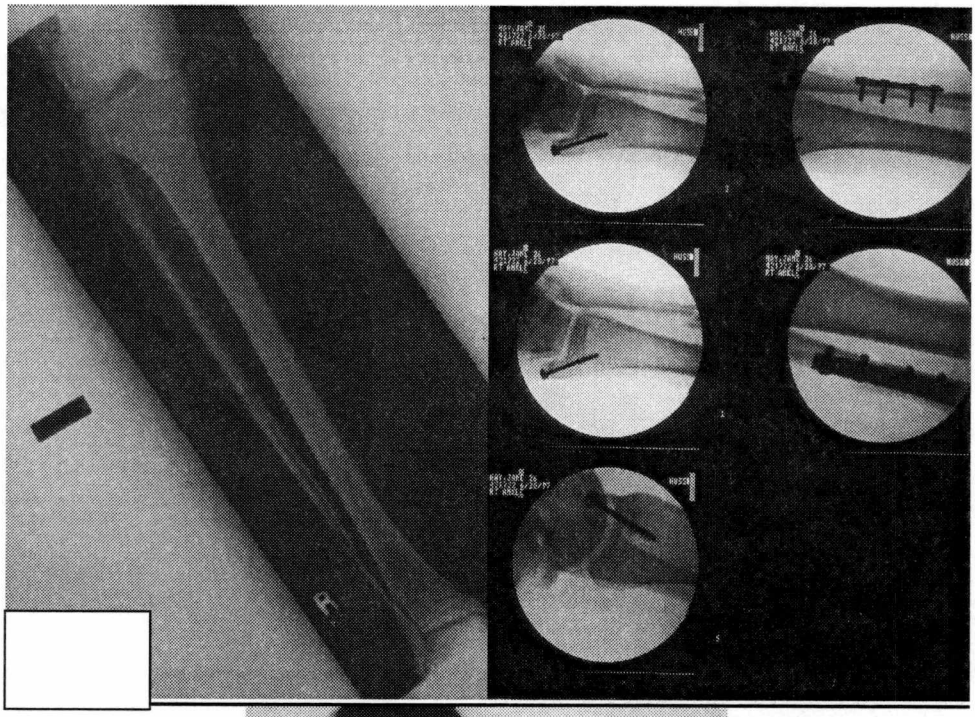

Figure 3.6. X-rays from file 1KRY.

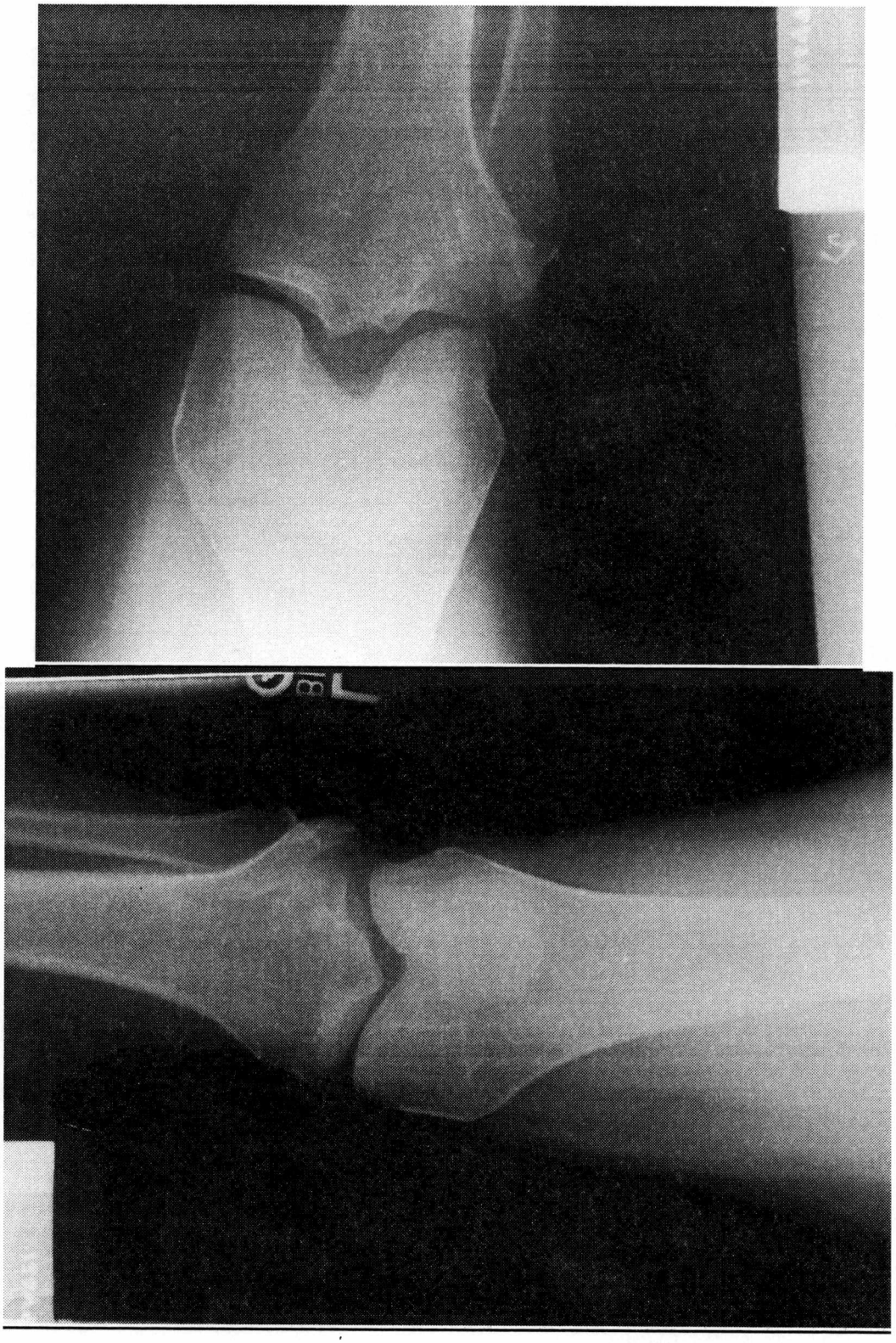

Figure 3.7. X-rays from file 3KRB.

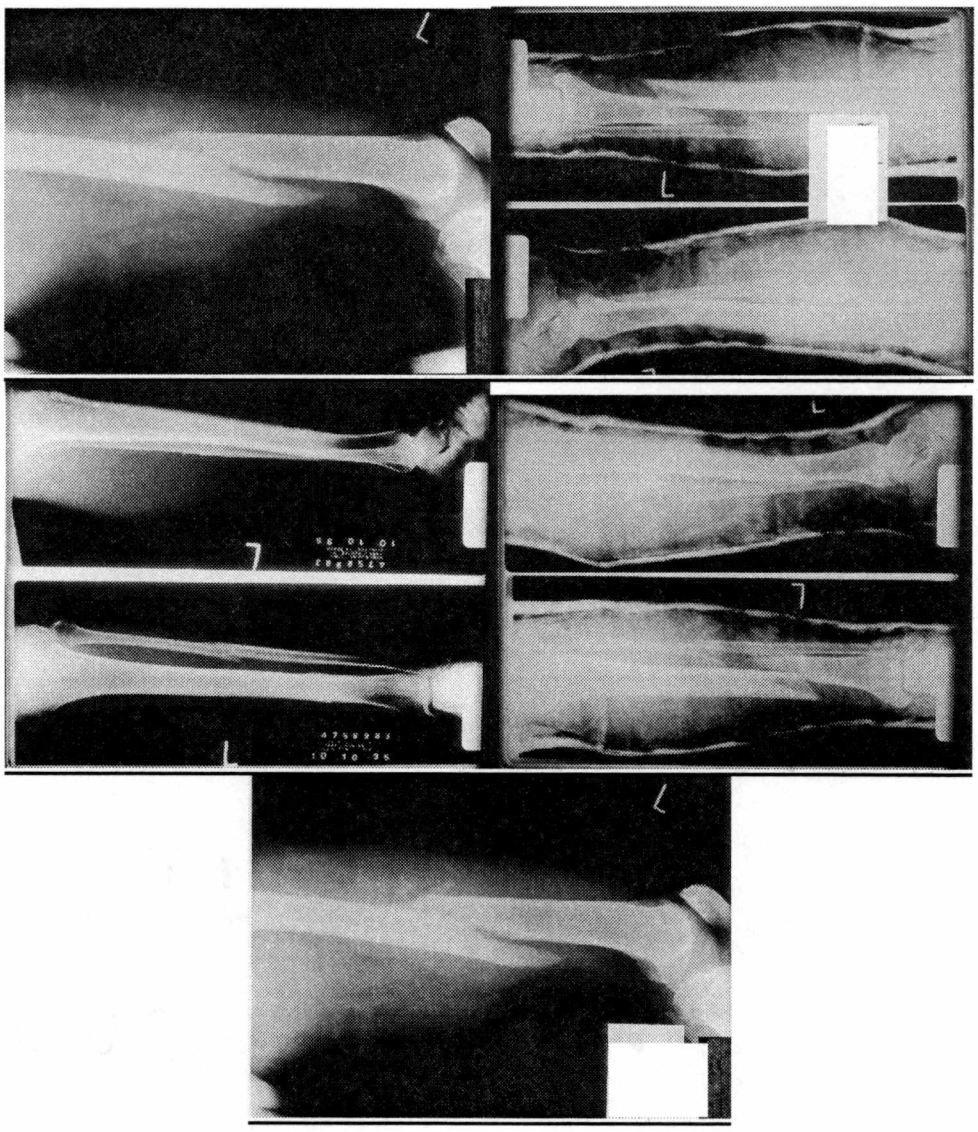

Figure 3.8. X-rays from file 4KWB.

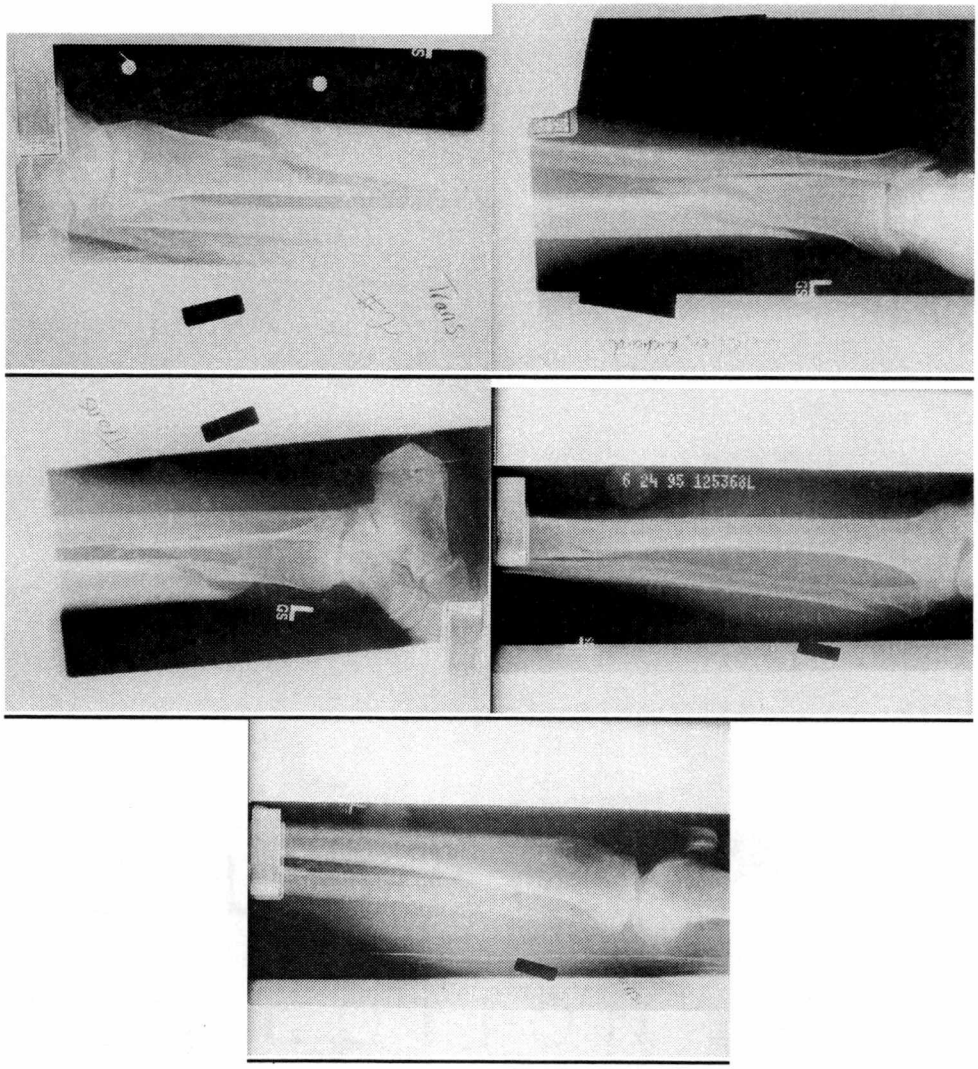
6 24 95 125368L

Figure 3.9. X-rays from file 4LOK.

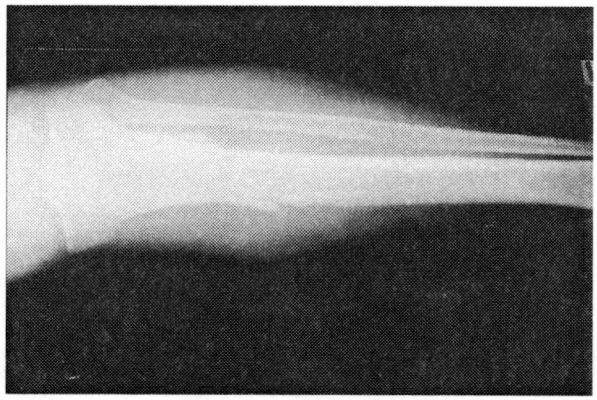

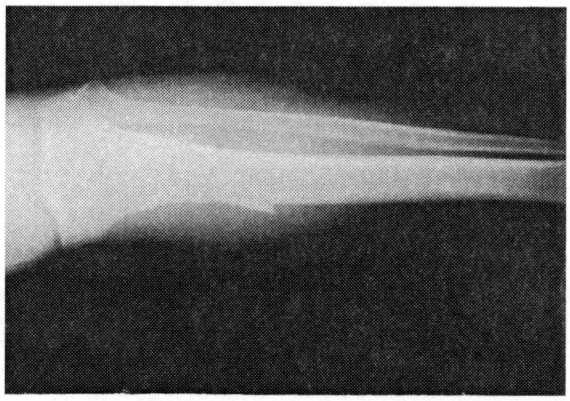

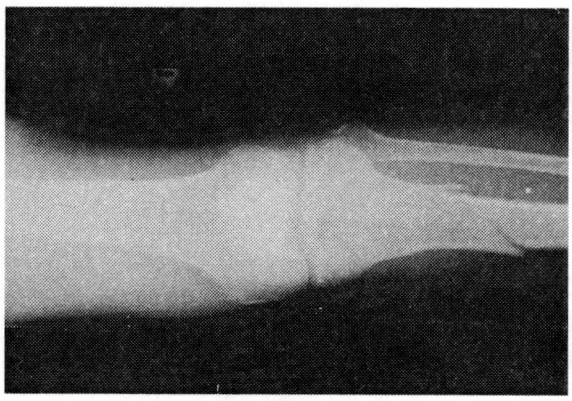

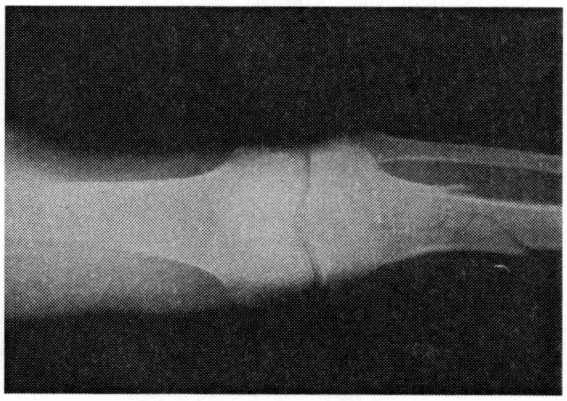





Figure 3.10. X-rays from file 5MAK.

R

Figure 3.11. X-rays from file 6MAK.

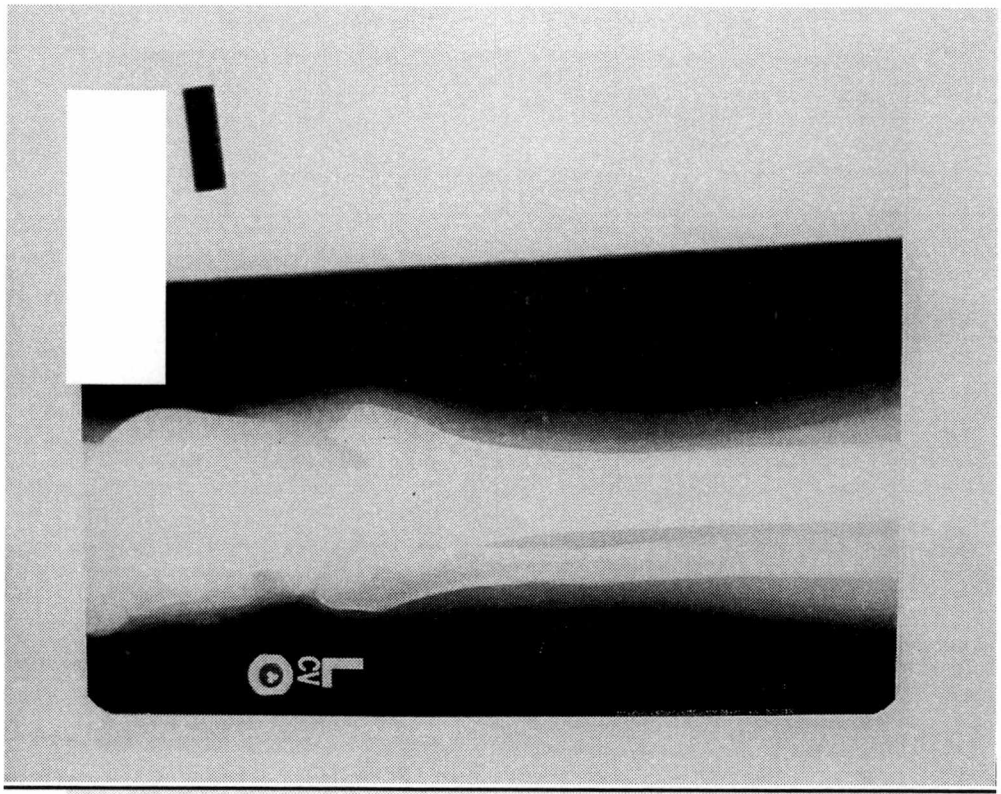

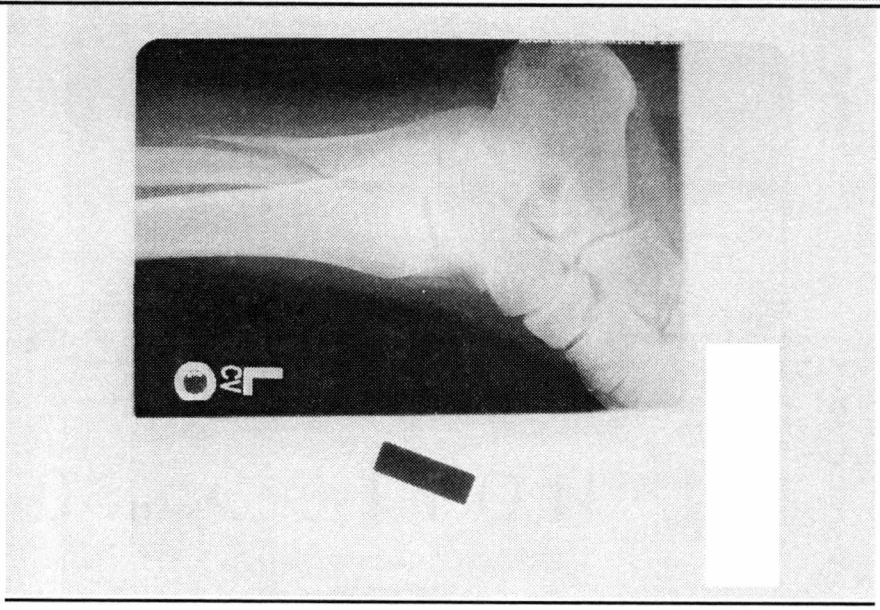

Figure 3.12. X-rays from file 7MAK.

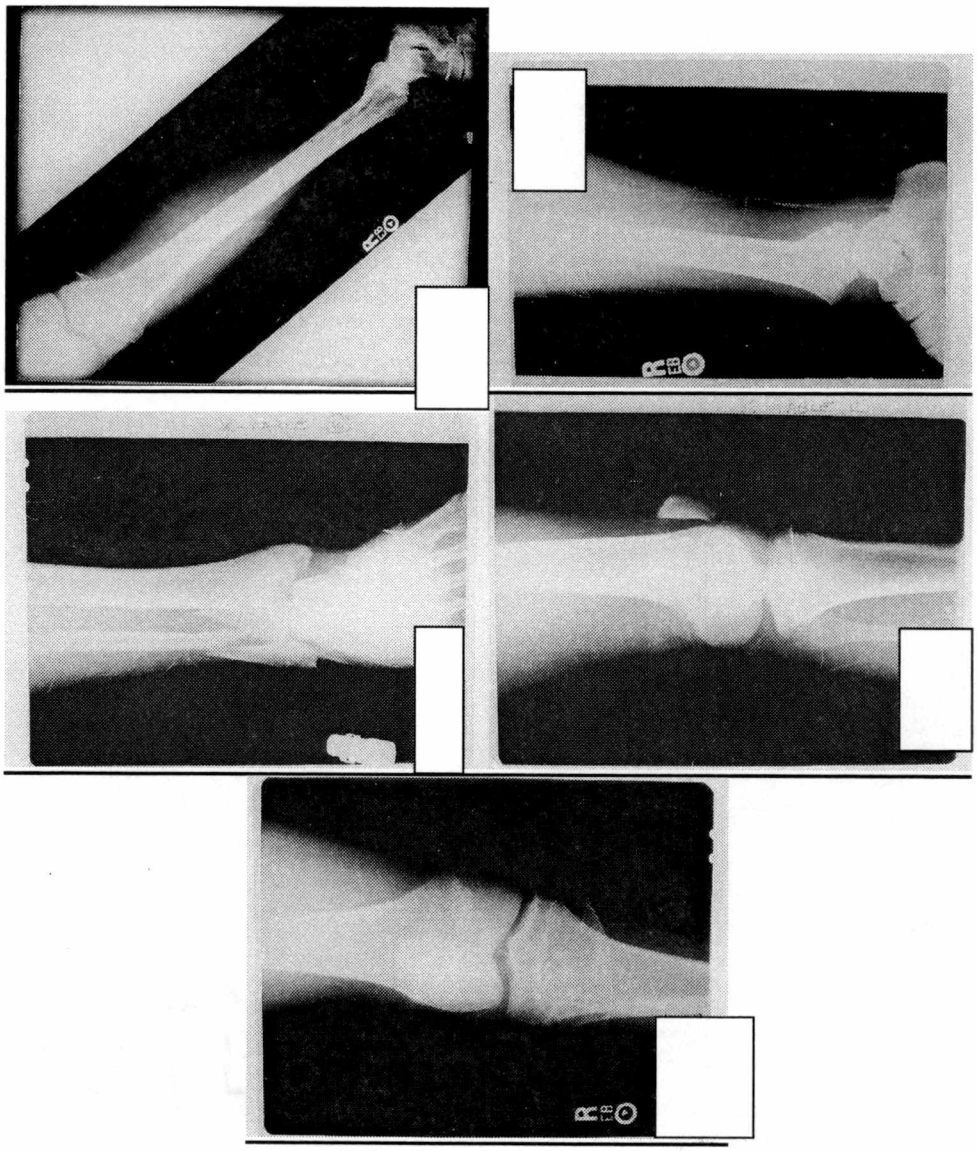

Figure 3.13. X-rays from file 8MIK.

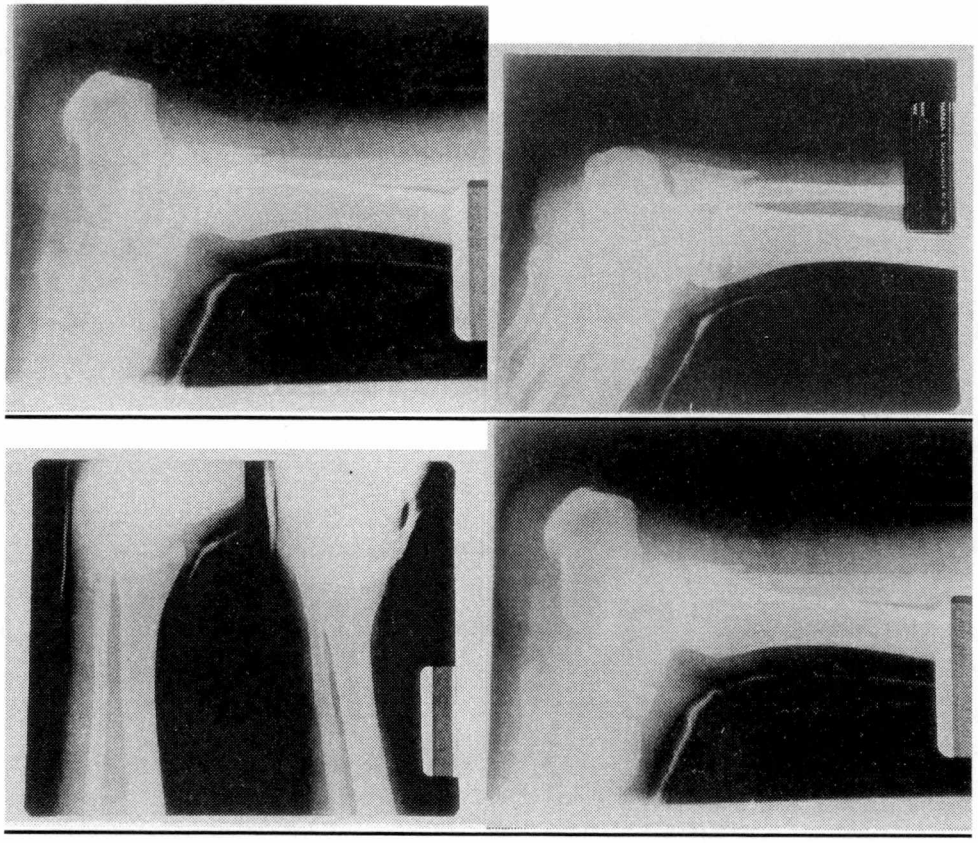

Figure 3.14. X-rays from file 2PAY.

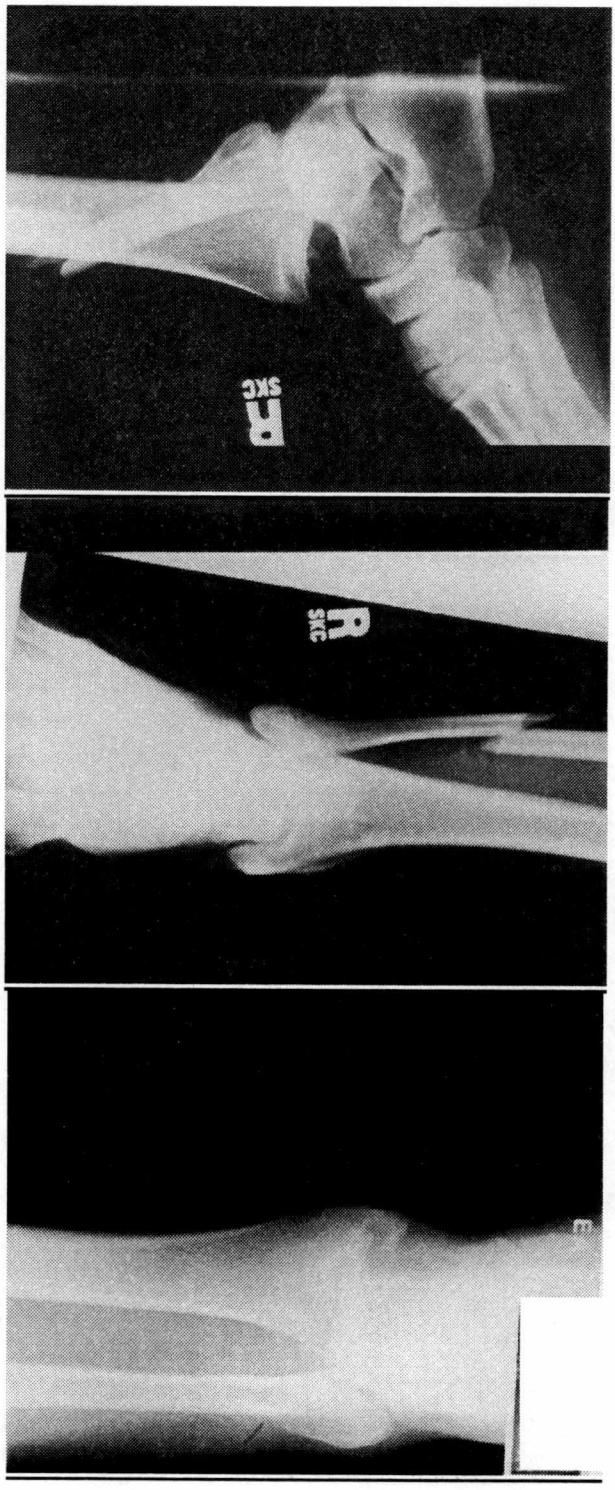
R
SKC
R
SKC

Figure 3.15. X-rays from file 5PEB.

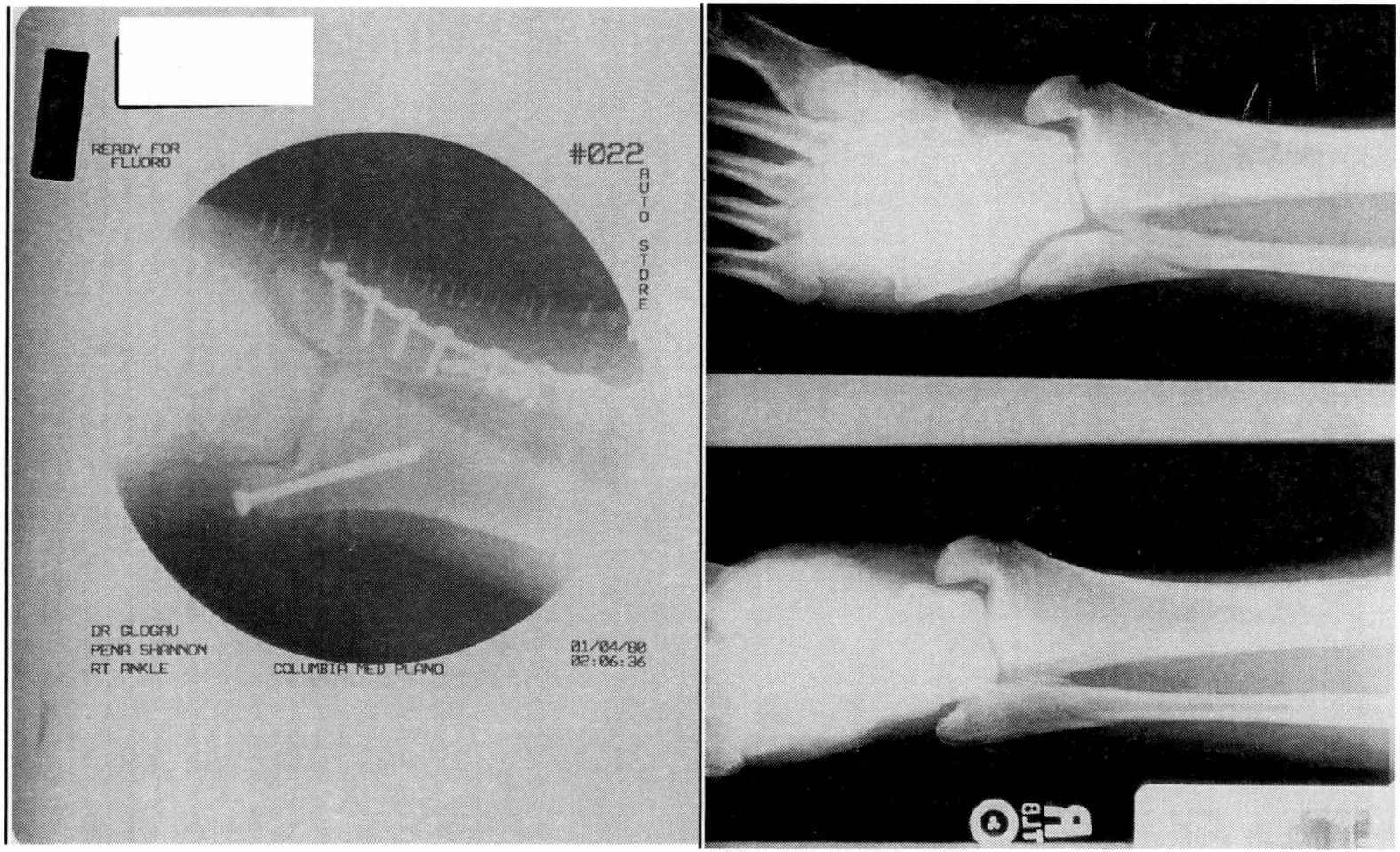
READY FOR
FLUORO
#022
AUTO
SIDRE
DR GLOGAU
PENA SHANNON
RT ANKLE
COLUMBIA MED PLAND
01/04/00
02:06:36

Figure 3.16. X-rays from file 3PLY.

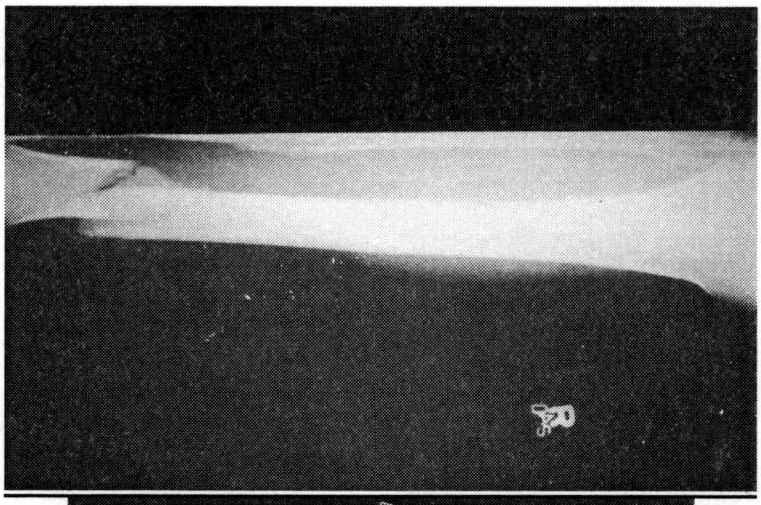

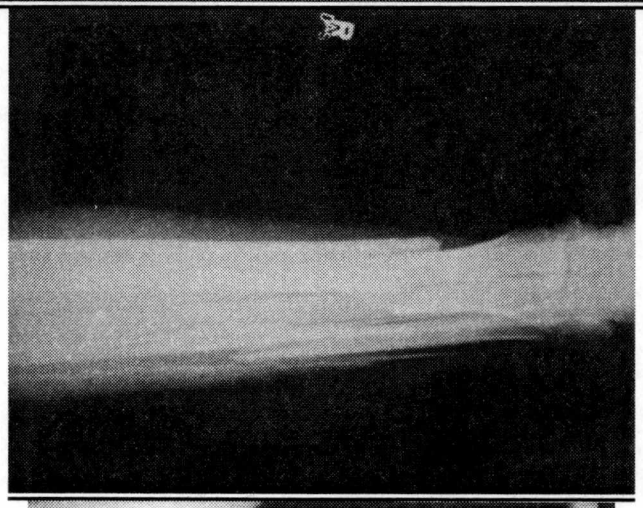

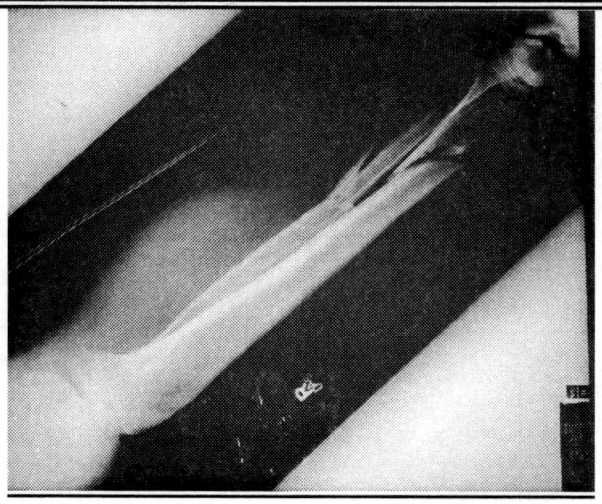

Figure 3.17. X-rays from file 6PUB.

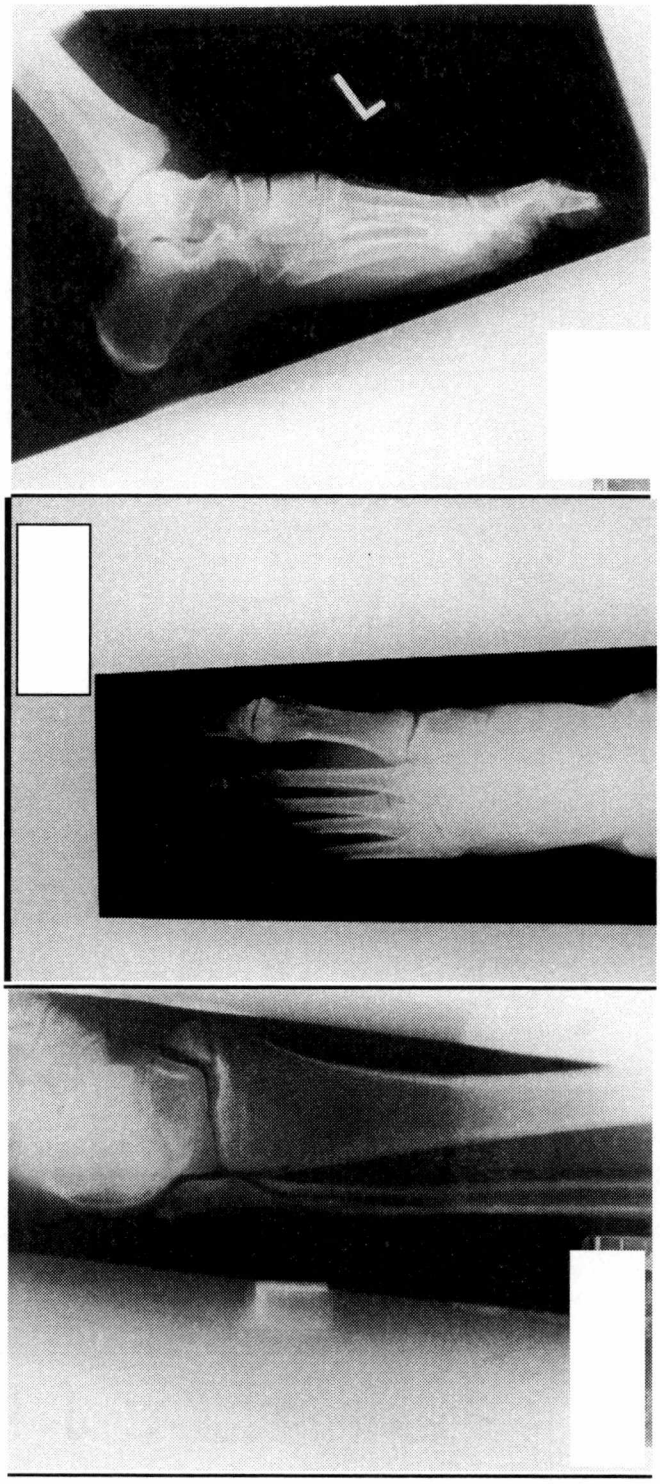
L

Figure 3.18. X-rays from file 7RAB.

L
DF
8 1 2 95
L
DF
8 1 2 95
a
L
DF
8 1 2 95
a se ae

Figure 3.19. X-rays from file 4ROY.

Figure 3.20. X-rays from file 9SAK.

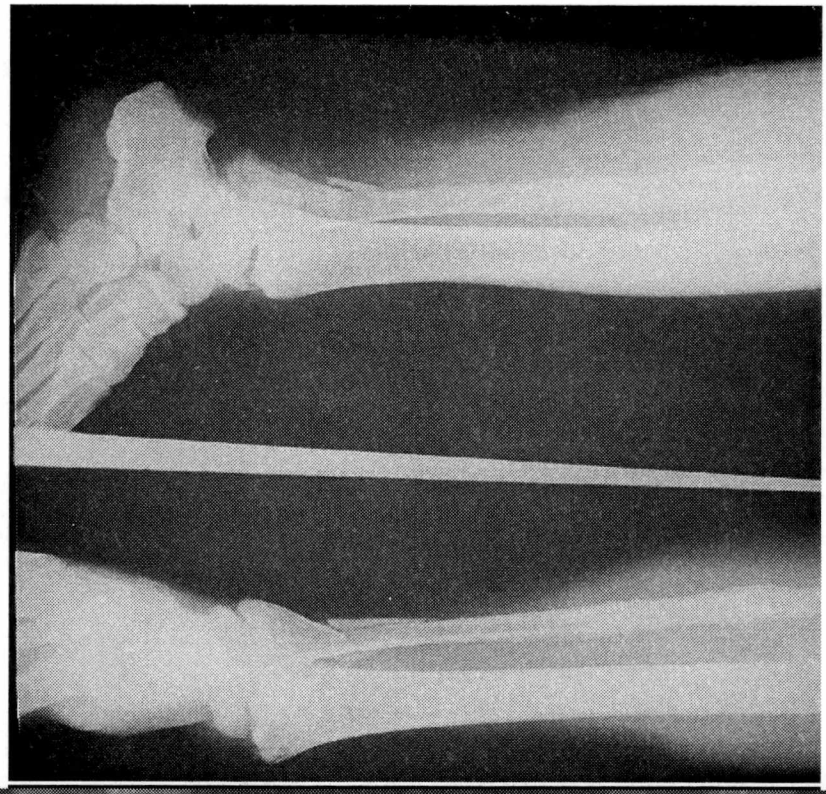

Figure 3.21. X-rays from file 10SCK.

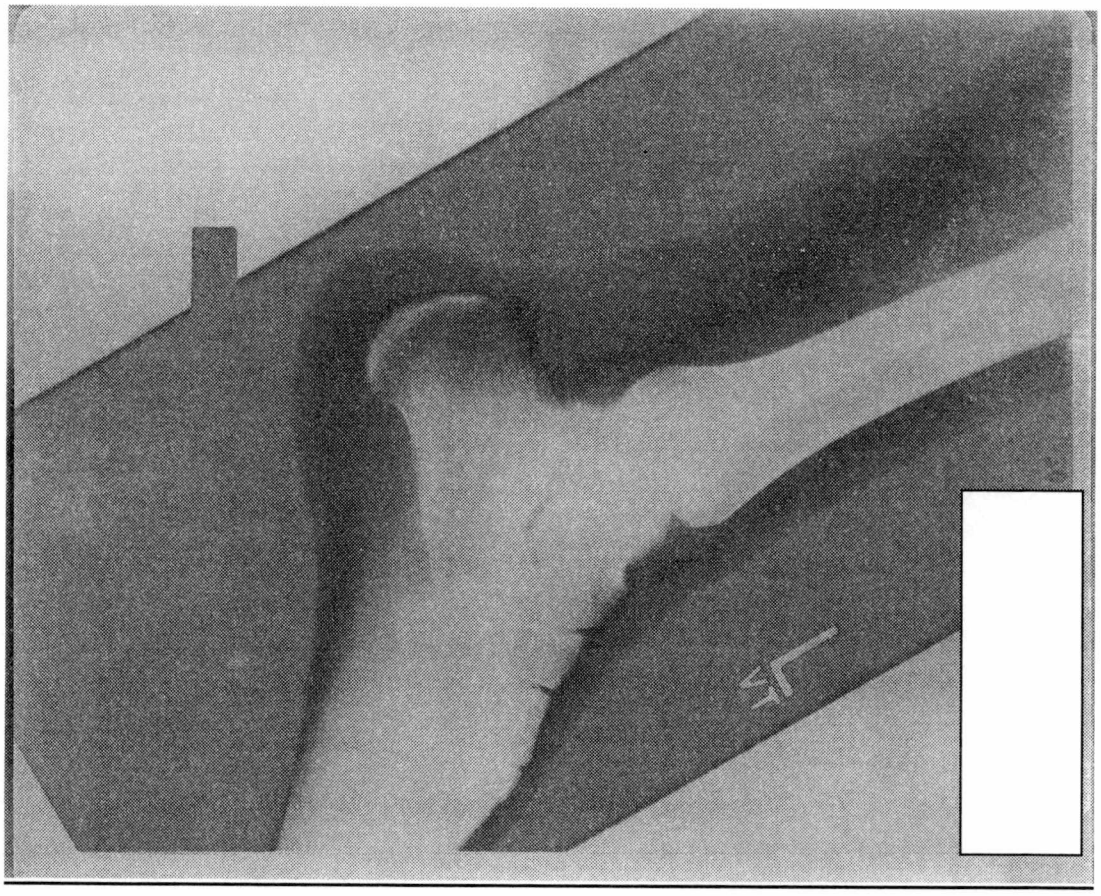

Figure 3.22. X-rays from file 8SHB.

Figure 3.23. X-rays from file 5TUY.

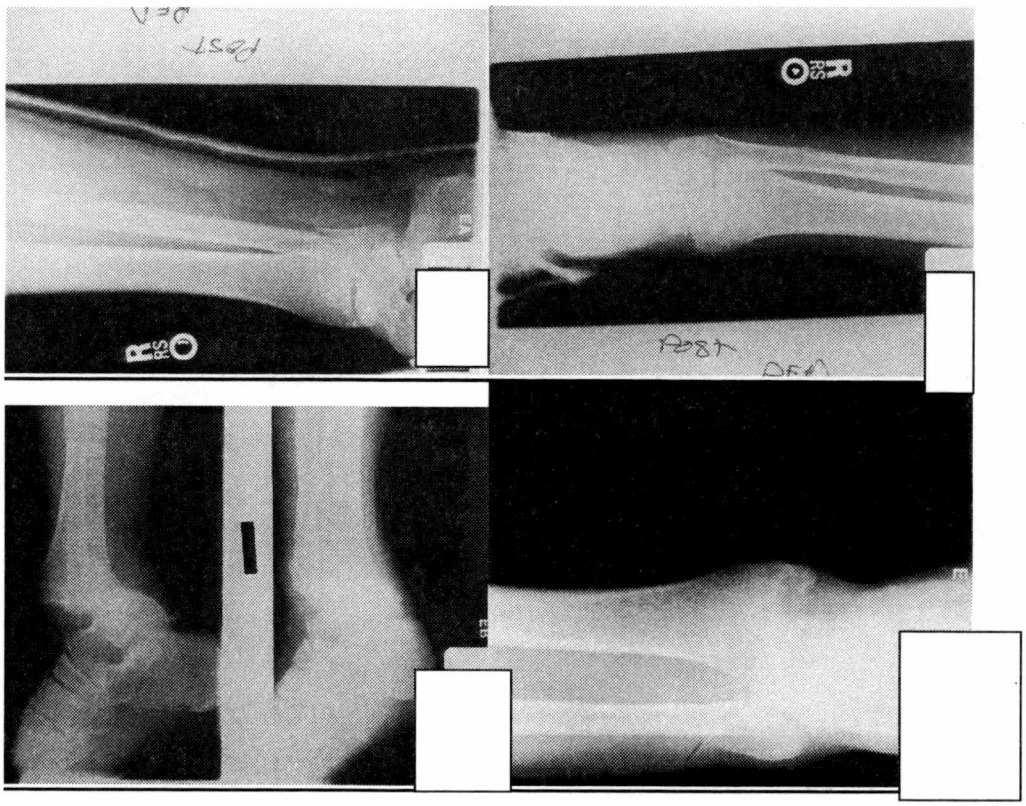
POST
DEF
POST
DEF

Figure 3.24. X-rays from file 11WIK.

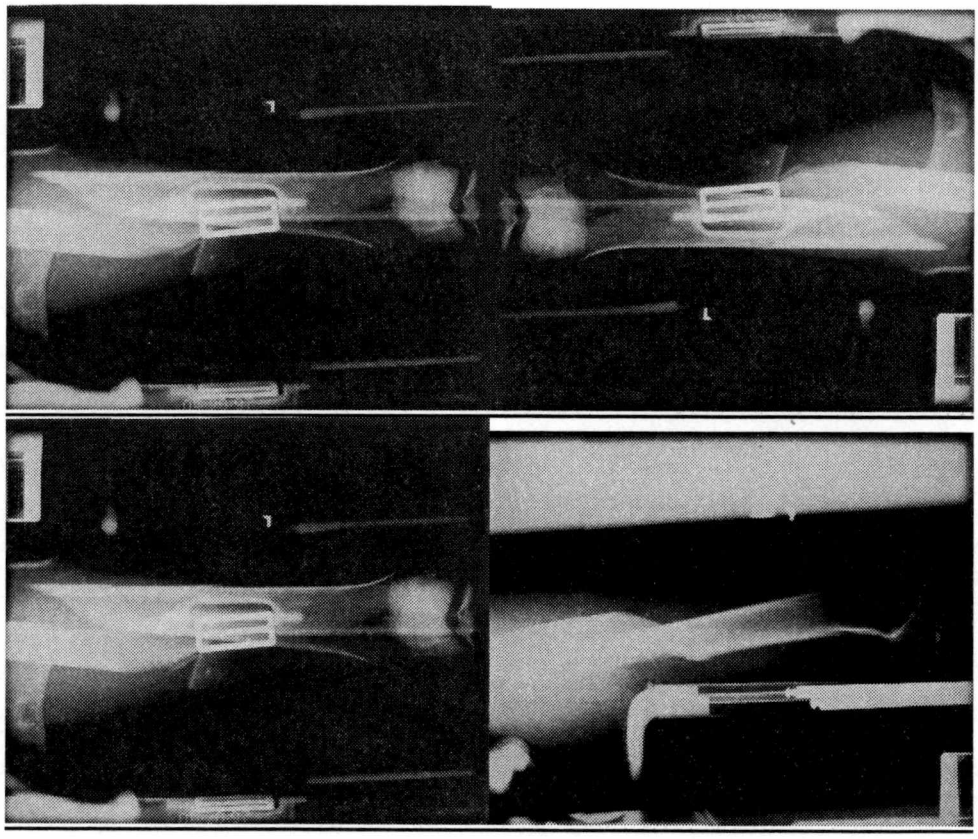

Figure 4.0. James Galyon, M.D. Curriculum Vitae

CURRICULUM VITAE

NAME:	James Theodore Galyon, M. D.
BIRTHDATE:	April 13, 1930
BIRTHPLACE:	Knoxville, Tennessee
SOCIAL SECURITY:	408-44-7770
MARITAL STATUS:	Married – Virginia D. Galyon, M. D.
EDUCATION:	
High School:	Knox County Central, Knox County, TN., 1948
Undergraduate:	University of Tennessee College of Medicine, Knoxville, TN., 1948 – 1950, BS - 1950
Medical School:	University of Tennessee College of Medicine Memphis, TN., 1950–1953, M. D. - 1953
Internship:	Richland County Hospital, Columbia, SC Jan. 1954-Dec 1954
Residency:	General Surgery, Kennedy General Hospital, Memphis, TN., June 1957 – June 1958
	Orthopaedic Surgery, Kennedy General Hospital Memphis, TN., July 1958 – December 1959
	Orthopaedic Surgery, Arkansas Children's Hospital, Little Rock, Ark., January 1960 – December 1960
	Orthopaedic Surgery, University of Arkansas Medical Center, Little Rock, Arkansas, January 1961 – June 1961

MILITARY:	June 1955 – June 1957. Medical Corps. U. S. Army Orthopaedic ServiceGermany
MEDICAL LICENSURE:	Tennessee – 2000 - February, 1954 Arkansas - R1634 August, 1961 (Current)
SOCIETY MEMBERSHIPS:	Memphis and Shelby County Medical Society American Academy of Orthopaedic Surgery American Medical Association Tennessee Medical Association Mid- American Orthopaedic Association
HOSPITAL APPOINTMENTS:	St. Francis Hospital -- Active Staff Methodist Hospital -- Courtesy Staff Baptist Hospital -- Courtesy Staff City of Memphis Hospital -- Active Staff
UNIVERSITY APPOINTMENTS	Clinical assistant, Orthopaedic Surgery, UTCHS, November, 1964 Clinical Instructor, Orthopaedic Surgery, UTCHS, 1967 Clinical Assistant Professor, Orthopaedic Surgery, UTCHS, July, 1973
BOARD CERTIFICATION:	American Board of Orthopaedic Surgery January 1964
PUBLICATIONS:	Journal of TMA – Volume II – Nov. 1993 "Enterprise Liability"
LECTURES:	UT – St. Francis Update '93 Pediatric Office Orthopaedics Orthopaedic Nurse Association Intraoperative Cost Containment UT – St. Francis Update '95 Managed Care Risk Management SVMIC – Loss Prevention Seminar August 1995. 1996, 1997, 1998

COMMITTEES AND OFFICES HELD:

Memphis and Shelby County Medical Society:

U.T. Liason Committee, 1977 - 1978
Membership Committee, 1978
Executive Committee
President, 1980 - 1981
Long Range Planning Committee – Current
Membership Services Committee – Current
Contract Review Committee - Current

Tennessee Medical Association

TMA Board, 1980, 1981, 1982
Chairman of the Board, 1982
President, 1987
TMA Foundation – Board of Directors
TMA Med – Religion Committee – Chairman – 1995 - 1996

St. Francis Hospital

Constitution and By – Laws Committee, 1978 to present – Chairman
Department of Orthopaedics, 1978 - Charman
President of Staff, 1976
Infection Control Committee, 1985 to date.
Clinical Studies Committee, 1985 to date
Representative to AMA Hospital Medical Staff Section, 1984, 1985, 1986
Clinical Studies Comittee
Quality Committee
Education and CME Committee
St. Francis Hospital – Chairman of the Board – 1994 to present

St. Joseph Hospital

President of Staff, 1971

PRACTICE (PROFESSIONAL) EXPERIENCE

Private Practice, Everts, Kentucky, Jan. 1955 to June 1955
Private Practice, Memphis, Tennessee, 1961 to present

CIVIC AND NON-MEDICAL

Elder, Second Presbyterian Church
Served on Medical Advisory Board, St. Peter Villa
Served on Board of Trustees, Presbyterian Services
Tennessee Board For Licensing Health Care Facilities, 1986 to date
Served on Memphis Coalition For Health Care, 1981 to present
SVMIC – Board of Directors
SVMIC – Risk Identification Committee
SVMIC – Underwriting Committee – Vice Chairman
Compensation Committee - Chairman

Figure 5.0 AO Ankle Fracture Classification System Taken
Directly from "Pocketbook of Orthopaedics
and Fractures", by Ronald McRae,
Published by Churchill Livingstone
in 1999

The AO classification

It follows the lines of the Weber classification (it is sometimes referred to as the AO Weber classification), but takes into account damage to other structures. The groups within each type tend to follow the Pott's classification.

(44-)A1 = Isolated infrasyndesmotic injuries
- A1.1 = rupture of the lateral ligament
- A1.2 = avulsion at the tip of the lateral malleolus
- A1.3 = transverse fracture of the lateral malleolus.

(44-)A2 = Infrasyndesmotic lesion with a fracture of the medial malleolus
- A2.1 = rupture of the lateral ligament
- A2.2 = avulsion of the tip of the lateral malleolus
- A2.3 = transverse fracture of the lateral malleolus.

(44-)A3 = Infrasyndesmotic lesion with a posteromedial fracture
- A3.1 = rupture of the lateral ligament
- A3.2 = with avulsion of the tip of the lateral malleolus
- A3.3 = with transverse fracture of the lateral malleolus.

(44-)B1 = Isolated trans-syndesmotic fibular fractures
- B1.1 = non-comminuted
- B1.2 = with rupture of the anterior syndesmosis
- B1.3 = comminuted (multifragmentary).

(44-)B2 = Trans-syndesmotic fibular fracture with a medial lesion
- B2.1 = non-comminuted, with rupture of the medial ligament and of the anterior syndesmosis
- B2.2 = non-comminuted, with fracture of the medial malleolus and rupture of the anterior syndesmosis
- B2.3 = comminuted (multifragmentary) fibular fracture.

(44-)B3 = Trans-syndesmotic fibular fracture, with medial lesion and posterior malleolar fracture
- B3.1 = non-comminuted fracture of fibula with rupture medial ligament
- B3.2 = non-comminuted fracture of the fibula with fracture of the medial malleolus (illustrated in two planes with Tillaux fracture)
- B3.3 = comminuted (multifragmentary) fracture of the lateral malleolus with fracture of the medial malleolus.

(44-)C1 = Suprasyndesmotic lesion, with non-comminuted fracture of the fibular shaft
- C1.1 = with rupture of the medial collateral ligament
- C1.2 = with fracture of the medial malleolus
- C1.3 = with fracture of the medial and posterior malleoli.

(44-)C2 = Suprasyndesmotic lesion with comminuted fracture of the fibular shaft
- C2.1 = with rupture of the medial ligament
- C2.2 = with fracture of the medial malleolus
- C2.3 = with fracture of the medial and posterior malleoli.

(44-)C3 = Proximal fibular supra-syndesmotic fracture
- C3.1 = without shortening or a posterior malleolar fracture
- C3.2 = with shortening, but no posterior malleolar fracture
- C3.3 = with medial lesion and a posterior malleolar fracture

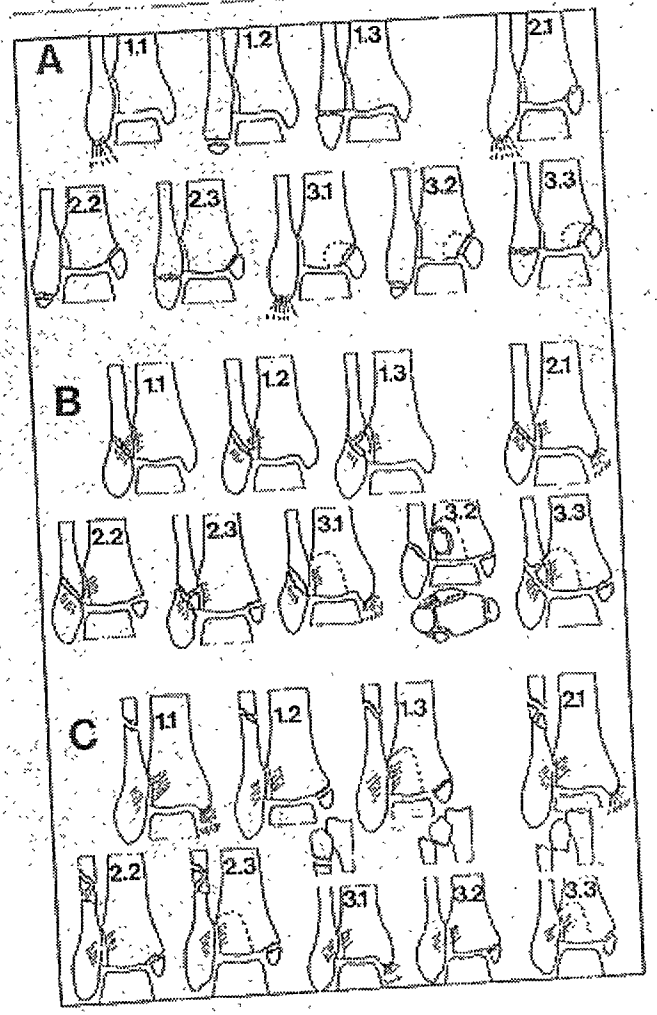

VITA

David Crandall Paulus was born in Charleston, WV on October 6, 1976. He attended high school at Dickson County High School in Dickson, TN, graduating in 1994. From there, he went to the University of Tennessee, Knoxville and received a B.S. in mechanical engineering with a concentration in thermal sciences in 1999. He also received a M.S. in industrial engineering in 2001.

On completion of this thesis, David will be pursuing his doctorate in mechanical engineering at Colorado State University, CO.