To the Graduate Council:

I am submitting enclosed a thesis written by Michael W. Hance entitled "Leydig Stem Cell Differentiation in the Prepubertal Hamster ***(Mesocricetus auratus)***." I have examined the final electronic copy of this thesis for form and content and recommend that it be accepted in partial fulfillment of the requirements for the degree of Master of Science, with a major in Comparative and Experimental Medicine.

S.M.L. Chamindrani Mendis-Handagama

_____

Major Professor

We have read this thesis
and recommend its acceptance:

Jack Oliver

_____

Juergen Schumacher

_____

Jon Wall

_____

Accepted for the Council:

Anne Mayhew

_____

Vice Chancellor and Dean of Graduate Studies

(Original signatures are on file with official student records)

LEYDIG STEM CELL DIFFERENTIATION IN THE PREPUBERTAL HAMSTER *(Mesocricetus auratus)*

A Thesis Presented for the Master of Science Degree
The University of Tennessee, Knoxville

Michael W. Hance
December 2005

Copyright © 2005 by Michael W. Hance
All rights reserved.

DEDICATION

This thesis is dedicated to my mother, Patricia Hance, wife, Emily Hance, friends and family, and my great role models, Dr. Charmindrani Medis-Handagama and Dr. Robert Moore, for always believing in me, inspiring me, encouraging me to push myself to work harder to accomplish my goals.

Acknowledgments

I thank all those who helped me to complete my Master of Science degree in Comparative and Experimental Medicine. I thank Dr. Siril Ariyaratne for his guidance and supplemental teachings on tissue processing, histology and stereology. I would like to thank Dr. Kellie Fecteau and the endocrinology laboratory staff for their guidance and patience during my many radioimmunoassays. I also thank my committee, the laboratory care staff, and laboratory technicians whose contributions are invaluable to the completion of this project.

Lastly, I thank my friends and loved ones whose immense encouragement and support made this work possible.

Abstract

Leydig cells in the testis are the primary source of androgens in the adult male mammal. Therefore, the process of Leydig cell differentiation during the prepubertal period is essential to establish the Leydig cell population in the adult. Little has been published regarding the factors that regulate the postnatal Leydig cell differentiation in hamsters. However, it has been observed in adult male hamsters that Leydig cells regress under reduced photoperiods, but recrudesce with re-exposure to normal photoperiods. In the present investigation, the effects of light, hypothyroidism, hyperthyroidism, and melatonin treatment on Leydig cell differentiation in the neonatal-prepubertal hamster are investigated. Six treatment groups of male Syrian Golden hamsters were used. Group I male hamsters were raised under regular light conditions (12hr: 12hr Light:Dark) and group II hamsters were raised under reduced light (23hr: 1hr Dark: Light). Hamsters in Groups III received triidothyronine (T3; 50 μg/ kg. bwt); lactating mothers were injected every four days from birth of pups to day 28, and were maintained under regular light conditions. Hamsters in Group IV were maintained under regular light regimes (12hr: 12hr) and were made hypothyroid by adding 0.1% propylthiouracil to drinking water of lactating mothers from birth to day 28. Hamsters in Group V were raised in dark (similar to Group II), but their mothers received T3 injections similar to those in Group III. Lactating mothers in Group VI received melatonin injections (15 milligrams/ kg. bwt) every other afternoon from birth to day 28. Following euthanasia at postnatal day 28, blood was collected from the heart, serum prepared and stored until assay for hormones: thyroxin (T4), and melatonin.

One testis from each hamster in each group was fixed by whole body perfusion, processed and embedded in epon-aradite. Using 1-micron sections that were stained with Methylene Blue-Azure II, Leydig cell numbers per testis in the experimental groups were quantified by the disector method. Leydig cells were identified by their characteristic morphology and their location in the testis interstitium. The ipsilateral testis from each hamster in each group was incubated in media containing luteinizing hormone (100ng/ml) and used to determine testosterone and androstenedione secretory capacity per testis *in vitro*. There was a reduction in Leydig cell numbers per testis in D28 hamsters (Group II), D28T3 hamsters (Group V), L28PTU hamsters (Group IV), and L28M hamsters (Group VI) when compared to L28 hamsters (Group I) and L28T3 hamsters (Group III). Significantly increased testosterone secretory capacities were found in the hamster groups D28 (Group II) and L28T3 (Group III) when compared to L28 (Group I). There were significantly reduced testosterone secretory capacities in hamsters in L28PTU (Group IV), L28M (Group VI), and D28T3 (GroupV), compared to L28 (Group I).The majority of the groups were not significantly different in androstenedione secretory capacity per testis except there were significantly lower values in L28PTU (Group IV) and D28T3 (GroupV). L28 (Group I) hamsters had significantly higher serum thyroxin levels than hamsters in D28 (Group II), L28PTU (Group IV), L28M (Group VI). Serum melatonin levels were the lowest in L28 (Group I) hamsters and the highest in L28PTU (Group IV) hamsters. These findings demonstrate that increased levels of melatonin and decreased levels of thyroxin negatively regulate and decreased levels of melatonin and increased levels of thyroxin positively regulate Leydig cell differentiation in the prepubertal hamster testis. It is concluded that thyroid pineal interactions are

important in regulating the process of postnatal Leydig cell differentiation in the perpubertal hamster testis.

Table of Contents

Chapter I: Introduction	**pg. 1**
Chapter II: Materials and Methods	**pg. 15**
Chapter III: Results	**pg. 21**
Chapter IV: Discussion	**pg. 46**
List of References	**pg. 58**
Vita	**pg. 65**

List of Tables

1. **Table 1: Volume Density of Testis Components (%)** **pg. 33**
2. **Table 2: Absolute Volumes of Testis Components (mm^3)** **pg. 34**
3. **Table 3: Total Cell Counts per Testis (10^6)** **pg. 38**
4. **Table 4: Androgen Secretory Capacity per Gram of Testis (ng)** **pg. 42**

List of Figures

1. **Figure 1: Gross Anatomy of the Testis** **pg. 1**
2. **Figure 2: A Schematic Diagram of the Interstitial Tissue** **pg. 3**
3. **Figure 3: Leydig Cell Lineage** **pg. 4**
4. **Figure 4: Body Weights (g)** **pg. 22**
5. **Figure 5: Fresh Testis Weights (g)** **pg. 23**
6. **Figure 6: A Representative Photomicrograph of a L28 Testis** **Pg. 24**
7. **Figure 7: A Representative Photomicrograph of a D28 Testis** **pg. 26**
8. **Figure 8: A Representative Photomicrograph of a D28 Testis at 100X Photographic Magnification** **pg. 27**
9. **Figure 9: A Representative Photomicrograph of a L28T3 Testis** **pg. 28**
10. **Figure 10: A Representative Photomicrographs of a L28PTU Testis** **pg. 29**
11. **Figure 11: A Representative Photomicrograph of a D28T3 Testis** **pg. 31**
12. **Figure 12: A Representative Photomicrograph of a L28M Testis** **pg. 32**
13. **Figure 13: Leydig Cell Absolute Volume per Testis (mm^3)** **pg. 35**
14. **Figure 14: Total Leydig Cell Number per Testis (10^6)** **pg. 37**
15. **Figure 15: Testosterone Secretory Capacity per Testis (ng/testis) Radioimmunoassay** **pg. 40**
16. **Figure 16: Androstenedione Secretory Capacity per Testis (ng/testis) Radioimmunoassay** **pg. 41**

17. Figure17: Serum Thyroxine Concentrations (ng/mL) Radioimmunoassay pg. 43

18. Figure18: Serum Melatonin Concentrations (ng/ml) Radioimmunoassay pg. 45

19. Figure 19: Regulation of Postnatal Leydig Cell Differentiation by Melatonin and T4 pg. 57

List of Symbols and/or Abbreviations

g	**grams**
mm	**millimeter**
ng/ml	**nanograms per milliliter**
µ	**micro**
D28	**short day photoperiod**
D28T3	**short day photoperiod supplemented with T3**
LD	**long photoperiod (12L : 12D)**
L28	**control animals**
L28PTU	**long photoperiod supplemented with PTU**
L28M	**long photoperiod supplemented with Melatonin**
L28T3	**long photoperiod supplemented with T3**
SD	**short photoperiod (1L : 23D)**
RIA	**Radioimmunoassay**
LC	**Leydig cell**
ALC	**Adult Leydig cell**
FLC	**Fetal Leydig cell**

CHAPTER I

INTRODUCTION

Male Reproductive System

The mammalian testes are encapsulated paired organs that produce spermatozoa within the seminiferous tubules, and androgens (male hormones) in the interstitium; the latter separates the seminiferous tubules (ST) and contains blood, lymph vessels, and nerves. Figure 1 is a schematic diagram of the gross anatomy of the testis, epididymis, and ductus deferens. Extending from the anterior portion of the testes is the epididymis, which is a highly convoluted duct that is involved with the maturation of sperm and storage of mature sperm. The ductus deferens, which transports sperm to the urethra, connects the epididymis and testes to the rest of the male reproductive tract (1).

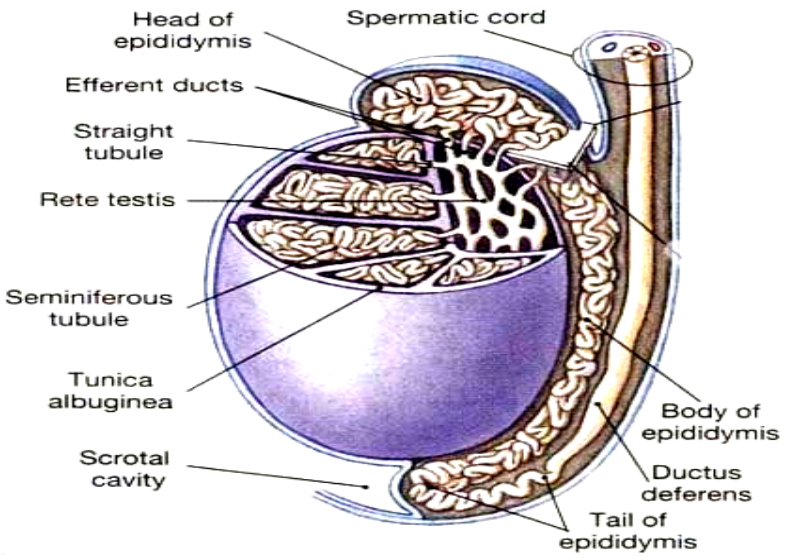

Figure 1: Gross Anatomy of the Testis (Including Epididymis and the Ductus Deferans). Photo courtesy of www.bio.davidson.edu/.../ companat/companat.html

Organization of the Testis

The tough fibrous capsule of the testis, called the tunica albuginea, is composed of three layers: the tunica vaginalis, the tunica albuginea proper, and the tunica vasculosa. The tunica is innervated, well-muscled, and producing contractions that are important for transport of spermatozoa, produced in the (ST), out of the testis. The majority of the testis is composed of the ST. The convoluted ST are two ended and attach to the rete testis, which is a complicated network of channels that carry the spermatozoa to the epididymis. The number of ST in the hamster is unknown but in rats, there are normally 30 tubules (1). Mature spermatozoa, produced in the ST, are released into the lumen of the ST (1).

Boundary tissues are peripheral to the ST and have four tissue layers: the innermost layer of non-cellular material, a layer of myoid cells that provide peristaltic movements of the tubules, a layer of collagen fibers, and a layer of endothelial cells that line the interstitial tissue (1). The interstitial tissue, or the testis interstitium, provides support to the areas between the ST, as shown in Figure 2. In addition, the interstitium contains blood vessels, lymph vessels, and nerves to the testicular parenchyma. Leydig cells, macrophages, plasma cells, fibroblasts, mesenchymal cells and mast cells are present in the interstitial tissue. In the hamster and many other seasonal breeders, the testis as a whole, and other testicular components such as the ST and Leydig cells, undergo regression in photo-restrictive periods (2).

Leydig cells are the primary source of male hormones/androgens, which are important in normal male reproductive physiology. In addition, androgens are required for the maintenance of many other organ systems of the male mammal (e.g. muscle, bone, and skin) (7). In hamsters, there are approximately 15-18x10^6 Leydig cells per

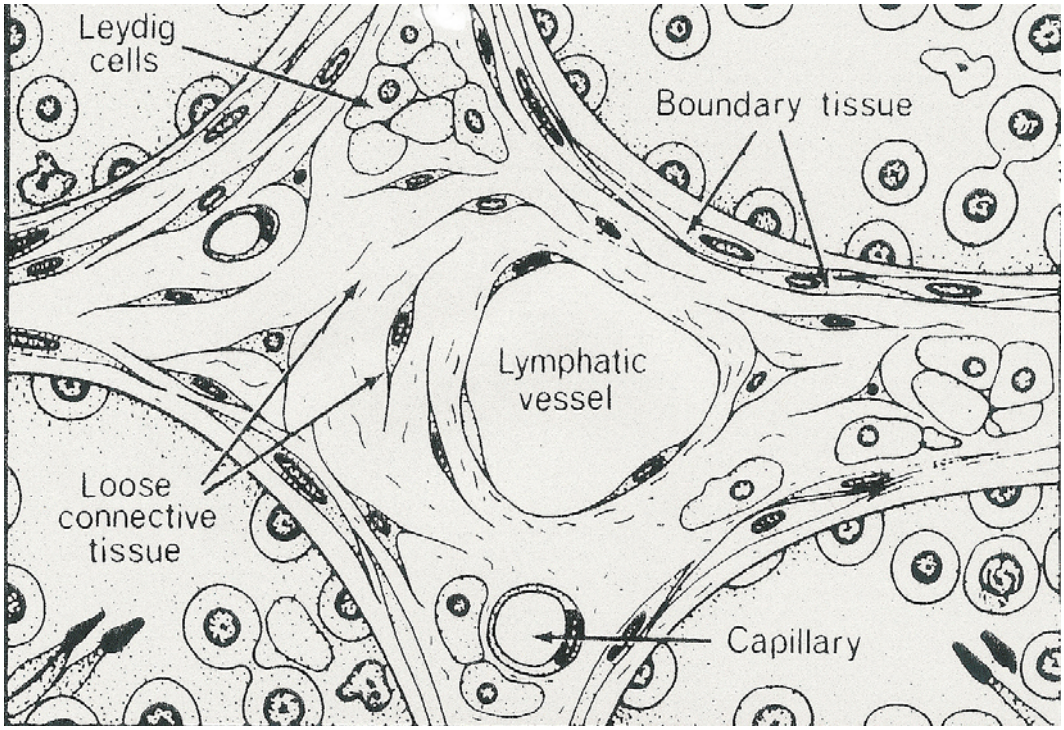

Figure 2: **A Schematic Diagram of the Interstitial Tissue. (From ref. 1.)**

testis (3,4,5,6). It is established that luteinizing hormone (LH) produced in the anterior pituitary stimulates the Leydig cells to produce testosterone. Leydig cells and macrophages have a suggested functional relationship; the macrophages may have a role in Leydig cell steroidogenesis, and their depletion from the testis reduces secreted testosterone (7).

Leydig Cell Lineage

There are two distinct populations of Leydig cells in mammals studied to date; prenatal and postnatal, or fetal and adult. The rat is the most studied species for the process of postnatal Leydig cell differentiation. It is suggested that postnatal Leydig cell differentiation in rats and mice occurs within the second week of the postnatal life (7).

Postnatal differentiation of Leydig cells is crucial to the male mammal to establish the adult Leydig cell population. The latter secrete testosterone needed for reproduction and overall health. Leydig cell differentiation is divided into several steps: precursor cell proliferation, differentiation of precursor cells to Leydig cell progenitors, progenitors give rise to newly formed adult Leydig cells, newly formed adult Leydig cells differentiate into the immature adult Leydig cells, and finally the immature adult Leydig cells differentiate into the mature adult Leydig cells (7). Figure 3 is a schematic diagram of Leydig cell lineage to show this process (7).

As shown in Figure 3, mesenchymal cells of the testicular interstitium are precursor cells to adult Leydig cells; they originate from either the mesonephric tubules or the loose connective tissue of the developing gonad that originated from the embryonic mesoderm (8). During gestation, some of the mesenchymal cells differentiate into fetal Leydig cells and others remain undifferentiated and function as precursor cells to the adult Leydig cells in the postnatal testis (8).

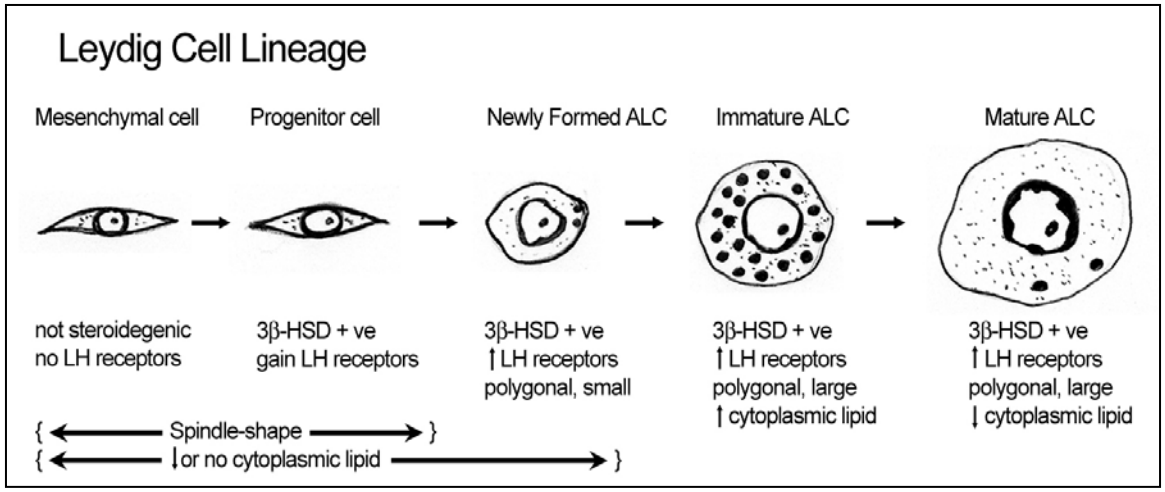

Figure 3: **Leydig Cell Lineage. (From ref. 7)**

Mesenchymal cells are spindle shaped cells with little cytoplasm, as shown in Figure 3. They are not steroidogenic and lack LH receptors (7). They occupy the peritubular (i.e. around the seminiferous tubules) and non-peritubular areas of the testicular interstitium; peritubular mesenchymal cells give rise to almost all of the adult Leydig cells in the postnatal testis (7).

The first step in the process of postnatal Leydig cell differentiation is the differentiation of precursor mesenchymal cells into progenitor cells. The progenitor cells are identical in appearance to precursor cells, but express a few steroidogenic enzymes and produce some androgens. In addition, the progenitor cells have a truncated form of LH receptor that is capable of binding small amounts of LH (7). Progenitors differentiated from precursor cells, concurrently acquire 3β-hydroxysteroid dehydrogenase (3β-HSD), cytochrome $P450_{SCC,}$ and $P450_{C17}$ enzymes necessary for testosterone production. Interestingly, all of the above steroidogenic enzymes are acquired in progenitors prior to gaining the LH receptors, thus, demonstrating that LH is not the trigger for the onset of precursor cell differentiation into progenitor cells (7). As differentiation continues, the progenitors become more round in appearance which signifies the progression into newly formed adult LC, as seen in Figure 3 (7).

Newly formed adult Leydig cells are polygonal compared to the progenitor cells that are spindle shaped as shown in Figure 3. They move toward the central portion of the interstitium. In newly formed adult Leydig cells, the cytoplasmic volume is relatively small compared to the size of the nucleus (see Figure 3). These newly formed adult Leydig cells lack 11β-hydroxysteroid dehydrogenase 1 immediately after their differentiation, but they obtain it progressively from postnatal day 21 onward through

maturation of the Leydig cells (9). Newly formed adult Leydig cells comprise 40% of the testosterone secretory capacity of adult Leydig cells in a sexually mature testis and the greatest capacity for secreting androstenedione (7).

Immature adult Leydig cells are larger than newly formed adult Leydig cells because of increased cytoplasm, organelle content, and cytoplasmic lipid droplets. Immature adult Leydig cells appear in the testis interstitium from postnatal day 26-28 until day 45-50 in the rat testis (7). From postnatal day 28 through day 56, a steady increase is seen in 3β-HSD, cytochrome $P450_{SCC,}$ $P450_{C17,}$ and 17β-hydroxysteroid dehydrogenase (17β-HSD) activity in Leydig cells; these enzyme activities reach the highest levels in the adult Leydig cells at sexual maturity. There are high concentrations of 5α-reductase and 3α-hydroxysteroid dehydrogenase in the immature adult Leydig cells. For this reason, the newly formed adult Leydig cells and immature adult Leydig cells produce more of 5α- reduced androgens instead of testosterone (7). In the interstitium of the prepubertal testis, a mixture of immature adult Leydig cells and newly formed adult Leydig cells are observed.

The final step in Leydig cell differentiation is when the immature adult Leydig cells develop into mature adult Leydig cells, distinguished by a significant increase in cell size and the disappearance of cytoplasmic lipid, and increase in the capacity to secrete testosterone (7). The increase in the capacity of testosterone secretion in the mature adult Leydig cells result from the development of organelles for steroid production such as smooth endoplasmic reticulum, mitochondria, and peroxisomes, and enhanced LH responsiveness. These cells have an increased 17β-HSD activity that catalyzes the final step in testosterone biosynthesis. In addition, there is a reduction in testosterone

metabolizing enzymes, which increase testosterone secretion efficiency, indicating the onset of puberty (7).

Thyroid Hormones and Leydig Cell Differentiation

Thyroid hormone has been shown to have a regulatory effect on Leydig cell differentiation mice and rats (7,10). Leydig cell differentiation is interrupted in the absence of thyroid hormones in prepubertal rat testis (10) and ethane dimethane sulfonate (EDS) treated rat testis (11). EDS is a unique toxin for Leydig cells; it kills Leydig cells 48 hours after treatment, but new Leydig cells differentiate by 21 days to repopulate the testicular interstitium. Hyperthyroidism, conversely, accelerates Leydig cell differentiation (7,10). These observations, combined with the premature recruitment of mesenchymal cells in greater numbers into the Leydig cell lineage in hyperthyroid perpubertal rat testis, support the notion that the differentiation of mesenchymal cells to Leydig cell progenitors requires thyroid hormone. Thyroid hormones give rise to increased proliferation of mesenchymal cells and acceleration of their differentiation into Leydig cell progenitors, and enhance proliferation of progenitors and newly formed adult Leydig cells (10).

Thyroid abnormalities are associated with reproductive dysfunction and affect gonadotropin release, androgen metabolism and testicular functioning (7,10,12). In intact prepubertal hypothyroid animals, induced by administration of propylthiouracil (PTU), there is a noticeable decrease in body weight, testis weight, and an absence of postnatally differentiated Leydig cells (7,10,12). Reductions in testosterone production have been observed in adult hypothyroid animals due to a decreased synthesis of cAMP and reduced activity of enzymes in the androgen biosynthetic pathway rather than changes in LH

receptors (10). In prepubertal rats, thyroid hormone treatment causes early atrophic changes in fetal Leydig cells and the testicular capacity to secrete testosterone in response to reduced LH stimulation (7,10). Interestingly, testicular androstenedione secretory capacity per testis in response to LH stimulation *in vitro*, is considerably increased in hyperthyroid perpubertal rats and is explained by an increased differentiation in the number of mesenchymal cells into newly formed adult Leydig cells in these testes (10).

Effects of Photoperiod on Testis Structure and Function

Seasonal-breeding mammalian males, such as hamsters, undergo a marked testicular atrophy during non-breeding seasons or shorter day lengths (6L and 18D) (2). During these periods, the hamster testis shows a reduced capacity to secrete testosterone and is reported to show Leydig cell atrophy (3,6). Stereological studies have demonstrated a reduction of the volumes of Leydig cell organelles, most notably in those that are involved with steroidogenesis (2). The induction of recrudescence is initiated by an increased photoperiod (long day 14L and 10D) that restores Leydig cell numbers and size or a spontaneous recrudescence after 18 weeks of exposure to SD lengths (13). Therefore, the suggestion that light may have a regulatory role in postnatal Leydig cell differentiation in hamsters appears to be logical, because light is an important factor in maintaining the differentiated status of the Leydig cells in such species (2,3,4,13).

Brown et al. (14), have shown that gonadatropin-releasing hormone (GnRH) mRNA is highly expressed in adult male Syrian hamsters (*Mesocricetus auratus*) even when their reproductive axis was induced sexually dormant through exposure to SD (6L:18D), and that photoperiod induced changes in GnRH secretion are likely to control the timing of the breeding season (14). Kawazu et al. (15), demonstrated that adult male

Syrian hamsters exposed to SD photoperiods had a significant decrease of plasma follicle stimulating hormone (FSH), plasma testosterone and immunoreactive(ir) inhibin (an assayable form of inhibin); inhibin is a hormone that is produced by the Leydig cells and Sertoli cells (15,16,17). FSH is produced by the pituitary gland and may be involved in Leydig cell differentiation through LH sensitivity in steroidogenesis (18). In SD hamsters, significantly reduced testicular ir-inhibin, testosterone, pituitary LH, and pituitary FSH have been associated with reduced testes weight, and reduced sperm head counts (15). However, all reproductive parameters and secretions of LH, FSH, ir-inhibin and testosterone slowly recovered after 17 weeks of SD exposure even in a continued SD regimen (15). Jin et al. (16) and Kishi et al. (17), suggest that inhibin B is involved directly with the regulation of FSH secretion during both regression and recrudescence. Currently, there is nothing published describing a potential involvement of melatonin in the observed inhibin mediated regulation of FSH (15,16,17). However, hamsters in a SD photoperiod have shown a reduction of FSH, LH, and prolactin (PRL) levels (19). Results of studies by Frungieri et al. (19), showed that exposure of adult Syrian hamsters to a short photoperiod produced a significant reduction in serum concentrations of dihydrotestosterone and androstane-3α, 17β-diol, but normal testicular 5α-reductase activity. Hamsters in short photoperiods produce more androstane-3α, 17β-diol than did normal adult hamsters in long day photoperiod (19).

Serotonin (5-HT) and its primary metabolite 5-hydroxyindoleacetic acid (5-HIAA) are located and can be produced in Leydig cells and mast cells in the Syrian hamster testis (20); 5-HT has been suggested to be a negative regulator of LH activity of gonadotropin-induced cAMP production and steroid production (20). Frungieri et al (19)

state that 5-HT is a modulator of gonadotropin action on steroidogenesis during sexual maturation and photoperiodic-induced regression-recrudescence evolution in the hamster. Johnston et al (21) demonstrated heterogeneous regulation of different lactotrophs (secrete PRL) of the pars distalis in the anterior pituitary gland and the secretion of PRL in response to photoperiod (LD and SD). They found that photoperiod had no effect on approximately 25% of the expression of PRL mRNA in lactotrophs, and a similar percentage expressed very low levels of PRL mRNA suggesting that they are unresponsive to photoperiods. The remaining pars distalis cells expressed a marked increase in PRL mRNA during LD (21). In SD hamsters, melatonin (Mt), a hormone secreted by the pineal gland, stimulates the pars tuberalis region of the pituitary gland to secrete tuberalin, an endocrine factor that acts on lactrotrophs in the pars distalis responsible for synthesizing PRL, which down-regulates PLR production (21). This reduction in PRL is important in hamster Leydig cell function because it has a negative influence on the number of LH receptors (2).

Carr et al. (22), suggest that circadian oscillators in peripheral tissues are involved in photoperiodic time measurement in seasonal breeding mammals. The suprachiasmatic nuclei (SNC), located within the hypothalamus, houses the primary circadian oscillator; animals that have undergone spontaneous recrudescence require the involvement of intermediate factors that play a role in the entrainment of the peripheral oscillators, not the SNC or Mt directly (22). The mechanism for long-term time keeping is explained by Mt controlled expression of clock genes in calendar cells. Agranular secretory cells of the pituitary pars tuberalis, express high concentrations of Mt receptors (mt1), which are involved with photoperiod and PRL secretion (22, 23). In the hamster, pars tuberalis of

the pituitary gland, Per 1 is a clock gene with high amplitude rhythms that are suppressed in SD photoperiods or treatment with Mt (23). Per 1 gene is activated in early light or dawn and Cry 1 is activated in the dark phase or dusk; thus both are clock genes (23). It is suspected that the photoperiod-induced changes that occur by altering Per1/Cry1 gene expression in the peripheral oscillators in hamsters could be a potential mechanism for Mt response and long-term photoperiod response (23).

Melatonin and Leydig Cells

Mt is produced by the pineal gland from the precursor 5-HT and is at the highest concentrations during the nighttime hours; Mt concentration in blood is regulated by photoperiod (24). Mt secretion establishes the circadian system which induces the secretion of a long signal during the winter (SD 6L: 18D) and a short signal during the summer (LD 14L: 10D) (2). In seasonally breeding animals, a change in photoperiod can initiate changes in reproductive activity. Gunduz et al. (25) demonstrated that Mt has an inhibitory role on testicular development irrespective to the presence or absence of the pineal gland. Edmonds et al. (26) established that adult pinealectomized male rice rats, that had undergone testicular regression, experienced a delayed photo-stimulated recrudescence in LD animals, but spontaneous recrudescence was unaffected in SD animals. However, pinealectomized male rice rats with regressed testes, and melatonin treatment via implants, had delayed photo-stimulated and spontaneous recrudescence (26). Melatonin activates receptors located in different regions of the hypothalamus and the pituitary pars tuberalis, which modifies hypothalamic control of anterior pituitary function. The latter leads to changes in gonadotropin release that results in seasonal alterations in testis function with reductions in testosterone release (2). Pinealectomized

male hamsters do not demonstrate photoperiod-induced testicular atrophy (25, 27). However, when exogenous melatonin injections were administered to these animals the pinealectomy was functionally reversed and testicular regression was observed (25, 27). Redins et al. (28) demonstrated that melatonin may act directly on the Leydig cells in mice resulting in a decreased production of testosterone, decreased nuclear volumes, increased cytoplasmic volumes, and reduced Leydig cell organelles.

Melatonin stimulated secretion of tuberlin, from the pituitary pars tuberalis, regulates PRL secretions from lactotrophs; these secretions have been found to increased in summer (long day photoperiod) and decreased during winter (short day photoperiods) (23). PRL is involved in the regulation of Leydig cell function by regulating testicular LH/hCG receptors and steroidogenic receptiveness (29). During a SD photoperiod there is a decreased release of FSH, LH, and PRL (30), and a reduction in LH/hCG receptor numbers in the Leydig cells (29). In contrast, LD photoperiods result in increased concentrations of PRL that serves as a positive regulator of PR2 receptors and LH receptors, and induces normal Leydig cell steroidogenesis (29).

It has been demonstrated in isolated Leydig cells, from both LD and SD hamsters, that melatonin causes significantly reduced human chorionic gonadotropin (hCG) induced production of cAMP. Lowered cAMP in the Leydig cells results in lowered synthesis of the primary androgens; namely testosterone and androstane-3α, 17β-diol, and expression of steroidogenic acute regulatory protein (StAR), cytochrome $P450_{SCC}$, 3β-hydroxysteroid dehydrogenase (3βHSD) and 17β-hydroxysteriod dehydrogenase (17βHSD)(30). In the Leydig cells of hamsters exposed to SD photoperiod, melatonin induced the conversion of testosterone into 5α-reduced androgens (30). Recently,

Frungieri et al. (30) detected melatonin subtype a receptors (mel1a) on hamster Leydig cells, which has an inhibitory effect on steroidogenic enzyme activity and androgen production. Furthermore, they state that melatonin can be synthesized in the testis, which lacks the involvement of serotonin action on the pineal gland (30). However, to date, the effects of melatonin on Leydig stem cell differentiation in the prepubertal testis has not been addressed.

Interactions of Melatonin and Thyroid Hormone

Reduced thyroxine (T4) levels induced by melatonin do not reduce serum testosterone levels (31). Champney (31) demonstrated that castration reduced serumT4 levels in male Syrian hamsters but the replacement of testosterone restored T4 levels. However, the observed decrease in serum T4 levels induced by melatonin injections was not restored in castrated hamsters by replacement with testosterone pellet implants. Results of the above studies suggest that the effect of melatonin on thyroid gland function may be independent of the effects of melatonin on mel1a Leydig cell receptors and testosterone production (31).

Hoover et al. (32) found that exogenous supplementation of hamsters with melatonin in a 14 light:10 dark photoperiod resulted in decreased testis weights, serum and pituitary PRL levels, and serum T4 levels and mimicked a SD photoperiod in adults of this species. Vriend et al. (33) found that melatonin and T4 have an antagonistic effect on the pituitary hormones, growth hormone (GH), and FSH. Hamsters made hypothyroid with thiourea have reduced pituitary GH but significantly increased serum GH; afterwards, T4 injections were found to restore pituitary GH content, reduce serum GH levels and significantly increase FSH levels over control levels (33). Hypothyroid

hamsters that received both T4 and melatonin did not have reduced serum GH levels, but had reduced FSH levels (33). These authors suggest that T4 has a regulatory role on melatonin receptors in the pituitary or central nervous system (33).

Vriend et al (34) demonstrated that the pineal gland is required for the inhibitory action exerted on the pituitary and thyroid glands. Furthermore, electron microscopy examination of Syrian hamster thyroid gland revealed flattened follicular cells with contracted endoplasmic reticulum when compared to control hamsters. Vriend et al (35) have also shown that melatonin supplementation increases serum GH levels and serum levels of insulin-like growth factor 1 (IGF-1). Baltaci et al. (36) demonstrated melatonin induced inhibitory effects on thyroid function in adult Sprague-Dawley rats, with lower levels of free thyroid stimulating hormone (TSH), T4 , and T3. These results were supported by the studies of Petterborg et al. (37), which showed that female hamsters that were treated with melatonin had lower serum free T4 levels, reduced free T3 levels (in the morning only) and reduced T4 and T3 uptake.

The reviewed literature suggests that photoperiod and thyroid hormone have a significant role in the maintenance of the adult Leydig cell population in adult male seasonal breeders. Therefore, it is logical to hypothesize that photoperiod, or more specifically melatonin and thyroid hormone have important roles in prepubertal Leydig cell differentiation in the hamster, and testicular steroidogenesis. The goal of this study is to investigate the roles of melatonin and thyroid hormone on prepubertal Leydig cell differentiation in the hamster testis.

CHAPTER II

MATERIALS AND METHODS

Animals

Sexually mature male and female golden Syrian hamsters (*Mesocricetus auratus*) were purchased from Charles Rivers Laboratories (Wilmington, Ma.). The animals were housed according to the approved University of Tennessee Institutional Animal Care and Use Committee (IACUC) protocols 811 and 1360. All pups born were maintained with the mother until 28 days of age.

Breeding

Sexually mature males were introduced into the female's enclosure and kept for five days, or until aggression was noticed between the pair as specified in the approved University of Tennessee IACUC protocol 1360. Food and water were provided *ad libitum*.

Experimental Design

Six groups of 28-day-old male golden Syrian hamsters were used in this study. Hamsters in treatment group 1 were controls and they were exposed to a standard 12-hour light/12 hour dark photoperiod (LD) and were identified as L28. Hamsters in treatment group 2 received 1 hour light/ 23 hours of dark (SD) and were identified as D28. Hamsters in treatment group 3 received LD photoperiod and were supplemented with thyroid hormone (T3; 50μg/kg every four days injected subcutaneously into lactating mothers, Sigma, St. Louis, MO) (38); they were identified as L28T3. Hamsters in treatment group 4 received LD photoperiod and were supplemented with propylthiouracil

(PTU; 0.1%, w:v, Sigma, St. Louis, MO) (12) in the mother's drinking water and they were identified as L28PTU. Hamsters in treatment group 5 received a SD photoperiod, were supplemented with T3 in a similar manner as treatment group 3, and were identified as D28T3. Hamsters in treatment group 6 received a LD photoperiod and were supplemented with melatonin (MT; 15mg/kg every other morning injected subcutaneously into lactating mothers, Sigma, St. Louis, MO) (39); and were identified as L28M.

Blood Collection and Preparation of Serum for Hormonal Analysis

Hamsters were weighed and given a subcutaneous injection of 0.1 ml heparin per animal (Heparin solution for injection, USP, 10000 U/ml, Steris Laboratory Inc., Phoenix, AZ.). Twenty minutes after administration of heparin hamsters were anesthetized with inhalation anesthesia (Isoflurane, IsoFlo, Abbott Laboratories, North Chicago, IL.) and blood was collected from each animal via cardiocentesis. An overdose of inhalational agent was used for humane euthanasia of the hamsters. Serum was prepared and then stored at -80 ºC until hormone assays were performed (12). Blood collection and humane euthanasia were conducted in accordance to the approved University of Tennessee IACUC protocol #811.

Testis Incubation, Fixation, and Processing for Microscopy

All hamsters were humanely euthanized before tissue collection. Testes were fixed via whole body perfusion (n=4 animals/group) following blood collection. Before fixation, testis A (left) was removed from each animal, cleaned, weighed and decapsulated. This testis (A) was incubated in stimulatory media (2 ml) consisting of aerated Krebs-Ringer bicarbonate buffer (pH 7.4) supplemented with 7% glucose and a

maximum stimulatory dose of ovine LH (100 ng/ml) as previously described (9,12). The LH was obtained from the National Institute of Diabetes and Digestive and Kidney Diseases hormone distribution program, Torrance, CA (12). Incubations were performed in 10 ml vials in a 37º **C** water bath with 90 oscillations/min for 3 hours.

The ipsilateral testis B (right) was fixed *in situ* by whole-body perfusion using 2.5% glutaraldehyde in 0.1 M cacodylate buffer (pH 7.4) as described previously (12). A 22-gauge cannula was inserted into the ascending aorta via an incision made in the left ventricular wall. A 0.9% NaCl solution was perfused through the aorta for 10-15 minutes to clear the blood from the tissue including the testes. After clearance of the blood, 250ml glutaraldehyde/ cacodylate solution was injected through the cannula for 45-60 minutes at an approximate rate of 4.2 ml/minute. Afterwards, the fixed testis was weighed, cut into 1 mm cubes, and post-fixed (in a 1:1 mixture of 2% osmium tetroxide and 3% potassium ferrocyanide). The testis cubes were then dehydrated in series of graded ethanol solutions, and embedded in epon araldite (6,12). Sectioning and staining techniques of the testis tissue are described in the Stereology and Numerical Density section.

Stereology

Volume Density (V_v) of testicular components is the volume of a component per unit volume of testis tissue. The testicular volume densities of testis components were obtained by point counting using an 11x8 inch grid with 88 test points on a color video monitor that was connected to the Olympus BH-2 light microscope as previously described (9,12). Ten sections were counted from each treatment to provide an estimate of the percentage of the following: seminiferous tubules, Leydig cells, macrophages,

blood vessel lumen, blood vessel wall, peritubular mesenchymal cells, the rest of mesenchymal cells, lymphatic tissue, and myoid cells. The objective lens used was X40.

The absolute volume of testicular components per testis (mm^3) was calculated by multiplying the volume density of each component by the fresh testis volume (mm^3) (12). The volume of the fresh testis was calculated by multiplying the fresh testis weight (g) by the density of the testis that is approximately 1 (12).

The numerical density (N_v), or the number of cells per unit volume of the testis tissue of interstitial cells (Leydig cells, mesenchymal cells and macrophages), was quantified using the disector principle (40). A modified version of the original technique (6), published later (9), was used for this study. Two 1-µm sections (the reference section and the look-up section) that were 4 microns apart were cut from each plastic tissue block and affixed to a glass slide flanking each other. The sections were stained with methylene blue azure II stain and cover-slipped. The sections were viewed side by side on two color video monitors. The first area of the reference section was identified at 40x with a microscope mounted with a color video camera (DXC-107A; Sony Corporation) and recorded onto a high quality VHS videotape. Afterwards, the first area of the look up section was located corresponding to the area of the first section so that both sections could be compared side by side. Only those cell types whose nuclear area appeared in one section and not in the other (i.e. unique nuclei) were counted according to the unbiased counting rule of Sterio (40); nuclear profiles that touched the upper or left margins were excluded. Twenty areas per block, and four blocks per animal in a group that contained four animals, were scored for all groups. The area of the tissue section representing the image on the video monitor was determined by the perimeter of the test area using a slide

micrometer. The formula N_v =(Q/AxT)(1-St) in reference 6 was used to calculate N_v. Q is the number of unique nuclei in the test area, AxT is the volume of the test area, and St is the total shrinkage of testicular tissue from fresh unfixed state to final embedded stage.

St was calculated by St=S1(shrinkage 1)+S2(shrinkage 2) (1-S1) as described by Mendis-Handagama and Ewing (6). The total number of each cell type per testis was calculated by multiplying the numerical density of the cell type and testis volume (6).

Hormonal Assays

Testosterone and androstenedione concentrations in 2 ml of stimulatory medium (amount/testis) were measured by using commercially prepared RIA kits (Total Testosterone by Coat-A-Count; DPC, Los Angeles, CA and Androstenedione by ImmuChem; ICN Pharmaceuticals, Costa Mesa, CA). The analytical sensitivity of the testosterone assay was 4ng/dL, and the sensitivity of the androstenedione assay was 5ng/dL. The androstenedione intraassay coefficient of variation was 6.6% and the interassay coefficient of variation was 7.8%. The testosterone intraassay coefficient of variation was 6.7% and the interassay coefficient of variation was 7.9%.

Melatonin and thyroxine concentrations in serum were measured by using commercially prepared RIA kits (Melatonin Direct RIA by ALPCO, Windham, NH and Thyroxine by Coat-A-Count; DPC, Los Angeles, CA). The analytical sensitivity for melatonin was 0.84pg/ml and the sensitivity for thyroxine was 0.25µg/dL. The melatonin intraassay coefficient of variation was 6.7% and the interassay coefficient of variation was 10.4. The thyroxine intraassay coefficient of variation was 3.2% and the interassay coefficient of variation was 8.2%. The melatonin RIA utilizes the Kennaway G280 anti-

melatonin antibody, which has been shown to be very sensitive in the Syrian hamster (41).

Statistics

Statistical analysis was performed using Microsoft Excel (Microsoft Office, Microsoft Corporation, North America). ANOVA was employed to determine whether significant differences ($p<0.05$) were present among the six experimental groups. Significant differences in means of parameters between two experimental groups were determined by paired t-test analysis.

CHAPTER III

RESULTS

Body Weights

Hamster body weights are shown in Figure 4. L28M hamsters were significantly heavier (87.5g) when compared to all other groups, and were followed by D28 hamsters (74.0g); in addition, both of these treatment groups had an observed increase in abdominal adipose tissue compared to other groups. The lightest hamsters were L28PTU (55.6), which were significantly lighter than the control hamsters.

Testis Weights

The mean testis weights compared by treatments are based on fresh testis weights (testis A) as shown in Figure 5. The results of the studies showed that hamsters maintained in the light for 28 days with T3 supplementation (L28T3), and those that were housed in the light for 28 days with PTU supplementation (L28PTU), had significantly reduced testis weights compared to controls (L28), as well as D28, D28T3 and L28M hamsters.

Light Microscopy

Figure 6 is a representative light photomicrograph of the testicular interstitum of L28 hamsters. There is an abundance of Leydig cells in the testis interstitium, which appear as round or polygonal-shaped cells with little or no cytoplasmic lipid ,or in contrast, with an abundance of cytoplasmic lipid. Leydig cells which do not have cytoplasmic lipid are identified as newly formed adult Leydig cells and those with an abundance of cytoplasmic lipid are identified primarily as immature adult Leydig cells.

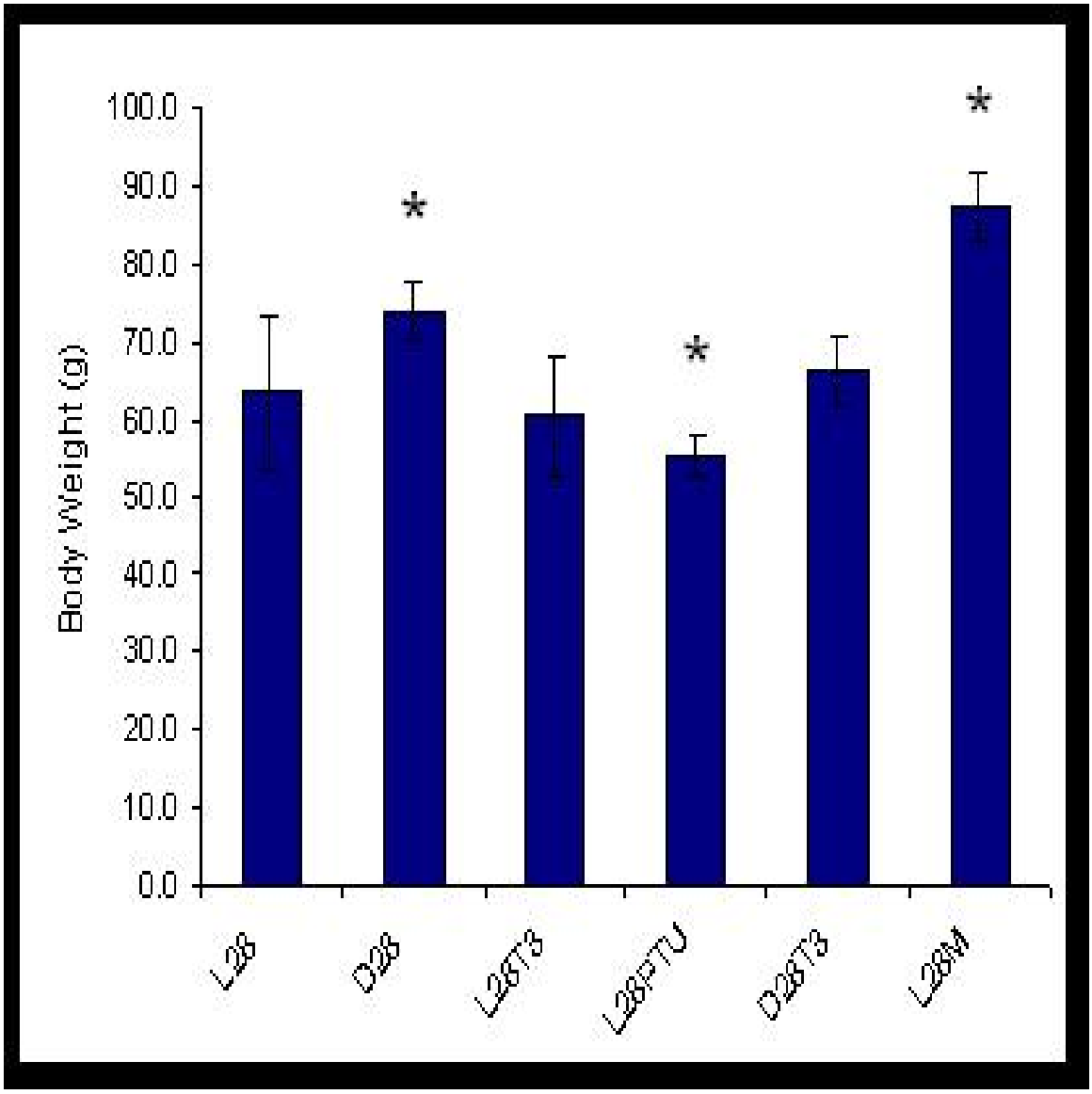

Asterisk (*) indicates a significant difference ($p < 0.05$) from L28 hamsters.

Figure 4: Body Weights (g)

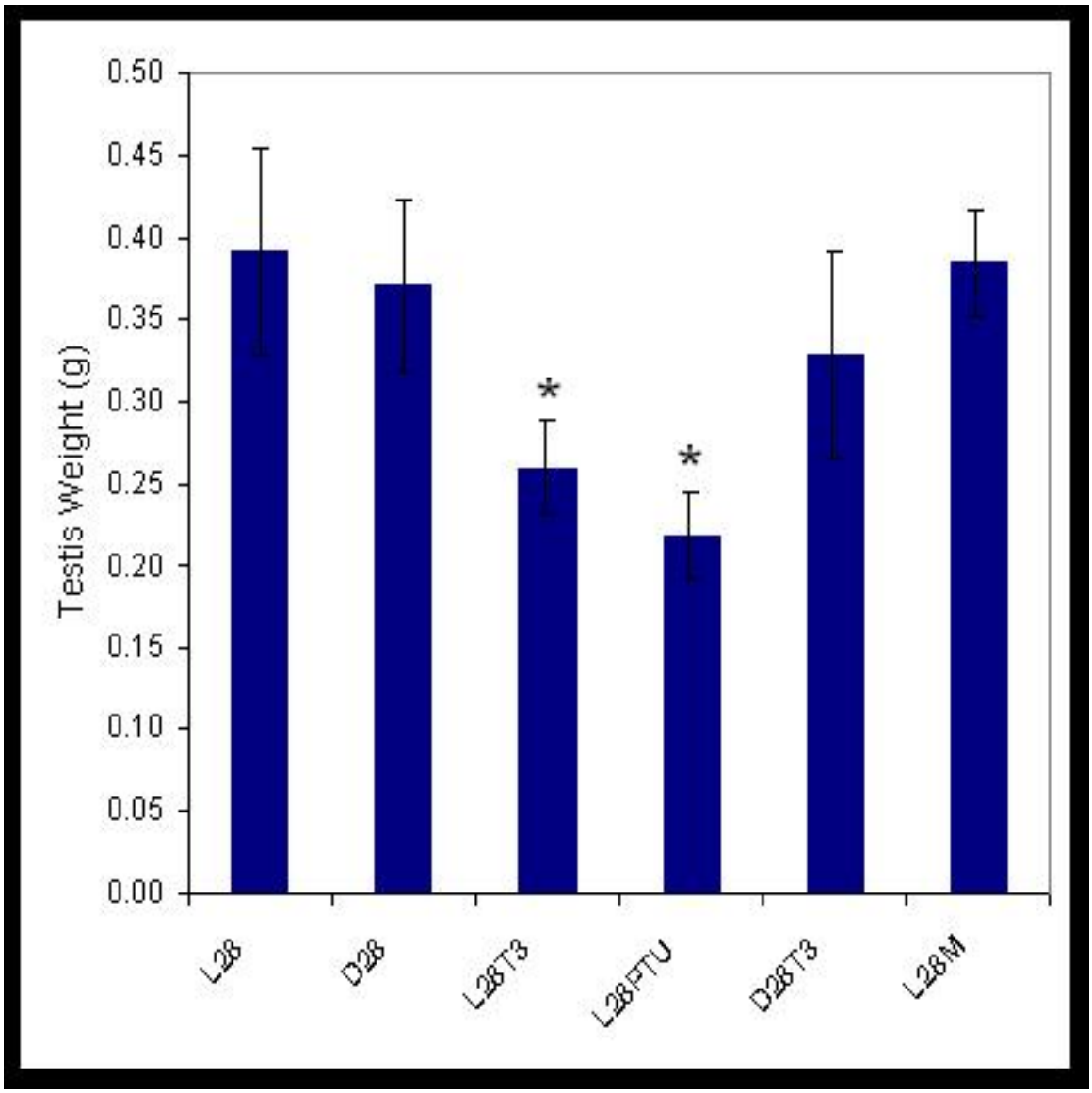

Asterisk (*) indicates a significant difference ($p < 0.05$) from L28 hamsters.

Figure 5: Fresh Testis Weight (g)

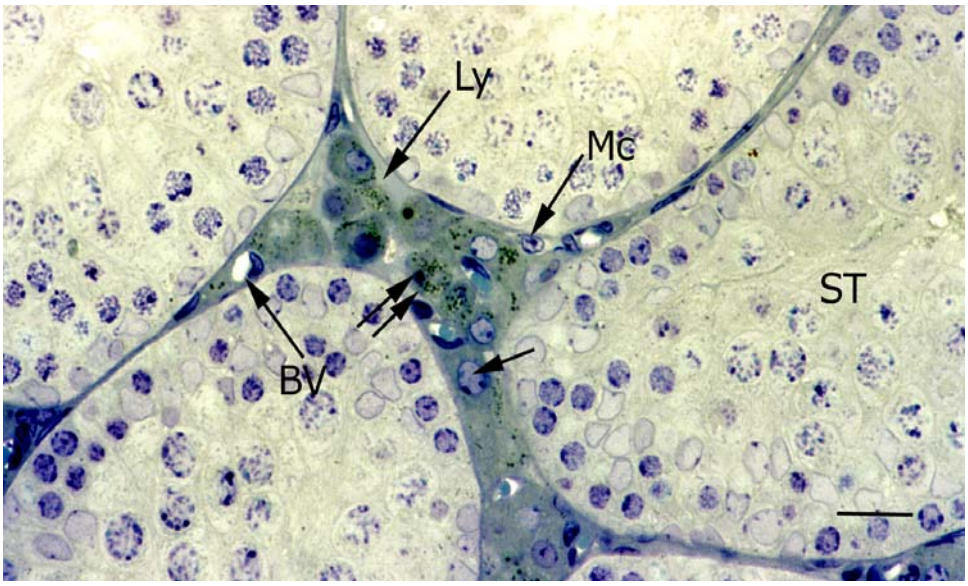

Figure 6: A Representative Photomicrograph of a L28 (28-day-old hamsters in 12 hour light: 12 hour dark, at 40X Photographic Magnification) Testis. Arrow (single) = Newly formed adult Leydig cells, Arrow (double)= Immature adult Leydig cells, BV=Blood vessels, Ly= Lymphatic tissue, Mc= macrophage, ST= Seminiferous tubules.

Figure 7 is a representative light photomicrograph of the testicular interstitium in D28 hamsters. Few newly formed Leydig cells were detected in the testis interstitium (Figure 7). However, fetal Leydig cells were present in some regions. They were identified by their characteristic morphology; Large clusters of cells that contain an abundance of cytoplasmic lipid as seen in Figure 8.

Figure 8 reveals a large population of fetal Leydig cells in a D28 hamster testis interstitium. Note the morphology of the fetal Leydig cells. They are large cells and have a large nucleus with an abundance of cytoplasmic lipid droplets, which appear as either dark regions or white spaces in the cytoplasm. The latter is due to extraction of lipid droplets during the process of tissue preparation for microscopic studies. Fetal Leydig cells in D28 hamster testes were extremely large and appeared as clusters.

Figure 9 is a photomicrograph of the testicular interstitum of L28T3 hamsters that were kept in control conditions and supplemented with T3 to induce a hyperthyroid state. Newly formed adult Leydig cells were abundant in the testis interstitium. They were either organized around blood vessels in groups or found as isolated cells away from the blood vessels. Lymphatic space was seen in abundance in the tissue section (vv % = 8.5%).

Figure 10 is a photomicrograph of the testicular interstitium from a L28PTU hamster that was subjected to hypothyroidism from birth to 28 days of age. Newly formed adult Leydig cells were rare and occasionally spotted as shown; they were extremely small in sections. Clusters of fetal Leydig cells were much smaller than those in D28 hamsters, and were seen in some sections (results not shown). Most of the testicular interstitium

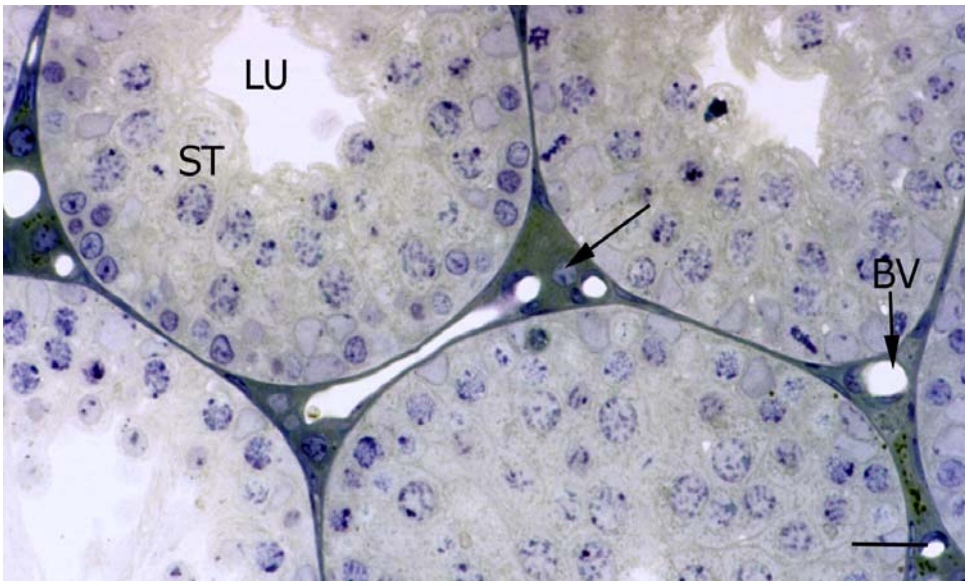

Figure 7: A Representative Photomicrograph of a D28 (28-day-old hamsters in 1 hour light: 23 hour dark, at 40X Photographic Magnification) Testis. Arrow (single) = newly formed adult Leydig cells, BV=Blood vessels, LU=Lumen of the semineferous tubules, ST= Seminiferous tubules.

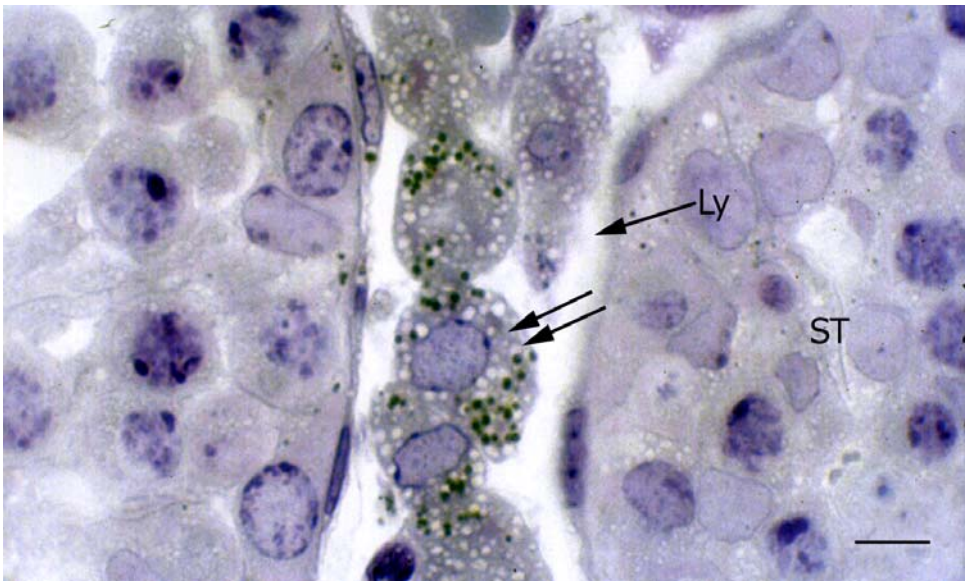

Figure 8: A Representative Photomicrograph of a D28 (28-day-old hamsters in 1 hour light: 23 hour dark) Testis at 100X Photographic Magnification. Arrows (double)= Fetal Leydig cells, Ly= Lymphatic tissue, ST= Seminiferous tubules.

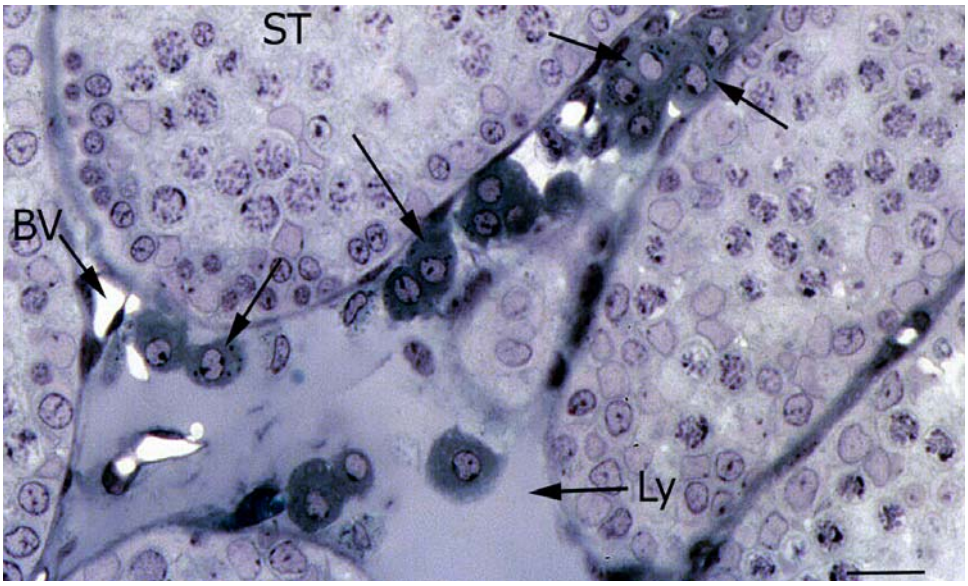

Figure 9: A Representative Photomicrograph of a L28T3 (28-day-old hamsters in 12 hour light: 12 hour dark supplemented with T3, at 40X Photographic Magnification) Testis. Arrow (single)= newly formed adult Leydig cells, BV= Blood vessel, Ly= Lymphatic tissue, and ST= Seminiferous tubules.

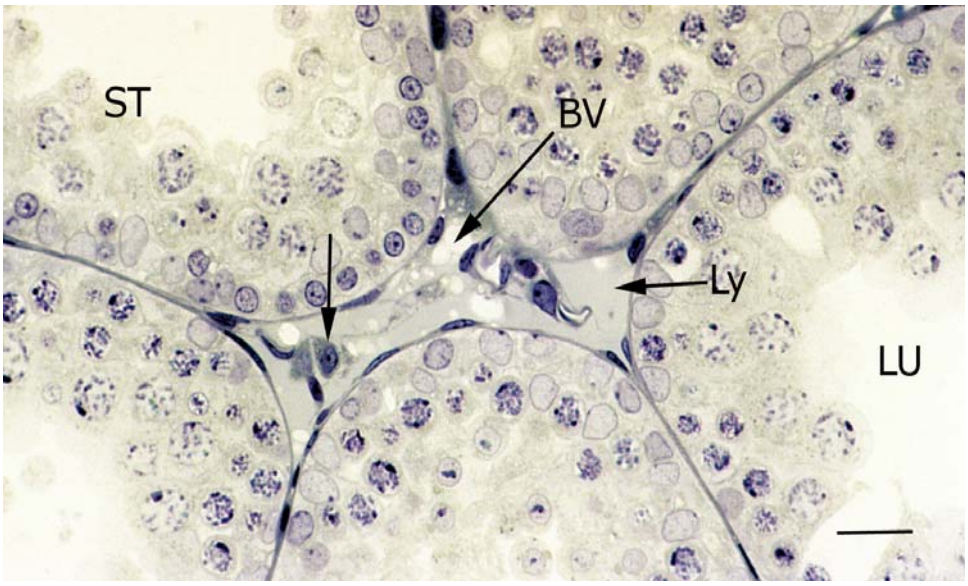

Figure 10: A Representative Photomicrograph of a L28PTU (28-day-old hamsters in 12 hour light: 12 hour dark and supplemented with PTU, at 40X Photographic Magnification) Testis. Arrow (single) = Newly formed adult Leydig cells, BV=Blood vessels, Ly= Lymphatic tissue, LU= Lumen of semineferous tubules, ST= Seminiferous tubules.

was occupied by the lymphatic space; this observation agrees with the stereological estimates of % volume density of lymphatic space in the L28PTU group which is 8.5%.

Qualitative light microscopic studies on the testis interstitium of D28T3 hamsters raised in the dark and supplemented with T3 showed shrunken Leydig cells, which contained many cytoplasmic lipid droplets. These were identified as shrunken fetal Leydig cells (Figure 11). The testicular interstitium also contained small Leydig cells that contained little or no cytoplasmic lipid droplets. These were identified as newly formed adult Leydig cells.

In L28M hamsters, that were kept in a normal photoperiod and supplemented with melatonin, testicular interstitium contained an abundance of fetal Leydig cells. They appeared as clusters of large cells containing an abundance of cytoplasmic lipid (Figure 12).

Volume Density of Testis Components

The volume density of testicular components are shown in Table 1. These values are for reference only. However, it is important to note that the seminiferous tubules comprise most of the testicular volume (84-88%) in contrast to Leydig cells, which are less than 2% (0.7-1.1 %) of the testicular volume.

Absolute Volume of Testis Components

The results of the absolute volume of testicular components, excluding the data on Leydig cells (shown in Figure 13), are given in Table 2. The absolute volume of the semineferous tubules was lowest in the hypothyroid hamsters (L28PTU), and highest in hamsters treated with melatonin (L28M) and those raised in the dark (D28). The absolute

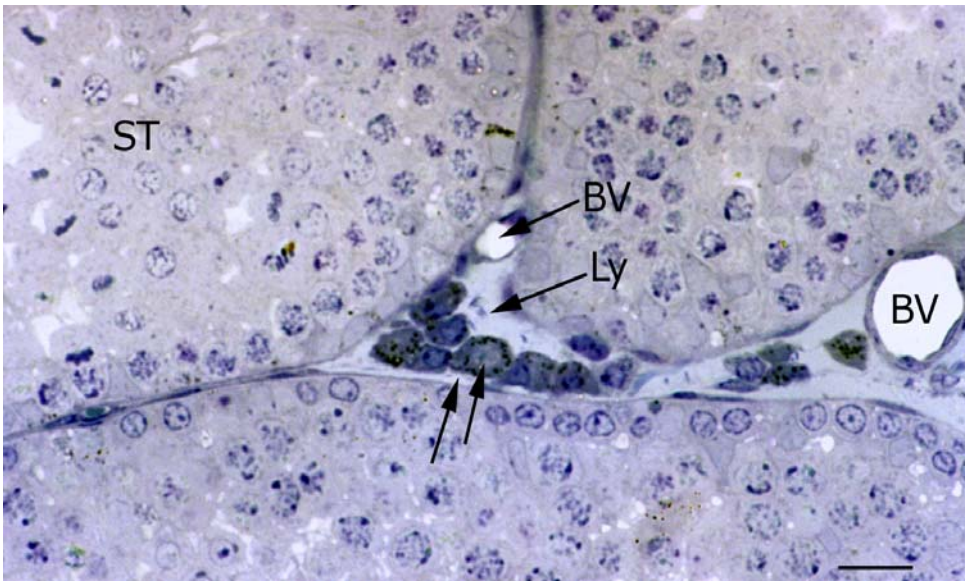

Figure 11: A Representative Photomicrograph of a D28T3 (28-day-old hamsters in 1 hour light: 23 hour dark and supplemented with T3, at 40X Photographic Magnification) Testis. Arrow (double) = Fetal Leydig cells, BV=Blood vessels, Ly=Lymphatic tissue, ST= Seminiferous tubules.

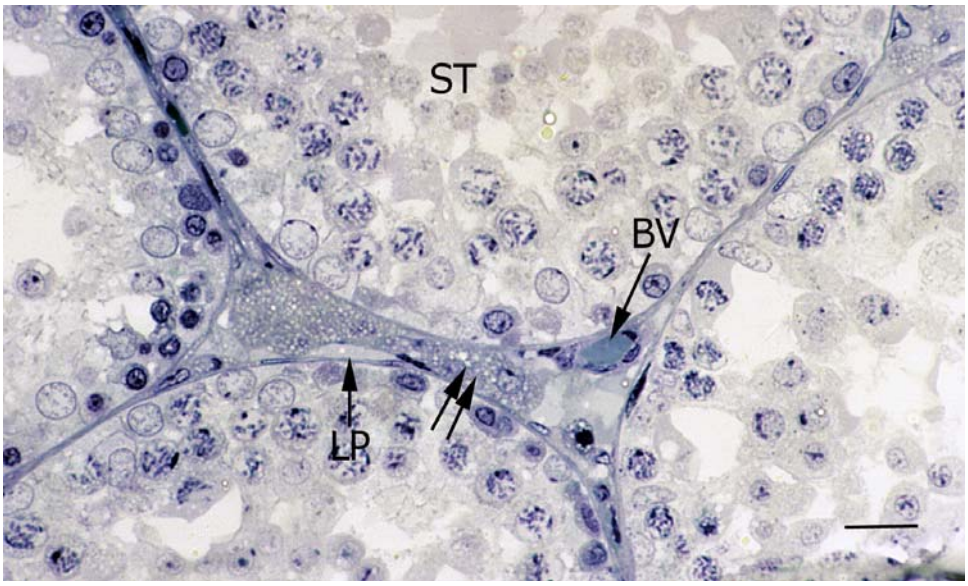

Figure 12: A Representative Photomicrograph of L28M (28-day-old hamsters in 12 hour light: 12 hour dark supplemented with MT, at 40X Photographic Magnification) Testis. Arrow (double) = Fetal Leydig cells, BV=Blood vessels, Ly=Lymphatic tissue, ST= Seminiferous tubules.

Table 1: Volume Density of Testis Components (%)

Parameter	L28 (n=4)	D28 (n=4)	L28T3 (n=3)	L28PTU (n=4)	D28T3 (n=4)	L28+M (n=4)
Seminiferous tubules	85	87	86	86	88	84
Leydig cells	1.1	0.8	1.4	0.8	0.9	0.7
Macrophage	0.4	0.2	0.3	0.2	0.1	0.2
Blood vessel lumen	1.9	2.8	0.8	1	1.1	0.6
Blood vessel wall	0.9	1.3	0.6	1	1.0	0.7
Peritubular mesenchymal cells	1	0.6	1	0.8	0.3	0.6
Other mesenchymal cells	1.3	0.7	1.5	1.3	0.9	1.1
Lymphatics	7.9	6.8	8.5	8.5	7.3	11
Myoid cells	0.3	0.3	0.6	0.5	0.7	1.1

Statistics were not performed on this data

.

Table 2: Absolute Volumes of Testis Components (mm^3).

Parameter	L28 (n=4)	D28 (n=4)	L28T3 (n=3)	L28PTU (n=4)	D28T3 (n=4)	L28M (n=4)
Seminiferous tubules	291.6± 76.1	322.9± 44.6	223.6± 25.3	187.8± 22.9*	288.2± 53.7	323.4± 26.9
Macrophage	1.5±0.4	0.7±0.1*	0.7± 0.1*	0.4± 0.1*	0.3± 0.1*	0.7± 0.1*
Blood vessel lumen	6.5±1.7	10.2±1.4*	2.0± 0.2*	0.4± 0.1*	3.6± 0.7*	2.3± 0.2*
Blood vessel wall	3.1±0.8	4.8±0.7	1.4± 0.2*	2.1± 0.3*	3.2± 0.6	2.5± 0.2*
Peritubular mesenchymal cells	3.4±0.9	2.2±0.3*	2.6± 0.3	1.7±0.2*	1.1± 0.2*	2.4± 0.2*
Other mesenchymal cells	4.4±1.2	2.6±0.4*	3.8± 0.4	2.8± 0.4*	2.8± 0.5*	4.2± 0.4
Lymphatics	27.1±7.1	25.2±3.5*	22.1±2.5*	18.6±2.3*	24.0±4.5*	42.4±3.5*
Myoid cells	1.0±0.3	1.1± 0.2	1.6± 0.2	1.2± 0.1	2.5± 0.5*	4.2± 0.4*

Asterisk (*) indicates a significant difference ($p < 0.05$) from L28 hamsters.

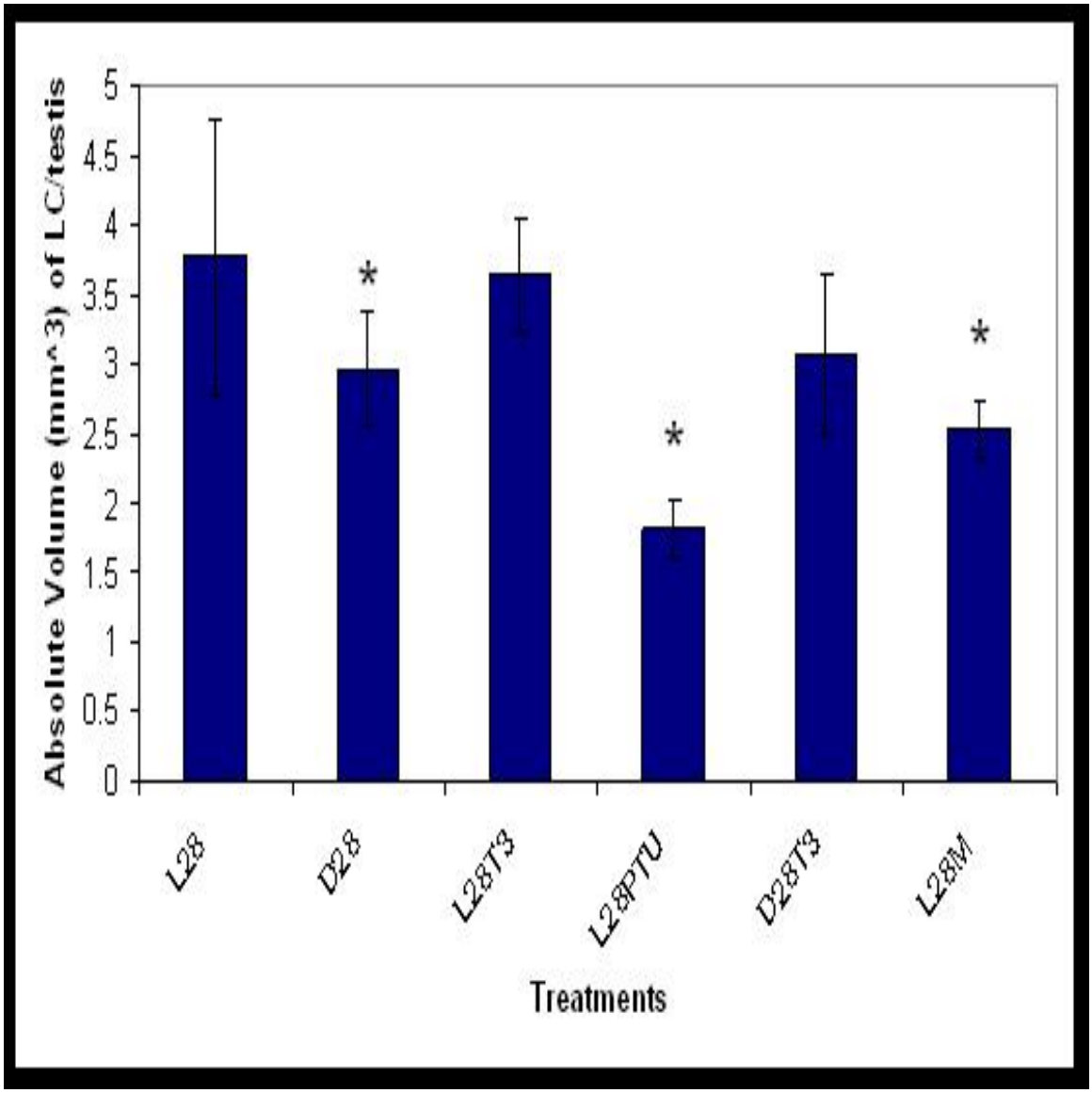

Asterisk (*) indicates a significant difference ($p < 0.05$) from L28 hamsters.

Figure 13: Leydig Cell Absolute Volume per Testis (mm^3).

volumes of other components (except the absolute volume of Leydig cells) are for reference only and were beyond the scope of this study.

Compared to the control hamsters (L28), there was a significant reduction in the absolute volume of Leydig cells per testis in hamsters raised in the dark for 28 days (D28), in the group raised in light for 28 days with melatonin supplementation (L28M), and in hamsters raised in light with PTU supplementation (L28PTU). The most notable and significant reduction of absolute volume of Leydig cells was in the group that was raised in light for 28 days and supplemented with PTU (L28PTU). The absolute volumes of Leydig cells per testis were similar in the control group (L28), the group that was raised in the light and supplemented with T3 (L28T3), and in hamsters that were raised in the dark with T3 (D28T3).

Number of Leydig cells, Mensenchymal cells, and Macrophages per testis

The results of the total Leydig cells (including fetal and adult Leydig cells) per testis are summarized in Figure 14. L28 ($12.8x10^6$) and L28T3 ($13.0 x10^6$) hamsters had a significantly higher number of Leydig cells/testis compared to all other groups. It should be noted that these groups with low Leydig cell numbers per testis had significantly lower levels of serum T4 compared to controls (L28). All treatment groups met the minimum sample size (n=4) except L28T3 (n=3).

Table 3 shows the number of mesenchymal cells (MC) and macrophages (Mac) per testis in the six hamster groups. L28 ($13.7 x10^6$), D28 ($13.5 x10^6$) and, L28T3 ($12.3 x10^6$) treatment groups have significantly more mesenchymal cells per testis then L28M ($6.8 x10^6$), L28PTU ($5.4 x10^6$),and D28T3 ($5.1 x10^6$) treatment groups. L28 (1.7), D28 ($1.7 x10^6$), and L28T3 ($0.9 x10^6$) treatment groups had significantly more macrophages

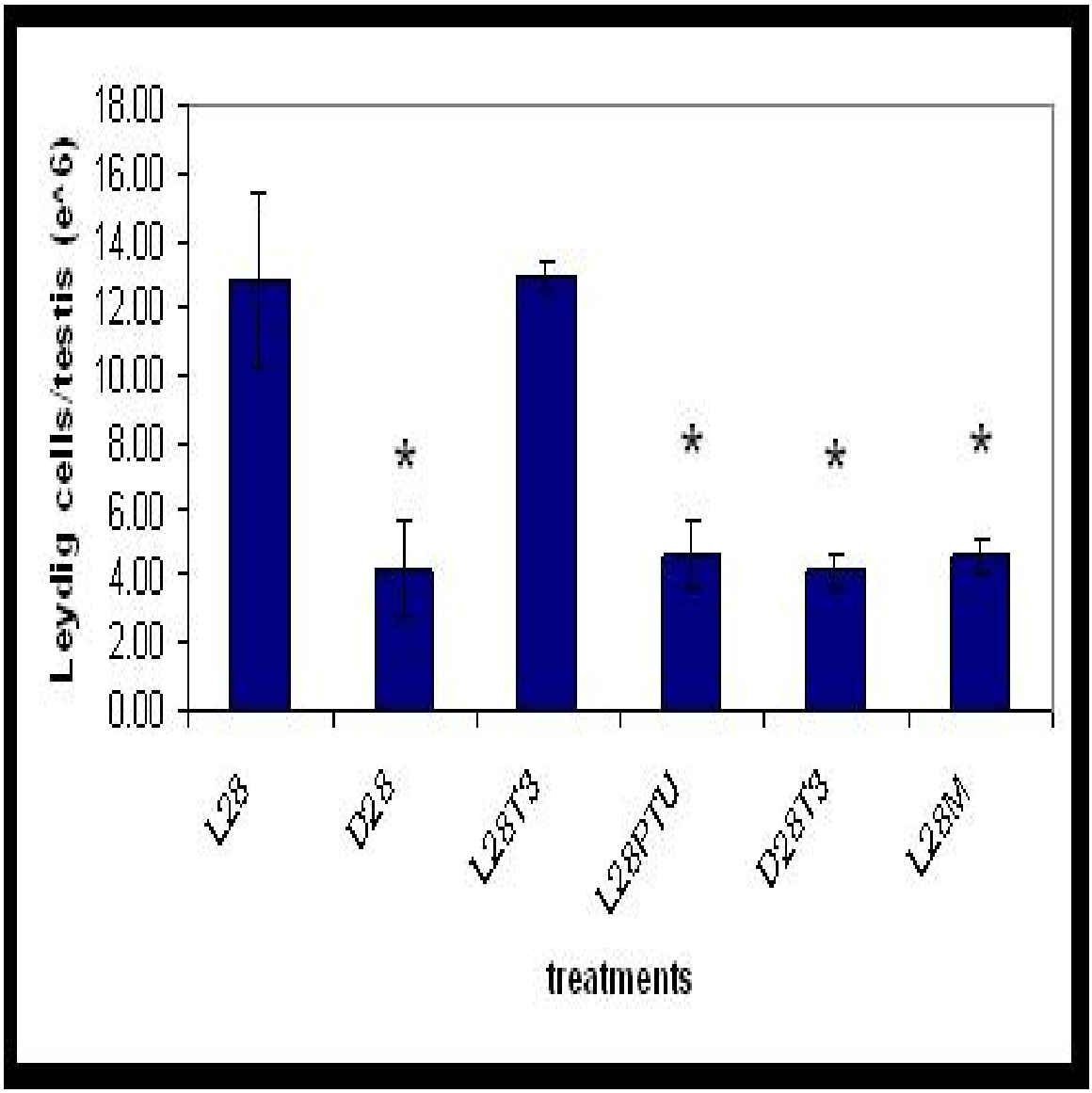

Asterisk (*) indicates a significant difference ($p < 0.05$) from L28 hamsters

Figure 14: Total Leydig Cell Number per Testis (10^6)

Table 3: Total Cell Counts per Testis (10^6).

Treatment	L28 (n=4)	D28 (n=4)	L28T3 (n=2)	L28PTU (n=4	D28T3 (n=4)	L28M (n=4)
MC Mean ± SE	13.7 ±2.3	13.5 ±1.0	12.3 ±0.3	5.4 ±0.7*	5.1 ±0.7*	6.8 ±0.7*
Mac Mean ± SE	1.7 ±0.25	1.5 ±0.16	0.9 ±0.16	0.6 ±0.07*	0.4 ±0.07*	0.4 ±0.15*

Asterisk (*) indicates a significant difference ($p < 0.05$) from L28 hamsters.

per testis compared to L28PTU (0.6 x10^6), L28M (0.4 x10^6), and D28T3 (0.4 x10^6) treatment groups. This table is for reference only. It should be noted that L28PTU, D28T3, and L28M groups had a lower number of macrophages per testis and had lower testicular testosterone secretory capacities (Fig 15).

Hormone Data

Testosterone secretory capacity of the testis *in vitro* in response to LH is shown in Figure 15. The highest testosterone secretory capacity/testis was noted in D28 and L28T3 hamsters, and lowest in D28T3 hamsters. Moreover, L28PTU and L28M hamsters had a significantly reduced capacity compared to L28, D28, and L28T3 hamsters. All treatment groups met the minimum sample size (n=4) except L28T3 (n=3).

Testicular androstenedione secretory capacity of the testis *in vitro* in response to LH stimulation is shown in Figure 16. The highest concentration of androstenedione in hamsters was found in the L28 treatment group and the lowest were in theD28T3 and L28PTU treatment groups. All treatment groups met the minimum sample size (n=4) except L28T3 (n=3).

The androgen testicular secretory capacity per gram of testis (shown in Table 4) was calculated from the amount of androgen secreted by the testis divided by the testis weights. These results show that the androgen secretory capacity per testis and per gram of testis follow the same trends.These values are for reference purposes only and will not be discussed further.

Results of the serum thyroxine levels are shown in Figure 17.Treatment groups that were given T3 were not included because of limited serum samples. The highest

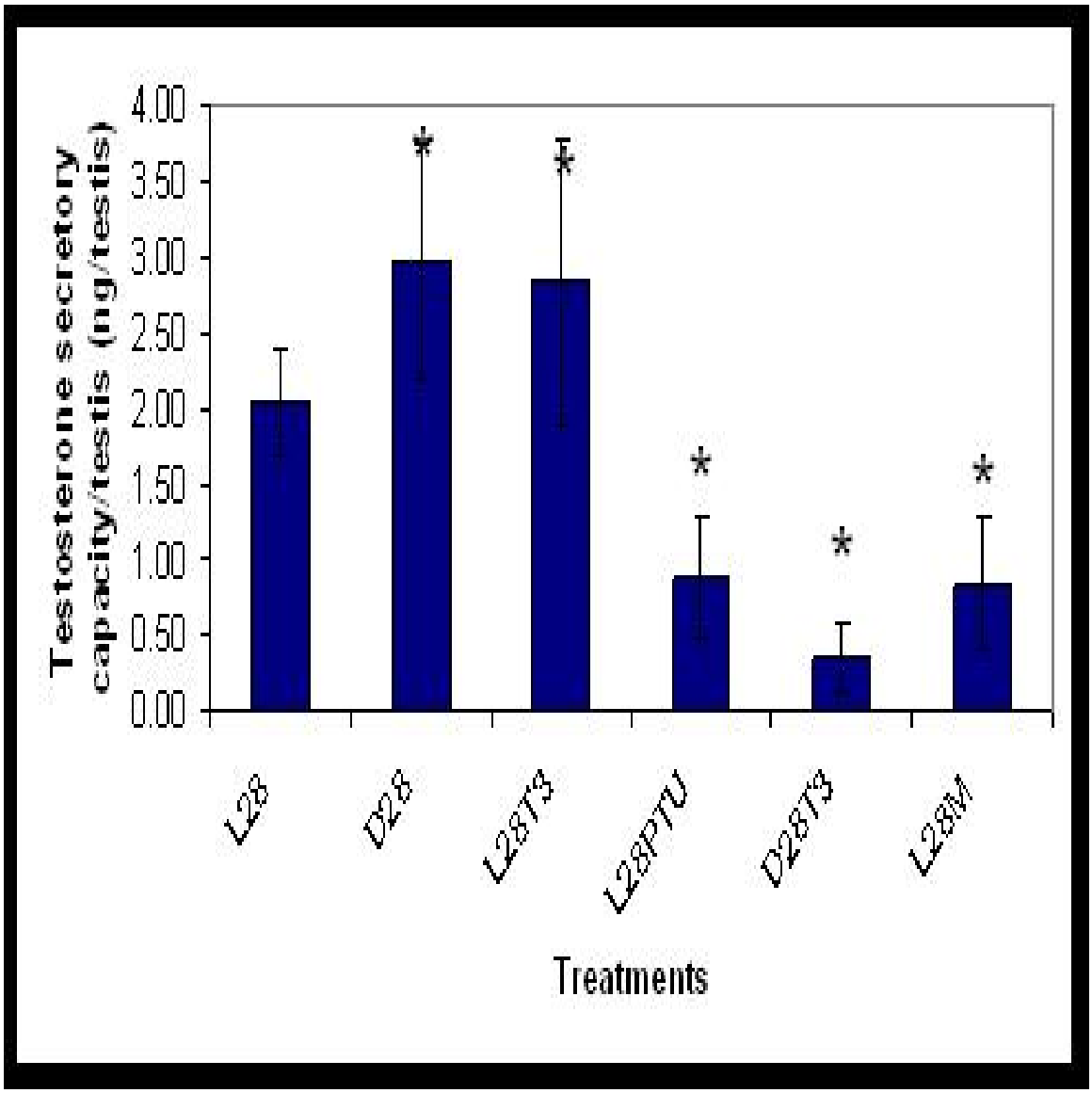

Asterisk (*) indicates a significant difference (p< 0.05) from L28 hamsters.

Figure 15: Testosterone Secretory Capacity perTestis (ng/testis)

Radioimmunoassay.

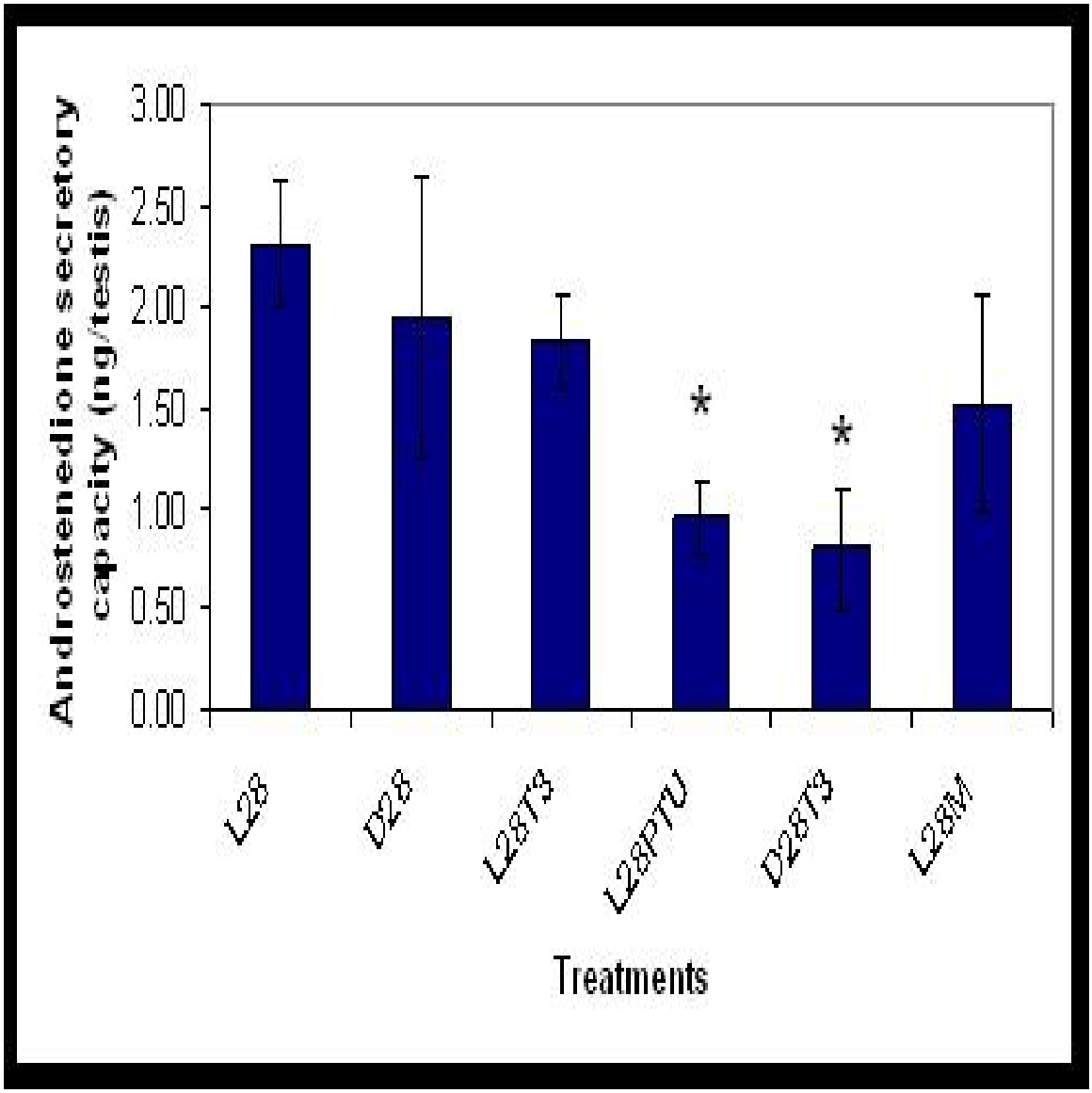

Asterisk (*) indicates a significant difference (p< 0.05) from L28 hamsters.

Figure 16: Androstenedione Secretory Capacity per Testis (ng/testis)

Radioimmunoassay

Table 4: Androgen Secretory Capacity per Gram of Testis (ng)

Parameter	L28	D28	L28T3	L28PTU	D28T3	L28M
Testosterone secretory capacity per gram of testis	5.1	7.5	10.9	4.0	1.1	2.1
Androstenedione secretory capacity per gram of testis	5.8	4.9	7.1	4.4	2.5	3.9

Statistics were not preformed on this data

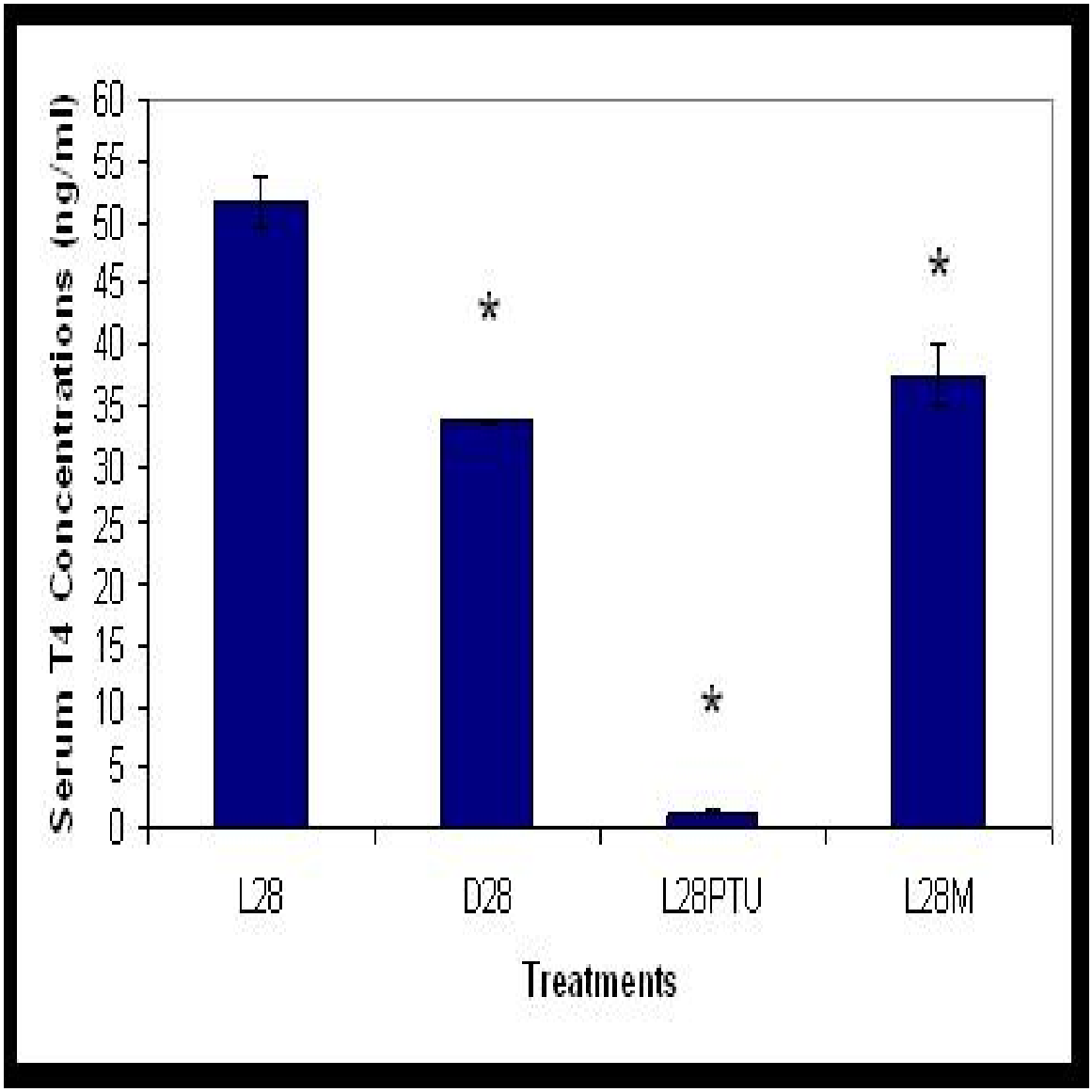

Asterisk (*) indicates a significant difference (p< 0.05) from L28 hamsters.

Figure 17: Serum Thyroxine Concentrations (ng/ml) Radioimmunoassay

concentrations of T4 were found in L28 hamsters and the lowest concentrations of T4 were found in the L28PTU treatment group.Hamsters in D28 and L28M treatment groups had significantly lower T4 levels when compared to the L28 treatment group. All treatment groups met the minimum sample size (n=4) except L28T3 (n=3).

Results of the serum melatonin levels are shown in Figure 18. The lowest melatonin concentrations were found in the L28 treatment group and the highest were found in the L28PTU treatment group. Interestingly, the latter values were more than 10-fold greater when compared to the melatonin levels in L28M hamsters. Significance was not included because of the small sample size.

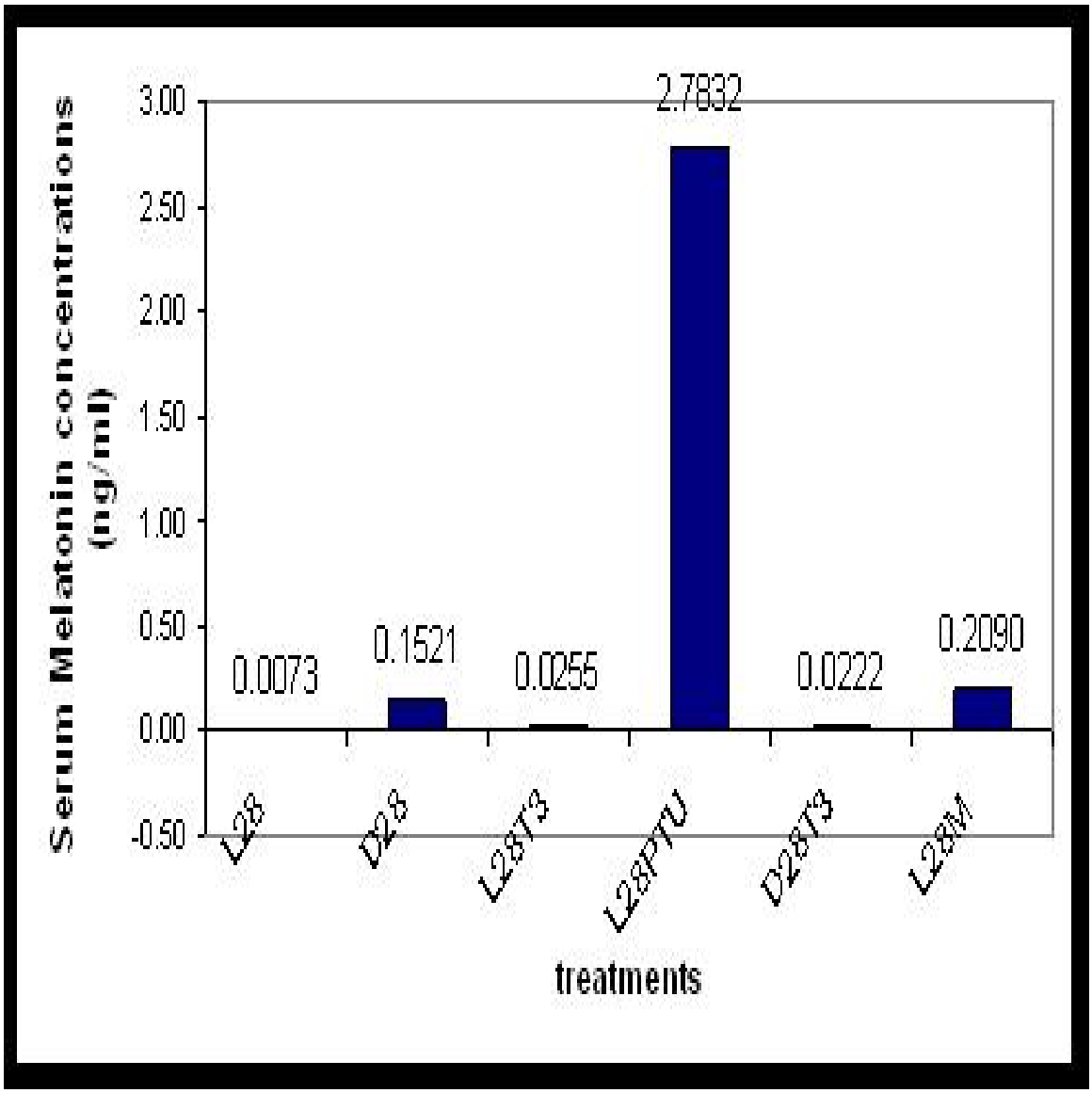

Significance is not included due to small sample size.

Figure 18: Serum Melatonin Concentrations (ng/ml) Radioimmunoassay

CHAPTER IV

DISSCUSSION

Postnatal Leydig stem cell differentiation has not been studied in the Syrian Golden hamster (*Mesocricetus auratus*), a seasonal breeder. The majority of published research on Leydig cells in hamsters focuses on adult males (2,3,4,5,6). The differentiation and maturation of Leydig cells has been studied to some extent in the rat (7, 9, 10, 11, 12) and the mouse (42). It is reported that this process in hamsters closely follows the development of the Sertoli cells and the germ cells (43). Based on the literature, it is logical to hypothesize that light could have an important regulatory role in the onset of postnatal Leydig cell differentiation in the hamster.

Results of the present study showed that hamsters raised under 12 hours light: 12 hours dark and supplemented with melatonin (LD28M) were the heaviest (87.5 g) of all treatment groups followed by hamsters raised under 1 hour light:23 hours dark (D28) (Figure 4). The results show that the L28M treatment group and D28 treatment group, an induced hibernation group, have high serum melatonin levels, as shown in Figure 18. The high melatonin levels in D28 hamsters can be attributed to the lack of light that would stimulate output of melatonin from the pineal gland (24). The L28M treatment group received melatonin supplementation that was injected to the mother (15mg/kg bodyweight) every two days at about 9am. This high dose was to ensure that the melatonin would pass through the milk to the offspring (24). Exogenous melatonin treatment, above physiological levels, has been shown to decrease serum PRL levels in lactating rats (44); it has been shown that reduced PRL levels in lactating rats decrease

milk leptin levels and milk fat content (45). These two groups (D28 and L28M) were in a simulated hibernation state and gained weight, which is supported by Pitrosky et al (46). It has been shown that short photoperiods (SD) cause an increased accumulation of interscapular brown adipose tissue (BAT) (46). Therefore, the increased body weights of the hamsters in L28M and D28 treatment groups may be attributed to this phenomenon, and was supported by our observation of increased abdominal adipose tissue during the tissue harvesting process. The increase in body weight in the L28M treatment group may be attributed to melatonin induced BAT accumulation and the normal feeding patterns of animals maintained in LD. In contrast, L28PTU hamsters had the highest circulating levels of melatonin, and the lowest bodyweights. This observation agrees with results of Morin et al (47), who observed reduced food intake in PTU-treated hamsters. In addition, Hapon et al. (48) demonstrated a reduced availability of mammary lipid (including cholesterol and triglycerides) in lactating PTU treated female rats, and could complicate the development of the offspring.

Propylthiouracil (PTU), a ringed structure with a molecular weight of 170.23 (Sigma-Aldrich.com), is a goitrogen and produces a hypothyroid state in many species (10, 49). In rats, PTU has been shown to cause a decrease in body, testis, and accessory sex organ weights (10, 49). In the rat, it has been shown that thyroid hormone is involved in many processes, including the onset of Leydig stem cell differentiation in the postnatal testes (10), regulation of gap junctions in the testis and epididymis (50), regulation of cerebellar protein expression in the central nervous system (51), bone remodeling via receptors on the osteoblasts and influential control of concentrations of nerve growth factor and norepinephrine in bones (52). It is suggested that PTU accumulates in the

thyroid follicular cells in high concentrations and causes damage which impairs thyroxine production (53) and iodine uptake and thyroid enzymatic activity (47, 48). However, the complete mode of action of PTU is not completely understood. Therefore, it is difficult to explain why the L28PTU, which had the highest serum melatonin levels, did not show increased body weight or accumulation of BAT as seen in D28 and L28M hamsters. The bodyweights of L28 (63.7g), L28T3 (60.6g), and D28T3 (66.4g) hamsters were not significantly different. Interestingly, hamsters treated with T3 (L28T3 and D28T3) had comparable weights to the other groups. The groups that were supplemented with T3 nursed from a female that was given injections of T3. It has been shown that lactating T3 treated rats have increased milk production with higher concentrations of lipids that lead to increased growth in the pups (54).

Hamsters supplemented with T3 (i.e. in L28T3 and D28T3 treatment groups) proved to be challenging to work with due to maternal cannibalism. In previous studies, rat pups that were individually injected with daily T3 became hyperthyroid (10, 22, 55, 56). This technique was not successful in producing hyperthyroid hamster pups because the mother usually consumed the entire litter by the following morning. Attempts were then made to inject mothers with T3 every 2 days but the pups became severely emaciated and rarely lived up to 28 days. Finally, T3 was administered to the mother every four days (57) to produce hyperthyroid pups. Mothers continued to cannibalize pups but with less frequency. Discussion of the L28T3 group in the current project is solely to show trends but the sample size is smaller than our minimum sample size requirements. This is especially true for the hormone assays, because of the difficulty in

obtaining hyperthyroid pups. We are presently working to fulfill the sampling adequacy requirements to confirm the observations on hormone data.

Findings on the testis weights in these hamsters can be explained by the absolute volumes of the seminiferous tubules (ST) per testis in Table 2. L28PTU hamsters have the lowest testis weights, which agree with published results that show neonatal PTU treatment results in reduced testis weight around 3 weeks of postnatal life in the rat (12). The observed decrease in testis weights in L28PTU hamsters was due to the decreased absolute volume of ST in these animals; 86% of testis volume density is ST as shown in Table 1. Although the absolute volume of Leydig cells in L28PTU hamsters is the lowest compared to all other experimental groups, it is unlikely that a significant reduction in weight of the testes was caused by this change on the absolute volume of Leydig cells, since this parameter does not contribute significantly to the overall weight or the testis (see Figure 12).

The results of the total Leydig cell numbers per testis for L28 treatment group was 12.8×10^6 and is significantly higher than those of the D28 treatment group. This reduction in Leydig cell numbers in hamsters in the D28 group agrees with the findings on reductions in Leydig cell numbers is adult male hamsters that are exposed to SD (2,3,4,5). The L28T3 (13×10^6) animals share comparable Leydig cell numbers with L28 control hamsters. However, it is reported that daily T3 injections to neonatal rats cause increased proliferation of mesenchymal cells and enhance their differentiation to Leydig cells (7, 10). The total Leydig cell numbers per testis of the L28T3 hamsters were significantly greater than L28PTU (4.6×10^6), L28M (4.6×10^6) and D28T3 (4.1×10^6) hamsters; but not greater than L28 hamsters. The exact cause of the reduction of Leydig

cells numbers in treatment groups with increased melatonin levels and lower T4 levels, and apoptosis, has not been addressed in the literature. This difference in the response of Leydig cell differentiation in the hamster, compared to the rat, can be attributed to the frequency and mode of T3 treatments in the two studies; daily T3 injections to rat pups versus T3 injections every four days to the nursing mothers.

There is no information available in the literature in relation to the absolute volumes of cellular components in the prepubertal hamster testis to compare with the present findings; therefore, these findings are primarily for reference only. The absolute volume of the seminiferous tubules per testis was significantly larger in L28M (323.4 mm^3), D28 (322.9 mm^3), and L28 (291.6 mm^3) treatment groups, in comparison to the L28PTU (187.8 mm^3) treatment group. Buzzard et al. (58) have shown that hypothyroid rats experience a delay in Sertoli cell differentiation, which supports our findings; Sertoli cells make up most of the seminiferous tubules of the prepubertal testes, and seminiferous tubules make up the majority of the testis weight. However, L28M and D28 hamsters had significantly lower absolute volumes of Leydig cells compared to the L28 treatment group, which can be explained by the presence of little or no postnatally-differentiated Leydig cells. This observation can be due to reduced T4 and increased melatonin levels in these hamsters. Interestingly, L28T3 hamsters have a lower absolute volume of seminiferous tubules, but are almost identical in value to the Leydig cell volumes of the L28 hamsters; they have decreased melatonin levels and increased T4 levels. The absolute volume of the seminiferous tubules and Leydig cells of L28PTU animals was considerably less than for other treatment groups except the Leydig cells of L28M, which was consistent for both L28PTU and L28M treatment groups. One study examined the

absolute volume of hamster Leydig cell organelles and suggested that the lack of organelles resulted in a decrease in the cellular activity in the regressed testis (59). Therefore, decreased androgen production occurred, which agrees with the present results. There is a reduction in the absolute volume of Leydig cells per testis in all treatment groups when compared to the L28 treatment group, except in the L28T3 treatment group. This suggests that L28T3 hamsters were able to maintain the adult Leydig cell population and numbers, and an increased testicular testosterone secretory capacity compared to L28 hamsters. The observations are supported by studies seen in the rat (9).

Comparison of LH-stimulated testosterone secretory capacity per testis *in vitro* revealed that D28 animals had the highest testosterone secretory capacity per testis when compared to the other treatment groups, even though their total Leydig cell numbers per testis were much lower than both the L28 and L28T3 treatment groups. These findings in the pre-pubertal hamster are different from what has been found in adult male hamsters (19). Frungieri et al. (19) found that adult male hamsters housed in a short day photoperiod (6L:18D) had significantly lower circulating testosterone levels than those in a long photoperiod (14L:10D),which can be attributed to the atrophy of mature adult Leydig cells in such testes due to the reduced photoperiod. Careful examination of the Leydig cells in D28 hamsters of the present study revealed that the testicular interstitium was abundant in volume with fetal Leydig cells which are known to produce increased amounts of testosterone (70-100x more) compared to mature adult Leydig cells (6,7,9). Results of the present investigation revealed that the Leydig cells in D28 hamsters were primarily the fetal Leydig cells, which have been shown to produce more testosterone

than mature adult Leydig cells (6,7,9). Therefore, it appears that, even in the arrest of postnatal adult Leydig cell differentiation in D28 hamsters, fetal Leydig cells have the capacity to maintain sufficient amounts of androgens during the pre-pubertal period that is needed to prime the brain, to function as a male in the adult life (6). However, D28T3 animals had a significantly lower testosterone secretory capacity than D28 animals. It is possible to attribute this reduced testosterone secretory capacity to the atrophy of fetal Leydig cells in response to the exogenous T3 treatment, as shown in the present study as well as a previous study in the rat (56). The L28T3 treatment group had the second highest testicular secretory capacity per testis of testosterone (2.84ng/testis), and this agrees with previous findings on increased androgen secretory capacity in T3 treated rats (56).

It is also important to note that, statistically, there was no difference between L28M (0.83ng/testis) and L28PTU (0.88ng/testis) treatment groups for testicular secretory capacity for testosterone. The reduced testosterone secretory capacity *in vitro* for testicular tissue of L28PTU hamsters agrees with what has been published in the rat (6, 7, 12) where hypothyroidism arrests the onset of Leydig cell differentiation (10,12). It has also been reported that melatonin inhibits testosterone secretion by the Leydig cells in sexually mature hamsters (30) and testicular regression by a reduction of LH receptors because of reduced PRL (2, 21). The L28PTU and L28M hamsters had the highest circulating melatonin levels; therefore, the reduced testosterone secretory capacity of testicular tissue in these hamsters can be attributed at least in part to this reason. To our knowledge, the inhibitory effect on testicular steriodogenic function by melatonin in prepubertal hamsters has not been investigated previously.

Frungieri et al. (30) has demonstrated that melatonin reduced basal and hCG-stimulated production of testosterone in LP adult hamsters. Champney (31) also noted reduced serum testosterone levels in male hamsters that received daily melatonin injections. Valenti et al. (60, 61) stated that, in the rat, GnRH-induced testosterone secretion is reduced by melatonin by a decrease in GnRH-dependant intracellular calcium release, reduced 17-20-desmolase activity, reduced adenylate cyclase activity, and an increase in 17-hydroxyprogesterone. Niedziela et al. (62) suggested that adenylate cyclase activity is involved, using Siberian hamsters, because melatonin can reduce forskolin stimulated testosterone secretion, which acts via the cAMP signaling pathway. Furthermore, Redins et al. (28) suggest that melatonin may alter the ultra-structure of mouse Leydig cells, and down-regulate their ability to secrete steroids, by reduced nuclear and cellular component volumes.

Circulating melatonin levels were highest in the L28PTU hamsters, which also showed decreased testosterone secretory capacity of testicular tissue as well as reduced T4. In addition, L28PTU hamsters had the lowest circulating T4 levels out of all of the tested groups. The latter observations compare favorably with published literature in the rat (12). There was a significant difference in serum T4 levels between the D28 (33.7ng/ml) and L28 treatment groups, which agreed with the observations of Potterborg et al. (63) that indicated decreased thyroxine levels occur in adult male hamsters exposed to SD photoperiods. The L28M (37.4 ng/ml) treatment group had a significantly lower serum thyroxine level than the L28 treatment group but similar to the D28 treatment group. This suggested that exogenous melatonin supplementation may act through the same pathway as SD photoperiods. There is further evidence that indicates melatonin

directly affects Leydig cells, and that is the identification of melatonin subtype 1a receptors on hamster Leydig cells (30). This reduction of thyroxine in melatonin-treated animals follows the observations of Champney (31) with melatonin-injected adult male hamsters. It has been shown that exogenous melatonin reduces serum thyroid hormone (T3 and T4) levels but an increases thyroid stimulating hormone (TSH) levels simulating reduced photoperiods in rats (64). Hamsters in D28T3 and L28T3 treatment groups were not tested for T4 because of a limited number of samples.

Testicular androstenedione seretory capacity *in vitro* was highest in the control L28 hamsters (2.31 ng/testis), and we attribute this finding to the high number of postnatally differentiated Leydig cells present in their testes. As shown, D28 hamsters (1.95 ng/testis) have primarily fetal Leydig cells, which secrete an abundance of androgens including testosterone and androstenedione. The significantly lower androstenedione secretory capacity per testis in D28T3 animals could be attributed to the absence, or low counts, of newly formed adult Leydig cells (and atrophy of fetal Leydig cells) in these testes, as shown in the rat (9). The L28PTU treatment group had a significantly lower testicular androstendione secretory capacity than L28 control animals. The reduced testicular secretory capacity of androstenedione in the L28PTU group could be attributed to the absence, or reduced number, of postnatally differentiated Leydig cells, because of insufficient thyroid hormone as shown in the rat (9). There was also a reduction in testicular androstenedione secretory capacity in the L28M hamsters when compared to the L28 hamsters, but it was not significant due to the large standard error of the treatment group. Valenti et al. (65) observed decreased androstenedione levels in

response to melatonin supplementation in rats, which is due to a reduction of cAMP production and reduced enzymatic activity during steriodogenesis.

A pooled sample of serum from the L28M group was included in the radioimmunoassay (RIA) to act as an in-laboratory control for the melatonin assays. Most notably, the L28PTU treatment group (2.78 ng/ml) had the highest serum melatonin concentrations of all treatment groups, and agreed with findings in hamsters and rats that describe an interaction between thyroid hormone and melatonin concentrations (31,33,34). In rats, melatonin has been suggested to have a suppressive action on thyroid function (36).There have been studies that show hypothyroid human patients have higher serum concentrations of melatonin (66) to support the inverse relationship of melatonin and thyroid hormone. The D28 group had the next highest concentrations of melatonin due to the reduced photoperiod that stimulates secretion of melatonin from the pineal gland and was comparable to the L28M treatment group. The D28T3 treatment group had substantially lower serum melatonin concentrations than the D28 treatment group, possibly due to the T3 treatment. However, melatonin levels in D28T3 hamsters were comparable to those of the L28T3 group but greater than the L28 treatment group. The increased melatonin levels in D28, L28PTU, L28M, D28T3, and L28T3 compared to the L28 treatment group could be attributed to a regulatory mechanism in response to exogenous T3 treatment. However, to date nothing has been published on the thyroid hormone-melatonin interaction in the regulation of postnatal Leydig cell differentiation in the hamster. The findings of the present investigation suggest that increased thyroid hormones and decreased melatonin levels positively regulate Leydig cell differentiation.

Conversely, decreased thyroid hormones and increased melatonin levels negatively regulate the process of postnatal Leydig cell differentiation.

There is strong evidence from the present study that there is an inverse relationship between melatonin and thyroid hormone in regulating the differentiation of postnatal Leydig cell population in hamsters. The experimental groups that have increased serum thyroid hormone concentrations, which have increased numbers of Leydig cells per testis, also demonstrate a low serum melatonin concentration. The L28 and L28T3 treatment groups had the highest number of Leydig cells per testis suggesting that Leydig cell differentiation has been positively regulated by these conditions. Additionally, the experimental groups that had increased serum melatonin concentrations, and low serum levels of thyroid hormone (D28, L28PTU, and L28M), had the lowest number of Leydig cells per testis, which suggests that Leydig cell differentiation is negatively regulated by these conditions. Based on these findings, a mechanism for the relationship between melatonin and thyroid hormones on postnatal Leydig cell differentiation is proposed in Figure 19.

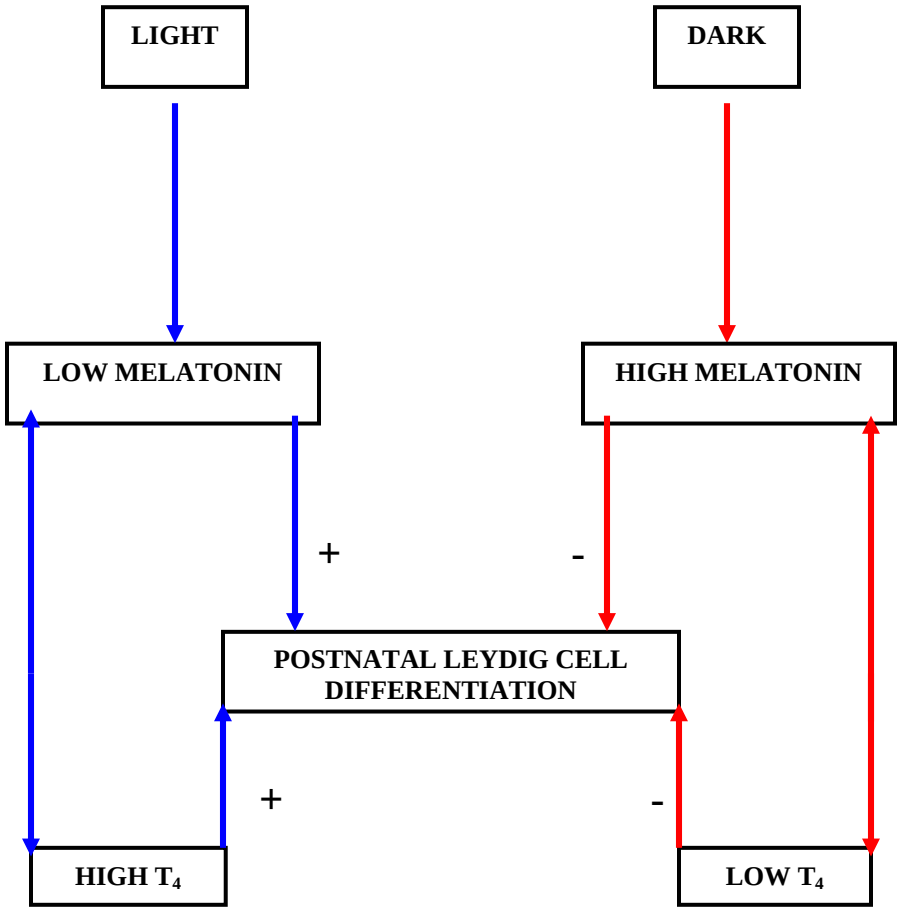

Figure 19: Regulation of Postnatal Leydig Cell Differentiation by Melatonin and T4.

LIST OF REFERENCES

1. Setchell BP, Maddocks S, Brooks, DE. Anatomy, Vasculature, Innervation, and fluids of the Male Reproductive Tract. In: Knobil E, Neill JD, editors. The Physiology of Reproduction, Volume 1, 2nd ed. New York: Raven Press; 1994. p. 1063-1079.

2. Bartke A, Hikim APS, Russell LD. Leydig Cell Structure and Function in Seasonal Breeders. In: Payne AH, Hardy MP, Russell LD, editors. The Leydig Cell. Vienna IL: Cache River Press; 1996. p 431-450

3. Hardy MP, Mendis-Handagama SMLC, Zirkin BR, Ewing LL. Photoperiodic variation of Leydig cell numbers in the testis of the golden hamster: a possible mechanism for their renewal during recrudescence. J Exp Zool 1987;244:269-276

4. Sinha HAP, Bartke A, Russell LD. Morphometric studies on hamster testes in gonadally active and inactive states: light microscope findings. Biology of Reproduction 1988;39:1225-1237

5. Mendis-Handagama SMLC, Zirkin BR, Ewing LL. Comparison of components of the testis interstitium with testosterone secretion in hamster, rat and guinea pig testes perfused in vitro. Am J Anat 1988;181:12-22

6. Mendis-Handagama SMLC, Ewing LL. Sources of error in the estimation of Leydig cell numbers in control and atrophied mammalian testes. J Microscop 1990;159:73-82.

7. Mendis-Handagama SMLC, Ariyarante HBS. Differentiation of the Adult Leydig Cell Population in the Postnatal Testis. Biology of Reproduction 2001;65:660-671

8. Byscove AG. Differentiation of mammalian embryonic gonad. Physiol Rev 1986;66:77-112

9. Ariyarante SHB, Mendis-Handagama SMLC. Changes in the Testis Interstitium of Sprague Dawley Rats from Birth to Sexual Maturity. Biology of Reproduction 2000;62:680-690

10. Mendis-Handagama SMLC, Ariyaratne HBS. Effects of thyroid hormones on Leydig cells in the postnatal testis. Histol Histopathol 2004;19:985-997

11. Ariyaratne S, Kim I, Mills N, Mason I, Mendis-Handagama SMLC. Effects of Ethane Dimethane Sulfonate on the Functional Structure of the Adult Rat Testis. Archives of Andrology 2003; 49:313-326.

12. Mendis-Handagama SMLC, Ariyaratne HBS, Teunissen can Manen KR, Haupt RL. Differentiation of Adult Leydig Cells in the Neonatal Rat Testis Is Arrested by Hypothyroidism. Biology of Reproduction 1998;59:351-357

13. Caillol M, Rossano B, Martinet L. Effect of Short Photoperiods on the *in vitro* GnRH Release by Hypothalamic Explants in Intact and Castrated Male Syrian Hamsters: Relation to Testicular Regression and Recrudescence. J Neuroendocrinology 1998;10:343-351

14. Brown DI, Garyfallou VT, Urbanski HF. Photoperiodic modulation of GnRH mRNA in the male Syrian hamster. Molecular Brain Research 2001;89:117-125

15. Kawazu S, Kishi H, Saita E, Jin W, Suzuki AK, Watanabe G, Taya K. Inhibin Secretion in the Golden Hamster (*Mesocricetus auratus*) Testis During Active and Inactive States of Spermatogenesis Induced by the Restriction of Photoperiod. J Reprod. Dev. 2003; 49:87-97

16. Jin W, Herath CB, Yoshida M, Arai KY, Saita E, Zhanquan S, Ren L, Watanabe G, Groome NP, Taya K. Inhibin B Regulating Follicle-Stimulating Hormone Secretion During Testicular Recrudescence in the Male Golden Hamster. J Androl 2002;23:845-853

17. Kishi H, Itoh M, Wada S, Yukinari Y, Tanaka Y, Nagamine N, Jin W, Watanabe G, Taya K. Inhibin is an important factor in the regulation of FSH secretion in the adult male hamster. Am J Physiol Endocrinol Metab 200;278:E744-E751

18. Sriraman V, Jagannadha Rao A. Evaluation of the role of FSH in regulation of Leydig cell function during different stages of its differentiation. Mol Cell Endocrinol. 2004 Sep;224:1-2:73-82

19. Frungieri MB, Gonzalez-Calvar SI, Bartke A, Calandra RS. Influence of age and photoperiod on steroidogenic function of the testis in the golden hamster. International j andrology 1999;22:243-252

20. Frungieri MB, Gonzalez-Calvar SI, Rubio M, Ozu M, Lustig L, Calandra RS. Serotonin in Golden Hamster Testes: Testicular Levels, Immunolocalization and Role during Sexual Development and Photoperiodic Regression-Recrudescence Transition. Neuroendocrinology 1999; 69:299-308

21. Johnston JD, Stirland JA, White MRH, Davis JRE, Loudin ASI. Heterogeneous regulation of individual lactotroph cells by photoperiod in the Syrian hamster *(Mesocricetus auratus)* Ceneral and Comparative Endocrinology 2003;134:182-186

22. Carr AJF, Johnston JD, Semikhodskii AG, Nolan T, Cagampang FRA, Stirland JA, Loudon ASI. Photoperiod Differentially Regulates Circadian Oscillators in Central and Peripheral Tissues of the Syrian Hamster. Current Biology 2003;13:1543-1548

23. Lincoln GA, Andersson H, Loudon A. Clock genes in calendar cells as the basis of annual timekeeping in mammals- a unifying hypothesis. J Endocrinology 2003; 179:1-13

24. Davis FC. Melatonin: role in development. J Biol Rhythms. 1997 Dec;12:6:498-508

25. Gunduz B, Stetson MH. Effects of photoperiod, pinealectomy, and melatonin implants on testicular development in juvenile Siberian hamsters (Phodopus sungorus). Biol Reprod. 1994 Dec;51:6:1181-7.

26. Edmonds KE, Stetson MH. Pineal gland and melatonin affect testicular status in the adult marsh rice rat (Oryzomys palustris). Gen Comp Endocrinol. 1995 Sep;99:3:265-74

27. Ojeda SR, Urbanski HF. Puberty in the Rat. In: Knobil E, Neill JD editors. The Physiology of Reproduction 2nd ed. New York; 1994. p. 387-388

28. Redins CA, Redins GM, Novaes JC. The effects of treatment with melatonin on the ultrastructure of mouse Leydig cells: a quantitative study. Braz J Biol. 2002 Aug;62:3:517-23

29. Saez JM, Lejeune H. Regulation of Leydig Cell Functions by Hormones and Growth Factors Other Than LH and IGF-1. In: In: Payne AH, Hardy MP, Russell LD, editors. The Leydig Cell. Vienna IL: Cache River Press; 1996. p. 386

30. Frungieri MB, Mayerhofer A, Zitta K, Pignataro OP, Calandra RS, Gonzalez-Calvar SI. Direct Effect of Melatonin on Syrian Hamster Testes: Melatonin Subtype 1a Receptors, Inhibition of Androgen Production, and Interaction with the Local Corticotropin-Releasing Hormone System. Endocrinology 2005; 146:1541-1552.

31. Champney TH. Reductions in Hamster Serum Thyroxine Levels by Melatonin Are Not Altered by Changes in Serum Testoterone. General and Comparative Endocrinology 2001;123:121-126

32. Hoover PA, Vaughan MK, Little JC, Reiter RJ. N-methyl-D-aspartate does not prevent effects of melatonin on the reproductive and thyroid axes of male Syrian hamsters. J Endocrinol. 1992;133(1):51-8

33. Vriend J, Borer KT, Thliveris JA. Melatonin: its antagonism of thyroxine's antisomatotrophic activity in male Syrian hamsters. Growth. 1987;51(1):35-43.

34. Vriend J, Thliveris JA. Effects of pinealectomy and melatonin administration on thyroid follicles of blind Syrian hamsters. Anat Rec. 1985 Jan;211:1:29-33.

35. Vriend J, Sheppard MS, Borer KT. Melatonin increases serum growth hormone and insulin-like growth factor I (IGF-I) levels in male Syrian hamsters via hypothalamic neurotransmitters. Growth Dev Aging. 1990 Winter;54:4:165-71.

36. Baltaci AK, Mogulkoc R, Kul A, Bediz CS, Ugur A. Opposite effects of zinc and melatonin on thyroid hormones in rats. Toxicology. 2004 Jan 15;195:1:69-75.

37. Petterborg LJ, Rudeen PK. Effects of daily afternoon melatonin administration on body weight and thyroid hormones in female hamsters. J Pineal Res. 1989;6:4:367-73.

38. Teerds KJ, de Rooij DG, deJong FH, Van Haaster LH. Development of the adult-type Leydig cell population in the rat is affected by neo-natal thyroid hormone levels. Biol Reprod 1998:59:344-350

39. Karbownik M, Gitto E, Lewinski A, Reiter RJ. Induction of lipid perozidation in hamster organs by the carcinogen cadmium: amelioration by melatonin. Cell Biology and Toxicology 2001;17:33-40

40. Sterio DC. The unbiased estimation of numbered and sizes of arbitrary particles using the disector. Journal of Microscopy 1984; 134:127-136

41. Vaughan GM. New sensitive serum melatonin radioimmunoassay employing the Kennaway G280 antibody: Syrian hamster morning adrenergic response. Journal of pineal research 1993;15:2:88-103

42. O'Shaughnessy PJ, Baker P, Sohnius U, Haavisto AM, Charlton HM, Huhtaniemi I. Fetal development of Leydig cell activity n the mouse is independent of pituitary gonadotroph function. Endocrinology.1998; 139: 1141-1146.

43. Miething A., The establishment of spermatogenesis in the seminiferous epithelium of the pubertal golden hamster *Mesocricetus auratus*. Adv Anat Embryol Cell Biol. 1998;140:1-92.

44. Juszczak M, Stempniak B. The Effect of Melatonin on Suckling-Induced Oxytocin and Prolactin Release in the Rat. Brain Research Bulletin. 1997;44:3:253-258.

45. Bonomo IT, Lisboa PC, Passos MC, Pazos-Moura CC, Reis AM, Moura EG. Prolactin inhibition in lactating rats changes leptin transfer through the milk. Horm Metab Res. 2005 Apr;37(4):220-5.

46. Pitrosky B, Delagrange P, Rettori MC, Pevet P. S22153, a melatonin antagonist, dissociates different aspects of photoperiodic responses in Syrian hamsters. Behav Brain Res. 2003 Jan 22;138:2:145-52.

47. Morin LP, Gavin ML, Ottenweller JE. Propylthiouracil causes phase delays and circadian period lengthening in male and female hamsters. Am J Physiol. 1986 Feb;250(2 Pt 2):R151-60.

48. Hapon MB, Varas SM, Jahn GA, Gimenez MS. Effects of hypothyroidism on mammary and liver lipid metabolism in virgin and late-pregnant rats. J Lipid Res. 2005 Jun;46:6:1320-30. Epub 2005 Mar 1.

49. Rao JN, Liang JY, Chakraborti P, Feng P., Effect of thyroid hormone on the development and gene expression of hormone receptors in rat testes in vivo. J Endocrinol Invest. 2003 May;26:5:435-43.

50. St-Pierre N, Dufresne J, Rooney AA, Cyr DG. Neonatal hypothyroidism alters the localization of gap junctional protein connexin 43 in the testis and messenger RNA levels in the epididymis of the rat. Epub 2002 Oct 30 Biol Reprod. 2003 Apr;68:4:1232-40.

51. Li GH, Post J, Koibuchi N, Sajdel-Sulkowska EM. Impact of thyroid hormone deficiency on the developing CNS: cerebellar glial and neuronal protein expression in rat neonates exposed to antithyroid drug propylthiouracil. Cerebellum. 2004;3:2:100-6

52. Yao M, Dooley PC, Schuijers JA, Grills BL The effects of hypothyroidism on nerve growth factor and norepinephrine concentrations in weight-bearing and non-weight-bearing bones of rats. J Musculoskelet Neuronal Interact. 2004 Sep;4:3:319-24.

53. Mattioli F, Martelli A, Garbero C, Gosmar M, Manfredi V, Paolo Mattioli F, Torre G, Brambilla G. DNA fragmentation and DNA repair synthesis induced in rat and human thyroid cells by four rat thyroid carcinogens. Toxicol Appl Pharmacol. 2005 Mar 1;203:2:99-105.

54. Quevedo-Corona L, Franco-Colin M, Caudillo-Romero M, Pacheco-Rosado J, Zamudio-Hernandez S, Racotta R. 3,5,3,'Triidothyrionine administered to rat dams during lactation increases mike yield and triglyceride concentration and hastens pups growth. Life Sciences. 2000; 66: 21: 2013-2021.

55. Canavan JP, Holt J, Easton J, Smith K, Goldspink DF. Thyroid-induced changes in the growth of the liver, kidney, and diaphragm of neonatal rats. J Cell Physiol. 1994 Oct;161:1:49-54.

56. Ariyaratne HB, Mendis-Handagama SM, Mason JI. Effects of tri-iodothyronine on testicular interstitial cells and androgen secretory capacity of the prepubertal Rat. Biol Reprod. 2000 Aug;63:2:493-502

57. Del Prado M, Da Costa TH, Williamson DH. Effects of tri-iodothyronine administration on the disposal of oral [1-14C]triolein, lipoprotein lipase activity and

lipogenesis in the rat during lactation and on removal of the litter. Biochem J. 1994 Jul 15;301 Pt 2:495-501.

58. Buzzard JJ, Wreford NG, Morrison JR. Thyroid hormone, retinoic acid, and testosterone suppress proliferation and induce markers of differentiation in cultured rat sertoli cells. Endocrinology. 2003 Sep;144:9:3722-31.

59. Hikim AP, Amador AG, Bartke A, Russell LD. Structure/function relationships in active and inactive hamster Leydig cells: a correlative morphometric and endocrine study. Endocrinology. 1989 Oct;125:4:1844-56.

60. Valenti S, Thellung S, Florio T, Giusti M, Schettini G, Giordano G. A novel mechanism for the melatonin inhibition of testosterone secretion by rat Leydig cells: reduction of GnRH-induced increase in cytosolic Ca2+. J Mol Endocrinol. 1999 Dec;23:3:299-306

61. Valenti S, Giusti M. Melatonin participates in the control of testosterone secretion from rat testis: an overview of our experience. Ann N Y Acad Sci. 2002 Jun;966:284-9.

62. Niedziela M, Lerchl A, Nieschlag E. Direct effects of the pineal hormone melatonin on testosterone synthesis of Leydig cells in Djungarian hamsters (Phodopus sungorus) in vitro. Neurosci Lett. 1995 Dec 15;201:3:247-50.

63. Petterborg LJ, Vaughan MK, Johnson LY, Champney TH, Reiter RJ. Modification of testicular and thyroid function by chronic exposure to short photoperiod: a comparison in four rodent species. Comp Biochem Physiol A. 1984;78:1:31-4.

64. Mirunalini S, Subramanian P. Temporal oscillations of thyroid hormones in long term melatonin treated rats. Pharmazie. 2005 Jan;60:1:52-6.

65. Valenti S, Guido R, Giusti M, Giordano G. In vitro acute and prolonged effects of melatonin on purified rat Leydig cell steroidogenesis and adenosine 3',5'-monophosphate production. Endocrinology. 1995 Dec;136:12:5357-62.

66. Rojdmark S, Berg A, Rossner S, Wetterberg L. Nocturnal melatonin secretion in thyroid disease and in obesity. Clin Endocrinol *Oxf*. 1991 Jul;35:1:61-5.

VITA

Michael William Hance was born in Staten Island, NY on April 17, 1974. Both of his parents were in the Armed Services allowing the family to live overseas. In 1981, they moved to Clarksville, TN. Michael attended Woodlawn elementary school, New Providence Middle school, and Northwest High school from which he graduated from high school in May 1993. Michael enlisted in the Armed Forces from April 1994 to April 2000. He started at The University of Tennessee, Knoxville in 1997 and completed a B.S. in biochemistry, cellular and molecular biology in May 2001. During the course of his studies for his M.S., Michael met an extraordinary person, Emily Williams, who helped him to balance life and he married her in December of 2004.

Following the completion of his M.S. in Comparative and Experimental Medicine in December 2005, Michael will be pursuing his doctorate in Comparative and Experimental Medicine at The University Of Tennessee, College Of Veterinary Medicine.