To the Graduate Council:

I am submitting herewith a thesis written by Lee Anne Cope entitled "Reproductive Anatomy of Adult Female Emus (Dromaius novaehollandiae)". I have examined the final copy of this thesis for form and content and recommend that it be accepted in partial fulfillment of the requirements for the degree of Master of Science, with a major in Animal Science.

Robert W. Henry, Major Professor

We have read this thesis
and recommend its acceptance.

Teresa K. Rowles

James T. Blackford

Accepted for the Council:

Associate Vice Chancellor and
Dean of The Graduate School

Reproductive Anatomy of Adult Female Emus
(*Dromaius novaehollandiae*)

A Thesis Presented
for the
Master of Science Degree

The University of Tennessee, Knoxville

Lee Anne Cope
December 1996

AS-VET-MED.
Thesis
96
.C66

DEDICATION

This thesis is dedicated to my parents

Mr. Charles Lee Cope

and

Mrs. Marianna Morrow Cope

who have always given me their

never ending love and support.

ACKNOWLEDGEMENTS

There are many people to whom I am grateful for making this thesis possible and my education in the Department of Animal Science a wonderful experience. I am especially grateful to Dr. R. W. Henry, Dr. J. T. Blackford and Dr. T. K. Rowles for your infinite words of wisdom, encouragement and never ending patience.

I would also like to express my sincere appreciation and admiration to Dr. F. W. Harrison. A wonderful teacher and mentor who challenged me to do my best and was always there to give me guidance and support.

ABSTRACT

The following investigation was conducted in order to describe the morphology of the female reproductive system of an adult, two year old physically mature, but reproductively inactive female emu (Dromaius novaehollandiae). The dissections focused on the morphology of the reproductive tract of the female emu including the vasculature and the innervation of the reproductive organs.

For this investigation, five female emus (Dromaius novaehollandiae) were obtained. Three were two years old, physically mature, but reproductively inactive. These emus were anesthetized and an endoscopic exam was done and a video recorded. Two were yearlings and not physically or reproductively mature. The emus were prepared for embalming via intravascular injection of 10% formalin and submerged in a 5% formalin solution. Two days after fixation, colored latex was injected into the arteries and veins to aid in the visualization and dissection of the vasculature of the reproductive tract.

The reproductive tract of the adult female emu consisted of an ovary and oviduct situated on the left side of the abdominal cavity. The left ovary was a dark brownish-black color with the ventral surface of the ovary covered in follicles. The ovary was medial to the spleen

and associated with the ventral surface of the cranial and middle lobes of the left kidney.

The left oviduct was a nearly straight tube that extended from the cranial extent of the left ilium (which corresponded to the thoracolumbar junction) to the caudal border of the left pubic bone. The oviduct was divided into five regions from cranial to caudal based on the pattern and orientation of the mucosal folds. The regions of the oviduct were the infundibulum, the magnum, the isthmus, the uterus and the vagina.

The arterial supply of the ovary and oviduct was accomplished by the ovarian artery, the cranial oviductal artery, the accessory cranial oviductal artery, the middle oviductal artery, the caudal oviductal artery and the medial and lateral vaginal arteries. These arteries supplied various regions of the oviduct and were branches of the left cranial renal artery, the left pubic artery, the left middle renal artery and the left pudendal artery.

The left ovary was drained by a single ovarian vein which joined the left adrenal vein and subsequently emptied into the left side of the caudal vena cava. The veins of the oviduct were satellites of the arteries that supplied the oviduct and also drained into the caudal vena cava.

The main innervation of the reproductive tract was via a large ovarian nerve plexus which emerged laterally from the left adrenal gland.

Overall the anatomy of the ovary and oviduct of the female emu was similar to the domestic fowl. The ovary was located on the left side of the abdomen, but the color, shape and size of the ovary and the follicles varied in the emu from that of the domestic fowl. Differences in the oviduct were observed in the pattern and orientation of the mucosal folds in the magnum, uterus and the vagina in the emu and from the domestic fowl. The pattern of vasculature was similar in both except for the presence of the accessory cranial oviductal artery, the anastomosis of the caudal oviductal artery with the dorsal uterine artery and the presence of medial and lateral vaginal arteries in the emu.

TABLE OF CONTENTS

PAGE

1. INTRODUCTION..... 1

2. REVIEW OF THE LITERATURE..... 3

3. MATERIALS AND METHODS..... 32

4. RESULTS..... 35

5. DISCUSSION..... 87

BIBLIOGRAPHY..... 116

APPENDICES..... 119

APPENDIX A..... 120

APPENDIX B..... 121

VITA..... 122

LIST OF FIGURES

FIGURE PAGE

1-4. Left ovary of the emu..... 36

2-4. Left ovary of the emu *in situ*..... 37

3-4. Left oviduct of the emu *in situ*..... 40

4-4. Mucosal folds of the emu's left oviduct..... 41

5-4. The funnel of the infundibulum..... 43

6-4. The tubular region of the opened infundibulum..... 44

7-4. Transition from the infundibulum to the magnum..... 46

8-4. Mucosal folds of the magnum..... 47

9-4. Endoscopic view of the reproductive tract... 48

10-4. Isthmus and uterus of the emu's left oviduct..... 50

11-4. The mucosal folds of the isthmus..... 51

12-4. The mucosal folds of the uterus..... 53

13-4. Vagina of the emu's left oviduct *in situ*.... 54

14-4. Attachment from the vagina to the descending colon..... 55

15-4. The mucosal folds of the vagina..... 56

16-4. Rectocoprodeal junction..... 58

17-4. Coprourodeal fold of the cloaca..... 60

18-4. The dorsal and ventral ligaments of the oviduct..... 63

19-4. Cranial ligament of the infundibulum..... 64

FIGURE PAGE

20-4. Arterial supply of the left ovary and cranial extent of the left oviduct..... 66

21-4. Cranial oviductal artery and vein..... 68

22-4. Accessory cranial oviductal artery and its branches..... 71

23-4. Middle oviductal artery..... 73

24-4. Branches of the middle oviductal artery..... 74

25-4. Caudal oviductal artery and its branches.... 76

26-4. Medial vaginal artery and its branches..... 78

27-4. Lateral vaginal artery..... 79

28-4. The ovarian plexus of the left ovary (lateral view). Inset: dorsolateral view... 82

29-4. The innervation of the left ovary..... 83

30-4. The ovarian-adrenal plexus..... 84

31-4. Collage of the ovarian plexus..... 85

1-5. Left ovary and oviduct of an actively laying domestic fowl *in situ*..... 88

2-5. Left ovary from an actively laying domestic fowl *ex vivo*..... 90

3-5. Mucosal folds of the magnum in the domestic fowl..... 96

4-5. Mucosal folds of the magnum in the domestic fowl after an egg had passed..... 97

5-5. Left oviduct of the domestic fowl *ex vivo*... 99

FIGURE PAGE

6-5. Mucosal folds of the isthmus of the domestic fowl..... 100

7-5. The mucosal folds of the uterus of the domestic fowl..... 103

8-5. The mucosal folds of the vagina from an actively laying hen..... 106

Chapter 1

INTRODUCTION

The earliest anatomic description of ratites dates back to 1682. This report by E. Brown described the dissection of the ostrich and was presented to the Royal Society of London. After this initial presentation, there were other scattered studies Horne,1812; Mcalister,1864; Gadow,1890; Mitchell,1901; Schulz,1908; Duerden,1912. Although little work was done between 1912 and the present interest has recently increased in the anatomy of ostriches (Struthio camelus) and emus (Dromaius novaehollandiae) as the commercial popularity of these birds has increased.

The literature available deals mainly with the anatomy of ostriches, with the areas of concentration being the thoraco-abdominal viscera, circulatory system and the musculo-skeletal system (Fowler, 1991; Bezuidenhout, 1986; Cho, et al., 1984). There is little to no information available on the normal anatomy of the reproductive system of the adult female emu (Dromaius novaehollandiae).

The current investigation describes the morphology of the female reproductive tract of the emu (Dromaius novaehollandiae). The investigation used three two year old female emus that were physically mature but reproductively inactive. Two yearling emus were also available which were neither physically mature nor reproductively active. The

dissection focused on the morphology of the reproductive tract of the female emu, along with the vasculature and the innervation of the reproductive organs.

The rationale and importance for this research is that it will provide written descriptions and photographs of the reproductive system of adult female emus which are becoming commercially valuable as a farm "critter". Hopefully this information will aid in finding solutions for infertility problems. Only when the normal is known can one determine the pathology.

Chapter 2

REVIEW OF THE LITERATURE

Early in the avian embryo there are two bilateral symmetrical gonads and a bilateral oviduct (King, 1984). During subsequent developmental stages, the right ovary and oviduct will degenerate and the left ovary and oviduct (which has five parts) will continue to develop (King, 1984). Therefore, when the reproductive tract of most adult female avians are examined only the left ovary and oviduct will be present and functional.

1. Ovary

The left ovary of an adult female avian that is sexually mature will resemble a cluster of grapes (Getty, 1975; Nickel, 1977; King, 1984). This typical appearance of the left ovary is due to the presence of numerous follicles of various sizes covering the surface of the ovary. The follicles which cover the ventral surface of the left ovary are suspended by a pedicle (follicular stalk) and have a light to dark yellow color (Getty, 1975; King, 1984).

The left ovary of the adult female avian is usually in close association with the cranial division of the left kidney (Getty, 1975). The hilus of the left ovary is attached to the dorsal body wall by the mesovarium, which suspends the ovary from the dorsal body wall into the body

cavity (Getty, 1975). The mesovarium consists of a peritoneal fold which will be greatly reinforced by connective tissue, smooth muscle, blood vessels and nerves that penetrate into the parenchyma of the left ovary (Baumel, 1993).

Overall the anatomy of the left ovary seems to be the same in principle in all domestic fowl species according to the information found in Sisson and Grossman's The Anatomy of Domestic Animals (Getty, 1975). The literature stated that there is no full description of the structure of the ovary in domestic birds, other than the domestic chicken and a brief description of the ovary of the aquatic domestic birds and the duck (Getty, 1975).

2. **Oviduct**

The oviduct of the domestic fowl has an epithelial lining of the lumen consisting of ciliated columnar cells and unicellular glands (Getty, 1975). The unicellular glands are often known as goblet cells and produce mucin. These glands are most numerous and largest in the magnum (Getty, 1975). There are also multicellular glands of two types, glandular grooves and tubular glands which are located in the grooves between the secondary folds of the mucosa (Getty, 1975). The tubular glands occur continuously throughout most of the oviduct and develop the most in the

magnum, while the glandular grooves are located only throughout the infundibulum (Getty, 1975).

The mucosa of the oviduct is thrown into primary folds which are tall enough to be seen with the unaided eye (Getty, 1975). These folds are continuous throughout the oviduct and usually have a gentle spiral orientation (King, 1984; Getty, 1975). The primary folds often have smaller secondary folds and between the secondary folds are the openings of the tubular glands.

The left oviduct of the domestic fowl can be divided anatomically into five distinct regions (King, 1984; Getty, 1975). This division of the oviduct is based on the external diameter of the oviduct, the pattern of the mucosal folds and the type of glands (Getty, 1975). The regions of the oviduct are: a) the infundibulum, b) the magnum, c) the isthmus, d) the uterus and e) the vagina (Getty, 1975).

a) **Infundibulum**

The infundibulum consists of two components, a funnel portion and a tubular region (King, 1984). The funnel portion of the infundibulum opens as the ostium infundibulare which appears as an elongated slit (Baumel, 1993). The opening into the funnel portion of the infundibulum is surrounded by thin, flared lips with small finger-like projections known as the fimbrae infundibulares

(Baumel, 1993). The funnel of the infundibulum tapers into the tubular region (also known as the chalaziferous zone) (Getty, 1975).

Both the funnel and tubular regions of the infundibulum have mucosal folds which house the tubular glands (Getty, 1975; King, 1984). These folds are taller in the tubular region than in the funnel portion of the infundibulum, and there is an increase in the number of secondary folds in the tubular region (Getty, 1975). Also the mucosal folds lie in a gentle spiral orientation which becomes more evident in the magnum, along with the mucosal folds becoming enlarged (Getty, 1975).

b) **Magnum**

The magnum often appears as the longest part of the oviduct in domestic fowl (Baumel, 1993). It is characterized by the sudden enlargement of the mucosal folds which is due to an increase in the height of the folds and the size of the glands within the folds (King, 1984). This increase in the height of the folds and the size of the glands results in an increase in the thickness of the wall of the magnum (Getty, 1975; King, 1984). At this point the mucosal folds are taller and thicker than anywhere else in the oviduct (Getty, 1975; King, 1984). Also, the individual folds of the mucosal surface of the magnum of most domestic fowl have a more pronounced spiral (wavy)

pattern, which is easily seen with the unaided eye (King, 1984). These mucosal folds may either be orientated in a longitudinal or oblique pattern (King, 1984; Getty, 1975).

c) **Isthmus**

The isthmus is characterized by a change in the calibre of the left oviduct; i.e. the diameter of this section of the oviduct will be decreased and the mucosal folds may not be as prominent nor demonstrate the pronounced spiral (wavy) pattern when compared to the magnum (Baumel, 1993; King, 1984). The individual folds are often described as being orientated longitudinally with or without the spiral (wavy) pattern (Getty, 1975; King, 1984).

The boundary between the isthmus and the magnum is easily distinguishable in domestic fowl due to the presence of a narrow band of tissue (zona translucens) which looks translucent in fresh tissue and is a region where there are no tubular glands (Getty, 1975; King, 1984).

d) **Uterus (Shell Gland)**

Generally there is no distinct boundary between the isthmus and the uterus (Getty, 1975). The uterus is often described as having three regions, but the literature can be controversial as to whether the three regions are easily distinguishable (Getty, 1975; King, 1984). The first region, the pars cranialis uteri, is the initial short

region and is often called the red region (Baumel,1993; Getty, 1975). This name is often misleading since the first region is only distinguishable when the uterine vasculature is engorged during the phase of calcium transfer to the developing egg (Baumel, 1993). The second region is the pars major uteri, which is the pouch like portion that holds the egg during the shell formation (Baumel, 1993; King, 1984; Getty, 1975). The third region is the recessus uterinus, which is the caudal funnel-shaped region that will lead into the uterovaginal junction (Baumel, 1993; Getty, 1975; Fuji, 1963).

The mucosal folds of the uterus are described as being intersected by many transverse and oblique furrows, resulting in mucosal folds that are similar to leaf-like lamellae (King, 1984; Getty, 1975). This intersection of the mucosal folds also results in the folds not being as obviously continuous or longitudinal when compared to other mucosal folds of the oviduct (King, 1979). Subsequently, these mucosal folds are often referred to as lamellae uterinae in other literature (Baumel, 1993).

e) **Vagina**

The vagina appears as a short muscular s-shaped tube which connects the uterus to the cloaca and opens into the urodeum of the cloaca by a narrow opening known as the ostium cloacale oviductus sinistri in domestic fowl (Baumel,

1993; King, 1979). The vagina of the domestic fowl as it arises from the uterus will be folded into it's characteristic s-shape against the ventral surface of the uterus (Getty, 1975). This modification in the shape of the vagina is maintained by the dorsal and ventral ligaments of the oviduct, which attach the vagina to the uterus, to the coprodeum and to the adjacent body wall (Getty, 1975). In order for the vagina to be straightened these ligamentous attachments would have to be transected. The vagina is characterized by the thickening in the tunica muscularis along with the presence of a strong vaginal sphincter (Baumel, 1993; Nickel, 1977; King, 1984). Although it has been questioned as to whether or not a true vaginal sphincter exists and its exact location. King (1984) describes the sphincter as being located at the cranial end of the vagina while Getty (1975) describes the sphincter as being located at the uterovaginal junction (King, 1984; Getty, 1975).

The mucosal folds of the vagina are thinner and lower (i.e. not as tall as previously seen) than any other part of the oviduct, except for the funnel portion of the infundibulum (King, 1984; Getty, 1975). Also the mucosal folds of this region are orientated longitudindally without the spiral (wavy) pattern as previously seen in the magnum and isthmus (Getty, 1975).

In the region of the vaginal sphincter, the longitudinal folds are mashed together which reduces the vaginal lumen to a narrow ring, and the surface of the folds appear to have a roughened appearance instead of being smooth (Getty, 1975). These folds are important because they house the vaginal glands which are involved in the storage of spermatozoa in the domestic fowl (Getty, 1975). An article by Bezuidenhout (!995) describes the presence of the vaginal glands (also referred to as the sperm storage tublues) in the ostrich at the utero-vaginal junction but there was no mention of these glands in the emu.

3) **Cloaca**

The cloaca, even though not a true component of the oviduct is important because in a study of the reproductive tract it has chambers that receive the terminal parts of the urogenital and digestive tracts (King, 1984). The avian cloaca consists of three chambers: the coprodeum, the urodeum and the proctodeum (King, 1984; Getty, 1975).

These three chambers according to research by Gadow 1887 are separated by three mucosal folds (King, 1981). The cranial most fold between the rectum and the coprodeum is referred to as the rectocoprodeal fold (plica rectocoprodealis), the next fold located between the coprodeum and the urodeum is known as the coprourodeal fold (plica coprourodealis)and the final fold which marks the

boundary between the urodeum and the proctodeum now referred to as the uroproctodeal fold (plica uroproctodealis) (King,1981; King, 1984; Getty, 1975). Gadow 1887 also concluded that these folds do not exist in all avian species, and this fact causes difficulty in distinguishing between the three chambers of the cloaca (King, 1981).

The coprodeum is the most cranial chamber and the largest of the three (King, 1984; Nickel, 1977; Getty, 1975). The junction between the rectum and the coprodeum is usually unmarked in many avian species except in the ostrich (Struthio camelus), where there is a prominent rectocoprodeal fold (King, 1984; Getty, 1975; King, 1981).

In the cloaca of avian species where there is not a rectocoprodeal fold, a distinct anatomical boundary between the rectum and coprodeum has been described as a change in the appearance of the mucosal folds of the mucosa of the rectum and the coprodeum (King, 1981). The mucosa of the caudal part of the rectum is arranged into mucosal folds(also known as intestinal plicae) which give the surface of the rectum a matted appearance (King, 1981; Getty, 1975). As for the mucosa of the coprodeum, various descriptions were found. The mucosa was described as changing from the matted appearance of the rectum to a mucosal surface where the mucosal folds were shorter than those in the rectum or to a mucosal surface that was smooth depending on the avian species (King, 1981; Getty, 1975).

The next chamber is the urodeum, which is the middle and smallest of the three chambers (King, 1984). The boundaries of the urodeum are demarcated by the coprourodeal fold cranially and the uroproctodeal fold caudally (Getty, 1975; King, 1984).

The coprourodeal fold which separates the coprodeum from the urodeum has been found in many species of birds (Getty, 1975; King, 1981). This fold is often described as a well developed transverse, circular or annular ridge depending on the condition of the cloaca, i.e. when there are no feces contained within the coprodeum (King, 1981; Getty, 1975). When the cloaca is distended with feces, the fold becomes a thin diaphragm with a central circular aperture which would eventually be everted through the vent (Getty, 1975; King, 1981; King, 1984).

The most important structures of the urodeum are the openings for the left and right ureters (ostium ureteris) and the left oviduct (ostium cloacale oviductus sinistri) (King, 1984, King, 1981). The openings for the left and right ureters are on the dorsal surface of the urodeum with the opening of the left oviduct being on the left side of the urodeum (King, 1984; Getty, 1975). In most avians each ureter will open by a simple orifice located in the dorsal wall of the urodeum (King, 1984; Getty, 1975). However, it is reported that in some species, the opening of the right

and left ureters can be situated on the apex of a small papilla (King, 1984; Getty, 1975).

As mentioned earlier the opening of the left oviduct is usually located on the lateral wall of the urodeum, ventral to the opening of the left ureter (Getty, 1975). The opening of the left oviduct is often described as a broad slit (Getty, 1975). However some literature reports that in domestic fowl and the turkey the opening to the left oviduct may be located on a "dome-like mound or a rosette-like mound", which will appear flattened if the cloaca is incised on the ventral surface and spread open (King, 1984).

The mucosa of the urodeum was at first thought to be similar to the mucosa of the coprodeum lined with mucosal folds which are shorter and more leaf-like (Getty, 1975). However, other literature reports that instead of distinct mucosal folds lining the interior of the urodeum, there are irregular folds which are intersected by oblique and longitudinal furrows (Getty, 1975).

The third chamber, the proctodeum, is located between the uroproctodeal fold and the lips of the vent (Getty, 1975). The proctodeum is the caudal most chamber and the connector between the urodeum and the vent (King, 1981). In domestic fowl, the mucosa of the proctodeum is described as being "regularly arranged in craniocaudal folds (plicae proctodeales) along the dorsolateral and lateral walls of the proctodeum" (King, 1981). Often between the mucosal

folds there will be deep depressions or grooves seen (King, 1981).

The uroproctodeal fold which separates the urodeum and the proctodeum has been found to be well developed in all avian species examined thus far (King, 1981). The fold is described as a " semilunar ridge that curves around the dorsal and lateral walls of the cloaca and ventrally disappears completely" (Getty, 1975).

4. **Ligaments of the Oviduct**

The oviduct is held in place by dorsal and ventral ligaments (King, 1984; Getty, 1975). The dorsal ligament is also referred to as the mesoviductum (Nickel, 1977).

The dorsal ligament (mesoviductum) extends from the dorsal abdominal wall ventrally along the left kidney to the oviduct (King, 1984; Nickel, 1977; Getty, 1975). The dorsal ligament is described as a short peritoneal fold that contains smooth muscle fibers which are continuous with the outer longitudinal layer of muscle in the wall of the oviduct. The ligament also contains numerous blood vessels and nerves that supply the oviduct (Nickel, 1977; Getty, 1975). The cranial part of the dorsal ligament is referred to as the cranial ligament of the infundibulum (Getty, 1975; Nickel, 1977). The importance of the cranial ligament is that it extends from the next to last or the last left thoracic rib to the cranial division of the left kidney

(Getty, 1975). This helps maintain the opening of the infundibulum in a good position to catch ovum from the ovary during ovulation (Getty, 1975).

The ventral ligament of the oviduct is an extension of the peritoneum beyond the left oviduct (Getty, 1975). The ventral ligament extends from the caudal region of the funnel portion of the infundibulum to the proximal part of the vagina (Getty, 1975). The ventral ligament may also be referred to as the ventral suspensory ligament (Nickel, 1977). The ventral border of the ventral ligament is a free edge. This border is often reinforced with smooth muscle to give the appearance of a muscular cord which can be referred to as the Funiculus musculosus (Getty, 1975; Baumel, 1993). This thickened caudal portion fuses with the pouch like portion of the uterus (pars major uteri) and the proximal part of the vagina (Getty, 1975).

5. **Vasculature**

a) **Arterial**

The arterial supply to the left ovary is accomplished by a branch from the left cranial renal artery (Getty, 1975). This branch is often referred to as the ovario-oviductal branch which will bifurcate within the parenchyma of the ovary into the ovarian artery and the cranial oviductal artery (Getty, 1975). There are also several

other mechanisms by which the left ovary can receive a vascular supply:

1. the ovarian artery may come directly off the aorta, cranial to the left cranial renal artery (Getty, 1975);

2. there may be one or two branches from the aorta into the ovary plus the ovarian artery that comes from the left cranial renal artery (Getty, 1975).

The arterial supply to the left oviduct is accomplished by branches coming from the left cranial renal, left external iliac, left ischiatic, and the left pudendal arteries (Getty, 1975; Baumel, 1993). There are four or possibly five arteries that supply the oviduct depending on the literature that is consulted. The cranial oviductal artery is the first artery that supplies the infundibulum and the cranial end of the magnum (Baumel, 1993). This artery arises from the ovario-oviductal artery a branch from the left cranial renal artery (Baumel, 1993; Getty, 1975). According to the older literature this artery used to be referred to as the anterior oviductal artery (Hodges, 1965).

The ovario-oviductal artery will divide within the parenchyma of the left ovary into the ovarian and the cranial oviductal arteries (Getty, 1975). The cranial oviductal artery after emerging from the ovary will enter the dorsal ligament of the oviduct (Hodges, 1965; Getty, 1975). This artery, which used to be known as the anterior

oviductal artery, supplies the dorsal surface of the infundibulum and the cranial end of the magnum.

The second artery supplying the left oviduct is the accessory cranial oviductal artery, which supplies the middle and caudal parts of the magnum (Baumel, 1993; Hodges, 1965; King, 1984). From the literature the origin of this artery is unclear. Baumel (1993) reports it arising from the left external iliac artery. Whereas R. D. Hodges (1965) states "this artery (the accessory cranial oviductal artery), which is usually inconstant, is a branch of the left femoral artery, which passes between the cranial and middle lobes of the kidney and divides in the dorsal ligament to supply the middle and caudal parts of the magnum."

The third artery of the left oviduct is the middle oviductal artery, which supplies the caudal end of the magnum, the isthmus and the cranial part of the uterus (Baumel, 1993). This artery according to Sisson and Grossman's The Anatomy of Domestic Animals, is a branch off the left ischiatic artery arising between the middle and caudal renal arteries (Getty, 1975). This artery instead of arising between the middle and caudal renal arteries may be found coming directly off the left middle renal artery in some cases (Nickel, 1977; Baumel, 1993). Older literature may often refer to the middle oviductal artery as the hypogastric artery (Hodges, 1965).

Once the middle oviductal artery arises from the left middle renal artery or from the left ischiatic artery between the middle and caudal renal arteries, it will enter the dorsal ligament (Getty, 1975). At this point, the artery sends out multiple branches that appear to fan out through the dorsal ligament to supply the caudal end of the magnum, the isthmus and the cranial extent of the uterus (Getty, 1975; Hodges, 1965). This artery also receives a large anastomotic branch traveling caudally in the dorsal ligament from the cranial oviductal artery (Getty, 1975; Nickel, 1977). The middle oviductal artery will terminate at the cranial extent of the uterus by dividing into the medial (right) and lateral (left) cranial uterine arteries and the dorsal uterine artery (Getty, 1975). These vessels have also been referred to as the medial and lateral anterior uterine arteries or the right and left cranial uterine arteries and the dorsal uterine artery as the superior uterine artery (Hodges, 1965; Getty, 1975; Baumel, 1993).

The medial and lateral cranial uterine arteries supply the medial and lateral sides of the cranial part of the uterus (Getty, 1975; Baumel, 1993; Hodges, 1965). The lateral cranial uterine artery usually passes vertically down the lateral side of the uterus (Hodges, 1965). At this point numerous small branches come off to supply the lateral (left) side of the cranial part of the uterus and some of

the branches will anastomose with arterial branches that supply the caudal extent of the isthmus (Hodges, 1965).

When the lateral cranial uterine artery reaches the ventral surface of the uterus it bifurcates into the inferior oviductal artery and the inferior uterine artery (Hodges, 1965; Getty, 1975). The inferior oviductal artery, which in more recent literature is called the ventral marginal artery travels cranially along the ventral surface of the uterus in the ventral ligament (Hodges, 1965; Getty, 1975). This artery supplies the ventral surface of the caudal extent of the isthmus, the magnum and the infundibulum (Hodges, 1965; Getty, 1975). The inferior uterine artery which is currently referred to as the ventral uterine artery travels caudally along the ventral surface of the uterus (Hodges, 1965; Getty, 1975). This artery supplies the ventral surface of the uterus by numerous small branches which anastomose with branches from the medial (right) and lateral (left) uterine arteries, which are branches of the dorsal uterine artery (Hodges, 1965; Getty, 1975; Baumel, 1993).

The branching pattern of the medial cranial uterine artery is usually very similar to the lateral cranial uterine artery (Hodges, 1965). Although, the arteries on the medial side tend not to be as well developed and the pattern is often obscured (Hodges, 1965). The medial cranial uterine artery is often poorly developed. Instead

of a well developed main trunk that travels to the ventral surface of the uterus and bifurcates into the ventral marginal and ventral uterine artery, it gives off two to three minor branches (Hodges, 1965). These minor branches travel ventrally to anastomose with branches of the ventral uterine artery on the lateral side of the oviduct (Hodges, 1965).

The caudal extent of the ventral uterine artery goes to either the medial or the lateral side of the uterus and terminates by anastomosing with the medial or lateral caudal uterine artery (Hodges, 1965; Getty, 1975). These arteries may be referred to as the right and left caudal uterine arteries or the medial and lateral posterior uterine arteries in other literature (Baumel, 1993; Getty, 1975).

In some cases the ventral uterine artery may divide to anastomose with the medial and lateral caudal uterine arteries, which are branches of the caudal oviductal artery, instead of ending on the medial or lateral side of the cranial extent of the uterus (Hodges, 1965). Also, the ventral uterine artery may send branches to the ventral surface of the vagina and anastomose with vaginal arteries (Hodges, 1965).

The final branch of the middle oviductal is the dorsal uterine artery, (the superior uterine artery) (Hodges, 1965; Getty, 1975). This artery travels caudally along the dorsal surface of the uterus and terminates by dividing into the

medial and lateral uterine arteries, which supply the medial and lateral sides of the middle portion of the uterus (Getty, 1975; Baumel, 1993). These latter arteries are sometimes known as the left and right lateral uterine arteries or the lateral lateral and medial lateral arteries in older literature (Hodges, 1965; Getty, 1975).

The fourth artery that supplies the oviduct is the caudal oviductal artery. This artery is a branch that arising from the left pudendal artery, which is a branch from the left internal iliac artery (Baumel, 1993; Getty, 1975). The caudal oviductal artery will divide immediately into the medial and lateral caudal uterine arteries to supply the caudal extent of the uterus and possibly the vagina (Getty, 1975). These latter two arteries may also be referred to as the right and left caudal uterine arteries the medial and lateral posterior uterine arteries or the middle uterine arteries (Baumel, 1993; Getty, 1975; Hodges, 1965).

Older literature refers to the caudal oviductal artery as the pelvic branch of the left internal iliac artery (Hodges, 1965). As mentioned previously the caudal oviductal artery usually arises from the left pudendal artery. Although R. D. Hodges (1965) mentions that in some cases the caudal oviductal artery may arise from the left internal iliac at a position cranial to the bifurcation into the left pudendal and the lateral caudal artery. When this

occurs, the arteries that arise from this branch of the internal iliac are called the posterior uterine arteries, also known as the medial (right)and lateral (left) caudal uterine arteries (Hodges, 1965; Baumel, 1993; Getty, 1975).

Usually the medial and lateral caudal uterine arteries will anastomose with the medial and lateral uterine arteries and two branches may occur(Hodges, 1965). The first branch will travel ventrally to anastomose with the ventral uterine artery and the second branch will supply the utero-vaginal junction and be called the utero-vaginal artery (Hodges, 1965) another variation in the origin of the caudal oviductal artery is described in the Anatomy of the Domestic Bird (Nickel,1977). The paired pudendal arteries arise from the aorta instead of the internal iliac artery (Nickel, 1977). The pudendal artery will bifurcate into the ramus muscularis and the ramus intestinalis (Nickel, 1977). The ramus intestinalis is the branch which gives rise to the caudal oviductal artery (Nickel, 1977).

The final artery that supplies the caudal extent of the oviduct is the vaginal artery. This artery usually arises as a separate branch from the left pudendal artery, caudal to the origin of the caudal oviductal artery (Baumel, 1993; Getty, 1975). Occasionally the vaginal artery may be seen arising as a branch from the caudal oviductal artery (Baumel, 1993; Getty, 1975). Irrespective of its origin the vaginal artery will divide into vaginal arteries supplying

the lateral (left) and medial (right) sides of the vagina (Baumel, 1993; Getty, 1975).

b) **Venous**

The left ovary of domestic fowl is drained by two to three ovarian veins, depending on the literature that is consulted (Getty, 1975; King, 1979). These veins, which are referred to as the cranial, middle and caudal ovarian veins are formed by the anastomoses of veins from the follicular stalks of the ovary (Getty, 1975; King, 1979).

The cranial ovarian vein join the left adrenal vein and forms a common trunk which empties into the left side of the caudal vena cava cranial to the entrance of the left common iliac vein (King, 1979; Getty, 1975). The left common iliac vein is formed by the confluence of the left external iliac vein and the caudal renal portal vein (also known as the internal iliac vein) (Getty, 1975).

The middle ovarian vein, if present, is described as a single vein that joins the cranial extent of the caudal vena cava along the left side (Getty, 1975). This vein is only mentioned in one reference as being present in the domestic fowl (Getty, 1975).

The caudal part of the ovary will be drained by the caudal ovarian vein (Getty, 1975). Most of the literature states that the caudal ovarian vein opens into the caudal vena cava near the origin of the left common iliac vein

(Getty, 1975; King, 1979). The only controversy in the literature was the exact location that the caudal ovarian vein emptied into the caudal vena cava (Getty, 1975; King, 1979). A.S.King (1975) described the caudal ovarian vein entering the ventral aspect of the caudal vena cava, while A.B.Gilbert (1979) described the vein entering into the dorsal surface of the caudal vena cava. Getty (1975) also mentions that the caudal ovarian vein may join the cranial oviductal vein near its entry into the left common iliac vein.

The venous return of the oviduct is accomplished by the cranial oviductal vein, the middle oviductal vein, the caudal oviductal vein and the vaginal vein(s) (Getty, 1975; Nickel, 1977). These veins are usually satellites of the arteries that supply the oviduct, but there are instances where some of the veins do not parallel the arteries (Getty, 1975; Hodges, 1965).

The cranial oviductal vein will drain the dorsal surface of the infundibulum and the cranial end of the magnum by two branches that are referred to as the infundibulum vein and the magnum vein (Getty, 1975). A unique feature of this vein is that it may be joined by the caudal ovarian vein before it drains into the left common iliac vein (Getty, 1975; Hodges, 1965).

The next vein the drains the oviduct is the middle oviductal vein. This vein is often described as the largest

venous pathway of the uterus (Getty, 1975; Hodges, 1965). The middle oviductal vein will also drain the dorsal and ventral marginal veins, which lie along dorsal and ventral surface of the magnum, isthmus and the infundibulum (Getty, 1975). The dorsal marginal vein is a branch of the middle oviductal vein and drains the dorsal surface of the magnum, isthmus and infundibulum. The ventral marginal vein is a branch of the lateral cranial uterine vein and will drain the ventral surface of the magnum, isthmus and infundibulm (Getty, 1975). Other literature may refer to the dorsal and ventral marginal veins as magnum veins isthmus veins and infundibulum veins (Baumel, 1993).

The middle oviductal vein will generally have the same branching pattern as the middle oviductal artery (Hodges, 1965). The vein will divide into the medial and lateral cranial uterine veins and the dorsal uterine vein (Hodges, 1965). The middle oviductal vein will drain into the left caudal renal vein of the caudal lobe of the left kidney (Hodges, 1965; Getty, 1975). The vein then empties into the left common iliac from which the venous blood will drain into the caudal vena cava (Getty, 1975).

The major difference between the middle oviductal vein and artery is that some of the branches of the vein do not parallel the branches of the artery (Getty, 1975; Hodges, 1965). Also the dorsal uterine vein may be more developed than the artery and the course of the vein may vary (Hodges,

1965; Getty, 1975). Hodges (1965) describes that the dorsal uterine vein as being longer than the artery and running the entire length of the dorsal surface of the uterus.

The dorsal uterine vein will terminate by joining the left internal iliac vein or one of the caudal uterine veins which are branches of the caudal oviductal vein (Hodges, 1965; Getty, 1975). Alternatively the dorsal uterine vein may empty into the left renal vein which leads into the caudal vena cava (Getty, 1975).

The caudal oviductal vein will drain the caudal extent of the uterus and possibly the cranial extent of the vagina (Hodges, 1965). The medial and lateral caudal uterine veins which are branches of the caudal oviductal vein may be absent, with the lateral caudal uterine vein being the most frequently present (Hodges, 1965; Getty, 1975).

The vaginal vein(s) in general parallel the vaginal arteries (Hodges, 1965). The only exception was that the lateral uterine vein may anastomose with the (lateral) vaginal vein (Hodges, 1965). The vaginal vein(s) will empty into the caudal oviductal vein which is a branch of the left pudendal vein and then into the left iliac vein (Getty, 1975).

6. **Innervation of the left ovary and oviduct**

The innervation of the left ovary of the domestic fowl is accomplished by an ovarian plexus (Getty, 1975). The

ovarian plexus is described as a continuous sheet of nervous tissue that lies dorsal to the ovarian hilus and ventral to the abdominal aorta (Gilbert, 1969; Getty, 1975). From the ovarian plexus, large nerve fibers are usually seen traveling to the left ovary along the ovarian stalk, which penetrate the parenchyma of the gland for innervation (Gilbert, 1969; Getty, 1975; Mauger, 1941).

Earlier research attempted to divide the ovarian plexus into the renal, adrenal, aortic and ovarian plexus based on the close association of the ganglia to these structures (Mauger, 1941). More recent research indicates that the division is unjustified because the ganglia are clustered and often fused and cannot be distinguished or separated into the renal, adrenal, aortic or ovarian plexus (Gilbert, 1969; Getty, 1975). Another key factor is that most of these nerve fibers were distributed to the left ovary with few fibers going to the adrenal gland or the kidney (Gilbert, 1969; Getty, 1975).

The literature indicates that a majority of the ovarian plexus consists of sympathetic fibers (Getty, 1975). A.B.Gilbert (1969) mentions "that branches from three sympathetic ganglia were seen going to the ovarian plexus, but the sympathetic fibers did not enter the ovarian stalk directly. Instead branches going to the ovarian plexus always entered into the ganglion associated with the adrenal gland, which was part of the ovarian plexus". The

sympathetic innervation to the left ovary is thought to be via the fifth, sixth and the seventh thoracic ganglia, along with the first and second lumbosacral ganglia of the sympathetic chain (Getty, 1975). These ganglia distribute the sympathetic innervation to the ovary via splanchnic nerves (Getty, 1975; Gilbert, 1969). As for the parasympathetic innervation to the left ovary, controversy exists concerning whether the vagus nerve supplies fibers to the ovarian plexus and the exact origin of the nerve fibers (King, 1984; Getty, 1975).

The left oviduct of the domestic fowl has both parasympathetic and sympathetic innervation, which arising only from the left side of the body, according to the information found in Sisson and Grossman's The Anatomy of Domestic Animals.

The sympathetic innervation comes from the aortic plexus and ganglia of the left sympathetic trunk, which lie caudal to the external iliac artery (Getty, 1975). Fibers from the ovarian plexus and the left sympathetic trunk supply sympathetic nerves that accompany the ischiatic artery to the origin of the middle oviductal artery (also known as the hypogastric artery) (Getty, 1975; Hodges, 1965). From here, nerves follow branches of the arteries.

An article entitled "*Extrinsic Nerves of the Chicken Uterus*", describes the aortic plexus as traveling along the ventromedial surface of the descending aorta (Freedman,

1963). At the level of the ischiatic artery, two nerves are given off and travel along the ventral surface of the ischiatic artery (Freedman, 1963). These nerves travel ventrally across the lateral surface of the left ureter to the origin of the middle oviductal artery to the hypogastric plexus as described below (Freedman, 1963; Getty, 1975).

The ganglia of the left sympathetic chain, which are caudal to the external iliac artery give off several postganglionic nerves (Getty, 1975; Freedman, 1963). These nerves travel ventrally across the lateral side of the left ureter to the origin of the hypogastric artery (Freedman, 1963).

At this point the nerves from the aortic plexus and the ganglia of the left sympathetic trunk form a plexus at the origin of the hypogastric artery (middle oviductal artery) on the medial side (Getty, 1975). This plexus of sympathetic nerves is known as the hypogastric plexus (Getty, 1975; Freedman, 1963). The hypogastric plexus supplies innervation to the magnum, isthmus and uterus by sending out nerves that travel with the branches of the middle oviductal artery, which supplies the caudal end of the magnum, the isthmus and the cranial extent of the uterus (Getty, 1975; Baumel, 1993; Freedman, 1963).

The parasympathetic innervation of the left oviduct in domestic fowl is derived from visceral branches of the eighth to the eleventh lumbosacral spinal nerves (30-33

spinal nerves) which combine to form the pudendal nerve (also known as the pelvic nerve; pelvic splanchnic nerve) (Getty, 1975; Baumel, 1993; Freedman, 1963). These branches from the eighth to eleventh lumbosacral spinal nerves travel ventrally toward the left ureter and combine to form the pudendal (pelvic) nerve (Getty, 1975). At this point, the pudendal nerve closely follows the left ureter and the pudendal vessels toward the termination of the ureter in the urodeum of the cloaca (Freedman, 1963; Getty, 1975).

Other research also indicates that scattered ganglia are located along the left pudendal nerve (Getty, 1975; Freedman, 1963). Usually there are three ganglia along the proximal part of the pudendal nerve and a larger one at the junction of the uterus and the vagina (Getty, 1975; Freedman, 1963). The larger ganglion located at the junction of the uterus and the vagina is known as the uterovagianl ganglion or the cloacal ganglion (Getty, 1975).

The pudendal nerve is a branch of the pudendal plexus, which is composed of the ventral rami from spinal nerves 31-34 (Getty, 1975). The trunk and proximal part of the branches of the pudendal plexus are usually found lateral to the medial sacral artery and the internal iliac veins (Getty, 1975). The branches of this plexus accompany the branches of the internal iliac vessels (Getty, 1975).

The largest branch of the pudendal plexus is the lateral caudal nerve (also known as the external pudendal

nerve) (Getty, 1975). This nerve travels with the lateral caudal vessels (Getty, 1975).

No information on the innervation of the female reproductive tract of the emu was found in the literature searched.

Chapter 3

MATERIALS AND METHODS

1. **Specimens**

Specimens were obtained from local farmers by Dr. James Blackford in Department of Large Animal Clinical Sciences at the University of Tennessee, College of Veterinary Medicine. Since the birds were obtained during the laying season, it would have been anticipated that they should have been reproductively active, however they were reproductively quiescent. The emus that were used in this research project were either received dead (two yearlings, not physically mature or reproductively active) or euthanized for various health problems (three, two year old physically mature, but reproductively quiescentsent). Live emus were first used for endoscopic examamination of the reproductive tract and then used to study the anatomy of the reproductive tract. (Appendix B)

2. **Experimental Protocol**

The emus which were received alive during the laying season were used for endoscopic exam before they were euthanized. For the endoscopic exam, the emus were sedated with a cocktail of Ketamine Hydrochloride (Ketaset, Fort Dodge, Fort Dodge, IA), Acepromazine (Acepromazine Injection, Vedco, St. Joseph, MO), Xylazine Hydrochloride

(Rompun, Fermenta, Kansas City, MO), Dexamethazone (Dexamethazone Injection, Vedco, St. Joseph, MO) and water via intravenous injection into the right jugular vein given to effect. The emus were intubated and maintained on Isoflurane (Anaquest, Madison, WI) (2-4%) in oxygen. The tracheal diverticulum in the neck of the emu was wrapped with vet wrap to prevent expansion but not compromise the circulation. After the endoscopic exam was completed and while still anesthetized, the emus were exsanguanated. For exsanguination, the thorax was opened and canulas were placed into the descending aorta and the caudal vena cava. After blood flow had ceased, a 10% formalin solution was injected into the aorta, and the cadavers were subsequently submerged in a 5% formalin solution. After two days colored latex was injected via the in place cannulas into the arteries and veins to aid in visualization and dissection of the vasculature of the reproductive tract.

After the latex had hardened, the abdominal cavity was opened and macroscopic evaluation of the female reproductive system was performed. The reproductive tract was examined *in situ* and *ex vivo*. Measurements of the ovary, infundibulum, magnum, isthmus, uterus and the vagina were taken *ex vivo* with needle point calipers. Macroscopic measurements (maximum length cranial to caudal) of the components of the female reproductive tract (ovary infundibulum, ostium infundiulare, magnum, isthmus, uterus

length, vagina) were taken and recorded. In addition measurements of the ovary (medial to lateral) were taken and recorded. (Appendix A)

Chapter 4

RESULTS

The reproductive tract of the adult female emu consisted of an ovary and an oviduct on the left side. There was no evidence of a right ovary and oviduct.

1. **Ovary**

The ovary of the reproductively inactive adult female emu appeared long and shaped like a misshapen isosceles triangle. The ventral surface of the ovary was covered with follicles of various sizes. The ovary of the emu was a dark brownish-black color, while the follicles were a light gray color (Figure 1-4). The follicles were rather small and attached to the ovary by a pedicle (follicular stalk).

The ovary of the emu when examined *in situ* was located medial to the spleen (Figure 2-4). The spleen of the emu was crescent-shaped and located on the left side of the abdominal cavity, cranial to the left kidney. It was also observed that the cranial end of the ovary was ventromedial to the junction of the ilium and the ninth thoracic rib. The middle portion of the ovary was located along the ventral surface of the cranial lobe of the left kidney. The caudal end of the ovary was located in the groove along the ventral surface of the kidney between the cranial and middle lobes of the left kidney.

Figure 1-4. Left ovary of the emu. Note that the ventral surface of the ovary is covered with follicles (f) of various sizes. (Generally cranial is to the left of the photo and dorsal is the top of the photo unless otherwise indicated)

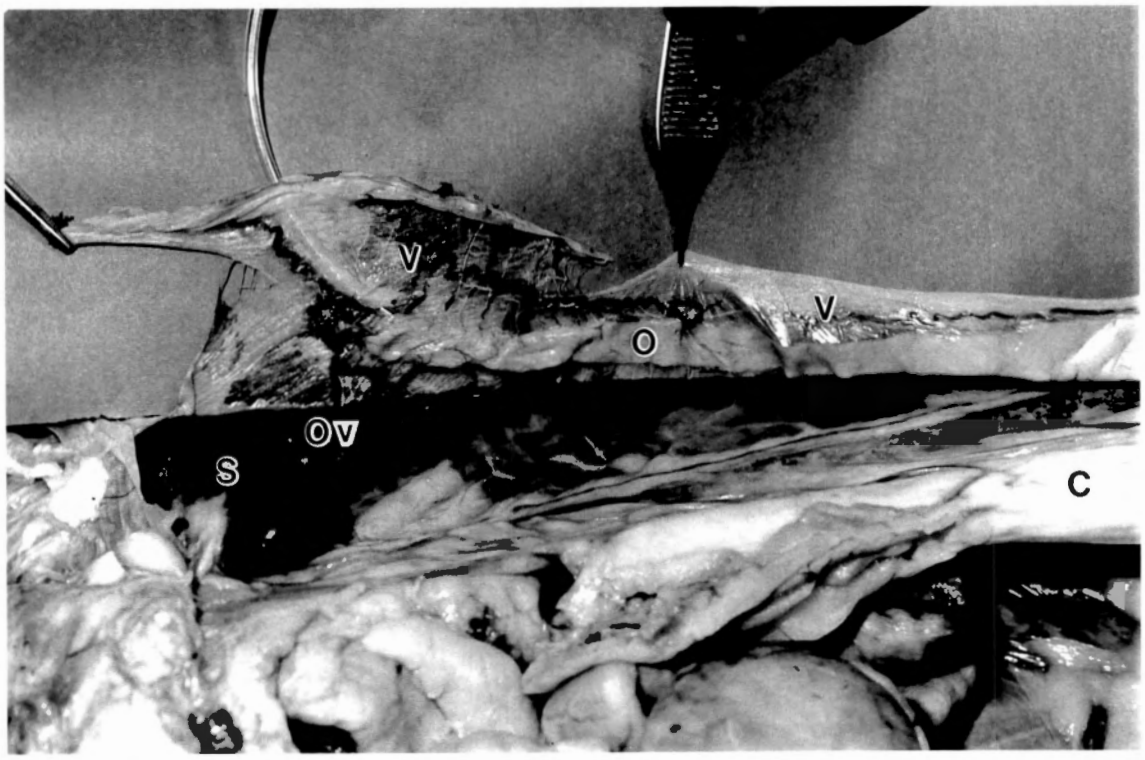

Figure 2-4. Left ovary of the emu in situ. The ovary (Ov) is medial to the spleen (S) and the lateral side of the ovary was covered by the raised left oviduct (O) and the dorsal (D) and ventral (V) ligaments of the oviduct. (C) Descending colon

The left and right kidneys of the emu were located along the ventral aspect of the ilium and synsacrum and medial to the ischium. The kidneys of the emu consisted of cranial, middle and caudal lobes which were separated on the dorsal surface by the external iliac and ischiatic arteries.

The lateral side of the ovary was covered by the infundibulum and the dorsal and ventral ligaments of the oviduct. It was also observed that the infundibulum and the dorsal and ventral ligaments of the oviduct covered the dorsolateral surface of the spleen *in situ* (Figure 2-4).

The ovary was suspended from it's dorsal surface to the dorsal body wall by the mesovarium. The mesovarium was a peritoneal fold along the entire dorsal surface of the ovary that was reinforced with connective tissue, blood vessels and nerves that penetrated into the parenchyma of the ovary. The blood vessels that penetrated into the ovary appeared to enter at the middle third of the ovary through the mesovarium. The nerves penetrated the parenchyma of the left ovary at it's middle third.

The ovary of the emu was not encased in an ovarian bursa as is typical of mammalian ovaries. The only covering of the ovary on the lateral side was the infundibulum and the dorsal and ventral ligaments of the oviduct. The mesovarium which has already been described covered the dorsal surface of the ovary. The ventral surface of the ovary was covered with ovarian follicles and by the spleen,

and the medial side of the ovary was in contact with the mesentery of the descending colon (Figure 2-4).

2. **Oviduct**

The oviduct of the emu *in situ* appeared as a long nearly straight tube that extended from the cranial extent of the ilium, caudal to the ninth thoracic rib, to the caudal border of the left pubic bone. The oviduct of the emu could be divided into five regions from cranial to caudal. These regions of the oviduct were: a) infundibulum, b) magnum, c) isthmus, d) uterus (shell gland) and e) vagina. Even though the oviduct was nearly a straight tube and lay in a similar position in all the emus examined, the precise location of its named regions was somewhat variable. The cranial part of the oviduct, the infundibulum and magnum, was ventral to the left ilium. The middle portion of the oviduct, the isthmus, was caudoventral to the left acetabulum and ventral to the left pubic bone. The caudal portion of the oviduct, the uterus and the vagina, was located along the dorsolateral surface of the descending colon and ventral to the caudal portion of the left pubic bone (Figure 3-4).

The mucosa of the oviduct was thrown into folds known as primary plicae. These folds were large enough to be seen macroscopically and appeared to be continuous throughout the length of the oviduct (Figure 4-4). The orientation and the

Figure 3-4. Left oviduct of the emu in situ. The small tube exits the ostium infundibulare (Oi)
(C) Descending colon
(I) Infundibulum
(Is) Isthmus
(K) Cranial and middle lobes of the left kidney
(M) Magnum
(U) Uterus
(V) Vagina

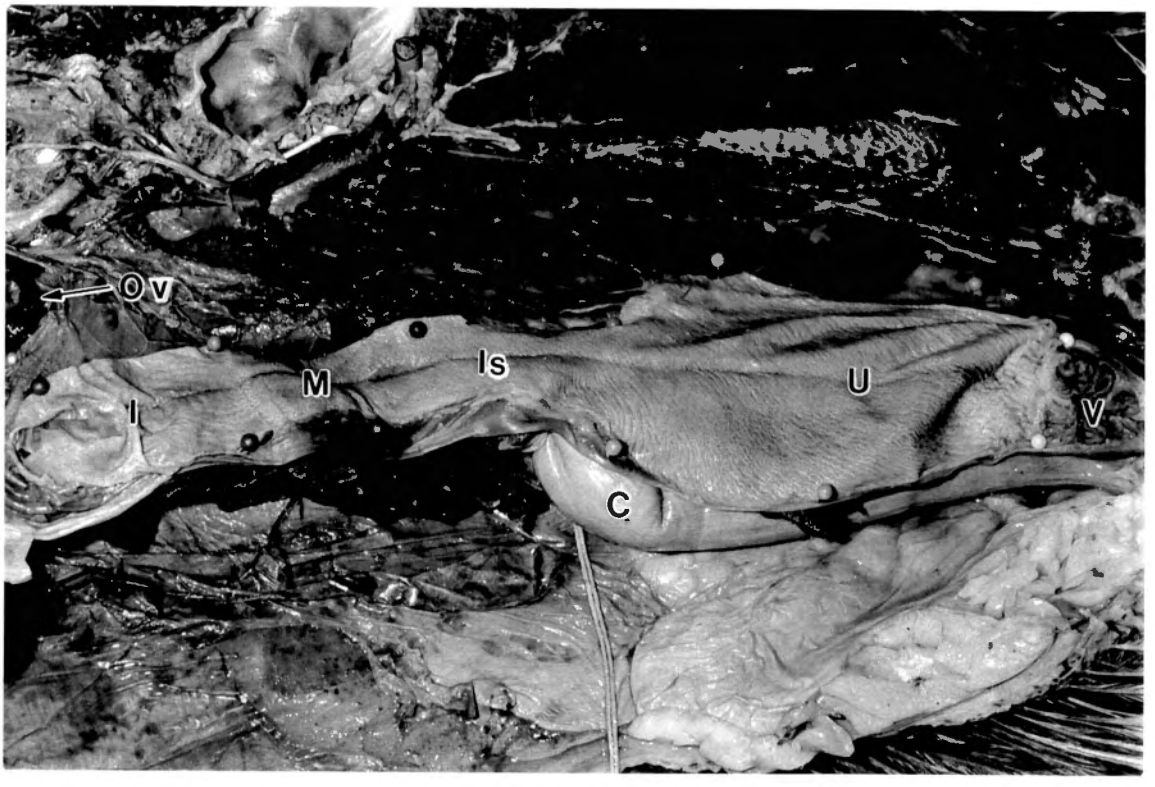

Figure 4-4. Mucosal folds of the emu's left oviduct. Note the variation in the orientation and pattern of the mucosal folds.
(C) Descending colon
(I) Infundibulum
(Is) Isthmus
(Ov) Caudal portion of the left ovary
(M) Magnum
(U) Uterus
(V) Vagina

pattern of the mucosal folds varied in each region of the oviduct and were used to demarcate between the various regions. The pattern of the mucosal folds varied from a wavy pattern to a nonwavy pattern and the orientation of the folds varied from oblique to longitudinal orientation (Figure 4-4).

a) **Infundibulum**

The infundibulum which covered the lateral side of the spleen and the left ovary *in situ*, consisted of two components: the funnel portion followed by the tubular portion (tubulus infundibularis), also known as the chalaziferous zone. The funnel of the infundibulum opened by an elongated slit known as the ostium infundibulare. This opening of the funnel portion was surrounded by thin, flared lips with small finger-like projections known as the fimbrae infundibulares (Figure 5-4).

The tubular region of the infundibulum, which was caudal to the funnel portion and cranial to the magnum, appeared to be the major part of the infundibulum. This region of the infundibulum was the most narrow region of the whole oviduct.

The mucosal folds of the infundibulum were extremely low and only observed in the tubular region of the infundibulum (Figure 6-4). The mucosal surface at the beginning of the tubular region appeared smooth, but toward



Figure 5-4. The funnel of the infundibulum. It opens by an elongated slit, indicated by the tube, known as the ostium infundubulare. This opening was surronded by thin flared lips (arrows).

Figure 6-4. The tubular region of the opened infundibulum. This region is outlined by the pins. The folds are extremely low and orientated longitudinally with a slight wavy pattern. Note the abrupt change in the mucosal folds at the transition from the infundibulum (I) to the magnum (M).

the middle and caudal extent the mucosa was thrown into individual mucosal folds. These folds were orientated longitudinally with a slight wavy pattern that became more pronounced near the magnum (Figure 6-4).

b) **Magnum**

The magnum was the next region of the oviduct. This region of the oviduct was not coiled; it was a short straight region ventral to the left ilium and left acetabulum.

The mucosal folds of the magnum were arranged in a wavy pattern and were orientated longitudinally. In this region, the mucosal folds were much thicker than the mucosal folds of the infundibulum (Figure 7-4 and Figure 9-4)

The transition from the infundibulum to the magnum was demarcated by the sudden enlargement of the mucosal folds of the magnum. There was a gradual increase in the size of the mucosal folds at the caudal end of the infundibulum however, this was minor when compared to the enlargement of the mucosal folds of the magnum (Figure 8-4 and Figure 9-4).

c) **Isthmus**

The isthmus was the third region of the left oviduct in the emu. It was located ventral to the middle and caudal lobes of the left kidney and ventral to the cranial extent

Figure 7-4. Transition from the infundibulum to the magnum. Note the enlargement in the mucosal folds and the pronounced wavy pattern of the folds of the magnum.
(I) Infundibulum
(M) Magnum

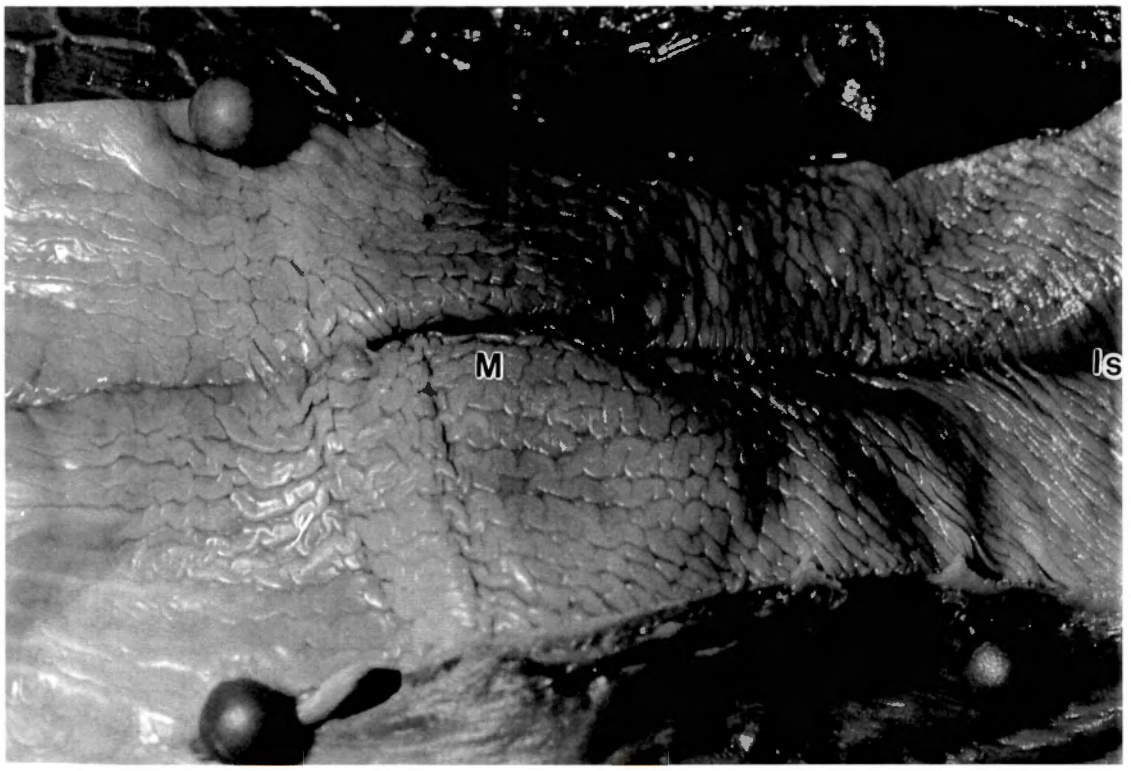

Figure 8-4. Mucosal folds of the magnum. Note the abrupt transition of the folds from the magnum (M) to the isthmus (Is).

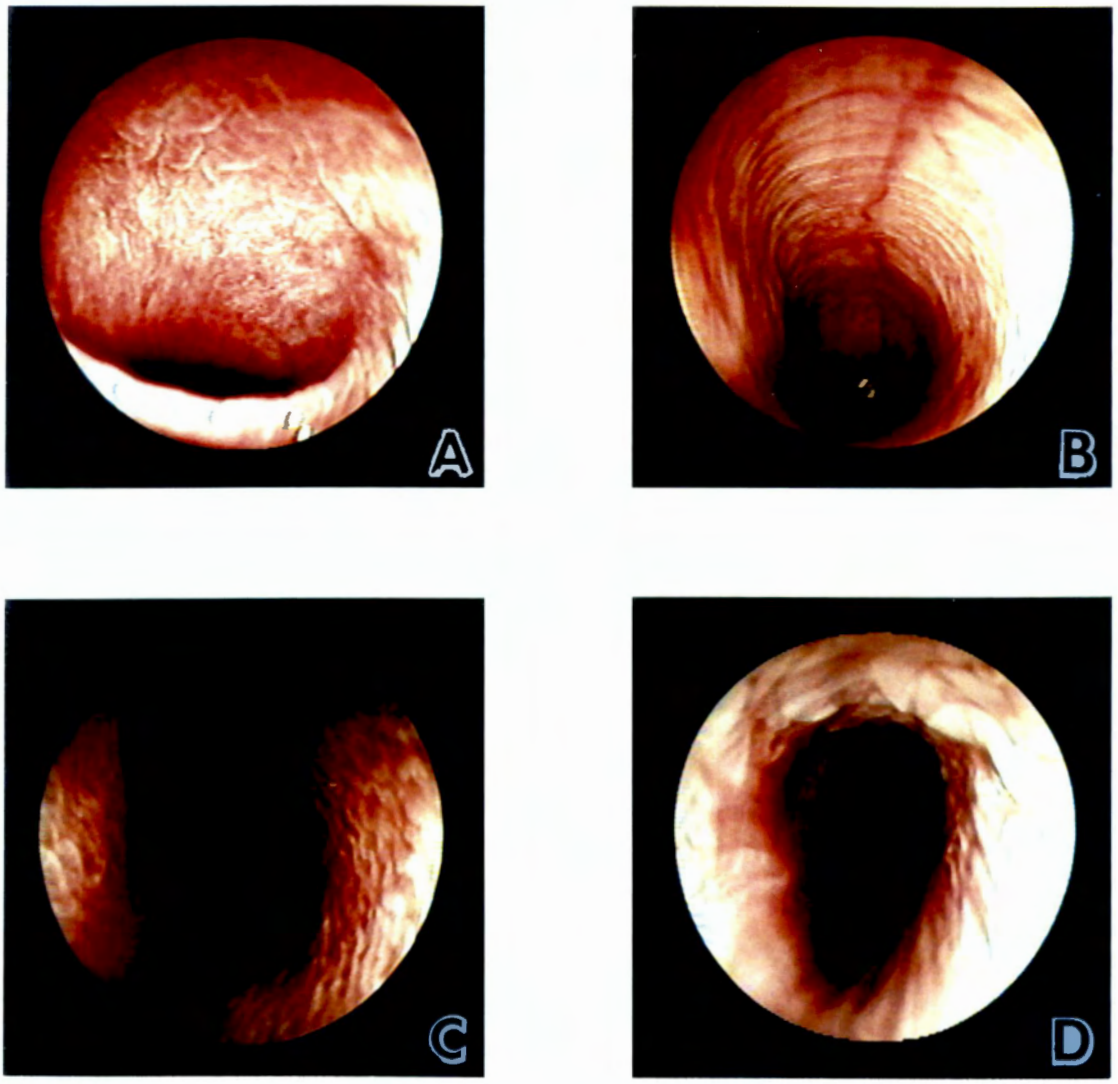

Figure 9-4. Endoscopic view of the reproductive tract.
(A) Magnum
(B) Isthmus
(C) Uterus
(D) Vagina

of the left ischium and left pubic bone. From a macroscopic view the overall size of this region decreased in calibre as compared to the uterus (Figure 10-4).

The mucosal folds of the isthmus were orientated obliquely with a wavy pattern that was not as pronounced as that previously seen in the magnum (Figure 9-4). In addition, the thickness of the mucosal folds was decreased when compared to the mucosal folds of the magnum (Figure 11-4 and Figure 9-4).

The zonula translucens, which usually demarcates the magnum from the isthmus in the domestic fowl, was not seen in the emus examined. The only demarcation between the magnum and the isthmus was the abrupt change in the pattern and the orientation of the mucosal folds from a wavy pattern with folds orientated longitudinally to mucosal folds with a less pronounced wavy pattern and an oblique orientation.

d) **Uterus**

This region of the oviduct appeared as a long sac-like expanded area. The uterus was ventral to the left pubic bone and located along the dorsolateral aspect of the descending colon (Figure 10-4).

The transition from the isthmus to the uterus was demarcated by an increase in the calibre of the uterus and a change in the pattern and orientation of the mucosal folds. The mucosal folds of the uterus had a wavy pattern with

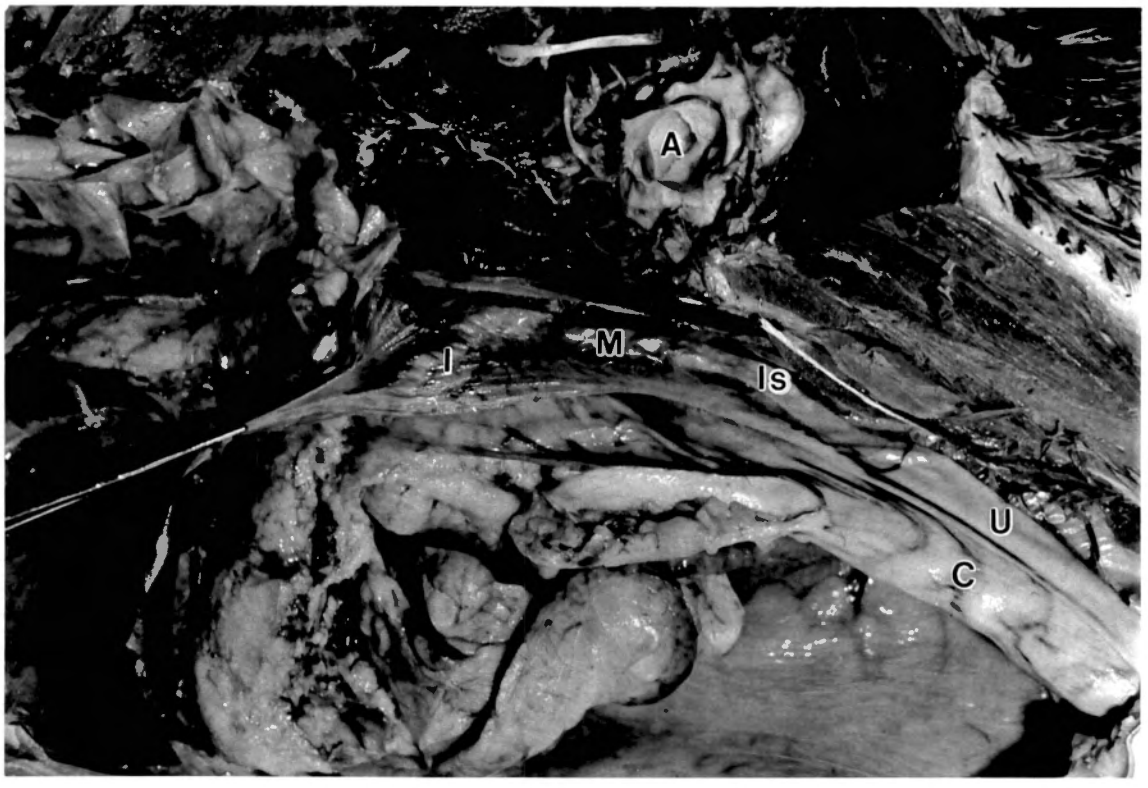

Figure 10-4. Isthmus and uterus of the emu's left oviduct.
(A) Left acetabulum
(C) Descending colon
(I) Infundibulum
(Is) Isthmus
(M) Magnum

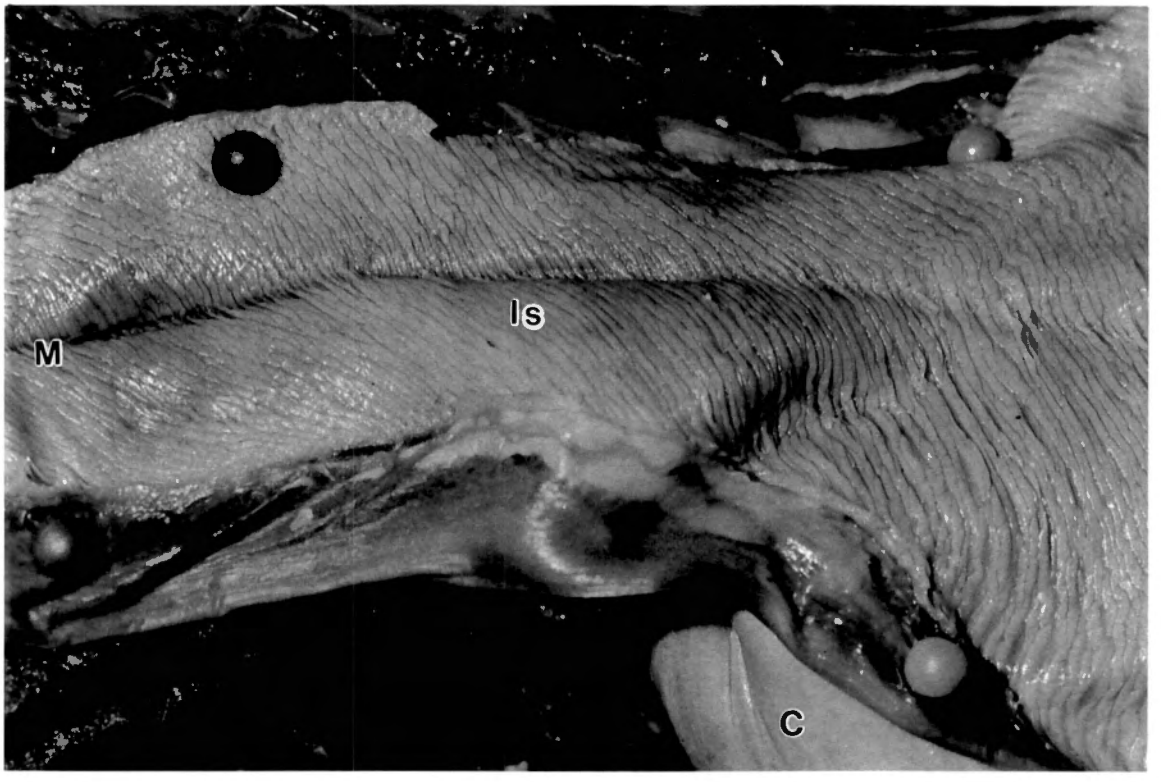

Figure 11-4. The mucosal folds of the isthmus. These folds are orientated obliquely with a less pronounced wavy pattern when compared to the magnum.
(C) Descending colon
(Is) Isthmus
(M) Caudal extent of the magnum

the orientation being at an oblique angle but gradually becoming orientated longitudinally near the caudal extent of the uterus. The wavy pattern was more pronounced in the middle and caudal sections of the uterus and along the medial (right) side than the lateral (left) side of the uterus (Figure 12-4 and Figure 9-4).

e) **Vagina**

The vagina was the caudal most region of the left oviduct. It was located along the dorsolateral surface of the descending colon and caudal to the left pubic bone (Figure 13-4). It was not fixed in the characteristic s-shape as described in the domestic fowl, but there did appear to be an attachment from the medial side of the caudal end of the vagina to the descending colon. This ligamentous structure was very tough and thick (Figure 14-4).

The mucosal folds of this region were much taller than those of any other region of the left oviduct. The mucosal folds were orientated longitudinally with the luminal surface of the folds appearing to be indentated or having a roughened appearance (Figure 9-4). A unique observation of this area was that the mucosal folds at the cranial end of the vagina were folded upon themselves in a semicircular fashion and mashed together. This modification appeared to decrease the size of the vaginal lumen (Figure 15-4).

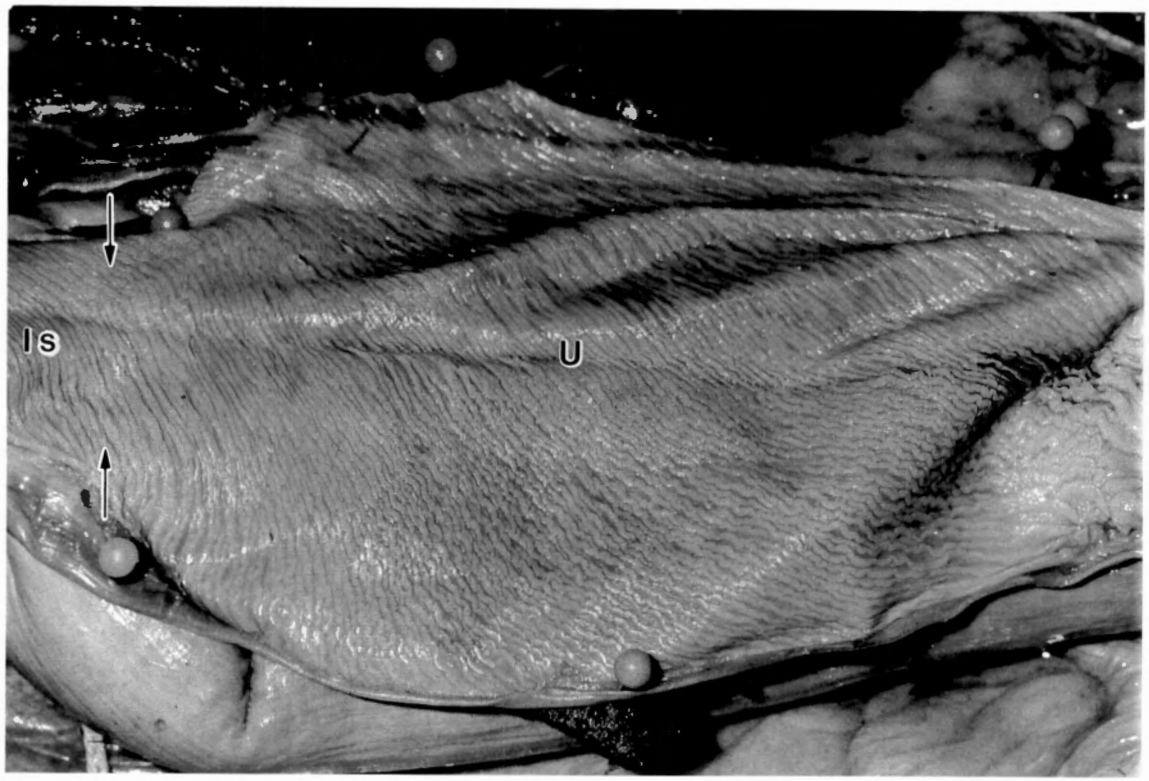

Figure 12-4. The mucosal folds of the uterus. The transition from the isthmus (Is) to the uterus (U) is indicated by the arrows. At this point there is a change in the pattern and orientation of the folds.

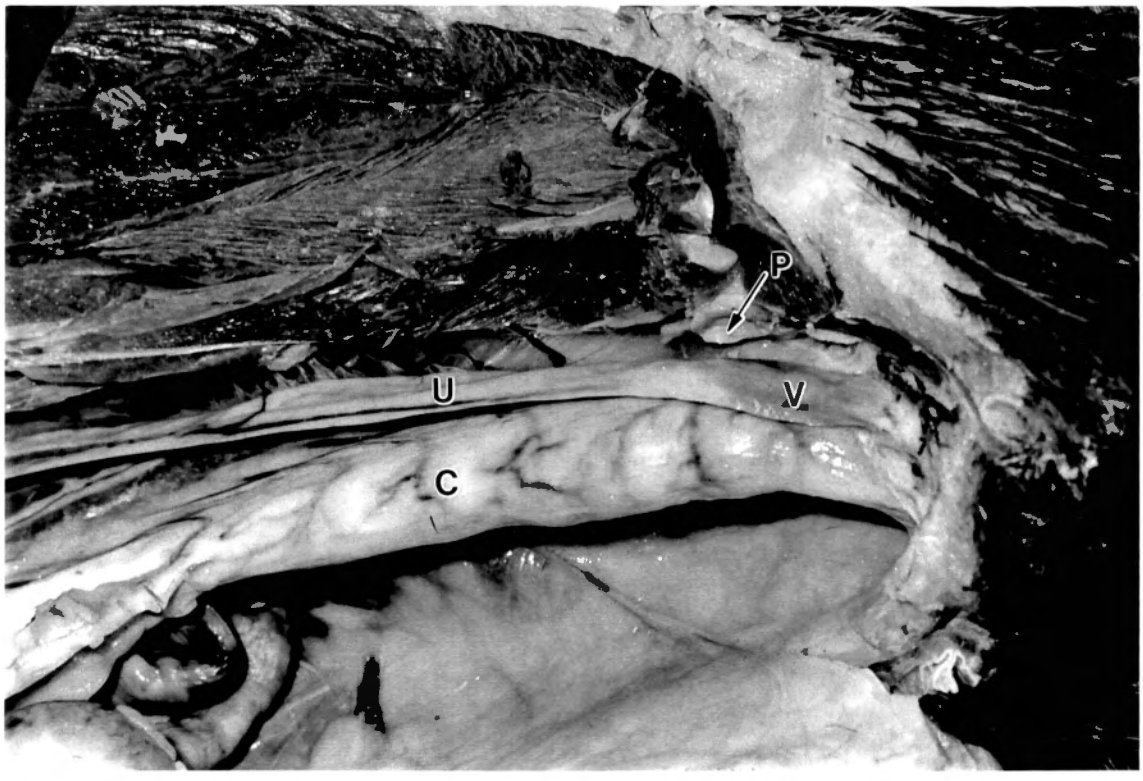

Figure 13-4. Vagina of the emu's left oviduct *in situ*.
(C) Descending colon
(P) Transected left pubic bone
(U) Uterus
(V) Vagina

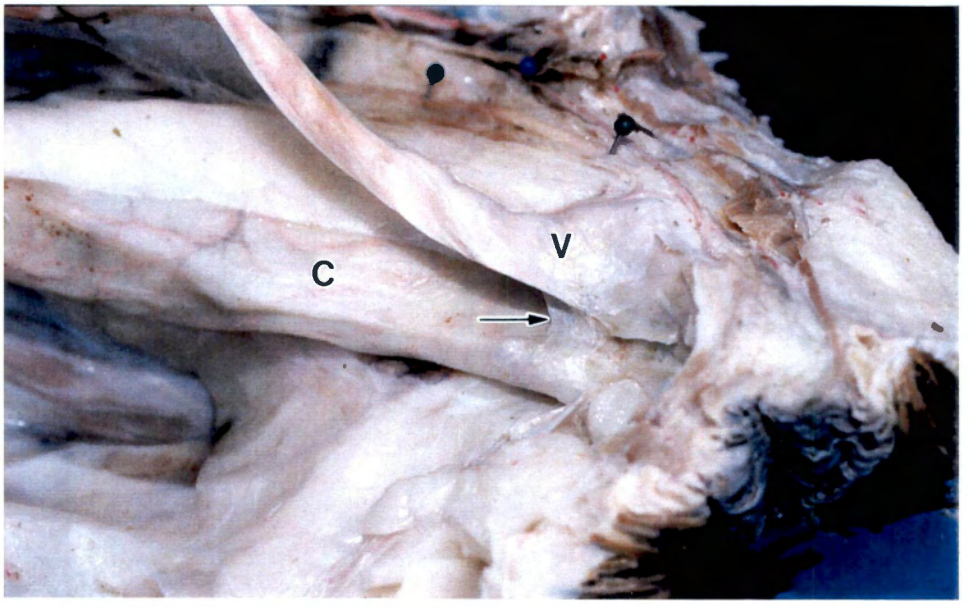

Figure 14-4. Attachment from the vagina to the descending colon. Arrow indicates the ligamentous attachment from the vagina (V) to the descending colon (C).

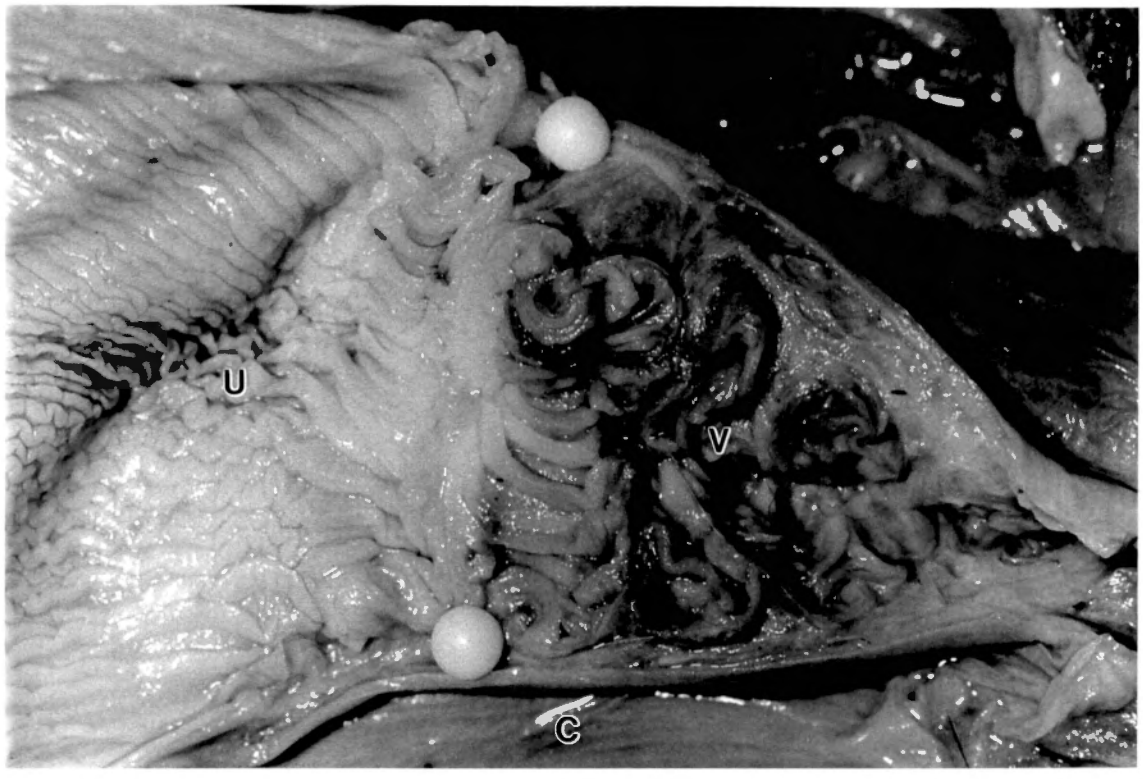

Figure 15-4. The mucosal folds of the vagina. Note the enlargement and modification in their pattern and orientation.
(C) Descending colon
(U) Uterus
(V) Vagina

3. **Cloaca**

The cloaca of the emu consisted of three chambers in order from cranial to caudal. The cranial most chamber was the coprodeum, followed by the urodeum and the proctodeum which was the caudal most chamber.

The coprodeum, the cranial most chamber of the cloaca, was the largest of the three chambers. No rectocoprodeal fold nor expansion in calibre was observed at the junction of the rectum and the coprodeum. Therefore the junction between the rectum and the coprodeum was unmarked externally (Figure 16-4).

Internally, the transition from the rectum to the coprodeum was determined by a change in the pattern and orientation of the mucosal folds of the rectum as compared to the coprodeum. The mucosal folds of the rectum were extremely thick and tall and orientated transversely with the luminal surface and sides of the folds indented. This gave the interior of the rectum a matted appearance. The mucosal folds of the coprodeum were also thick and orientated at a slight oblique to longitudinal angle but fewer in number as compared to the rectum (Figure 16-4).

The next chamber of the cloaca was the urodeum, which was the middle chamber and smaller than the coprodeum. The boundaries of the urodeum were demarcated by the coprourodeal fold cranially and the uroproctodeal fold caudally. The coprourodeal fold which separated the

Figure 16-4. Rectocoprodeal junction. The mucosal folds of the rectum (R) are high and orientated transversely as compared to the mucosal folds of the coprodeum (C) which are orientated longitudinally.

coprodeum from the urodeum appeared as a well developed circular ridge which curved around the dorsal, lateral and ventral walls at the junction of the coprodeum and the urodeum. This fold was thick when not distended with feces (Figure 17-4). The uroproctodeal fold which separated the urodeum from the proctodeum was also well developed in the emu. It appeared as a thick semilunar ridge which curved around the dorsal and lateral walls of the urodeum and disappeared ventrally.

The mucosa of the urodeum was smooth when compared to the coprodeum. The mucosa was not arranged into distinct mucosal folds as compared to the rectum and the coprodeum. The mucosa was arranged in small folds or ridges that were barely visible macroscopically and were irregularly orientated, giving the urodeum the appearance of having a smooth mucosa.

The urodeum contained the openings for the left and right ureters and the left oviduct. The openings for the left and right ureters were located on the dorsal wall of the urodeum. The left and right ureter opened by a simple orifice, but it was observed that the opening of the right ureter was situated at the apex of a small papilla. The left ureter was closely associated with the larger opening of the left oviduct. The opening for the left ureter did

Figure 17-4. Coprourodeal fold of the cloaca. This fold is indicated by the pins and separates the coprodeum (C) from the urodeum (U). Note the large opening (arrow) of the left oviduct.

not sit at the apex of a papilla as compared to the right ureter.

The opening of the left oviduct was ventrolateral to the opening of the left ureter. The oviductal opening appeared as a broad slit that was significantly larger than the opening for the left ureter (Figure 17-4).

The final chamber of the cloaca was the proctodeum. The boundaries for this chamber were cranially the uroproctodeal fold and caudally the lips of the vent. The uroproctodeal fold as already mentioned appeared as a thick semilunar ridge which curved around the dorsal and lateral walls of the junction between the urodeum and the proctodeum and disappeared ventrally.

The mucosal folds of the proctodeum were taller than the folds of the urodeum. The mucosal folds were orientated longitudinally and separated by grooves. In fact the mucosal folds of this region were very similar to lamellae.

4. **Ligaments of the Oviduct**

The left oviduct was suspended from the dorsal body wall by the dorsal ligament of the oviduct. This ligament was a broad sheet of peritoneum that extended the entire length of the oviduct and attached to the dorsal surface of the oviduct. The dorsal ligament of the oviduct was extremely thin and contained numerous blood vessels, nerves and the ureter from the left kidney.

The dorsal ligament of the oviduct traveled dorsally under the medial side of the left ilium, ischium and pubis and attached to the dorsal body wall. The dorsal ligament was also tightly adhered to the medial side of the left kidney (Figure 18-4). The dorsal ligament was reinforced by peritoneum that reflected from the left kidney and the dorsal body wall.

The dorsal ligament of the oviduct had a cranial extension known as the cranial ligament of the infundibulum. This ligament was an extension of the mesentery of the dorsal ligament of the oviduct which traveled craniodorsally to attach to the medial side of the seventh and eighth thoracic ribs and to the pleura of the caudal tip of the left lung. The ligament was very thin at the cranial tip of the infundibulum. As the ligament extended craniodorsally to it's attachment to the seventh thoracic rib, it became thickened and cord-like. This ligament invaginated through the peritoneum of the abdominal cavity and attached to the medial side of the seventh thoracic rib and the pleura of the left lung (Figure 19-4).

The ventral ligament of the oviduct was the ventral extension of the dorsal ligament of the oviduct along the ventral surface of the left oviduct. This ligament extended from the tip of the lips of the infundibulum to the proximal part of the vagina where it blended in with the ventral surface of the vagina. A unique characteristic was as the

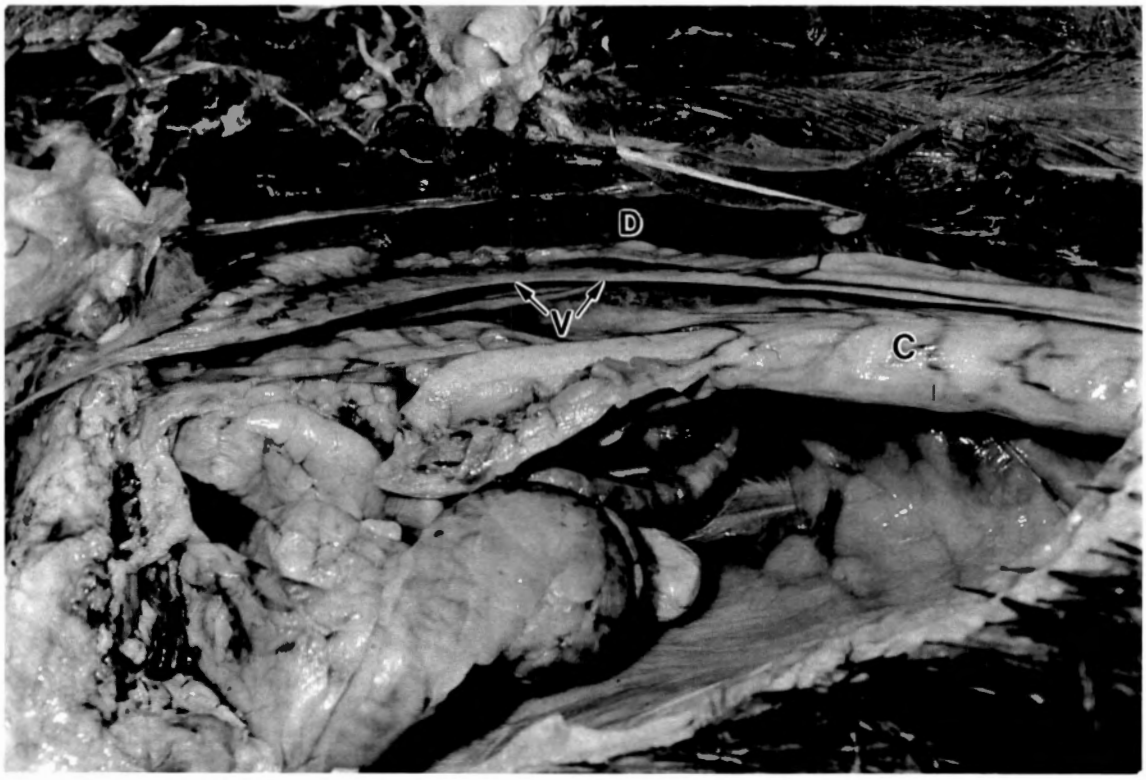

Figure 18-4. The dorsal and ventral ligaments of the oviduct.
(C) Descending colon
(D) Dorsal ligament of the oviduct
(V) Ventral ligament of the oviduct

Figure 19-4. Cranial ligament of the infundibulum. The ligament evaginates (arrow) through the peritoneum to attach to the pleura of the left lung.
(A) Adrenal gland
(I) Opened infundibulum
(K) Cranial lobe of the left kidney
(L) Lung
(S) Spleen
(V) Adrenal vein

ligament proceeded caudally it became progressively thicker. This thickening was first noticed around the isthmus and continued to the proximal part of the vagina (Figure 18-4).

5. **Vasculature**

a) **Arterial**

The arterial supply to the left ovary was accomplished by a branch from the left cranial renal artery. This artery branched from the lateral side of the descending aorta caudal to the tenth thoracic rib. This artery traveled under the ventral surface of the cranial lobe of the left kidney and bifurcated into a branch which penetrated into the parenchyma of the left kidney and the ovario-oviductal artery. The ovario-oviductal artery emerged from under the ventral surface of the cranial lobe of the left kidney and gave off branches to the ovary and the cranial extent of the oviduct (Figure 20-4).

The ovarian artery was the largest branch of the ovario-oviductal artery. It started out as a single branch from the ovario-oviductal artery, but gave off multiple branches that penetrated into the dorsal surface of the ovary near its middle one-third (Figure 20-4).

The arterial supply of the left oviduct was accomplished by the cranial oviductal artery, the accessory cranial oviductal artery, the middle oviductal artery, the caudal oviductal artery and the vaginal arteries. These

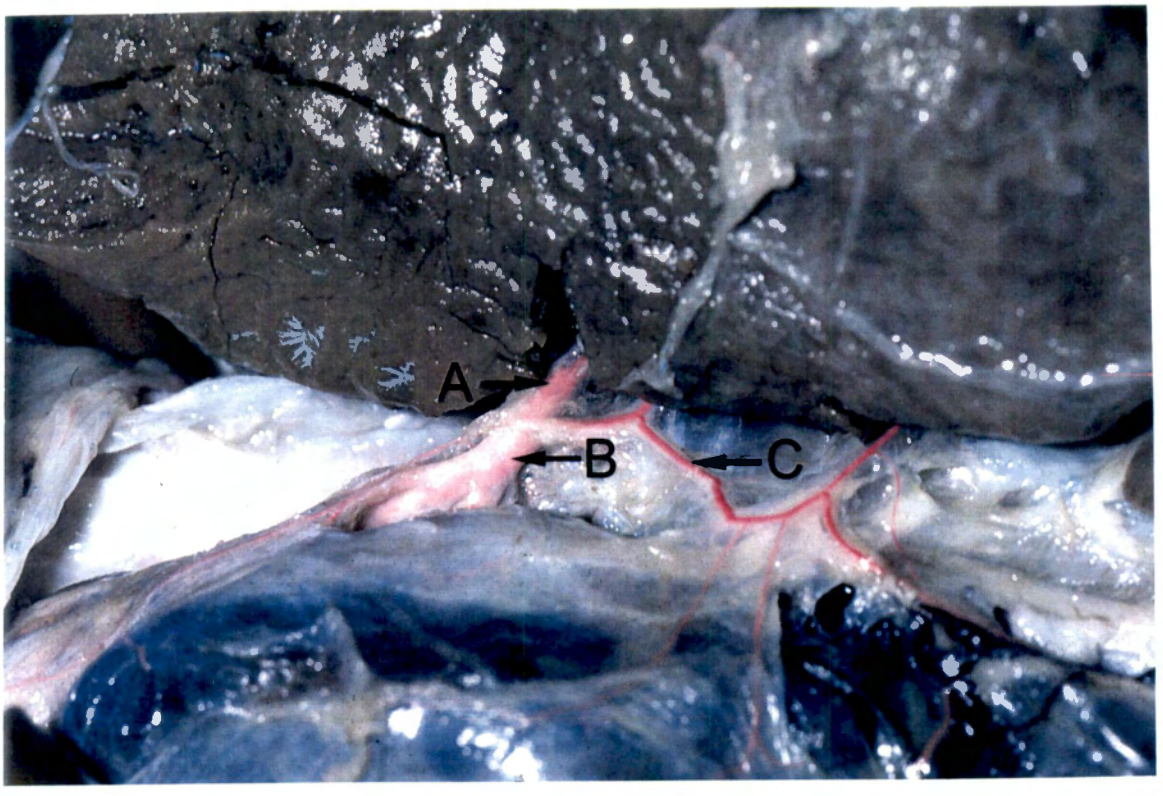

Figure 20-4. Arterial supply of the left ovary and cranial extent of the left oviduct.
(A) Ovario-oviductal artery
(B) Ovarain artery
(C) Cranial oviductal artery

arteries were branches of the left cranial renal artery, the left pubic artery (a branch of the left external iliac artery), the left middle renal artery and the left pudendal artery.

The most cranial artery of the oviduct was the cranial oviductal artery, a small branch of the ovario-oviductal artery (Figure 20-4). The cranial oviductal artery traveled caudally in the dorsal most extent of the dorsal ligament of the left oviduct before it turned ventrally. At this point it bifurcated into two branches that supplied the dorsal and ventral surface and the medial and lateral sides of the cranial extent of the oviduct (Figure 21-4). The cranial oviductal artery gave off several small branches that penetrated into the parenchyma of the cranial lobe of the left kidney. The main branch then traveled ventrally through the dorsal ligament of the oviduct to the dorsal surface of the left oviduct (Figure 20-4).

The main branch of the cranial oviductal artery as it traveled ventrally through the dorsal ligament of the oviduct bifurcated into a cranial and caudal branch. The cranial branch was very tortuous and supplied the dorsal surface plus the medial and lateral sides of the cranial and middle parts of the infundibulum. The caudal branch of the cranial oviductal artery supplied the dorsal surface, the medial and lateral sides of the caudal extent of the infundibulum, and the cranial portion of the magnum by a

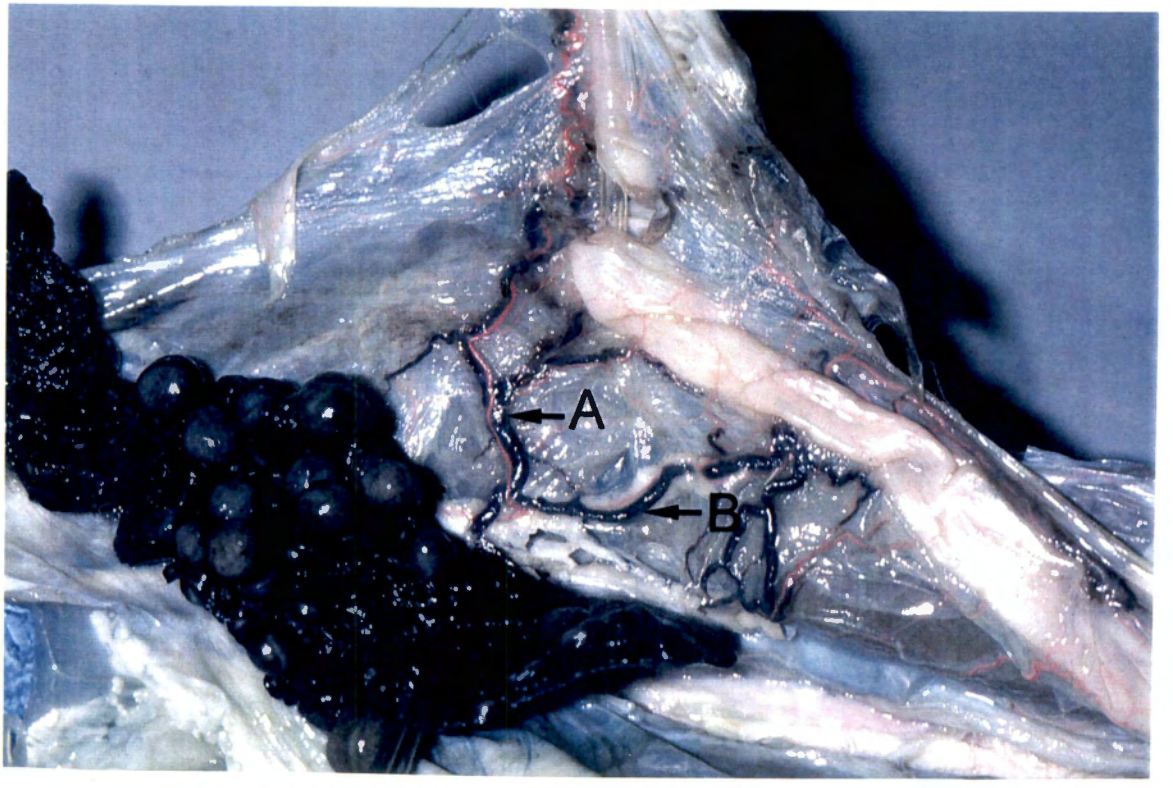

Figure 21-4. Cranial oviductal artery and vein.
(A) Cranial branch of the cranial oviductal artery and vein.
(B) Caudal branch of the cranial oviductal artery and vein.

large branch which traveled along the dorsal surface of this region of the oviduct (Figure 21-4). Also the caudal branch of the cranial oviductal artery gave off a branch which traveled to the ventral surface of the oviduct and anastomosed with the ventral marginal artery.

The next artery was the accessory cranial oviductal artery. It branched from the cranial extent of the left pubic artery (also known as the internal pelvic or the umbilical artery) near its origin from the left external iliac artery. After this artery gave off the accessory cranial oviductal artery, it traveled ventrocaudally along the lateral side of the middle lobe of the left kidney until it reached the ventral border of the pubis and paralleled it caudally.

The accessory cranial oviductal artery penetrated into the parenchyma of the middle lobe of the left kidney at its dorsal surface and emerged from under the ventral surface of middle lobe of the left kidney as a large single branch. Here it traveled ventrocaudally through the dorsal ligament of the oviduct to the dorsal surface of the oviduct giving off smaller branches. These small branches anastomosed with the caudal branch of the cranial oviductal artery and supplied the dorsal surface of the caudal extent of the infundibulum and the cranial and middle portions of the magnum.

As already mentioned, the accessory cranial oviductal artery started out as a large single branch which traveled ventrocaudally through the dorsal ligament to the dorsal surface of the oviduct. When this artery reached the dorsal surface of the caudal extent of the magnum it bifurcated. The first branch traveled caudally along the dorsal surface of the oviduct and eventually anastomosed with a branch from the middle oviductal artery. The second branch traveled ventrally along the lateral side of the magnum to the ventral surface and bifurcated into two branches, one branch traveled cranially and one traveled caudally in the ventral ligament of the oviduct. These branches anastomosed with the ventral marginal artery, a branch of the middle oviductal artery. These arteries supplied the ventral surface of the isthmus, magnum, and infundibulum (Figure 22-4).

The third artery that supplied the oviduct was the middle oviductal artery. This artery did not arise from the left ischiatic, but came from the left middle renal artery. The left middle renal artery was a small artery cranial to the left ischiatic and located on the dorsolateral side of the descending aorta. This artery penetrated into the parenchyma of the dorsal surface of the middle lobe of the left kidney and divided into three large branches. Two of the branches penetrated into the parenchyma of the kidney, while the third branch traveled caudally through the dorsal

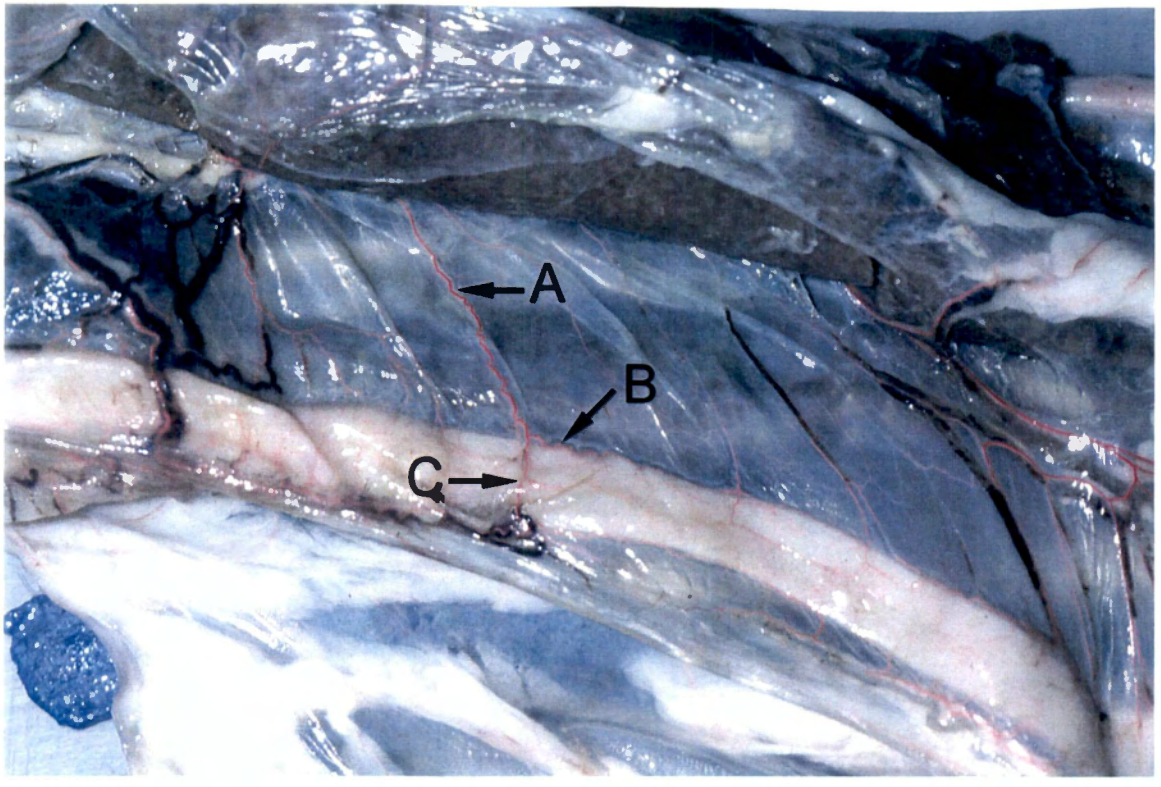

Figure 22-4. Accessory cranial oviductal artery and its branches.
(A) Accessory cranial oviductal artery
(B) Branch which anastomoses with a branch from the middle oviductal artery.
(C) Branch which anastomoses with the ventral marginal artery.

aspect of the kidney parenchyma. The middle oviductal artery was a branch of this third branch and emerged under the ventral surface of the caudal extent of the middle lobe of the left kidney.

The middle oviductal artery was a single branch that traveled ventrocaudally in the dorsal ligament of the oviduct and terminated by fanning out into multiple branches. The majority of these turned and went cranially, but one large branch traveled caudally along the dorsal surface of the uterus. Coming off one of the multiple branches were the medial (right) and lateral (left) cranial uterine arteries (Figure 23-4). The lateral (left) cranial uterine artery was better developed than the medial cranial uterine artery, and the branching pattern for the medial cranial uterine artery was not as well developed as that of the lateral cranial uterine artery and was difficult to follow. The lateral cranial uterine artery traveled down the lateral side of the uterus to the ventral surface and bifurcated into the ventral marginal and ventral uterine arteries.

The ventral marginal artery traveled cranially along the ventral surface of the oviduct and joined the cranial and caudal branches of the accessory cranial oviductal artery. These arteries supplied the ventral surface of the cranial extent of the uterus, the isthmus, the magnum, and the infundibulum (Figure 24-4).

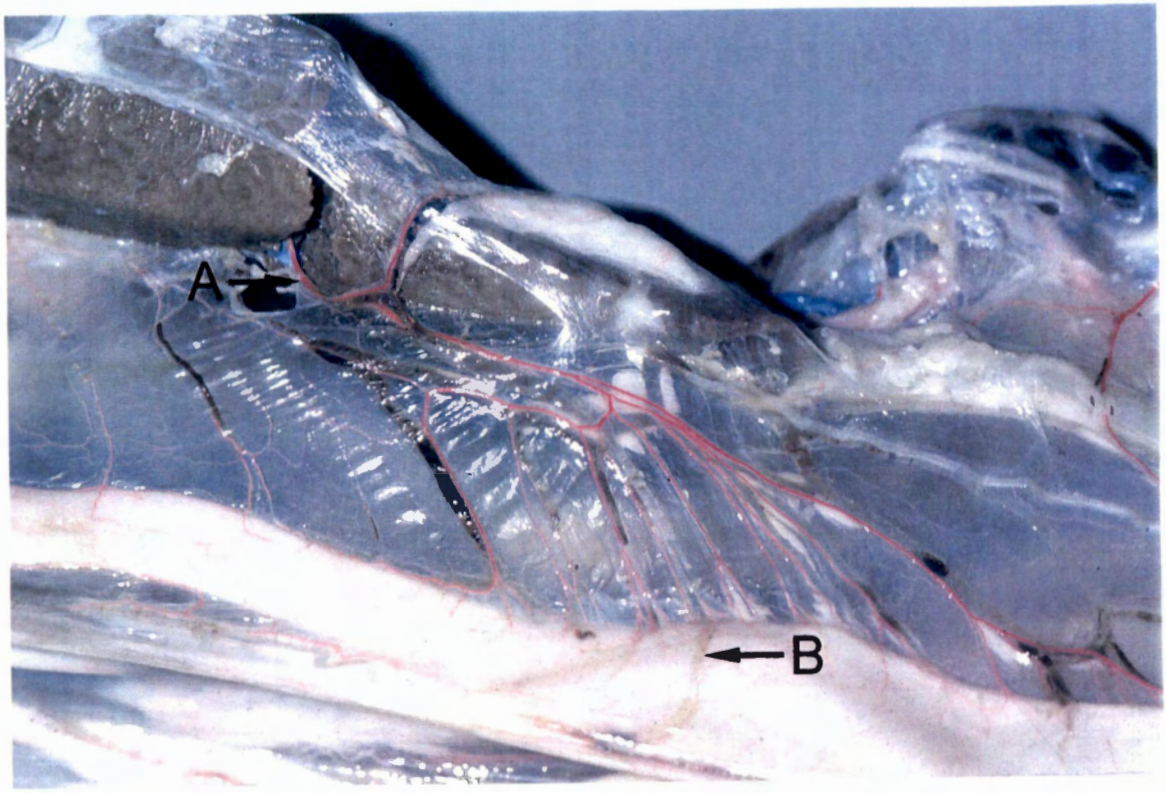

Figure 23-4. Middle oviductal artery.
(A) Middle oviductal artery emerging ventrally from the caudal extent of the middle lobe of the left kidney.
(B) Lateral cranial uterine artery not injected with latex.

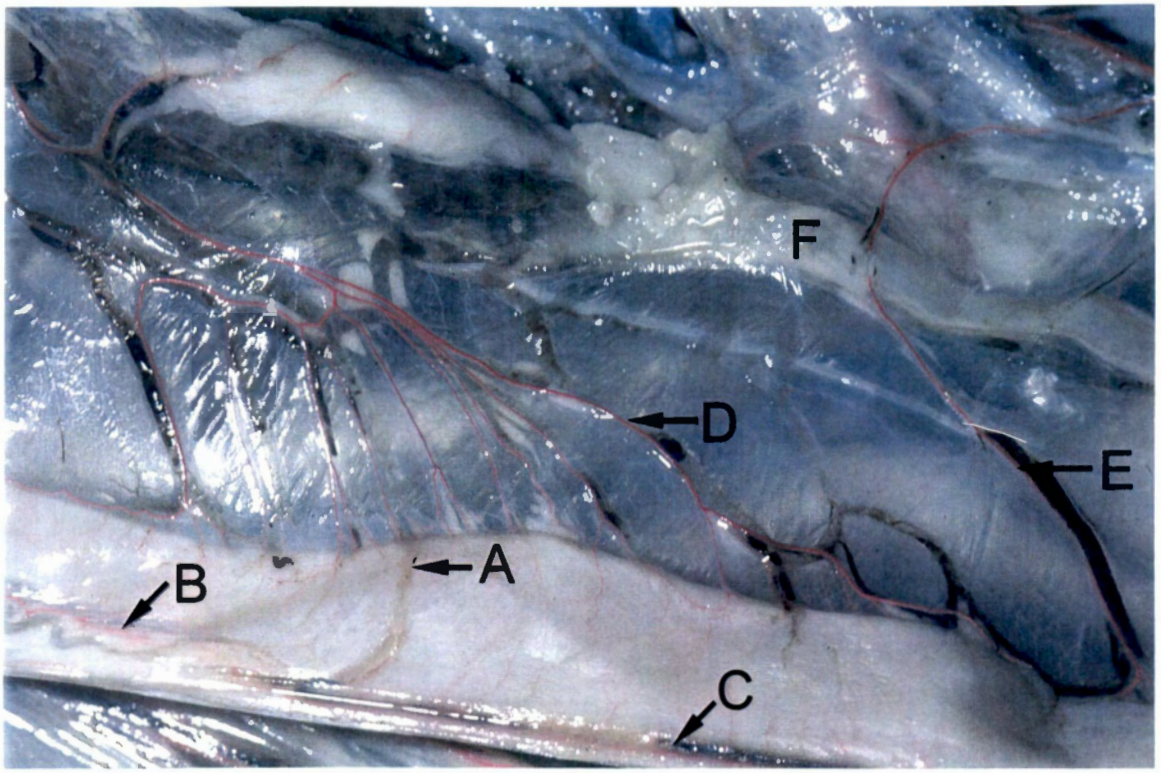

Figure 24-4. Branches of the middle oviductal artery.
(A) Lateral cranial uterine artery
(B) Ventral marginal artery
(C) Ventral uterine artery
(D) Dorsal uterine artery
(E) Caudal oviductal artery
(F) Left ureter

The ventral uterine artery traveled caudally along the ventral surface of the uterus. This artery supplied the ventral surface of the middle and caudal extent of the uterus and gave off numerous branches that supplied the medial and lateral sides of the uterus (Figure 24-4).

The final branch of the middle oviductal artery was the dorsal uterine artery. This artery was one of the largest branches of the middle oviductal artery and traveled ventrocaudally through the dorsal ligament to the dorsal surface of the uterus. This artery gave off multiple small branches to the medial and lateral sides of the uterus and terminated by anastomosing with the caudal oviductal artery along the dorsal surface of the uterus (Figure 24-4).

The caudal oviductal artery was the fourth artery that supplied the oviduct (Figure 25-4). It arose from a branch of the left internal iliac artery, cranial to where the left internal iliac bifurcated into the left pudendal and lateral caudal arteries. The branch which the caudal oviductal artery came from was a fairly large arterial branch and had multiple branches coming off in addition to the caudal oviductal artery (Figure 25-4).

The caudal oviductal artery traveled ventrally across the lateral side of the left ureter to the dorsal surface of the oviduct. At this point the artery bifurcated into a cranial branch which anastomosed with the dorsal uterine artery and a caudal branch which anastomosed with the

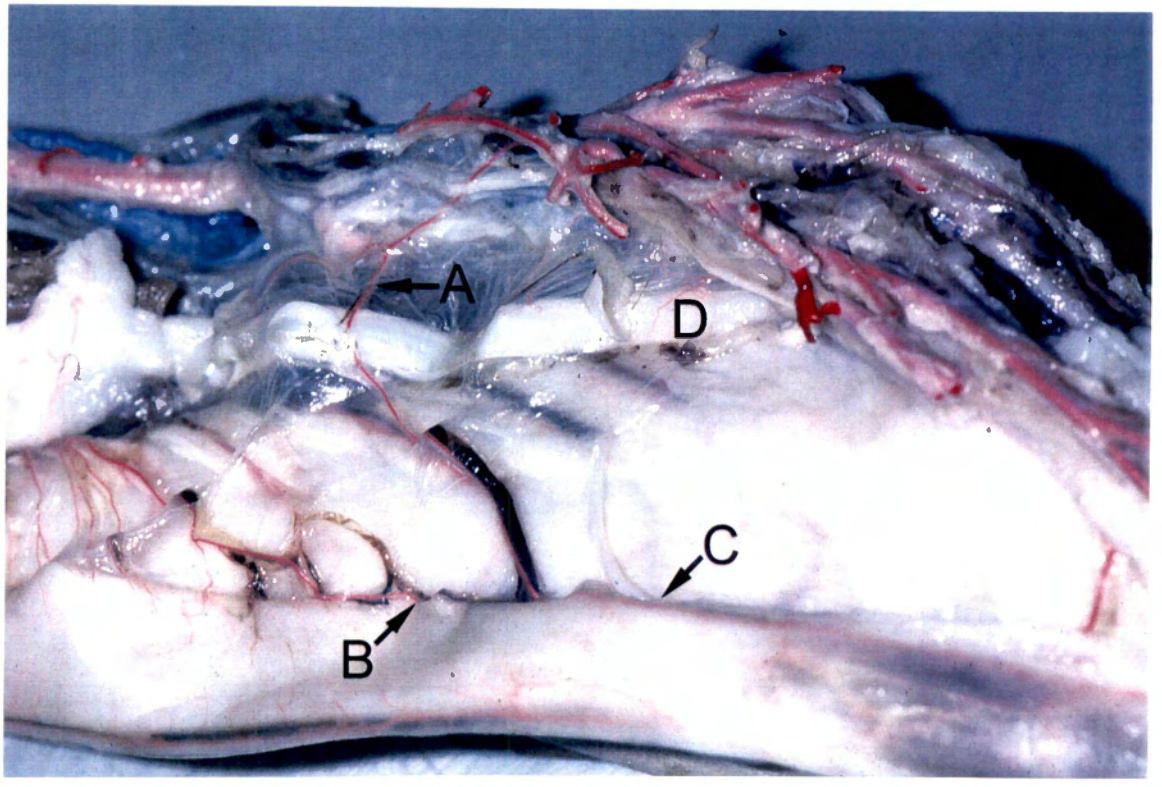

Figure 25-4. Caudal oviductal artery and its branches.
(A) Caudal oviductal artery
(B) Cranial branch which anastomoses with the dorsal uterine artery.
(C) Caudal branch which anastomoses with the lateral vaginal artery.
(D) Left ureter

lateral vaginal artery along the dorsal surface of the uterus and the vagina (Figure 24-4 and Figure 25-4).

The vaginal arteries were the caudal most arteries that supplied the left oviduct of the emu. These two arteries were branches of the left pudendal artery and supplied the medial and lateral sides of the vagina and the dorsal surface of the vagina.

The medial vaginal artery was a branch from the medial side of the left pudendal artery, cranial to the origin of the lateral vaginal artery. The medial vaginal artery traveled ventrally through the dorsal ligament of the oviduct along the medial side of the left ureter to the medial side of the vagina. The medial vaginal artery bifurcated into a cranial and caudal branch, which supplied the medial side of the vagina (Figure 26-4).

The lateral vaginal artery originated caudal to the medial vaginal artery and branched from the lateral side of the caudal end of the left pudendal artery. This artery gave off numerous branches to the caudal region of the lateral side of the vagina. The most prominent branch of the lateral vaginal artery was a cranial branch which traveled cranially along the dorsal surface of the vagina and anastomosed with the caudal branch of the caudal oviductal artery (Figure 27-4).

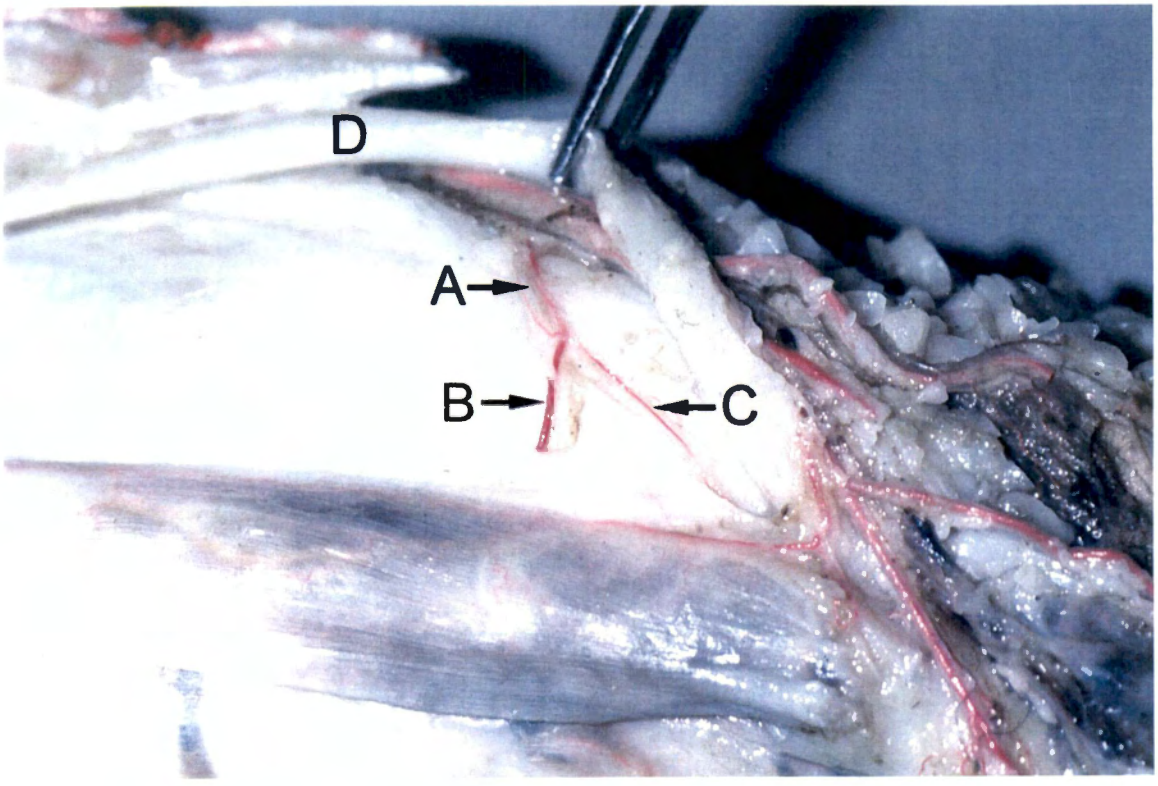

Figure 26-4. Medial vaginal artery and its branches.
(A) Medial vagainal artery
(B) Cranial branch of the medial vaginal artery.
(C) Caudal branch of the medial vaginal artery.
(D) Left ureter (displaced dorsally by forceps)

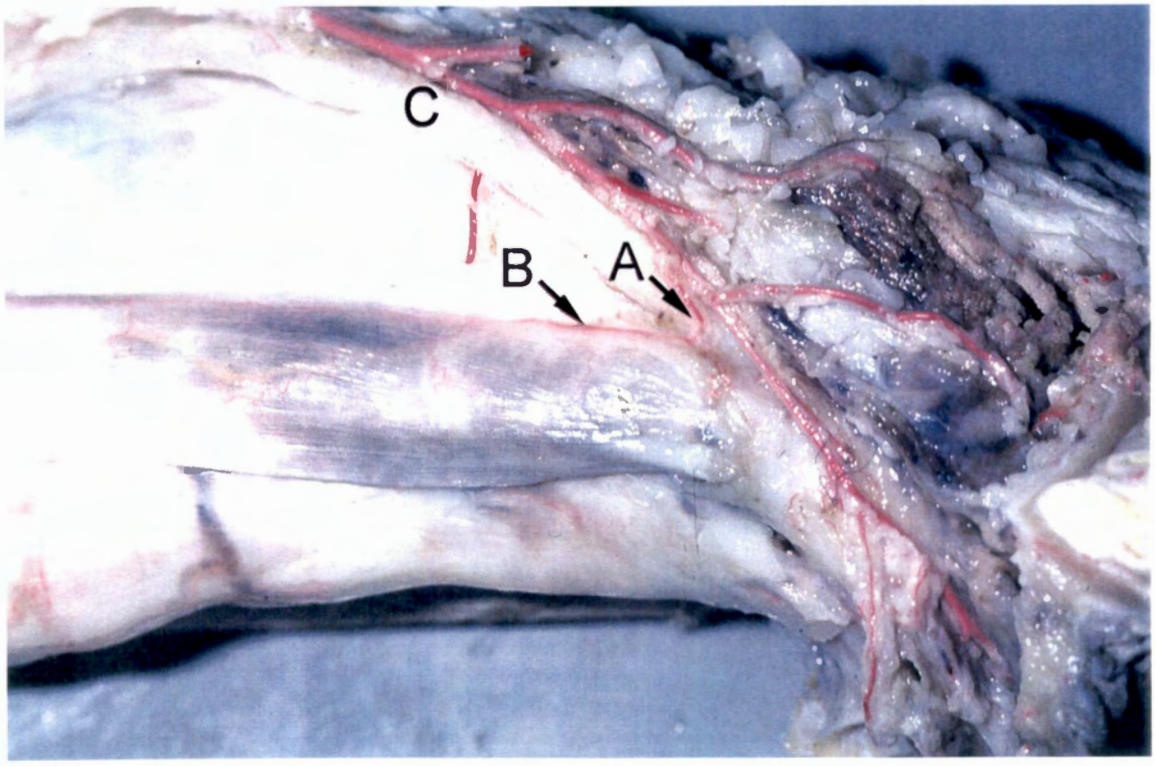

Figure 27-4. Lateral vaginal artery.
(A) Lateral vaginal artery
(B) Cranial branch of the lateral vaginal artery
(C) Left ureter

b) **Venous**

The left ovary of the emu was drained by a single ovarian vein. This vein was formed by the anastomoses of the veins from the follicular stalks of the left ovary. The left ovarian vein joined the adrenal vein from the left adrenal gland and emptied into the left common iliac vein and then into the left side of the caudal vena cava. The left adrenal vein was not only joined by the left ovarian vein but also received blood from the fifth through eighth left intercostal veins.

The adrenal glands of the emu were located along the medial side of the cranial lobe of the left and right kidneys, caudal to the ninth rib. These glands were elongated and measured 4 cm craniocaudally. The adrenal glands were held in position by tough connective tissue and fascia.

The venous return of the oviduct in the emu was accomplished by the cranial oviductal vein, accessory cranial oviductal vein, middle oviductal vein, caudal oviductal vein and the medial and lateral vaginal veins. These veins appeared as satellites of the arteries which supplied the oviduct.

6. **Innervation of the left ovary and oviduct**

The innervation of the left ovary of the emu was from the ovarian-adrenal plexus. This plexus arose from the

synsacral paravertebral trunk (sympathetic trunk) from nerves T6-T10 and L1-L2 (spinal nerves 24-30) (Figure 28-4 and Figure 29-4). The rami communicans from these spinal nerves emerged from the ventral branches just distal (ventrolateral) to the dorsal root ganglion, immediately after the dorsal branch of the spinal nerve was dispatched (Figure 28-4). Many branches (subvertebral synsacral plexus) arising from the synsacral paravertebral trunk converged and passed from medial to lateral through the left adrenal gland (Figure 30-4). As they emerged from the lateral surface of the left adrenal gland a large mass was formed. This large nervous tissue complex measured >4 mm and laid on the dorsolateral aspect of the ovary (Figure 30-4 and Figure 31-4). Nine to ten branches emerged from this large nerve complex and penetrated the parenchyma of the left ovary. Caudal to the left ovary, after the ovarian branches had been dispatched, there were smaller branches to the left oviduct. Hence, the nerve diminished in size as it continued toward the caudal end of the vagina (Figure 31-4). The only other nerve supply noted for the reproductive tract of the emu was from the left pudendal nerve which arose from the sacral plexus, caudal to the left acetabulum. This nerve followed the left pudendal vessels and entered with the left ureter at the vaginal-cloacal junction. The left pudendal nerve was formed by branches from S6-S10 (spinal nerves 37-40).



Figure 28-4. The ovarian plexus of the left ovary (lateral view). Inset: dorsolateral view.
(r) Rami communicans of T9
(s) Synsacral paravertebral trunk (sympathetic trunk)
(V) Ventral branch of spinal nerve T9
(L) Lateral dorsal branch of spinal nerve T9
(M) Medial dorsal branch of spinal nerve T9
(d) Dorsal root ganglion
(small white arrows) Branches of the subvertebral synsacral plexus to the adrenal plexus
(arrow heads) Ovarian nerve plexus
(R) Head of rib #9

Figure 29-4. The innervation of the left ovary.
(r) Rami communicans of T9
(s) Synsacral paravertebral trunk (sympathetic trunk)
(V) Ventral branch of spinal nerve T9
(L) Lateral dorsal branch of spinal nerve T9
(small white arrows) Branches of the subvertebral synsacral plexus to the adrenal plexus
(arrow heads) Ovarian nerve plexus

Figure 30-4. The ovarian-adrenal plexus.
(arrow heads) Branches of the subvertebral plexus forming the adrenal plexus
(black arrows) Ovarian portion of the plexus

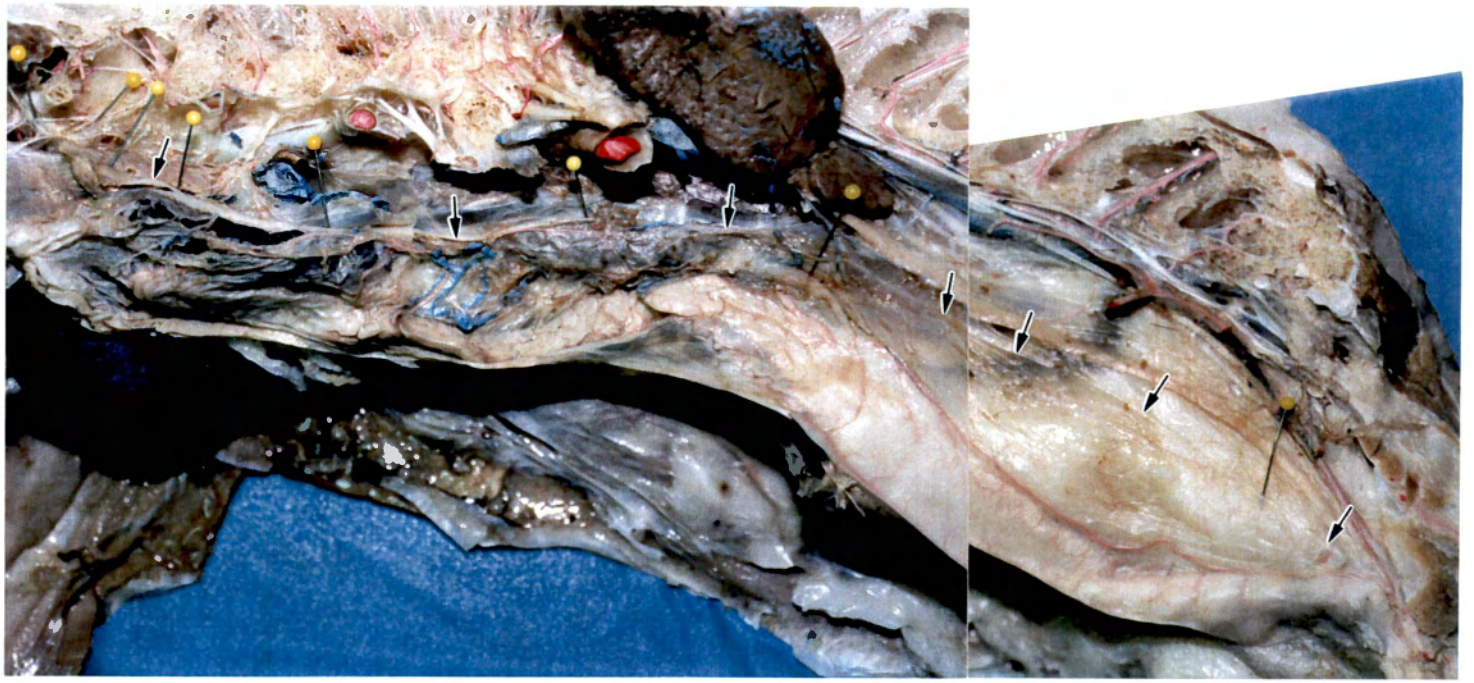

Figure 31-4. Collage of the ovarian plexus.
Arrows and pins indicate the course of the plexus and nerves.

In addition to the nerves of the ovarian-adrenal plexus, separate branches from the paravertebral trunk were observed supplying the celiac and cranial mesenteric plexuses. These plexuses supplied the gastrointestinal viscera of the emu. Cranial to thoracic vertebrae 7 the synsacral paravertebral trunk laid ventral to the vertebral bodies. Between thoracic vertebrae 7-8 the major thoracic splanchnic nerve was given off and coursed ventrocaudally to the celiac plexus. At this point, the synsacral paravertebral trunk turned dorsolaterally and laid on the ventral surface of the heads of the remaining ribs as it continued caudally, orientated in a more lateral position.

Chapter 5

DISCUSSION

Since little information on the morphology of the ratite was found in the literature, it was decided to compare our findings with the morphology of the domestic fowl, since considerable literature is available. Comparisons between these data in reproductively quiescent fowls would be ideal, however no information was found on physically mature but reproductively quiescent domestic fowl. The domestic fowl serves as a standard of avian reproductive anatomy.

Overall, the anatomy, including the vasculature and innervation, of the reproductive tract of the female emu and the domestic fowl were very similar. The reproductive tract of the female emu and the domestic fowl consisted of an ovary and an oviduct that was located on the left side of the abdominal cavity (Figure 3-4 and Figure 1-5)

1. **Ovary**

The left ovary of the emu was a dark brownish-black color and shaped like a misshapen triangle. The ventral surface of the ovary was covered with follicles of various sizes that were a light gray color. The majority of the follicles were not as large as those observed on the ovary of the domestic fowl and the largest follicles of the emu's

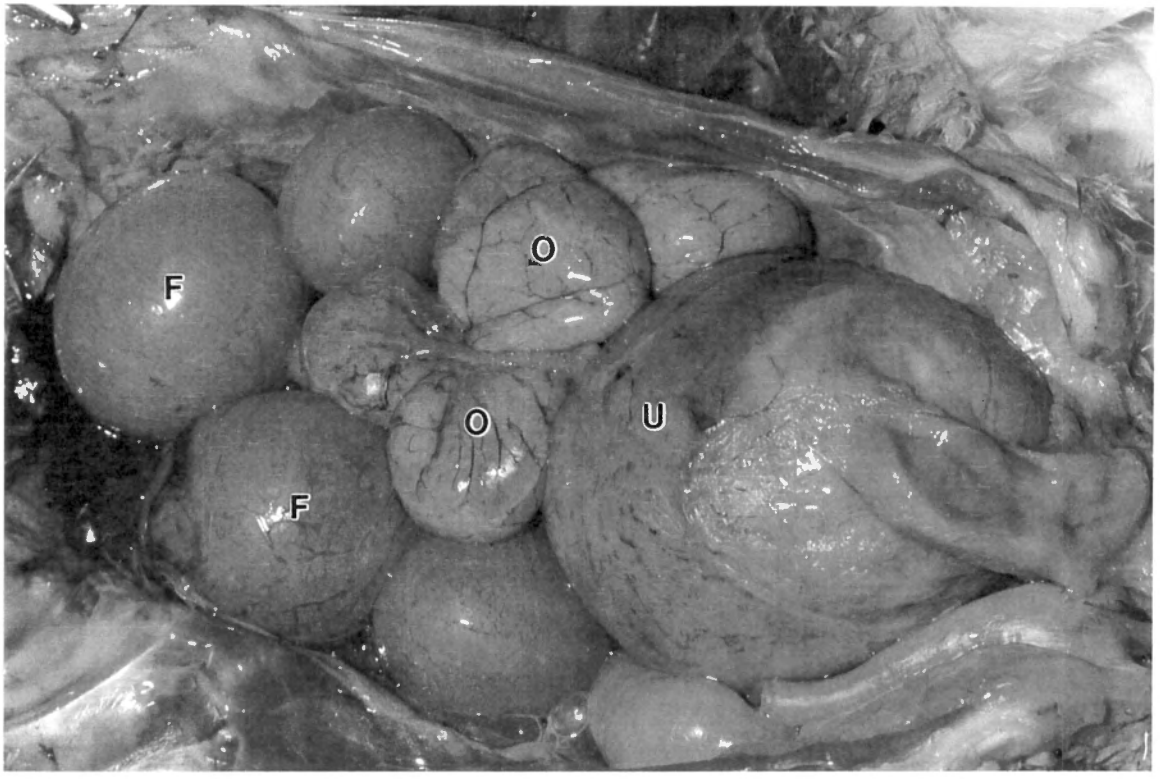

Figure 1-5. Left ovary and oviduct of an actively laying domestic fowl *in situ*.
(F) Follicles of the left ovary
(O) Left oviduct
(U) Uterus

left ovary measured 12 mm in diameter (Figure 1-4). The relative smallness of the emu's follicles was likely because the emus examined were two years of age and had not entered sexual activity at necropsy. The follicles were not fully developed.

In comparison the left ovary of the domestic fowl that is sexually mature is described as resembling a cluster of grapes with the size of the largest follicles being up to 40 mm in diameter (King, 1984; Getty, 1975) (Figure 2-5). This is due to the ventral surface of the ovary in the domestic fowl being covered with follicles of various sizes that are a light to dark yellow color (Getty, 1975).

The left ovary of the emu had an average length of 8.0 cm from cranial to caudal and an average width of 1.6 cm. While the left ovary of the domestic fowl when sexually active was often variable in shape and difficult to be consistently measured. However, Getty (1975) concluded that the left ovary of the domestic fowl was not less than 5 cm craniocaudally and transversely during sexual activity. It is presumed that the left ovary of an emu of similar sexual activity would be considerably larger as compared to the domestic fowl.

The left ovary of the emu and the domestic fowl were located on the left side of the abdominal cavity. The left ovary of the emu was associated with the cranial and middle lobes of the left kidney and medial to the spleen. The

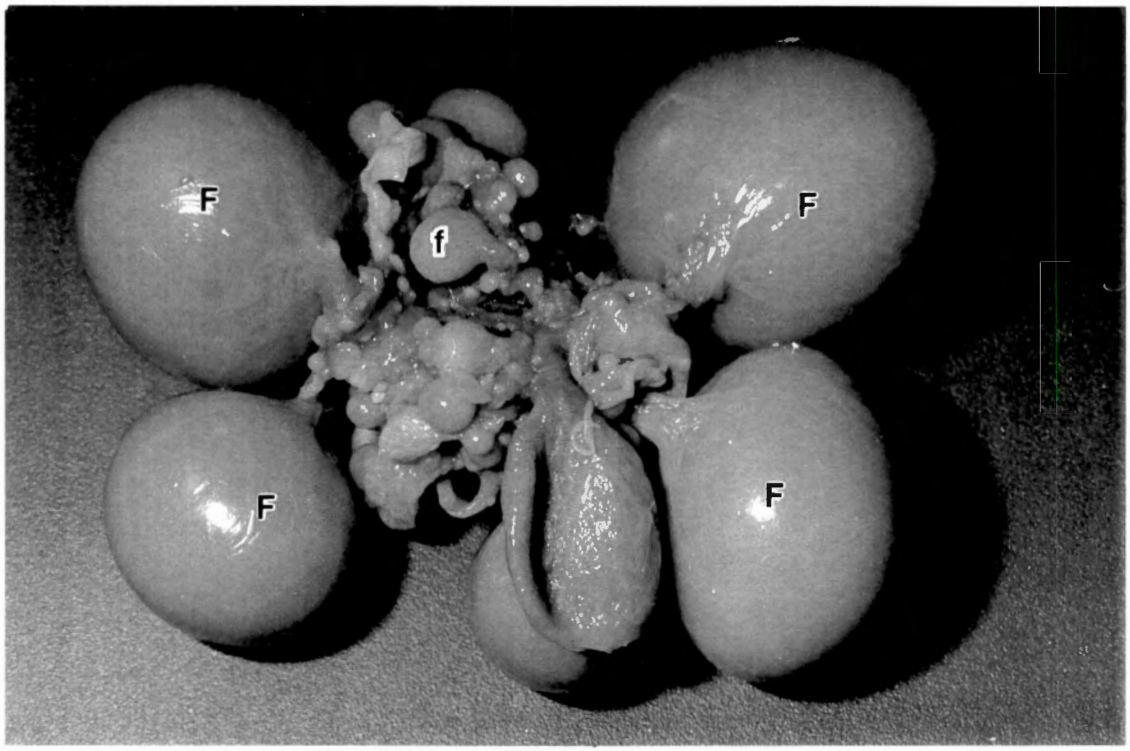

Figure 2-5. Left ovary from an actively laying domestic fowl *ex vivo*. Note the surface of the ovary covered with large and small follicles.
(F) Large follicles
(f) Small follicles

spleen of the emu was unique because it was crescent shaped and located on the left side of the abdominal cavity cranial to the left kidney. Earlier studies by Duerden 1912 of the anatomy of the ostrich had described the spleen as being on the left side of the abdominal cavity (Bezuidenhout, 1986). Although, an article by Bezuidenhout (1986) contradicted these earlier descriptions and described the spleen as a sausage-shaped organ that was located on the right side of the abdominal cavity in the ostrich.

The left ovary of the domestic fowl was also associated with the cranial lobe of the left kidney and occupied the dorsal part of the mid-region of the abdominal cavity (King, 1984; Getty, 1975). The left ovary depending on its development could sometimes overlap the cranial lobe of the right kidney (King, 1984; Getty, 1975).

The kidneys of the emu and the domestic fowl were similar in structure and anatomical location. The left kidney was important because of its association with the left ovary and oviduct. The kidneys of the emu were located along the ventral aspect of the ilium and the synsacrum and medial to the ischium. Also the kidneys of the emu extended from the middle of the ilium to the middle of the synsacrum, while in the ostrich they extended from the last rib to the middle of the ilium (Bezuidenhout, 1986). In comparison the kidneys of the domestic fowl were located along the ventral surface of the synsacrum (Getty, 1975; Nickel, 1977). They

extended cranially to the caudal tip of the lungs while the caudal extent of the kidneys reached to the end of the synsacrum (Nickel, 1977; Getty, 1975).

The kidneys of the emu and the domestic fowl consisted of three lobes (cranial, middle and caudal). In the emu the cranial, middle and caudal lobes were separated by the external iliac and ischiatic arteries on the dorsal surface of the kidneys. While in the domestic fowl, the division between the three lobes by the external iliac and ischiatic arteries was along the ventral surface of the kidneys (Nickel, 1977; Getty, 1975).

2. **Oviduct**

The oviduct of the emu, like that of the domestic fowl, could be divided into the five regions from cranial to caudal. The anatomy of the regions of the oviduct of the female emu and the domestic fowl were similar. Differences were often seen in the length of the various regions and sometimes in the pattern and orientation of the mucosal folds.

The oviduct of the reproductively quiescent female emu was a long nearly straight tube that extended from the cranial extent of the left ilium near the ninth thoracic rib to the caudal border of the left pubic bone. The left oviduct was not convoluted and did not occupy a majority of the left side of the abdominal cavity as compared to the

domestic fowl. In fact, the left oviduct was usually covered by loops of small intestine (Figure 3-4).

In comparison the oviduct of the mature reproductively active domestic fowl is very convoluted and occupied most of the left dorsal and ventral parts of the abdominal cavity (Getty, 1975). The coils of the oviduct were so tightly packed in the laying hen that no other viscera protruded between the coils (Getty, 1975). In fact the intestines were often pushed to the right side of the abdomen (Getty, 1975; Nickel, 1977) (Figure 1-5).

a) **Infundibulum**

The infundibulum of the emu and the domestic fowl were very similar in appearance. The average length of this region in the emu was 3.8 cm as compared to the 7.0 cm length of the actively laying domestic fowl.

The funnel portion of the infundibulum in the emu opened by an elongated slit known as the ostium infundibulare with finger-like projections around its perimeter. In the emu, the average length of the ostium infundibulare was 6.2 cm, while in the laying domestic fowl the average length was 9 cm (King, 1984; Getty, 1975).

The mucosal folds of the infundibulum had the same pattern and orientation in both the emu and the domestic fowl. The main difference was that the mucosal folds of the tubular region, which have a slight wavy pattern and are

orientated longitudinally, were not clearly visible in the funnel portion of the emu (Figure 6-4). The mucosal folds were also extremely low in the tubular region of the emus examined as compared to the domestic fowl and may be present in the funnel but were not visible macroscopically.

b) **Magnum**

This region of the oviduct wasn't coiled in the emu. It was a short region that was straight and had an average length of 4.8 cm. It is presumed that this region was short because the emus examined were just becoming sexually active and the oviduct had not completed the seasonal differentiation and growth which increases the length of the oviduct in the domestic fowl. This may also explain the relative shortness of the emu's magnum as compared to Marshall's (1995) description that this region in the reproductively active female emu was the longest section of the left oviduct.

In comparison, to these findings this region of the oviduct in the domestic fowl is described as the longest and most coiled part of the oviduct (Getty, 1975). The average length of this region in the laying hen was 34 cm (Getty, 1975; King, 1984).

This region of the oviduct in both the emu and the domestic fowl was characterized by the enlargement of the mucosal folds and the wavy pattern of the folds. These folds

were greatly enlarged when compared to those of the infundibulum in the emu and the domestic fowl. The mucosal folds in this region of the oviduct in the emu did not appear to be taller than the mucosal folds in other regions of the oviduct as was the case in the domestic fowl. Both Getty (1975) and King (1984) described the mucosal folds of the magnum as taller and thicker than folds in the other regions of the oviduct of the domestic fowl (Figure 3-5). The wavy pattern of the mucosal folds were pronounced in both the emu and the domestic fowl. The mucosal folds of this region in the domestic fowl were taller and thicker forming two patterns. In regions of the magnum distal to the developing egg, the folds appeared as longitudinal ridges with the surface of the folds being indented (Figure 3-5). Then in regions adjacent to the egg the folds were pressed against the wall of the magnum and the wavy pattern which was characteristic of this region was more easily seen (Figure 4-5).

As already mentioned the increase in the height of the mucosal folds in this region of the left oviduct in the emu was not as significant as that seen in the domestic fowl. Also the wavy pattern of the mucosal folds in the emu appeared to be more distinct in this region than in the domestic fowl (Figure 8-4).

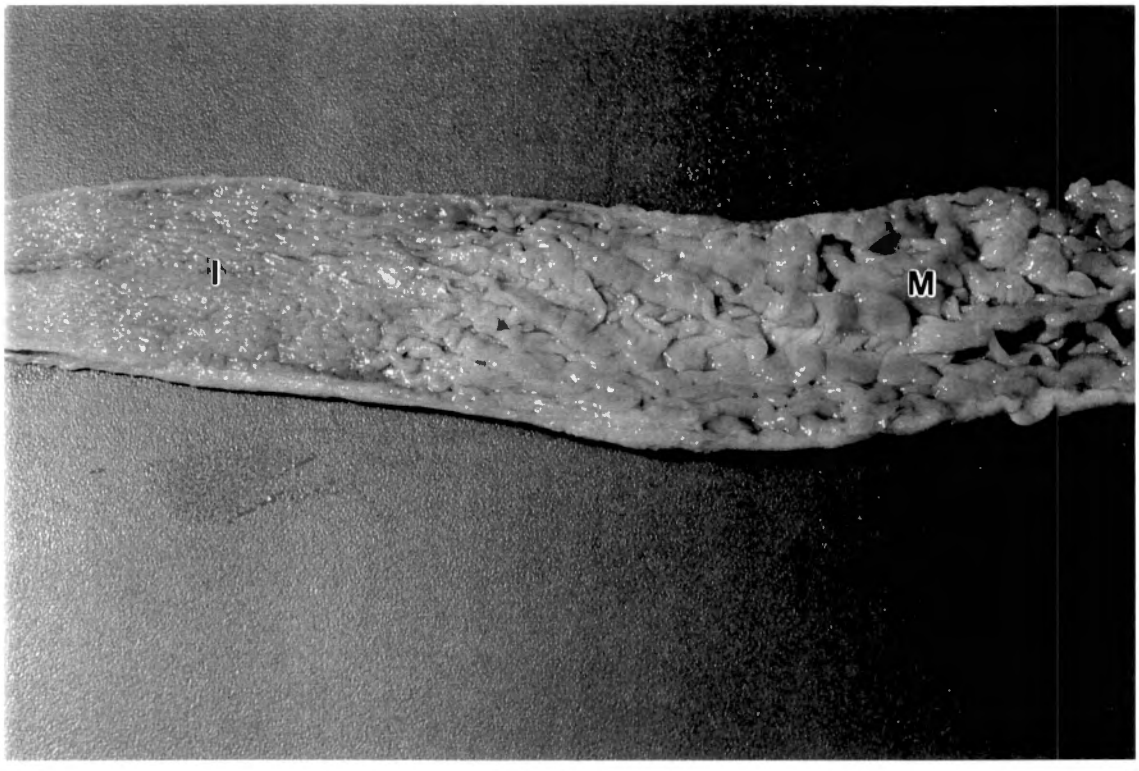

Figure 3-5. Mucosal folds of the magnum in the domestic fowl.
(I) Infundibulum
(M) Magnum

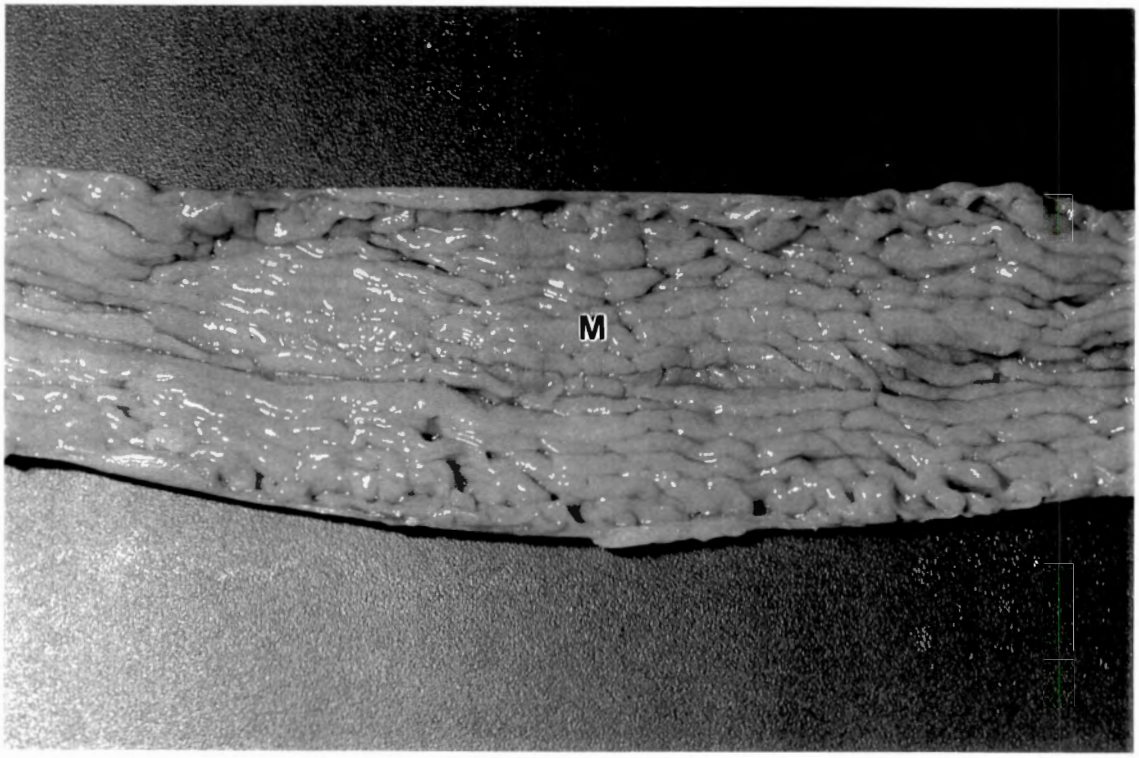

Figure 4-5. Mucosal folds of the magnum in the domestic fowl after an an egg had passed.
(M) Magnum

c) **Isthmus**

The isthmus of the emu was a relatively short region, with an average length of 5.8 cm. There did not appear to be a distinct decrease in the calibre of the isthmus when compared to the magnum as reported in the domestic fowl (King, 1984; Getty, 1975). Therefore in the emu, the isthmus could not be distinguished from the magnum by differences in calibre. To distinguish the isthmus from the magnum in the emu, it was necessary to view the mucosa of this region. The only change in calibre was observed at the transition from the isthmus to the uterus in the emu (Figure 10-4). It was at this point that there was an increase in the calibre of this region of the oviduct.

This region in the domestic fowl was relatively short, with an average length of 8 cm (King, 1984). It was characterized by a distinct decrease in the calibre of this region as compared to the magnum and uterus (King, 1984; Getty, 1975) (Figure 5-5).

The mucosal folds in the isthmus of both the emu and the domestic fowl were not as prominent as those of the magnum. The mucosal folds in the isthmus of the emu were orientated obliquely with a slight wavy pattern (Figure 11-4). While the mucosal folds in the isthmus of the domestic fowl were longitudinally orientated without a wavy pattern (Figure 6-5).

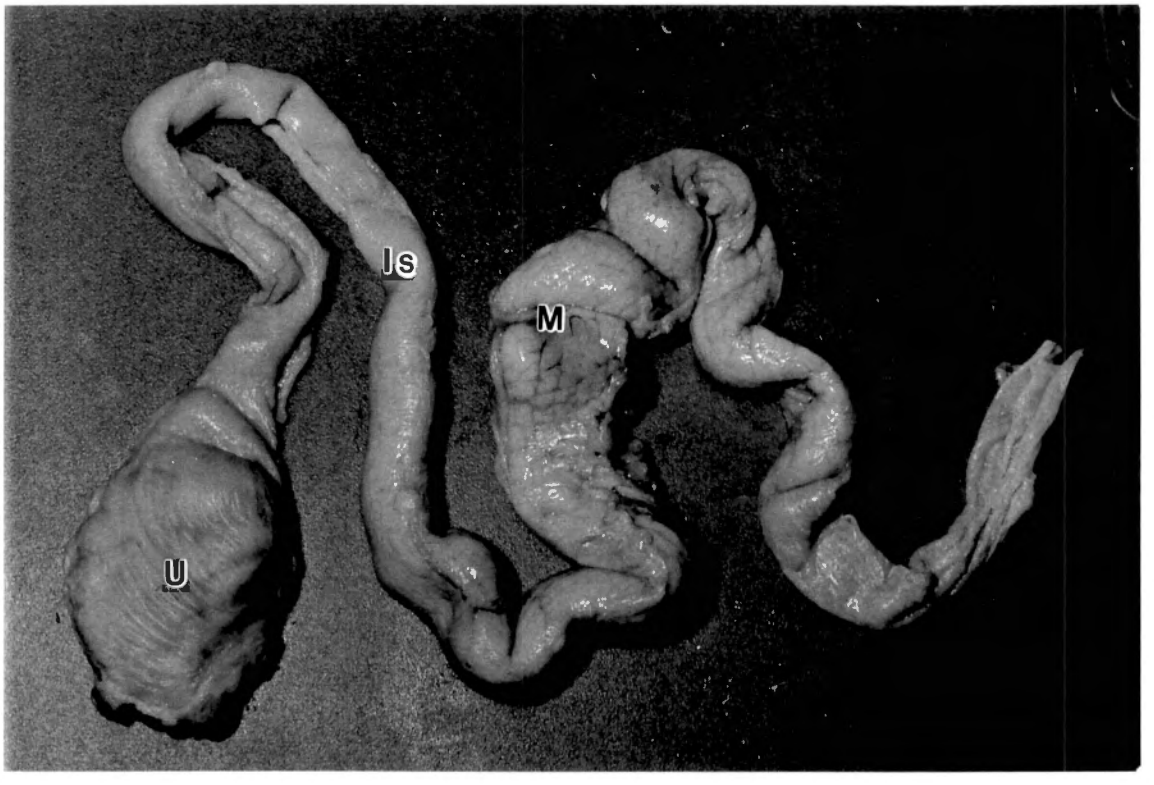

Figure 5-5. Left oviduct of the domstic fowl *ex vivo*.
(Is) Isthmus
(M) Magnum
(U) Uterus

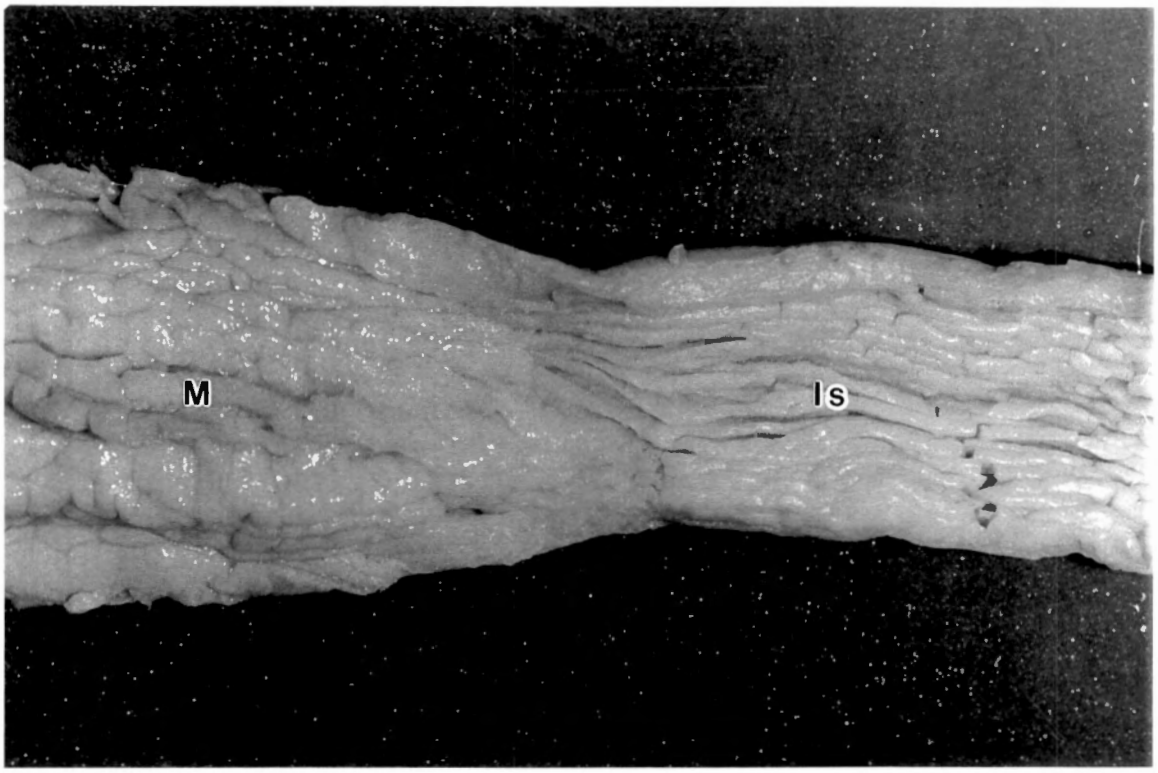

Figure 6-5. Mucosal folds of the isthmus of the domestic fowl.
(Is) Isthmus
(M) Magnum

The boundary between the isthmus and the magnum is demarcated by the zonula translucens in domestic fowl (King, 1984; Baumel, 1993). This area is a glandless zone at the beginning of the isthmus which is visible macroscopically in fresh tissue (Baumel, 1993). The zonula translucens was not observed in any of the oviducts from the emus examined. However, all the specimens were formalin fixed before they were examined grossly, which might explain it not being seen macroscopically.

d) **Uterus**

The uterus of the emu appeared as an elongated pouch-like region which had an average length of 9.6 cm (Figure 10-4). There were no demarcations present which could be used to divide the uterus into the three regions described in the domestic fowl.

The uterus in the domestic fowl is a relatively short region, approximately 8 cm in length (King, 1984). Controversy exists as to whether or not the uterus can be divided into three regions: the pars cranialis, the pars major uteri and the resessus uterinus (Baumel, 1993). This controversy exists mainly because the first region, the pars cranialis is only clearly visible during calcium transfer (Baumel, 1993). Otherwise, this region could be mistaken for the caudal extent of the isthmus macroscopically (Baumel, 1993).

In both the emu and the domestic fowl, the major portion of the uterus was the pouch-like region, which was referred to as the pars major uteri. The major difference between this region, was in the emu it was an elongated region whereas in the domestic fowl this region was rounded and 4-5 cm in length (Figure 10-4 and Figure 5-5).

The mucosal folds of the uterus in the emu and the domestic fowl were also distinctly different. The mucosal folds of the uterus in the emu were continuous and orientated at an oblique angle at the beginning of the uterus and changed to longitudinal near the caudal extent of the uterus. The mucosal folds unlike those of the domestic fowl were not intersected by transverse furrows or grooves. Instead they had a slight wavy pattern, which was more pronounced in the middle and caudal portions of the uterus and along the medial side rather than the lateral side of the uterus (Figure 12-4).

In contrast the mucosal folds of this region in the domestic fowl were described as leaf-like lamellae, due to the folds being intersected by transverse and oblique furrows (King, 1984; Getty,1975). This modification of the folds resulted in them appearing to be discontinuous and longitudinal when compared to other mucosal folds (King, 1979) (Figure 7-5).

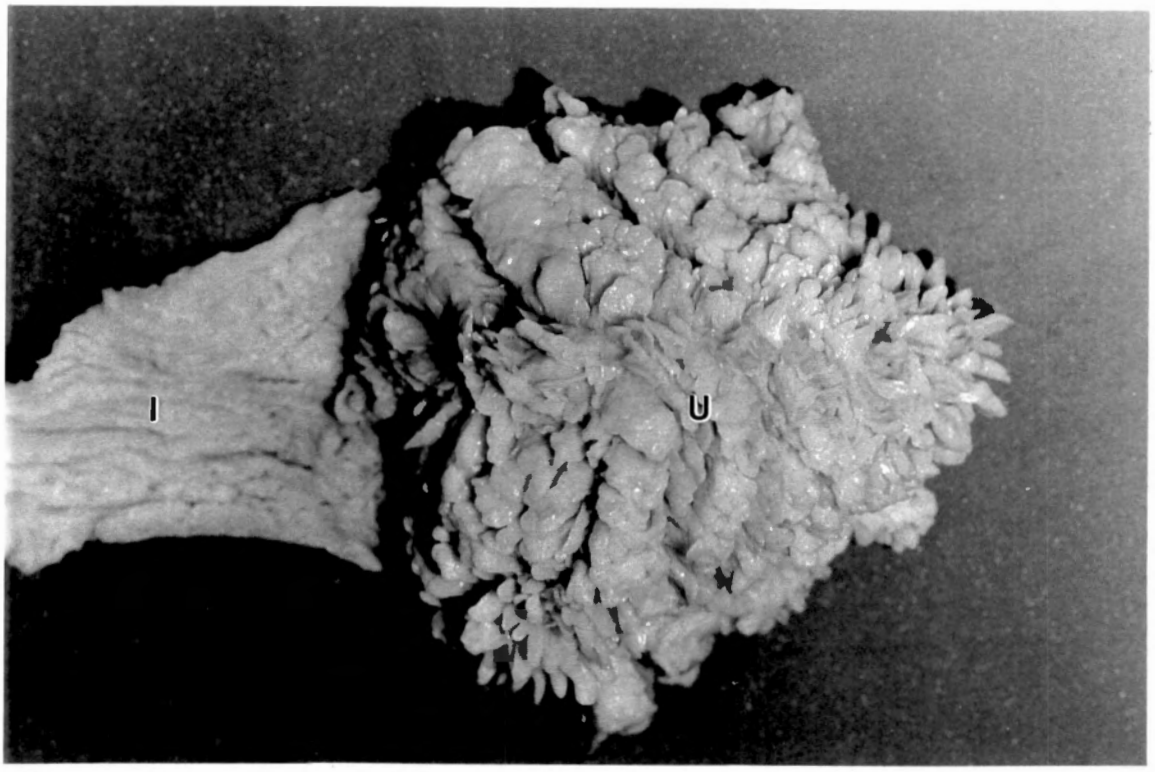

Figure 7-5. The mucosal folds of the uterus of the domestic fowl.
(I) Isthmus
(U) Uterus

e) **Vagina**

The vagina was the final region of the oviduct in both the emu and the domestic fowl. There were distinct differences in the anatomy of this region in the emu and the domestic fowl. The vagina of the emu was a short region that was not fixed in the characteristic s-shape and had an average length of 7 cm. The medial side of the caudal extent of the vagina in the emu was attached to the descending colon by a ligamentous structure. In comparison the characteristic s-shape of the vagina in the domestic fowl is maintained by the dorsal and ventral ligaments of the oviduct. These ligaments attached the vagina to the uterus, coprodeum and the adjacent body wall (Getty, 1975).

The vagina of the domestic fowl which is described as a short muscular s-shaped tube having an average length of 8 cm in the laying hen (King, 1984; Getty, 1975). It is also characterized by the thickening in the tunica muscularis along with the presence of a strong vaginal sphincter (King, 1984; Getty, 1975; Baumel, 1993).

The mucosal folds in the emu were taller than the mucosal folds in the domestic fowl. The folds were orientated longitudinally with the surface of the folds having a roughened appearance. The mucosal folds were folded upon each other in a wavy pattern which appeared to decrease the lumen of the vagina and give this region a thickened appearance macroscopically (Figure 15-4). It is

undetermined at this time if this modification in the arrangement of the mucosal folds resulted in the formation of a vaginal sphincter as described in the domestic fowl.

The mucosal folds in the domestic fowl are described as being longitudinally orientated (King, 1984; Getty, 1975). They are considerably thinner and lower than folds in any other region of the oviduct, except in the funnel of the infundibulum (King, 1984; Getty, 1975). The mucosal folds are also mashed together which decreases the lumen by forming the vaginal sphincter (Getty, 1975). However, it is questionable as to whether a true sphincter exists and if it does, is it located at the cranial extent of the vagina or at the uterovaginal junction (Figure 8-5).

3. **Cloaca**

The cloaca of the emu and the domestic fowl consisted of three chambers from cranial to caudal. The cranial most chamber was the coprodeum, followed by the urodeum and the proctodeum, the caudal most chamber.

The cloaca of the emu and the domestic fowl were divided internally by the coprourodeal fold and the uroproctodeal fold into the three chambers. There was not a mucosal fold which separated the rectum from the coprodeum in the emu or the domestic fowl. This mucosal junction was unmarked, except in the ostrich where there was a rectocoprodeal fold (King, 1981). The only demarcation from

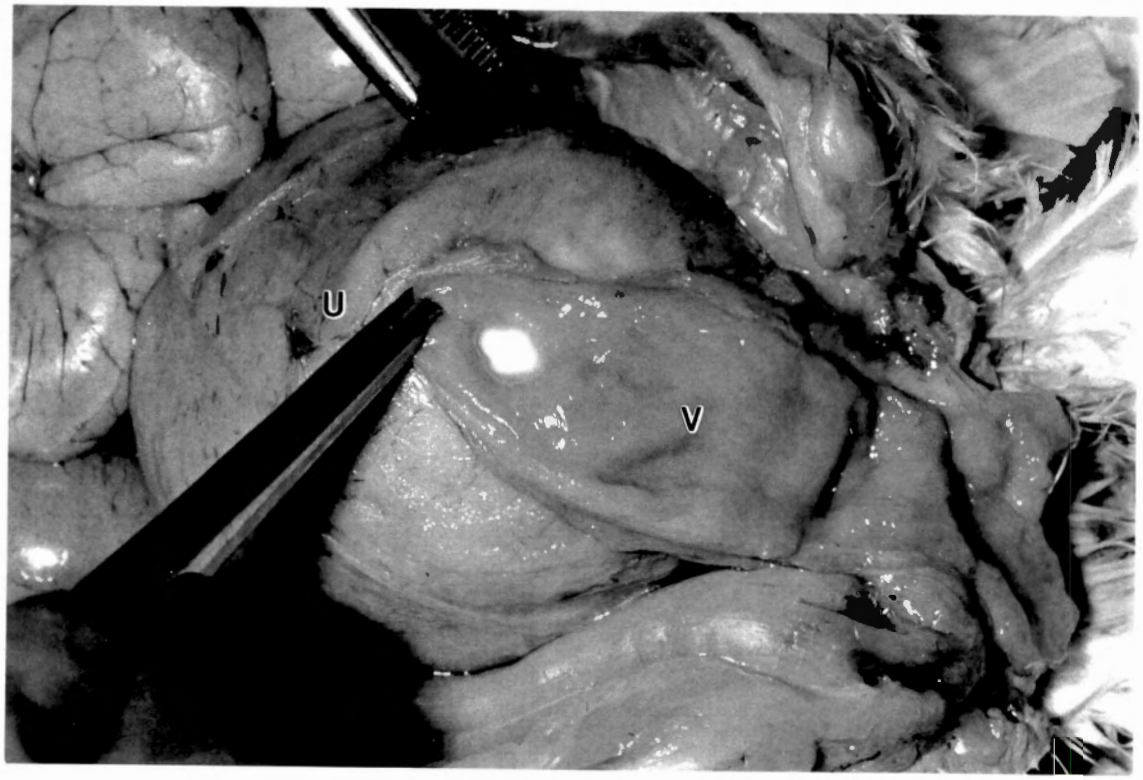

Figure 8-5. The mucosal folds of the vagina from an actively laying hen.
(U) Uterus containing an egg
(V) Vagina

the rectum to the coprodeum in the emu was a change in the pattern and orientation of the mucosal folds of the rectum as compared to the coprodeum.

The urodeum, the middle chamber was similar in both the emu and the domestic fowl. The boundaries for this chamber were the coprourodeal fold cranially and the uroproctodeal fold caudally. The urodeum also contained the openings for the left and right ureter and the left oviduct.

The mucosa of the urodeum of the emu and the domestic fowl was smooth when compared to the coprodeum. The mucosa was arranged in small folds which were irregularly orientated and sometimes intersected by longitudinal or oblique furrows.

The proctodeum was the caudal most chamber in the emu and the domestic fowl and was located between the uroproctodeal fold and the lips of the vent. This fold was well developed in both and curved around the dorsal and lateral walls and disappeared ventrally.

The mucosa of the proctodeum in the emu and the domestic fowl was arranged in folds that were orientated longitudinally with depressions or grooves between the mucosal folds.

4. **Ligaments of the Oviduct**

The left oviduct of the female emu and the domestic fowl was suspended by the dorsal ligament of the oviduct.

The dorsal ligament of the oviduct in the emu extended from the dorsal body wall and was tightly adhered to the medial side of the left kidney and the ischium. In comparison the dorsal ligament of the oviduct in the domestic fowl, extended from the dorsal abdominal wall along the medial side of the left kidney to the oviduct (King, 1984; Nickel, 1977).

A unique feature of the dorsal ligament of the oviduct in both the emu and the domestic fowl was the cranial ligament of the infundibulum. In the emu the cranial ligament of the infundibulum attached to the medial side of the left seventh thoracic rib and the pleura of the caudal tip of the left lung. Whereas in the domestic fowl the cranial ligament of the infundibulum attached to the left sixth or seventh thoracic rib and the medial side of the cranial lobe of the left kidney (Getty, 1975).

The cranial ligament of the infundibulum in both the emu and the domestic fowl placed the ostium infundibulare in a good position to catch ovum during ovulation.

The ventral ligament of the oviduct was the ventral extension of the dorsal ligament of the oviduct in both the emu and the domestic fowl. In the emu and the domestic fowl the ligament extended from the caudal tip of the funnel of the infundibulum to the proximal part of the vagina. This ligament was unique because it became thickened near the uterus and the vagina in both the emu and the domestic fowl.

5. **Vasculature**

a) **Arterial**

Seven arteries supplied the ovary and oviduct of the emu as compared to the five arteries that supplied the ovary and oviduct of the domestic fowl. The emu had three extra arteries due to the consistent presence of the accessory cranial oviductal artery which was usually described as being inconsistently present in the domestic fowl and two separate vaginal arteries.

Other than the number of vessels, the pattern of vasculature for the reproductive tract of the emu and the domestic fowl were very similar. Differences were mainly seen in the origin of the accessory cranial oviductal, the middle oviductal, the caudal oviductal and the vaginal arteries. The branching pattern and the areas supplied by the arteries were similar in both the emu and the domestic fowl.

The cranial most artery was the ovarian artery. This artery was a branch from the ovario-oviductal artery and branched from the cranial renal artery in both the emu and the domestic fowl.

In the emu, the ovario-oviductal artery emerged from under the cranial lobe of left kidney and divided dorsal to the ovary into the ovarian artery and the cranial oviductal artery. In contrast the ovario-oviductal artery of the

domestic fowl divided within the parenchyma of the ovary into the ovarian and the cranial oviductal artery (Getty, 1975).

The cranial arterial supply of the oviduct in both the emu and the domestic fowl was the cranial oviductal artery. This artery was a branch from the ovario-oviductal artery in both the emu and the domestic fowl. It supplied the dorsal surface of the infundibulum and the cranial extent of the magnum in both the emu and the domestic fowl. However, in the emu, the caudal branch of the cranial oviductal artery contributed to the arterial supply of the ventral surface of the infundibulum and magnum by anastomosing with the ventral marginal artery.

The next artery that supplied the oviduct was the accessory cranial oviductal artery. In the emus examined, this artery was a branch of the left pubic artery, a branch of the left external iliac artery. The accessory cranial oviductal gave off two distinct branches in the emu. The first one was a large anastomotic branch that joined a branch of the middle oviductal artery and supplied the dorsal surface of the magnum. The second branch traveled ventrally along the lateral side of the magnum to the ventral ligament and bifurcated to join the ventral marginal artery, which supplied the ventral surface of the infundibulum, magnum and isthmus.

This artery according to Hodges (1965), the accessory cranial oviductal artery, is inconsistently present in the domestic fowl, however it was consistently present in the emus. When this artery was present in the domestic fowl it was described as a branch from the femoral artery and supplied the dorsal surface of the middle and caudal regions of the magnum (Hodges, 1965).

The next artery was the middle oviductal artery. The main difference between this artery in the emu and the domestic fowl was the origin of the artery. In the emu, this artery was a branch of the left middle renal which came off the dorsolateral side of the descending aorta cranial to the left ischiatic artery. Whereas in the domestic fowl this artery could arise directly from the left ischiatic artery or from a branch of the left ischiatic artery (Getty, 1975; Baumel, 1993).

The branching pattern for this artery was similar in both the emu and the domestic fowl. This artery terminated by dividing into medial and lateral cranial uterine arteries and the dorsal uterine artery. The one difference between the emu and the domestic fowl was the pattern of the dorsal uterine artery. In the emu, the dorsal uterine artery anastomosed with the caudal oviductal artery. Also multiple small branches were given off to supply the medial and lateral sides of the uterus instead of distinct medial and lateral uterine arteries as in the domestic fowl.

The fourth artery that supplied the oviduct in the emu was the caudal oviductal artery. In the emu, this artery came directly off the left internal iliac cranial to it's bifurcation into the left pudendal and lateral caudal arteries. However Baumel (1993) and Getty (1975) reported that in the domestic fowl, this artery was a branch of the left pudendal artery, a branch of the left internal iliac artery. Whereas Hodges (1965) described the caudal oviductal artery as a branch of the left internal iliac artery cranial to it's bifurcation into the pudendal and lateral caudal arteries.

The caudal oviductal artery did not divide immediately into the medial and lateral caudal uterine arteries in the emu as was the case in the domestic fowl. The only clear division of this artery was at the dorsal surface of the uterus where the artery bifurcated into the two branches which joined the dorsal uterine artery and the lateral vaginal artery.

In the domestic fowl, the caudal oviductal artery divided immediately into the medial and lateral caudal uterine arteries to supply the caudal extent of the uterus and possibly the vagina (Getty, 1975; Baumel, 1993).

The caudal most arterial supply of the oviduct in the emu was accomplished by two separate vaginal arteries which were branches from the left pudendal artery. The first artery was the medial vaginal artery, which branched from

the medial side of the pudendal artery. It was cranial to the second artery, the lateral vaginal artery which branched from the lateral side of the pudendal artery.

However the final arterial supply of the oviduct in the domestic fowl was a single vaginal artery. This artery usually branched from the left pudendal artery, although occasionally it arose from the caudal oviductal artery (Baumel, 1993; Getty, 1975). Whether this artery was a branch from the left pudendal or the caudal oviductal artery it divided into the vaginal arteries which supplied the medial and lateral side of the vagina.

b) **Venous**

Unfortunately the venous system of the emu did not inject properly with latex, and the veins of the ovary and oviduct were difficult to dissect. Therefore, this area would require further examination for a better understanding of the venous drainage of the left ovary and oviduct.

The left ovary of the emu appeared to be drained by a single ovarian vein, which joined the left adrenal vein and emptied into the left side of the caudal vena cava. In comparison, the left ovary of the domestic fowl was drained by cranial, middle, and caudal ovarian veins which emptied into the left side of the caudal vena cava (Getty, 1975; King, 1984).

It appeared that the left oviduct of the emu was drained by veins that were satellites of the arteries that supplied the oviduct. The venous return of the oviduct in the domestic fowl was also accomplished by veins which were usually satellites of the arteries that supplied the oviduct (Getty, 1975; Hodges, 1965).

6. **Innervation of the left ovary and oviduct**

In both the emu and the domestic fowl, the left ovary received it's innervation from an ovarian plexus. However in the emu, the plexus which supplied the left ovary was a continuation of the fused fibers and apparently ganglia as they emerged from the lateral aspect of the left adrenal gland. From this mass, nine to ten distinct bundles of fibers penetrated the dorsum of the left ovary. It is presumed that fibers to the left adrenal were dispatched within the parenchyma of the left adrenal gland as the nerve fibers passed from medial to lateral. Whereas in the domestic fowl, the ovarian plexus is described as a continuous sheet of nervous tissue located along the dorsal surface of the ovary and ventral to the aorta (Gilbert, 1969; Getty, 1975). Earlier research attempted to divide the ovarian plexus into renal, adrenal, aortic, and ovarian plexus, but more recent research indicates that the division is unjustified (Gilbert, 1969; Getty, 1975). The majority of the fibers from this plexus were distributed to the ovary

with few nerves given to the adrenal gland or the left kidney (Getty,1975). In the domestic fowl, Getty (1975) indicated that 2-3 large adrenal ganglia are present. Dubbledman 1993 indicates that the ovarian/oviductal nerve plexus of the domestic fowl arises from the renal plexus with the adrenal plexus (Getty,1975). No grossly discernable individual ganglia were observed in the emu. Rather one large elongated mass was observed and presumed to be a consolidation of both nerve cell bodies (ganglia) and fibers. In comparison the majority of the fibers from this large mass in the emu were dispatched to the left ovary with some fibers continuing to the left oviduct and coursing with the vessels of the oviduct.

The only other observed nerve supply of the left oviduct in the emu was the left pudendal nerve which traveled with the pudendal vessels and entered with the left ureter at the vaginal-cloacal junction. Whereas in the domestic fowl, the sympathetic innervation of the left oviduct was accomplished by fibers from the hypogastric plexus which traveled with branches of the middle oviductal artery and the parasympathetic innervation by the left pudendal nerve (Getty, 1975 and Hodges, 1965). It is presumed that the parasympathetic innervation in the emu likely comes from the left pudendal nerve as well as the vagus. However physiological studies would be necessary to determine such.

BIBLIOGRAPHY

BIBLIOGRAPHY

Allen, Dana G., et.al. Handbook of Veterinary Drugs. Philadelphia. J.B. Lippincott Company. 1993. p.342-418 (Description of Drugs for Large Animals).

Baumel, J.J.,ed. Handbook of Avain Anatomy: Nomina Anatomica Cambridge, Massachusetts. Club; 1993. p.329-390 (Apparatus Urogenitalis), p.555-563 (Systema Nervosum Periphericum).

Bezuidenhout, A.J. The topography of the thoraco-abdominal viscera in the ostrich (Struthio camelus). Ondersteport Journal of Veterinary Research. 53: 111-117; 1986.

Cho, Patricia; Rosanne Brown and Marilyn Anderson. Comparative gross anatomy of ratites. Zoo Biology. 3: 133-144; 1984.

Drenowatz, Claire and Charlie Elrod., eds. The Ratite Encyclopedia. San Antonio, Tx. Ratite Records; 1995: p.31-61 (Hopkins, Brett A. and Constantinescu, George M., Anatomy of Ostriches, Emus and Rheas).

Fowler, Murray E. Comparative clinical anatomy of ratites. Journal of Zoo and Wildlife Medicine. 22(2): 204-227; 1991.

Freedman, S.L. and P.D. Sturkie. Extrinsic nerves of the chicken's uterus. Anatomy Record. 147: 431-437; 1963.

Getty, Robert., ed. Sisson and Grossman's The Anatomy of Domestic Animals. Philadelphia. W.B. Saunders Co.; 1975: p.1919-1964 (King, A.S., Aves Ureogenital System), p.1993-2000 (Baumel,J.J., Aves Heart and Blood Vessels).

Gilbert, A.B. Innervation of the ovary of the domestic hen. Quarterly journal of experimental physiology and cognate medical sciences. 54: 404-411; 1969.

Gilbert, A.B. and P.E. Lake. Terminal innervation of the uterus and vagina of the domestic hen. Journal of Reproductive Fertility. 5: 41-48; 1963.

Hodges, R.D. The blood supply to the avian oviduct with special reference to the shell gland. Journal of Anatomy. 99(3): 485-506; 1965.

King, A.S. and J. McLelland., eds. Form and Function in Birds. London, England. Academic Press; 1979. vol.1: p.237-361 (Gilbert, A.B. Female Genital Organs).

King, A.S. and J. McLelland., eds. Form and Function in Birds. London, England. Academic Press; 1981. vol.2: p.63-107 (King, A.S., Cloaca).

King, A.S. and J. McLelland. Birds their structure and function. London and Philadelphia: Bailliere Tindall; 1984: p. 145-165 (Female Reproductive System).

Mauger, H.M. autonomic innervation of the female genitalia. American Journal of Veterinary Research. 2: 447-452; 1941.

Nickel,R., A. Schummer, E.Seiferle. Anatomy of the Domestic Birds. Berlin and Hamburg: Verlag Paul Parey; 1977: p.70-84 (Urogenital System), p.85-103 (Circulatory System). Translated by W.G. Siller and P.A.L. Wright.

APPENDICES

APPENDIX A

MEASUREMENTS OF THE EMUS REPRODUCTIVE TRACT

	EMU #1	EMU #2	EMU #3	MEAN	STD. DEV.
Ovary (Cranial to Caudal)	8.5 cm	7.1 cm	8.3 cm	8.0 cm	3.5 cm
Ovary (Medial to Lateral)	1.2 cm	1.2 cm	2.4 cm	1.6 cm	1.5 cm
Infundibulum (Cranial to Caudal)	3.6 cm	4.3 cm	3.6 cm	3.8 cm	2.4 cm
Ostium Infundibulare	6.0 cm	6.5 cm	6.0 cm	6.2 cm	3.0 cm
Magnum (Cranial to Caudal)	5.3 cm	5.8 cm	3.4 cm	4.8 cm	2.7 cm
Isthmus (Cranial to Caudal)	5.5 cm	5.4 cm	6.6 cm	5.8 cm	2.9 cm
Uterus (Cranial to Caudal)	9.9 cm	8.9 cm	9.8 cm	9.5 cm	3.8 cm
Vagina (Cranial to Caudal)	7.2 cm	6.8 cm	7.0 cm	7.0 cm	3.2 cm

APPENDIX B

BACKGROUND INFORMATION ON THE ADULT FEMALE EMUS

The emus used in this researh project became availabe due to various health problems. All the female emus were obtained during the laying season (October to May). Even though physically mature they were assessed to be reproductively inactive because of failure to lay eggs. Also two of the emus (1 and 2) had a history of epileptic seizures.

VITA

Lee Anne Cope

Born: Cumming, Ga. 10-08-69

Education:

High school: Barnesville Academy; Barnesville, Ga. and Cullowhee High School; Cullowhee, North Carolina

College: Western Carolina University (Bachelor of Science in Biology and Minor in Chemistry) and University of Tennessee at Knoxville (Master of Science in Animal Science with an emphasis in Anatomy)

1904 8874 28
05/30/97 MAB