To the Graduate Council:

I am submitting herewith a dissertation written by Lee Anne Cope entitled "Comparative Anatomy of the Lower Respiratory Tract of the Gray Short-tailed Opossum (*Monodelphis domestica*) and North American Opossum (*Didelphis virginiana*)." I have examined the final electronic copy of this dissertation for form and content and recommend that it be accepted in partial fulfillment of the requirements for the degree of Doctor of Philosophy, with a major in Animal Science.

Robert W. Henry, Major Professor

We have read this dissertation
and recommend its acceptance:

Dr. R.B. Reed

Dr. C. Mendis-Handagama

Dr. J. Schumacher

Dr. S.E. Orosz

Accepted for the Council:

Dr. Anne Mayhew
Vice Provost and Dean of
Graduate Studies

(Original signatures are on file in the Graduate Student Services Office.)

COMPARATIVE ANATOMY OF THE LOWER RESPIRATORY TRACT OF THE GRAY SHORT-TAILED OPOSSUM (*Monodelphis domestica*) AND NORTH AMERICAN OPOSSUM (*Didelphis virginiana*)

A Dissertation

Presented for the

Doctor of Philosophy

Degree

The University of Tennessee, Knoxville

Lee Anne Cope

December 2001

Copyright © Lee Anne Cope, 2001
All rights reserved

DEDICATION

This dissertation is dedicated to my family

Mr. and Mrs. Charles Lee Cope

and

Mr. and Mrs. Jeffrey Morrow Cope and their children

Jeffrey Scott Cope and Ashley Channing Cope.

ABSTRACT

The present study describes the lower respiratory tract anatomy of the gray short-tailed opossum (*Monodelphis domestica*) and North American opossum (*Didelphis virginiana*). The trachea of the gray short-tailed opossum consists of 25 c-shaped tracheal cartilages. The trachea of the North American opossum consists of 28 c-shaped cartilages. The right lung of both species is separated into cranial, middle, caudal and accessory lobes by interlobar fissures. The left lung consists of unseparated cranial and caudal lobes. The right and left pulmonary arteries of the gray short-tailed and North American opossums divide into pulmonary lobar arteries. The pulmonary lobar veins join to form pulmonary veins. In the gray short-tailed opossum, the pulmonary lobar veins join to form a right and left pulmonary vein which join to form a common pulmonary venous trunk. In the North American opossum, a similar pattern occurs however the common pulmonary venous trunk is formed from three pulmonary veins (right, left and middle). Vascularization of the lung parenchyma is via the bronchial artery, a branch of the bronchoesophageal artery. Right and left bronchial branches course along the dorsal surface of the principal bronchi toward the hilus of the lung. In both species, the left bronchial branch anastomoses with a mediastinal artery originating from the aorta. Cranial deep cervical, cranial mediastinal and tracheobronchial lymph nodes drain the lower respiratory tract of both species. Sympathetic innervation to the lungs of the opossums comes from the sympathetic trunks as thoracic splanchnic nerves. Parasympathetic innervation to the lungs is via branches from the vagus nerves.

The trachea and principal bronchi of the gray short-tailed opossum are lined by pseudostratified ciliated columnar epithelium. Bronchial cartilages are irregular, shaped plates and localized to the extrpulmonary portion of the principal bronchus. The secondary and tertiary bronchi and primary and secondary bronchioles are lined by simple ciliated columnar epithelium. The terminal bronchioles and proximal portion of the respiratory bronchioles are lined by simple ciliated cuboidal epithelium. The distal portion of the respiratory bronchioles and the alveolar ducts are lined by simple squamous epithelium. The alveoli are lined by type I and II pneumocytes.

TABLE OF CONTENTS

CHAPTER PAGE

I. INTRODUCTION……... 1

II. REVIEW OF THE LITERATURE……. 4

Trachea……..….. 4

Bronchi…….…... 7

Alveoli and their cells…… 10

Lungs…….. 11

Pleura……..… 12

Pulmonary vessels……... 13

Bronchial artery…….. 14

Lymph nodes of the lower respiratory tract…… ……. 14

III. MATERIALS AND METHODS……... 18

Anesthesia, catheterization and exsanguination…… 18

Group I (Macroscopic Anatomy)…… 19

Group II (Microscopic Anatomy)……...…… 23

IV. MACROSCOPIC ANATOMY OF THE LOWER RESPIRATORY TRACT OF THE GRAY SHORT-TAILED OPOSSUM (*Monodelphis domestica*)……... 26

TABLE OF CONTENTS

CHAPTER PAGE

Abstract……. 26

Introduction…… 26

Materials and Methods…….. 27

Results……... 28

Discussion……. 40

V. MACROSCOPIC ANATOMY OF THE LOWER RESPIRATORY TRACT OF THE NORTH AMERICAN OPOSSUM (*Didelphis virginiana*)……. 44

Abstract……. 44

Introduction……... 44

Materials and Methods…….. 45

Results…… 46

Discussion…….. 58

VI. ANATOMY OF STRUCTURES ASSOCIATED WITH THE LOWER RESPIRATORY TRACT OF THE GRAY SHORT-TAILED OPOSSUM (*Monodelphis domestica*)……. 62

Abstract……. 62

Introduction…… 62

Materials and Methods……... 63

TABLE OF CONTENTS

CHAPTER PAGE

Results…… 64

Discussion…….. 79

VII. ANATOMY OF STRUCTURES ASSOCIATED WITH THE LOWER RESPIRATORY TRACT OF THE NORTH AMERICAN OPOSSUM (*Didelphis virginiana*)…….. 82

Abstract……. 82

Introduction…… 83

Materials and Methods…….. 83

Results……... 84

Discussion……. 97

VIII. MICROSCOPIC ANATOMY OF THE LOWER RESPIRATORY TRACT OF THE GRAY SHORT-TAILED OPOSSUM (*Monodelphis domestica*)……. 100

Abstract…… 100

Introduction…….. 101

Materials and Methods…… 102

Results……. 105

Discussion……... 128

TABLE OF CONTENTS

CHAPTER PAGE

IX. CONCLUSION…….. 135

REFERENCES……. 137

VITA…….. 149

LIST OF FIGURES

FIGURE PAGE

4 – 1. Ventral view of lower respiratory tract *in situ*……... 29

4 – 2. Cross section of trachea……. 30

4 – 3. Lateral view of right lung……... 33

4 – 4. Ventral view of thoracic viscera……. 35

4 – 5. Lateral view of left lung……. 37

4 – 6. Ventral view of tracheobronchial cast…….……... 38

5 – 1. Ventral view of thoracic respiratory tract (heart and great vessels removed)…….. …... 47

5 – 2. Caudal view of lungs……. …… 49

5 – 3. Dorsal view of the ventral thoracic cavity and sternum…….…… 50

5 – 4. Lateral view of right lung……. . 52

5 – 5. Lateral view of left lung……. 55

5 – 6. Ventral view of lower respiratory system cast……. ……. 56

5 – 7. Ventral view of bronchial cast……. 57

6 – 1. Tracheobronchial vascular cast – ventral view……. …….. 65

6 – 2. Ventral view of cranial portion of lungs…….. 67

6 – 3. Right view of thoracic cavity (right lung (L) reflected ventrally)……. ……. 68

LIST OF FIGURES

FIGURE PAGE

6 – 4. Right view of thoracic cavity (right lung (L) reflected)……... ……... 69

6 – 5. Left view of thoracic cavity (left lung (L) reflected ventrally)…… 71

6 – 6. Left ventral view of cervical region……. …….. 73

6 – 7. Ventral view of tracheobronchial lymph nodes…….. 74

6 – 8. Ventral view of cervical and thoracic region…….…….. 78

7 – 1. Ventral view of tracheobronchial vascular cast…….……... 86

7 – 2. Right lateral view of dorsal mediastinal structures (ribs reflected dorsally)…… 87

7 – 3. Dorsal mediastinal structures (lateral view)……. 89

a. Left lateral view of dorsal mediastinal structures (dorsal aspect of left lung pulled ventrally)…… 89

b. Close up of lateral view of dorsal mediastinal structures (dorsal aspect of left lung retracted ventrally)……... 90

7 – 4. Left ventrolateral view of cranial cervical region…… 92

7 – 5. Ventral view of cranial mediastinal lymph nodes…….. 93

7 – 6. Tracheobronchial lymph nodes……. 94

8 – 1. Cross section through the tunica mucosa of the trachea……. 106

8 – 2. Cross section of the trachea…… 108

LIST OF FIGURES

FIGURE PAGE

8 – 3. Tracheal gland in the tela submucosa of the trachea. …… 108

8 – 4. Tracheal gland duct (D)……. 109

8– 5. Tracheal gland. …….……. 109

8 – 6. Trachealis muscle (T) attaching to the luminal side of

the tracheal cartilage…….……. 111

8 – 7. Membranous carina of the tracheal bifurcation…….……. 113

8 – 8. Autonomic ganglion……... 113

8 – 9. Cross section of tunica mucosa of principal bronchus…… 115

8 – 10. Extrapulmonary part of principal bronchus…….. 116

8 – 11. Layers of intrapulmonary portion of principal bronchus…….…. .. 118

8 – 12. Longitudinal section of secondary bronchus…… 120

8 – 13. Longitudinal section of tertiary bronchus…….…… 120

8– 14. Cross section of primary bronchiole…….. 121

8– 15. Tunica mucosa of primary bronchiole…… 121

8– 16. Longitudinal section of terminal airways…….. 123

8– 17. Cross section of respiratory bronchiole……. 123

8– 18. Tunica mucosa of the respiratory bronchiole…….. 124

8 – 19. Lung parenchyma……. 126

8 – 20. Alveolar cells…… 126

LIST OF FIGURES

FIGURE PAGE

8 – 21. Alveolar macrophage passing through alveolar pore…… 127

8 – 22. Visceral pleura of the lung…… 127

CHAPTER I

INTRODUCTION:

Marsupials have been considered an ideal animal for biomedical research because of their short gestation period and a semiembryonic state of development of the offspring at birth (VandeBerg, 1983). However, the only indigenous species of marsupial in the United States is the North American opossum (*Didelphis virginiana*) and it has not proven to be an ideal laboratory animal due to its large size. The North American opossum also shows decreased reproductive capability, exhibits cannibalism of their offspring and has an aggressive behavior toward other animals in captivity (VandeBerg, 1983). Also, the only commercial source for the North American opossum is wild caught animals. Other species of marsupials from Australia and New Guinea have been used but they also exhibit the same limitations as a lab animal as the North American opossum (VandeBerg, 1983).

Until 1979, no marsupial species was considered to be ideal for biomedical research or easily adaptable to laboratory conditions (VandeBerg, 1983). However, the gray short-tailed opossum (*Monodelphis domestica*) has most of the desirable characteristics of a lab animal without the problems encountered in other marsupials. The adult, gray short-tailed opossum weighs only 80 to 150 grams allowing it to be housed in pairs in standard plastic rat cages with little aggression (Fadem *et al*., 1982; VandeBerg, 1983). The gestation period of the female opossum is two weeks and the size of the litter varies

from 8 to 14 pups which reach sexual maturity at 4 to 5 months of age. Gray short-tailed opossums are also docile making them easier to handle. These opossums, when raised under laboratory conditions, are free of diseases and parasites found in wild - caught marsupials. (Fadem *et al*., 1982; VandeBerg, 1983).

In 1978, nine gray short-tailed opossums were captured in Brazil by the National Zoological Park. The following year, twenty of the offspring from the first and second generations were donated to the Southwest Foundation for Biomedical Research (VandeBerg, 1983). Since then, this foundation has established and maintained a colony of approximately 1500 animals (VandeBerg, 1983; Oorschot *et al*., 1992). These opossums have been used for in house studies on genetics and reproduction (VandeBerg, 1983) while some of the opossums have been made available to outside investigators for studies in various areas such as the development of the central nervous system (Kuehl-Kovarik *et al*., 1995), embryogenesis (Klima, 1987; Baggott and Moore, 1990; Renfree, 1990; Selwood and VandeBerg, 1992; Szalay, 1994; Kuehl-Kovarik *et al*., 1995) and embryonic morphogenesis and differentation (Filan, 1991; Hubbard *et al.*, 1991; Krause, 1992; Morohunfola *et al.*, 1992).

Since the gray short-tailed opossum has been used as a model in these various areas of research, we realized a need for documentation of the normal macroscopic and microscopic anatomy of the various organ systems. This study documents the normal macroscopic and microscopic anatomy of the lower respiratory tract of the gray short-tailed opossum including associated systems and structures. In addition, since the North

American opossum is native to much of the United States, comparisons are made to the respective areas of the lower respiratory tract studied in the gray short-tailed opossum.

CHAPTER II

REVIEW OF LITERATURE:

The literature on the lower respiratory tract of marsupials is incomplete and scattered over 144 years. This literature focused only on select regions such as the trachea (Sonntag 1921a; Krause and Leeson 1973, 1975; Tucker, 1974), principal bronchi (Krause and Leeson 1973, 1975), bronchial glands (Sorokin, 1965), type II pneumocytes (Sorokin, 1967; Krause *et al*., 1976), lung lobation (Owen, 1852; Owen, 1868; Forbes, 1881; Parsons, 1903; Osgood, 1921; Sonntag 1921a, 1921b; Jones, 1949), pulmonary vessels (McClure, 1903; Wade and Neely, 1949; Hill, 1955; Dowd, 1969), bronchial circulation (Bernard *et al*., 1996) and associated lymph nodes (Zimmerman, 1940; Azzali and Didio, 1965; Kampmeirer, 1969) of various marsupials.

TRACHEA:

The available literature on the trachea of marsupials such as the common shrew opossum (*Caenolestes obscurus*) (Osgood, 1921), Perameles (Owen, 1868), native cat (quoll) (*Dasyurus viverrinus*) (Hill, 1955) and mulgara (*Dasycercus cristicauda*) (Jones, 1949) concentrate on the shape of the tracheal cartilages. These articles indicate the tracheal rings are incomplete dorsally similar to those of domestic mammals (Getty, 1975; Nickel *et al.,* 1979; Banks, 1993; Evans, 1993). In addition, Owen (1868) observed that the first twenty-four of the twenty-nine tracheal rings of the common brush-tailed opossum (*Trichosurus vulpecula)* were complete. However, based on his description it is not clear if the tracheal rings were truly complete or if the dorsal ends

overlapped similar to that of large domestic mammals such as the horse, cow, pig and goat (Getty, 1975; Nickel *et al*., 1979). Along with the variation in the shape of the tracheal rings, their number also varies among the marsupial species (Sonntag, 1921b) as it does in domestic mammals (Getty, 1975; Nickel *et al.*, 1979).

The literature found on the microscopic anatomy of the lower respiratory tract of marsupials is limited to one report on the tracheal epithelium of the North American opossum (Krause and Leeson, 1975). It reports the epithelium is simple ciliated columnar in areas overlying cartilage rings and nonciliated simple columnar between the tracheal cartilages. This differs from the pseudostratified ciliated columnar epithelium lining the trachea of domestic mammals (Getty, 1975; Banks, 1993; Dellmann and Eurell, 1998) and several species of small rodents (Hansell, 1968; Jeffery, 1975; Becci, 1978; Pack *et. al*, 1981).

In the North American opossum (Krause and Leeson, 1975), domestic mammals (Banks, 1993; International Committee on Veterinary Gross Anatomical Nomenclature, 1994; Dellmann and Eurell, 1998) and rodents such as the rat (Jeffery, 1975), mouse (Hansell, 1968; Pack *et. al*, 1981) and hamster (Becci, 1978), the predominant cell type of the tracheal epithelium is the columnar cell. This cell has a basally placed nucleus. Also depending on the species and location in the trachea, the apical (luminal) surface of the columnar cell may be covered with cilia (Breeze and Wheeldon, 1977; Dellmann and Eurell, 1998). Among these columnar cells are goblet cells and basal cells. In the North American opossum, rat, mouse and hamster only a few goblet cells are seen in the entire trachea in comparison to domestic mammals where they are found throughout the length

of the trachea. In all of these species, goblet cells are mucous secreting cells which have a mass of mucous granules within the apical cytoplasm. The nucleus of the goblet cell is basally located and surrounded by cytoplasmic organelles involved in the production of mucus (Breeze and Turk, 1984; Burkitt *et al*., 1993; Dellmann and Eurell, 1998).

Basal cells are small, round to ovoid cells with a centrally located nucleus. These cells function as germinal cells that differentiate and replace other epithelial cells including the columnar or goblet cells (Breeze and Wheeldon, 1977; Dellmann and Eurell, 1998). Basal cells are wedged between the other cells giving the epithelium a pseudostratified appearance in domestic mammals (Breeze and Wheeldon, 1977; Dellmann and Eurell, 1998), rat (Jeffery, 1975), mouse (Hansell, 1968; Pack *et. al*, 1981) and hamster (Becci, 1978). These cells are not discussed in the North American opossum.

Beneath the tracheal epithelium, a prominent vascular layer has been described in the koala and phalanger (Tucker, 1974). This vascular layer is composed of two or three rows of capillaries that may be close together (phalanger) or loosely organized (koala). Based on Tucker's (1974) description, this vascular layer must be part of the lamina propria mucosae as it is in domestic mammals (Dellmann and Eurell, 1998).

The tracheal glands of the North American opossum are found within the tela submucosa similar to that of domestic mammals (Getty, 1975; Burkitt *et al.*, 1993; Dellman and Eurell, 1998). These glands are abundant throughout the length of the trachea in contrast to domestic carnivores where they are numerous in the ventral and lateral walls of the proximal trachea and decrease in number distally (Getty, 1975; Burkitt

et al, 1993; Dellman and Eurell, 1998). The tracheal glands of the North American opossum are composed of mucous and serous cells which form acini (adenomeres) that are surrounded by myoepithelial cells (Krause and Leeson, 1973). Their description of these mucous cells suggest similarities to domestic mammals due to their pear shape, the mass of mucus granules within the apical cytoplasm and the flattened basally positioned nucleus. However, Krause and Leeson (1973) do not describe the histological features of the serous cells in the opossum tracheal glands. They assume these cells have similar features to the serous cells described in a detailed study of the bronchial glands of the North American opossum by Sorokin (1965b). In this article, Sorokin (1965b) states the serous cells of these glands are more specialized than those of domestic carnivores because of their ultrastructural and functional characteristics which are similar to cells specialized for ion and water secretion such renal tubular cells. In the North American opossum (Krause and Leeson, 1973) and domestic mammals (Getty, 1975; Schaller, 1992; Banks, 1993; Dellmann and Eurell, 1998), the tracheal glands open into the tracheal lumen via excretory ducts that pass through the tela submucosa and the lamina propria mucosae. The epithelium of this duct in the North American opossum is not described as it is in domestic mammals (Dellmann and Eurell, 1998). However, Krause and Leeson (1973) state mucous secreting cells are often present among the epithelial cells of the excretory duct.

BRONCHI:

The literature on the bronchial tree of marsupials is not as extensive as that of domestic mammals (Getty, 1975; Banks, 1993; Evans, 1993; Dyce *et al.*, 1996; Dellmann

and Eurell, 1998). Two articles trace the sequence of changes that occur within the principal bronchi of the North American opossum from birth until 85 days of age and a third article describes the bronchial glands of this marsupial (Sorokin, 1965b; Krause and Leeson, 1973, 1975). According to Krause and Leeson (1973), the epithelium of the principal bronchi is simple columnar with patches of ciliated and nonciliated cells. This epithelium is supported by a lamina propria mucosae which has an abundance of elastic fibers similar to domestic mammals (Krause and Leeson, 1973; Banks, 1993). Deep to this layer in the North American opossums and domestic mammals is a layer of smooth muscle called the lamina muscularis mucosae (Krause and Leeson, 1973; Banks, 1993). The smooth muscle of this layer is arranged in a helical pattern and separates the lamina propria mucosae from the tela submucosa.

The tela submucosa is composed of loose connective tissue and seromucous bronchial glands (Krause and Leeson, 1973; Schaller, 1992; Banks, 1993; Burkitt *et al*., 1993; International Committee on Veterinary Gross Anatomical Nomenclature, 1994). In the North American opossum (Sorokin, 1965b; Jeffery, 1983), these glands are described as compound acinar glands and extend the length of the bronchial tree as they do in domestic mammals (Getty, 1975). However, Sorokin (1965b) and Jeffery (1983) also observed these glands extending into the bronchiolar tree similar to the domestic feline (Getty, 1975; Jeffery, 1983). The bronchial glands of the North American opossum and domestic mammals (Getty, 1975) open into the lumen of the bronchi by an excretory duct. In the North American opossum, Sorokin (1965b) reports this duct is lined by nonsecretory cuboidal cells while Krause and Leeson (1973) state the duct is lined by a

columnar epithelium. Leading into the main duct of this bronchial gland are one to three orders of smaller ducts lined with secretory cells. These cells are described as either mucous cells or special serous cells, referred to by Sorokin (1965b) as hydrotic cells.

The mucous cells are similar to those of domestic mammals. They are pear shaped with a foamy, slightly basophilic cytoplasm and a flattened basally positioned nucleus that is surrounded by cytoplasmic organelles such as mitochondria, rough endoplasmic reticulum and golgi apparatus (Banks, 1993; Burkitt *et al.*, 1993). The mucous cells of these glands of the North American opossum may lie near its opening into the bronchial lumen, line one of the smaller ducts which leads into the main duct, line part of main excretory duct, or form acini (Sorokin, 1965b). The serous cells of the bronchial glands of the North American opossum are different from those of domestic mammals (Banks, 1993; Burkitt *et al*., 1993) because of surface modifications such as microvilli on the apical surface and changes in the internal cellular organelle organization. Therefore, Sorokin (1965b) states the serous cells have characteristics similar to cells functioning in water and ion secretion or absorption such as those of salivary glands or cells from renal tubules of the kidney. In addition to lining the smaller ducts of the bronchial glands, the serous cells are found in the acini among mucous cells forming serous acini or arranged peripheral to the mucous acini as serous crescents (demilunes) (Sorokin, 1965b). These demilunes are drained similar to those of domestic mammals (Banks, 1993) by intercellular canaliculi (Sorokin, 1965b). The acini of the bronchial glands of the North American opossum are surrounded by stellate shaped myoepithelial cells (Sorokin, 1965b; Krause and Lesson, 1973). These cells lie inside the basal lamina and extend

along the ducts until the epithelium becomes cuboidal and nonsecretory in the main duct (Sorokin, 1962, 1965b).

ALVEOLI AND THEIR CELLS:

The alveoli in the lungs of the North American opossum (Sorokin, 1967; Krause *et al.*, 1976) and domestic mammals (Schaller, 1992; Banks, 1993; Dellmann and Eurell, 1998) are lined by type I (alveolar type I cell) and type II pneumocytes (alveolar type II cell). The type I pneumocyte is the most abundant cell lining the alveoli of the North American opossum and domestic mammals (Sorokin, 1967; Banks, 1993). This cell is a simple squamous epithelial cell with a flattened nucleus that protrudes into the alveolar lumen (Sorokin, 1967; Banks, 1993; Dellmann and Eurell, 1998). The thin extremities of the type I pneumocytes join those of other type I pneumocytes to form a continuous lining of the alveolus (Sorokin, 1967; Banks, 1993). In the North American opossum (Sorokin, 1967; Krause *et al.*, 1976) and domestic mammals (Banks, 1993, Dellmann and Eurell, 1998), the type II pneumocyte is the secretory cell of the alveoli and scattered among the type I pneumocytes (Banks, 1993; Dellmann and Eurell, 1998). The type II pneumocyte is a round to cuboidal shaped cell with a foamy, vacuolated cytoplasm and a large centrally placed vesicular nucleus. In the North American opossum, Sorokin (1967) and Krause *et al*., (1976) also observed that the apical surface of this cell is covered with microvilli and may be seen in groups of two or three.

LUNGS:

Lobation of the right and left lungs of marsupials has been described in several species such as opossums (Tyson, 1698; Owen, 1868; Osgood, 1921; Sonntag, 1921a), bandicoots (Parsons, 1903; Sonntag, 1921a), kangaroos (Sonntag, 1921a), quoll (Owen, 1868), mulgara (Jones, 1949), koala (Owen, 1868; Forbes, 1881; Sonntag, 1921b), wallaroo (Sonntag, 1921a) and wombat (Owen, 1868). These descriptions indicate some marsupials have lung lobation identical to domestic carnivores (Evans, 1993).

The right lung lobation in the North American opossum, mouse opossum (*Marmosa elegans*), gray four-eyed opossum (*Metachirus opossum*), Phalangeridae (Sonntag, 1921a), brush-tailed opossum (*Trichosurus vulpecula*) (Sonntag, 1921b), common shrew opossum (*Caenolestes obscurus*) (Osgood, 1921), quoll (Owen, 1868), mulgara (Jones, 1949), Perameles and Petaurists (Owen, 1868) and long nosed bandicoot (*Perameles obesula*) (Sonntag, 1921a) is identical domestic carnivores (Evans, 1993). However, previous reports by Tyson (1698) and Owen (1868) state the right lung of the North American opossum consists of three lobes instead of the four described by Sonntag (1921a). Several other marsupials also possess right lung lobation which differs from domestic carnivores. The right lung of the tree kangaroo (*Dendorlagus ursinus*), eastern grey kangaroo (*Macropus giganteus*) and wallaroo (*Macropus bennetti)* is trilobate and described as having a deep median sulcus incompletely dividing the lung into anterior and posterior parts in addition to the azygous lobe (Sonntag, 1921a). The right lung of the red-legged short-tailed opossum (*Didelphys brachyura)* consists of three lobes and the right lung of the wombat (*Vombatus ursinus*) consists of two lobes (Owen, 1868). The right lung of the koala (*Phascolactos cinereus)* is described by Forbes (1881) as

having three lobes without the azygous lobe while Sonntag (1921b) states that the right lung of the koala consists of only two lobes. The right lung of the common shrew opossum has three lobes, however Osgood (1921) also reports the right lung of one of the three specimens consists of four lobes. This indicates variability in lung lobation within this species.

The left lung of the North American opossum (Owen, 1868), brush-tailed opossum (Sonntag, 1921b), mouse opossum (Sonntag, 1921a), Phalangeridae (Owen, 1868; Sonntag, 1921a), koala (Owen, 1868; Forbes, 1881), quoll (Owen 1868), mulgara (Jones, 1948) and Petaurists (Owen, 1868) is described as having a cranial and caudal lobe similar to that of domestic carnivores (Nickel *et al*., 1979; Evans, 1993). In addition, a previous report by Tyson (1698) states the left lung of the North American opossum is unilobate. This is identical to the lobation of the gray four-eyed opossum, long-nosed bandicoot (Sonntag, 1921a), pig-footed bandicoot (*Choeropus castanotis*) (Parsons, 1903), common shrew opossum (Osgood, 1921) and wombat (Owen, 1868) which is based on the external appearance of the lung as branching of the bronchial tree is not mentioned.

PLEURA:

The visceral (pulmonary) pleura covering the lungs in the North American opossum (Krause and Leeson, 1973, 1975) and domestic carnivores (Evans, 1993) is simple squamous mesothelium. In the North American opossum, a thick connective tissue layer of collagen and elastic fibers, referred to as the subplerual lamina, lies beneath the mesothelial basal lamina. This subplerual lamina is similar to the tunica subserosa

described in domestic carnivores (Banks, 1993; International Committee on Veterinary Gross Anatomical Nomenclature, 1994). According to Krause and Leeson (1973, 1975), the subpleural lamina of the North American opossum gives off septa which blend with the connective tissue components of the lung. Based on this description, these septa must be similar to those from the tunica subserosa of domestic carnivores which are continuous with the interalveolar septa of the lung (Banks, 1993; Burkitt *et al.*, 1993).

PULMONARY VESSELS:

Descriptions on the pulmonary vasculature of marsupials is limited to the pulmonary venous return to the heart. These articles on the North American opossum (Owen, 1868; McClure, 1903; Wade and Neely, 1949), brush-tailed opossum (Dowd, 1969) and native cat (Hill, 1955) describe a common pulmonary venous trunk opening into the left atrium. In two specimens of the North American opossum, the common brush-tailed opossum and native cat, the common pulmonary venous trunk is formed from a common right and common left pulmonary vein. In the North American opossum, Wade and Neely (1949) state these vessels are formed by two veins from each lung joining to form a common right and common left pulmonary vein before entering the left atrium. This pattern differs from that of domestic mammals (Nickel *et al*., 1981; Evans, 1993) in which the number of pulmonary veins usually corresponds to the number of lung lobes and these vessels remain separate to the heart to open individually into the left atrium. However, Wade and Neely (1949) also observed in two specimens four pulmonary veins entering directly into the left atrium of the North American opossum similar to the pattern in domestic mammals.

BRONCHIAL ARTERY:

The blood supply to the lung parenchyma of the North American opossum (Bernard *et al*., 1996) and domestic carnivores (Nickel *et al*., 1981; Evans, 1993) originates from right and left bronchial branches of the bronchial artery. In the North American opossum, the bronchial artery originates from either a distinct bronchoesopahgeal artery or a common bronchial artery from the ventral aspect of the thoracic aorta at the fifth intercostal space. Then similar to domestic carnivores, the bronchial artery of the North American opossum divides into right and left bronchial branches at the tracheal bifurcation. Previous descriptions of this artery in domestic mammals (McLaughlin *et al.*, 1961; Evans, 1993) state the right and left branches supply the respective tracheobronchial lymph nodes, the peribronchial connective tissue and the pulmonary artery and vein by vaso vasorum. However, these bronchial branches do not contribute to the blood supply of the visceral pleura of domestic carnivores as they do in other domestic mammals (McLaughlin *et al.*, 1961). The right and left bronchial branches then enter the associated lung and follow the bronchial divisions (Nickel *et al*., 1981; Evans, 1993). In domestic carnivores, these branches terminate at the level of the respiratory bronchioles in a capillary bed that is continuous with that of a pulmonary artery (Evans, 1993). No mention is made of the structures supplied or the branching pattern of the right and left bronchial branches within the lung of the North American opossum.

LYMPH NODES OF THE LOWER RESPIRATORY TRACT:

The North American opossum (Zimmerman, 1940; Kampmeier, 1969) and large American opossums of South America (*Didelphis marsupialis and Didelphis azarae)*

(Azzali and Didio, 1965) have a pair of lymph nodes near the laryngotracheal junction and lateral to the neurovascular bundle of the neck. Zimmerman (1940) and Kampmeier (1969) refer to these lymph nodes as superior cervical lymph nodes and Azzali and Didio (1965) refer to them as deep cervical lymph nodes. These lymph nodes lay in the same region as the cranial deep cervical lymph nodes of domestic carnivores (Nickel *et al*., 1981; Evans, 1993).

Previous descriptions on the North American opossum (Zimmerman, 1940; Kampmeier, 1969) and American opossums of South America (Azzali and Didio, 1965) document anterior mediastinal lymph nodes. These lymph nodes are cranial to the base of the heart at the level of the first ribs similar to the cranial mediastinal lymph nodes of domestic carnivores (Nickel *et al*., 1981; Evans, 1993). In the North American opossum and large American opossums of South America, an anterior mediastinal lymph node is located on the right and left ventrolateral surfaces of the trachea (Zimmerman, 1940; Azzali and Didio, 1965; Kampmeier, 1969). Azzali and Didio (1965) and Kampmeier (1969) also describe posterior cranial mediastinal lymph nodes. These lymph nodes are located on the ventral surface of the respective longus colli muscle with the left one laying in the aortic arch and the right one laying medial to the first and second intercostal spaces. In addition, Azzali and DiDio (1965) describe a single posterior middle mediastinal lymph located along the dorsal body wall, to left of the thoracic duct and in the arch of the left azygous vein. Based on their descriptions, the posterior middle mediastinal lymph node may be similar to the caudal mediastinal lymph nodes found in domestic mammals with the exception of domestic carnivores (Nickel *et al.*, 1981).

In the large American opossums of South America, Azzali and DiDio (1965) have described two bronchial lymph nodes. The cranial one lays on the ventrolateral aspect of the trachea cranial to the tracheal bifurcation. The caudal bronchial lymph node lays in the angle of the tracheal bifurcation on the ventral surface of the esophagus. This lymph node is located in a similar position to that of the middle tracheobronchial lymph node of domestic carnivores (Evans, 1993).

The lymph nodes of several marsupials such as the Northern brown bandicoot (*Isoodon macrourus*) (Cisternas *et al.*, 1999), quokka (*Setonix brachyurus)* (Ashman and Papadimitriou, 1975), tammar wallaby *(Macropus eugenii*) (Basden *et al.,* 1997) and fat-tailed dunnart *(Smithopsis crassicaudata)* (Haynes, 1991) are dense encapsulated lymphatic organs that are surrounded by a capsule similar to that of domestic carnivores (Banks, 1993; Dellmann and Eurell, 1998). The capsule surrounding the lymph node of the Northern brown bandicoot (Cisternas and Armati, 1999) and tammar wallaby (Basden *et al*. 1997) is a thick connective tissue capsule which gives off trabeculae similar to domestic carnivores. However, in the Northern brown bandicoot these trabeculae only penetrate the superficial region of the cortex as compared to those of domestic carnivores (Dellmann and Eurell, 1998) which extend into the cortical and medullary regions of the node. Similar to domestic carnivores (Banks, 1993; Dellmann and Eurell, 1998), the afferent lymphatic vessels of the Northern brown bandicoot (Cisternas and Armati, 1999) enter the lymph node by passing through the capsule at various points and opening into the subcapsular sinus. This sinus in the Northern brown bandicoot (Cisternas and Armati, 1999) and tammar wallaby (Basden *et al.,* 1997) contains lymphocytes,

erythrocytes, macrophages and plasma cells similar to domestic carnivores (Banks, 1993; Dellmann and Eurell, 1998).

The parenchyma of the lymph node of the tammar wallaby, Northern brown bandicoot and quokka is composed of lymphocytes, plasma cells and macrophages that are organized into an outer cortex and inner medulla similar to that of domestic carnivores (Banks, 1993; Dellmann and Eurell, 1998). The cortex of the lymph nodes of these marsupials and domestic carnivores consist of primary and secondary lymph nodules and a deep or paracortical region (Ashman and Papadimitriou, 1975; Banks, 1993; Basden *et al.,* 1997; Cisternas and Armati, 1999). This region is that portion of the cortex that surrounds the primary and secondary lymph nodules. In domestic carnivores (Dellmann and Eurell, 1998), the paracortical region is diffuse lymphatic tissue that consists mainly of T-lymphocytes which are not organized into nodules (Banks, 1993; Dellmann and Eurell, 1998). In the Northern brown bandicoot, Cisternas and Armati (1999) state the paracortical region has numerous capillaries, which are characterized by a flattened to cuboidal endothelial lining.

The medulla is centrally located toward the center of the lymph node in the Northern brown bandicoot (Cisternas and Armati, 1999), tammar wallaby (Basden *et al.,* 1997), quokka (Ashman and Papadimitriou, 1975) and domestic carnivore (Banks, 1993; Dellmann and Eurell, 1998). It is loosely organized into medullary cords which are extensions of the paracortical region of the cortex and are separated from one another by trabeculae and medullary sinuses (Ashman and Papadimitriou, 1975; Banks, 1993; Basden *et al.,* 1997; Dellmann and Eurell, 1998; Cisternas and Armati, 1999).

CHAPTER III

MATERIALS AND METHODS:

ANESTHESIA, CATHETERIZATION AND EXSANGUINATION:

To study the macroscopic and microscopic anatomy of the lower respiratory tract, twenty-five (14 males and 11 females) gray short-tailed opossums *(Monodelphis domestica)* and eighteen (9 males and 9 females) North American opossums *(Didelphis virginiana)* were used. The gray short-tailed opossums were obtained via donation from Iowa State University (Ames, Iowa) and purchased from Southwestern Foundation for Biomedical Research (P.O. Box 760549 San Antonio, Texas, 78245). These opossums were sexually mature and two years of age. The North American opossums were obtained from the Department of Comparative Medicine at The University of Tennessee College of Veterinary Medicine and the Tennessee Department of Natural Resources. These opossums were various ages. The gray short-tailed and North American opossums were randomly divided into two groups, to study the macroscopic anatomy and microscopic anatomy. Eighteen (11 males and 7 females) gray short-tailed opossums and sixteen (8 males and 8 females) North American opossums were used for the macroscopic anatomy. Seven (3 males and 4 females) gray short-tailed opossums along with the random samples taken from the opossums utilized for the gross anatomy, were used to describe the microscopic anatomy of the lower respiratory tract.

Each gray short-tailed opossum was administered 500 I.U. of heparin sodium (Heparin Sodium Injection, 1,000 units per 1.0 ml, Elkins-Sinn Inc. Cherry Hill, NJ

08003) via intraperitoneal (IP) injection to facilitate esanguination. Eighteen hours later, the opossums were anesthetized with an IP injection of 50 mg of Nembutal (Nembutal Sodium Solution, Pentobarbital Sodium Injection, Abbott Laboratories, North Chicago, IL 60064) per 100.0 grams of body weight. When stage 3 anesthetic plane was reached, the gray short-tailed opossums were placed in dorsal recumbency and the hair on the ventrolateral surfaces of the neck was clipped. An incision was made through the skin and the subcutaneous tissue over the right external jugular vein and the right common carotid artery. These vessels were exteriorized by blunt dissection and catheterized. A 20 gauge, 2 inch angiocath I.V. catheter (Becton Dickson Infusion Therapy Systems Inc., Sandy, Utah 84070) was inserted into the external jugular vein and a 22 gauge, 1 inch angiocath I.V. catheter into the common carotid artery for exsanguination.

The North American opossums were anesthetized with an intramuscular injection (IM) of 500 mg of Nembutal. When stage III anesthetic plane was reached, the right external jugular vein and common carotid artery were exteriorized similar to that of the gray short-tailed opossum. These vessels were then catheterized for exsanguination with a 5.0 mm plastic cannula for the external jugular vein and a 3.0 mm plastic cannula for the common carotid artery.

GROUP I (MACROSCOPIC ANATOMY):

The gray short-tailed and North American opossums of this group were used to observe and record the gross anatomy of the lower respiratory tract. This was

accomplished by dissection, vascular injections and the production of tracheobronchial and tracheobronchial vascular casts.

The gross anatomy of the lower respiratory tract was documented by dissecting a total of eighteen (11 males and 7 females) gray short-tailed opossums and eighteen (9 males and 9 females) North American opossums with each animal often being used for more than one objective. Out of the eighteen gray short-tailed opossums, twelve animals were used for descriptions of the trachea, lungs and pleura, eight animals were also used for the associated structures of the lower respiratory tract, six animals were used for tracheobronchial cast and two animals were utilized for tracheobronchial vascular casts. For the North American opossum, all eighteen animals were utilized for the anatomy of the trachea, lungs and pleura, fourteen animals were also utilized for associated structures, four animals were used for trachebronchial casts and two were used for tracheobronchial vascular casts.

To expose the lower respiratory tract after exsanguination a ventral midline incision was made through the skin and subcutaneous tissue from the caudal border of the larynx to the manubrium. The right and left sternohyoideus muscles were separated to expose the cervical trachea. The cervical incision was extended caudally and lateral to each sternoclavicular joint through the costal cartilages and intercostal muscles. The incisions were joined caudal to the xiphoid process to remove the sternum thus exposing the trachea, heart and lungs.

The vasculature of the lower respiratory tract was documented following embalming and vascular injections of two (one male and one female) gray short-tailed opossums and

one (female) North American opossum. The gray short-tailed opossums were embalmed with 15.0 to 34.0 ml of 10% buffered formalin and the North American opossum was embalmed with 70.0 ml via the catheterized common carotid artery. The next day red and blue latex were injected into the catheterized vessels. In the gray short-tailed opossum, approximately 0.8 ml of red latex was injected into the common carotid artery and 0.6 ml of blue latex was injected into the external jugular vein. In the North American opossum, 20.0 ml and 10.0 ml each of red and blue latex were injected into the common carotid artery and external jugular vein respectively. The opossums remained at room temperature for twenty-four hours to assure hardening of the vascular injections. Then they were submerged in 10% buffered formalin and stored at $5^{O}C$ until dissection at which time the chest was opened similar to that previously described.

A tracheobronchial cast was made of the conduction components of the lower respiratory tract of six gray short-tailed opossums (4 males and 2 females) and four North American opossums (2 males and 2 females). The chest was opened similar to the previous description and the topography of the thoracic viscera was observed and recorded for each species. The trachea was transected caudal to the larynx and a 3.0 mm o.d plastic cannula for the gray short-tailed opossum and a 6.0 mm o.d. plastic cannula for the North American opossum were inserted into the tracheal lumen. The cannulas were ligated in place and the trachea and lungs were removed and air-dried for 48 hours to remove the moisture from the lung parenchyma. Pressurized air was used to inflate and maintain the lungs in normal inspiratory anatomical position until they were dry. Following air-drying, 2.0 ml of RTV silicone (Silicone Inc. P.O. Box 363, 211 Woodbine

High Point, NC, 27261) for the gray short-tailed opossum and approximately 15.0 ml for the North American opossum was injected through the cannulated trachea into the airways of the lungs and allowed to harden at room temperature for 24 hours (Henry, 1992). After hardening, the lung parenchyma was removed by maceration in boiling water. The tracheobronchial cast was cleaned first with water then soaked in 10% hydrogen peroxide for final cleaning.

Tracheobronchial vascular casts were made from two (males) gray short-tailed opossums and two (1 male and 1 female) North American opossums. In the gray short-tailed opossums, red and blue latex was injected into the catheterized common carotid artery and external jugular vein respectively. The opossums remained at room temperature for twenty-four hours to assure hardening of the vascular injections. After hardening, the trachea was exposed and transected and the chest was opened as described previously. A 3.0 mm o.d. cannula was inserted into the tracheal lumen and ligated in place. Approximately 2.0 ml of RTV silicone was infused using digital pressure through the cannulated trachea into the airways and allowed to harden for twenty-four hours. After hardening the lung and heart were removed as a unit and the parenchyma was removed by maceration in water at room temperature. The tracheobronchial vascular casts were cleaned first with water then soaked in 10% hydrogen peroxide for final cleaning.

In the two North American opossums, the chest was opened similar to the gray short-tailed opossum and the trachea, heart and lungs were removed as a unit. The trachea was cannulated with a 6.0 mm o.d cannula and ligated in place. The conus arteriosus of the

heart was incised and cannulated with a 3.0 mm cannula. The cannula was directed into the pulmonary trunk and ligated in place. The apex of the left auricle was incised and a 3.0 mm o.d. plastic cannula was inserted into the lumen of the left atrium and ligated in place. The cannulas were then gently flushed with water to remove any blood clots prior to injecting red and blue silicone. Approximately 3.0 ml of blue silicone and 6.0 ml of red silicone were injected into the pulmonary arteries and pulmonary veins respectively. Following this, pressurized air was used to inflate and maintain the lungs in normal inspiratory anatomical position for 48 hours to remove the moisture from the lung parenchyma. Following air-drying, 15.0 ml of RTV Silicone was infused into the airways (Henry, 1992a and 1992b). After hardening the lung and heart parenchyma was removed by maceration in boiling water. The tracheobronchial vascular casts were cleaned first with water then soaked in 10% hydrogen peroxide for final cleaning.

GROUP II (MICROSCOPIC ANATOMY):

Following exsanguination, seven gray short-tailed opossums (three males and four females) along with random tissue samples taken from the gray short-tailed opossums used for the gross anatomy, were used for histologic study of the lower respiratory tract. The trachea and lungs of the six gray short-tailed opossums were formalin fixed *in situ* by intratracheal perfusion of 10% buffered formalin via a cannula from a height of 5.0 cm for 5 minutes. After fixation, the trachea and lungs were removed and placed in 10% buffered formalin for an additional 24-48 hours before sectioning. Tissue samples were taken from all six lung lobes from four animals for study of the lung parenchyma. The four tracheas from these animals were divided into cranial, middle and caudal thirds prior

to sectioning. The right and left lungs were removed from two opossums for serial sectioning of the conducting components of the respiratory system and parenchyma of the lung. All samples were processed for light microscopy using a Tissue TEK VIP 1000 (Floor Model, Mode #4617, Serial #8811895, Ames Division, Miles Laboratories Inc., P.O. Box 70, Elkhart, IN 46515) through a series of dehydration and infiltration. The tissues were dehydrated in a graded series of ethanol (80%, 95%, 95%, 100%, 100%, 100%) followed by two series of xylene under a pressure (.35 kg.cm^2) and vacuum cycle (50.0 cm Hg) at 40°C for one hour. The samples were infiltrated with paraffin (Paraplast Tissue embedding Medium, Oxford Labware, Division of Sherwood Medical, St. Louis, MO 63103) under a pressure (.35 kg. cm^2) and vacuum cycle (50.0 cm Hg) at 60°C for one hour (repeated twice). Samples were then embedded in paraffin and positioned in tissue molds to obtain blocks that would yield transverse sections through the trachea and bronchi when cut. Random sections 5.0 µm (microns) in thickness were taken at 75.0 µm intervals from the blocks containing the trachea and bronchi. Serial sections (5.0 µm thick) were made from both lungs. All sections were mounted on glass slides and stained with either hematoxylin and eosin or Acid Orcein Giemsa (Luna, 1968).

The trachea and lungs of the seventh gray short-tailed opossum (male) were fixed *in situ* by vascular of perfusion of 2.5% gluteraldehyde (25% Gluteraldehyde EM Grade, Electron Microscopy Sciences, PO Box 251, 321 Morris Road, Ft. Washington, PA 19034) in 0.1M cacodylate buffer (pH = 7.4) (Sodium Cacodylate Trihydrate, Electron Microscopy Sciences, PO Box 251, 321 Morris Road, Ft. Washington, PA 19034) via the catheterized left common carotid artery. The opossum was then placed in the cooler

at $5^{o}C$ for 24 hours after which the thoracic cavity was opened and the trachea and lungs removed and placed in new 2.5% gluteraldehyde in 0.1M cacodylate buffer. It was returned to the cooler until samples were taken. Tissue samples were taken from the trachea and lungs, cut into 1.0 mm cubes and washed three times, ten minutes each, in distilled water. Samples were post fixed in a 1:1 mixture of 2% aqueous osmium tetroxide and 3% aqueous potassium ferrocyanide at room temperature for 2 hours or longer until the tissue became dark brown or black in color. The samples were then removed from the osmium ferrocyanide and were again washed three times for ten minutes in distilled water. Following this, the samples were dehydrated for ten minutes each in 50%, 70%, 80% and 90% ethanol followed by two washes in 100% ethanol for 60 minutes each. Samples were then removed from the 100% ethanol and washed two times, fifteen minutes each, in propylene oxide (Polysciences Inc. Warrington, PA 18976). After the final washing the tissue samples were placed in tissue micromolds (Polysciences Inc. Warrington, PA 18976) and embedded in epon araldite (Russell and Burguet, 1977). Random sections of 1.0 – 2.0 µm were cut, mounted on glass slides and stained with a mixture of 1:1 mixture of methylene blue (Methylene Blue, Sigma Chemical Company, PO Box 14508, St. Louis, MO 63178) and azure blue (Azure II, Sigma Chemical Company, PO Box 14508, St. Louis, MO 63178).

CHAPTER IV

MACROSCOPIC ANATOMY OF THE LOWER RESPIRATORY TRACT OF THE GRAY SHORT-TAILED OPOSSUM (*Monodelphis domestica*)

ABSTRACT:

The present study describes the macroscopic anatomy of the lower respiratory tract of the gray short-tailed opossum (*Monodelphis domestica*). The trachea consists of approximately 25 c-shaped tracheal cartilages and extends from the larynx to its bifurcation into right and left principal bronchi. The right lung is divided into cranial, middle, caudal and accessory lobes by interlobar fissures. The left lung consists of cranial and caudal lobes which are not divided by an interlobar fissure. Lung lobation was verified from tracheobronchial casts.

INTRODUCTION:

Gray short-tailed opossums have become practical for use as models in several fields of research including embryogenesis (Baggott and Moore, 1990; Selwood and Vandeberg, 1992; Kuehl-Kovarik, 1995), reproduction, sexual differentiation, behavior, chemical communication (Vandeberg, 1983 and 1995), nervous system development, DNA repair mechanisms, cytogenetics and biochemical genetics (Vandeberg, 1990). They have also been identified as the only laboratory mammal that develops melanoma in response to ultraviolet radiation (Kusewitt *et al*., 1991; Ley *et al*., 1991; Sabourin *et al*., 1992; Vanderberg *et al*., 1992; Robinson, 1994; Hubbard, 1997). Despite their increasing

popularity as a research animal, few anatomical descriptions of the gray short-tailed opossum exist. Peukert-Adam *et al*. (1994) describe the pancreas while Koch *et al*. (1990) provide a general description of the abdominal organs of the gray short-tailed opossum. Kusewitt (1994) and Hubbard (1997) report pathological changes in the respiratory and cardiovascular system of the gray short-tailed opossum but do not describe normal thoracic anatomy. To benefit research involving these animals, especially when pathological changes are present, this study will document the normal macroscopic anatomy of the lower respiratory tract of the gray short-tailed opossum.

MATERIALS AND METHODS:

Eighteen, 2 - year - old, sexually mature gray short-tailed opossums of both sexes were randomly divided into two groups for study of lower respiratory tract anatomy. Following exsanguination, the lower respiratory tracts from six animals were air-dried for 48 hours after which RTV silicone (Silicone Inc. P.O. Box 363, 211 Woodbine High Point, NC, 27261) was injected into the trachea to produce tracheobronchial casts (Henry, 1992). The remaining twelve animals were embalmed with 10% buffered formalin and the lower respiratory tracts were removed and utilized for gross anatomical descriptions.

RESULTS:

Trachea:

The trachea consists of a cervical part (pars cervicalis trachea) and a thoracic part (pars thoracica trachea). The cervical trachea is located along the midline of the neck ventral to the bodies of the cervical vertebrae (vertebrae cervicales). The cervical portion of the esophagus (pars cervicalis esophagus) is located slightly dorsal and to the left of the trachea. The cervical trachea is covered ventrally by the sternohyoideus muscles (musculi sternohyoideus) and laterally by the sternothyroideus muscles (musculi sternothyroideus). After passing through the thoracic inlet (apertura thoracis cranialis), the thoracic trachea continues caudally along the midline, with the esophagus remaining dorsal and to the left of it, and terminates at the tracheal bifurcation (bifurcatio tracheae) (Figure 4 - 1). The trachea bifurcates dorsal to the base of the heart (basis cordis) at the level of the second to third intercostal spaces (spatium intercostale) and gives rise to the right and left principal bronchi (bronchus principalis, dexter et sinister). The trachea is made up in part by 23 to 26 tracheal cartilages (cartilagines tracheales) with the most frequent number being 25 (40% of animals). These hyaline cartilages are c-shaped and incomplete dorsally with the free ends of the cartilages joined by smooth muscle (musculus tracheales) (Figure 4 - 2). Tracheal cartilages will frequently anastomose with adjacent cartilages in a random manner (Figure 4 - 1). The average distance from the first tracheal cartilage to the tracheal bifurcation *in situ* is 30.27 mm with a standard deviation of ± 2.35 mm. The lumen of the trachea is round to oval on cross section with an average

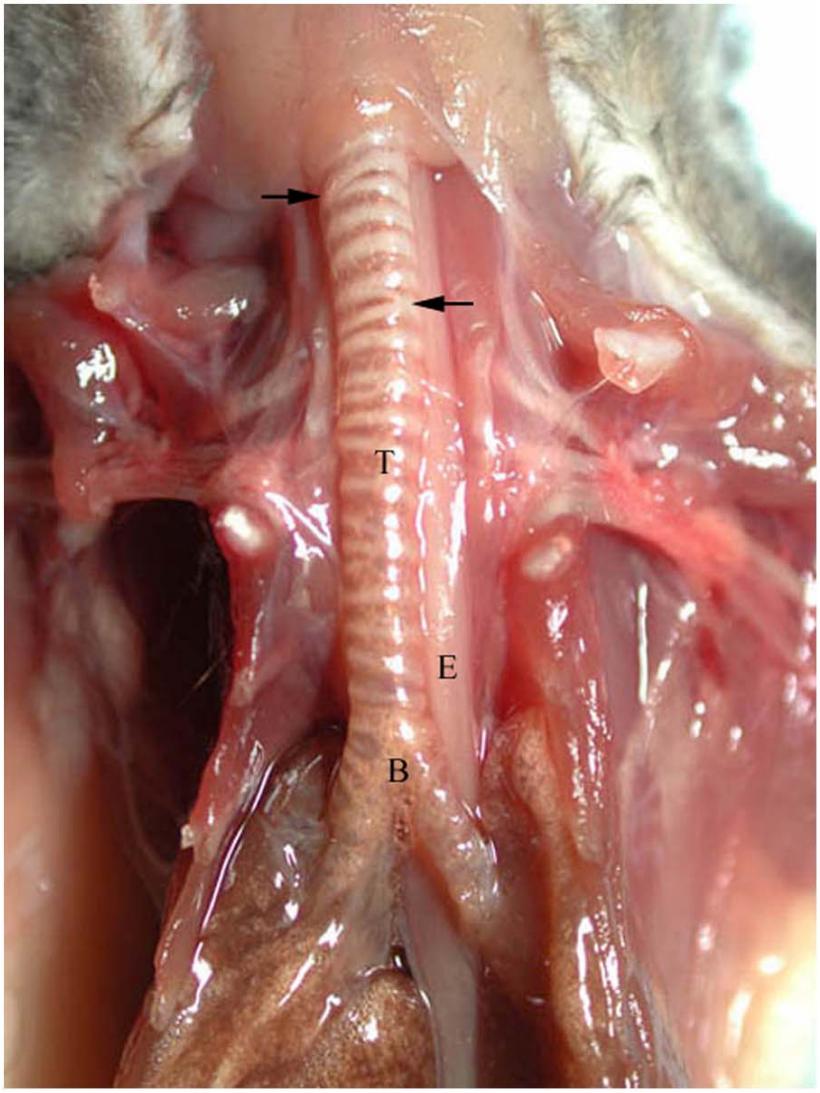

Figure 4 - 1. Ventral view of lower respiratory tract *in situ.* The heart and great vessels have been removed. Trachea (T), tracheal bifurcation (B), esophagus (E), tracheal ringanastomoses (arrows).

Figure 4 - 2. Cross section of trachea. Tracheal cartilage (C), trachealis muscle (T). H&E.

diameter in the cranial third of 3.18 ± 0.28 mm, in the middle third of 2.94 ± 0.20 mm and the caudal third of 2.05 ± 0.08 mm. The tracheal cartilages are approximately 1.0 mm wide in a cranial to caudal direction.

Lungs:

Each lung (pulmo) has a costal (facies costalis), medial (facies medialis) and diaphragmatic (facies diaphragmatica) surface, along with dorsal (margo dorsalis) and ventral (margo ventralis) margins. The costal surfaces are smooth, convex and in contact with the thoracic wall. The medial surfaces are smooth and concave. Present on the medial surface of each lung is a cardiac impression (impressio cardiaca) which is created by the heart. The diaphragmatic surfaces of the lungs are smooth and concave. This concavity results from the base of the lungs (basis pulmonis) lying against the cranial surface of the diaphragm. The dorsal margins of the lungs are rounded and located along the ventrolateral surfaces of the thoracic vertebral bodies (corpus vertebrae thoracicae). The ventral margin of the right lung is thin and interrupted by interlobar fissures (fissura interlobaris). The ventral margin of the left lung is thin with several small fissures.

A simple squamous pleural membrane lines the thoracic wall and covers the lungs and other mediastinal structures within the thoracic cavity (cavum thoracis). The visceral pleura (pleura pulmonalis) is tightly adhered to the lungs. The parietal pleura (pleura parietalis) covers the medial surfaces of the ribs (costae), the intercostal muscles (musculi intercostales), the thoracic portion of the sympathetic trunk (truncus sympathicus), the cranial surface of the diaphragm and numerous mediastinal structures. A pulmonary

ligament (ligamentum pulmonale) attaches the dorsomedial border of each lung to the middle and caudal mediastinal pleura (pleura mediastinalis). Each ligament extends along the medial surface of the lung from the hilus (hilus pulmonis) in a caudal direction.

The right lung (pulmo dexter) consists of a cranial lobe (lobus cranialis), middle lobe (lobus medius), caudal lobe (lobus caudalis) and an accessory lobe (lobus accessorius) (Figure 4 - 3). The cranial lobe is pyramidal. The apex of the right lung extends cranially to the thoracic inlet. During the inspiratory phase of respiration, the cranial lobe extends from the right first to fourth intercostal spaces. The medial surface of this lobe covers the right cranial vena cava (vena cava cranialis) and the cranial part of the right atrium (atrium dextrum) of the heart.

The middle lobe of the right lung is triangular in shape and extends ventrally toward the sternum. The cranial extent of this lobe covers the caudal part of the right atrium of the heart. The middle lobe curves caudoventrally around the right ventricle (ventriculus dextrum), extending past the apex of the heart (apex cordis), to the left of the median plane. Upon crossing the sternum, this appendage of the middle lobe inclines dorsally to terminate near the fourth to fifth costochondral junctions. The middle lobe extends from the right second through fifth intercostal spaces in the inspiratory phase and is approximately twice as large as the cranial lobe. The middle lobe is separated from the cranial lobe by a vertical fissure. A well-defined cardiac notch (incisura cardiaca pulmonis dextri) is not present between the cranial and middle lobes of the right lung. However, the auricular surface (facies auricularis) of the heart is exposed to the left ventral thoracic wall between the right and left lungs from the first to fourth intercostal

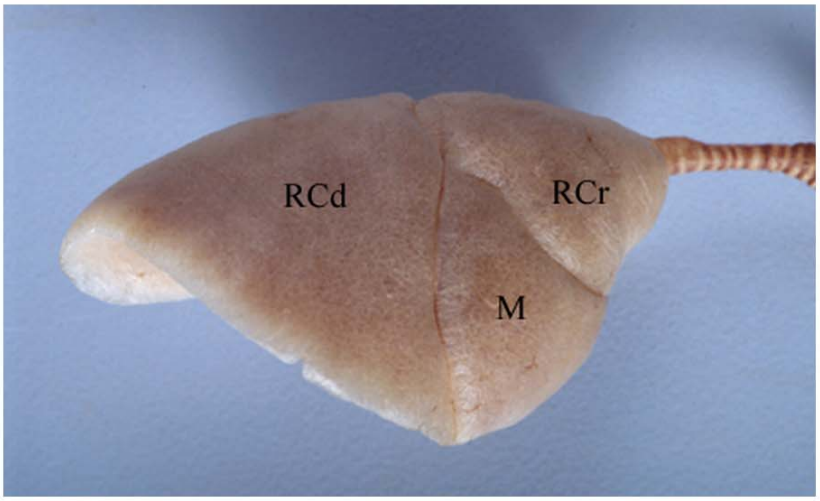

Figure 4 - 3. Lateral view of right lung. Cranial lobe (RCr), middle lobe (M), cadual lobe (RCd).

spaces. The apex of the heart is directed caudoventrally, as well as 35-40° to the left of the midline and extends toward the left fourth intercostal space (Figure 4 - 4). The sternopericardial ligament (ligamentum sternopericardiacum) connects the fibrous pericardium (pericardium fibrosum) at the apex of the heart to the endothoracic fascia (fascia endothoracica) at the left fourth intercostal space as well as to the diaphragm.

The caudal lobe of the right lung extends from the right third to sixth intercostal spaces in the inspiratory phase. This lobe is triangular in shape and is approximately twice as large as the middle lobe. The caudal lobe is separated from the middle lobe by an oblique fissure. The base of the caudal lobe is in contact with the cranial surface of the diaphragm. The caudal vena cava (vena cava caudalis) and the accessory lobe are located medial to this lobe. The cranioventral margin of the caudal lobe is notched by the caudal vena cava.

The accessory lobe is the smallest lobe of the right lung and is shaped like an irregular pyramid. The cranial surface of this lobe rests on the caudodorsal aspect of the heart resulting in a prominent cardiac impression on this lobe. The caudal surface of this lobe is molded to the convex, cranial surface of the diaphragm. The right and left surfaces of the accessory lobe lie adjacent to the medial surfaces of the caudal lobes of the right and left lungs. The right surface of the accessory lobe has a notch (sulcus venae cava caudalis) through which the caudal vena cava passes. The left surface of the accessory lobe is elongated and rests within the mediastinal recess (recessus mediastini) which is a space between the plica vena cava (plica venae cavae) and the caudal mediastinal pleura. The caudal vena cava is attached by the triangular shaped plica vena

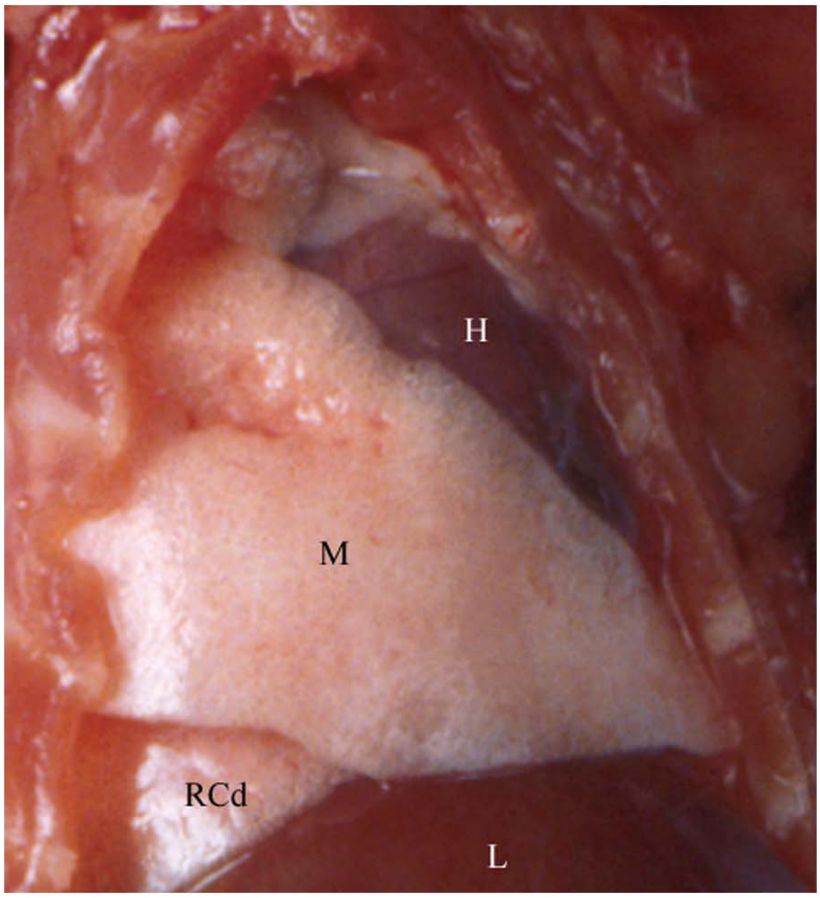

Figure 4 - 4. Ventral view of thoracic viscera. Heart (H), middle lobe of right lung (M), caudal lobe of right lung (RCd), liver (L).

cava to the mediastinal pleura. The plica, which is a double fold of mediastinal pleura, attaches dorsally to the caudal vena cava, cranioventrally to the pericardium of the heart and caudally to the diaphragm.

The left lung (pulmo sinister) consists of cranial and caudal lobes (Figure 4 - 5). These lobes are not separated from one another by a deep fissure. As a result, these lobes are not identifiable based on superficial features of the lung. This lung covers the left atrium (atrium sinister) and a portion of the left ventricle (ventriculus sinister) of the heart. The ventral margin of this lung typically has multiple small fissures. These fissures are randomly located and usually do not coincide with lobar division (Figure 4 - 5). In the inspiratory phase, the left lung extends from the first through seventh intercostal spaces. An aortic impression (impressio aortica) is formed on the dorsomedial surface of the cranial and caudal lobes by the aortic arch (arcus aortae) and descending aorta (aorta descendens). The caudal lobe also has an esophageal impression (impressio esophagea) formed by the esophagus on its medial surface.

Bronchial Tree:

Bifurcation of the trachea into the right and left principal bronchi marks the beginning of the bronchial tree (arbor bronchalis). The principal bronchi enter the hilus of the lungs where they divide into lobar bronchi (bronchi lobares) (Figure 4 - 6). The left principal bronchus is on average 6.22 ± 0.69 mm in length and the right principal bronchus averages 6.57 ± 0.6 mm in length.



Figure 4 - 5. Lateral view of left lung. Cranial lobe of left lung (LCr), caudal lobe of left lung (LCd), middle lobe of right lung (M).



Figure 4 - 6. Ventral view of tracheobronchial cast. Trachea (T), right principal bronchus (R), left principal bronchus (L), right cranial lobar bronchus (RCr), right middle lobar bronchus (M), right caudal lobar bronchus (RCd), accessory lobar bronchus (A), left cranial lobar bronchus (LCr), left caudal lobar bronchus (LCd).

The right principal bronchus divides into cranial, middle, caudal and accessory lobar bronchi. The cranial lobar bronchus originates from the dorsolateral surface of the right principal bronchus and gives off five segmental bronchi (bronchi segmentales) which radiate in cranial and caudal directions from their origin. The middle lobar bronchus originates from the ventrolateral surface of the right principal bronchus cranial to the origin of the accessory and caudal lobar bronchi. The middle lobar bronchus gives off six segmental bronchi, which radiate cranially, caudally and dorsally. The accessory lobar bronchus is the last branch to arise from the right principal bronchus at which point the right principal bronchus continues caudally as the caudal lobar bronchus. The accessory lobar bronchus originates ventromedially from the right principal bronchus and gives off five to six segmental bronchi which radiate in cranial and caudal directions. Finally, the caudal lobar bronchus gives off six to seven segmental bronchi which radiate into the lung parenchyma.

The left principal bronchus divides into cranial and caudal lobar bronchi. The cranial lobar bronchus originates ventrolaterally from the left principal bronchus. The cranial lobar bronchus divides into two bronchi which supply cranial and caudal parts of the left cranial lung lobe. Arising from each of these bronchi are six segmental bronchi which radiate into the parenchyma. The caudal lobar bronchus continues the left principal bronchus caudally and has six to eight segmental bronchi which radiate into the parenchyma.

DISCUSSION:

The trachea of the sexually mature gray short-tailed opossum consists in part of "c"-shaped tracheal cartilages with the free ends joined together by the trachealis muscle as is typical of most mammals. Tracheal cartilage number in the gray short-tailed opossum falls within the range reported in other marsupials which is nineteen rings in the gray four-eyed opossum (*Metachirus opossum)* to thirty-four in the bandicoot (*Perameles obesula)* and thirty-five in both the lesser gliding opossum (*Petaurus sciureus*) and tree kangaroo (*Dendrolagsus ursinus*) (Sonntag, 1921b).

The lobation of the right lung of the gray short-tailed opossum is similar to previous descriptions of many marsupials including the mouse opossum (*Marmosa elegans*), gray four-eyed opossum, bandicoot, Phalangeridae (Sonntag, 1921a), brush-tailed opossum (*Trichosurus vulpecula*) (Sonntag, 1921b), Caenolestes (Osgood, 1921), Dasyuridae (Owen, 1868; Jones, 1948), Perameles and Petaurists (Owen, 1868). Owen (1868) describes the right lung of Potoroo as having two to three deep fissures and an azygous lobe. This may indicate that it also has four lobes with one of them perhaps further subdivided. A right lung divided into four lobes is a common pattern found in most of the smaller marsupials.

Several other marsupials possess right lung lobation which differs from that of the gray short-tailed opossum. The right lung of the tree kangaroo (*Dendrolagus ursinus*), eastern grey kangaroo (*Macropus giganteus*) and wallaroo (*Macropus bennetti)*, which is trilobate, is described as having a deep median sulcus incompletely dividing the lung into anterior and posterior parts with the azygous lobe in addition (Sonntag, 1921a). Owen

(1868) states that the right lung of the whiptail wallaby (*Macropus parryi)* has one to two notches possibly indicating the absence of distinct divisions between lobes based on external appearance. The right lung of the red-legged short-tailed opossum (*Didelphys brachyura)* consists of three lobes and the right lung of the wombat (*Vombatus ursinus*) consists of a two lobes. The right lung of the koala (*Phascolactos cinereus)* is described by Forbes (1881) as having three lobes without the azygous lobe while Sonntag (1921b) states that the right lung of the koala consists of only two lobes. The right lung of the common shrew opossum (*Caenolestes obscurus)* has three lobes with the anterior lobe slightly notched which corresponds to where a complete division was found in Didelphids (Osgood, 1921). Osgood (1921) also states that in a third specimen the right lung consisted of four lobes thus indicating variability in lung lobation within this species. While a few of the smaller marsupials possess a right lung exhibiting a pattern of lobation different from that found in the gray short-tailed opossum, larger marsupials such as the kangaroos, wallabies and koala consistently have fewer lobes attributed to the right lung. Earlier reports on marsupial respiratory anatomy often use human anatomy terms in naming the cranial lobe as the upper lobe, the middle lobe as the ventral lobe, the caudal lobe as the lower lobe and the accessory lobe as the azygous lobe or intermediate lobe.

While a cardiac notch is not present on the right lung of the gray short-tailed opossum, the angulation of the longitudinal axis of the heart to the left of the midline allows access to the heart via cardiac puncture in the left third and fourth intercostal spaces near the sternum. The longitudinal axis of the koala heart is described as being

parallel to the left side of the sternum with the apex of the heart extending to the left fourth intercostal space (Sonntag, 1921b). Additional descriptions of marsupial heart angulation could not be located for further comparisons.

The left lung of the gray short-tailed opossum consists of two lobes with the cranial lobe being further sub-divided into two parts. The lobes of the left lung are not separated by an interlobar fissure as are those of the right lung. The only superficial indications which might be used for lobar demarcation are small, 1.0 – 2.0 mm fissures which are located along the ventral margin of the lung. These small fissures were found to be variable in location and number between animals with marked variation between animals obtained from different sources. Thus, the fissures were of little use in identification of the two lobes of the left lung from the surface of the organ. Due to the absence of external lobar demarcation, intercostal landmarks for the cranial and caudal lobes are difficult to define as well as the cranial and caudal parts of the cranial lobe without further study.

The left lung of the brush-tailed opossum (Sonntag, 1921b), Phalangeridae (Owen, 1868; Sonntag, 1921a), mouse opossum (Sonntag, 1921a), koala (Owen, 1868; Forbes, 1881), quoll (*Dasyurus*) (Owen, 1868), *Dasycercus cristicauda* (Jones, 1948) and Petaurists (Owen, 1868) is described as having a cranial and caudal lobe. Sonntag (1921a) and Owen (1852) state that in *Macropodidae*, in which the tree kangaroo, wallaroo and eastern grey kangaroo were examined, the left lung has deep median sulci or clefts dividing it into anterior and posterior parts. The left lung of other marsupials such as the gray four-eyed opossum, long-nosed bandicoot (Sonntag, 1921a), pig-footed

bandicoot (*Choeropus castanotis*) (Parsons, 1903), Caenolestes (Osgood, 1921), wombat and American opossum (Owen, 1868) is described as being unilobate apparently based on the external appearance of the lung as branching of the bronchial tree was not mentioned. Owen (1868) states that the left lung of Potoroo has a fissure on the anterior or upper ridge and the left lung of the whiptail wallaby has one to two notches. He classifies the left lung of these animals as unilobate. These external markings were probably similar to what we observed in the gray short-tailed opossum giving the impression of being not lobated. Lobation of the left lung, across all marsupial species, is described as having one or two lobes. Those described as having one lobe might actually be found to consist of two lobes should one examine tracheobronchial casts of those specimens or dissect the bronchial tree.

Lung lobation in the gray short-tailed opossum was based upon the division of the bronchial tree as described by Nomina Anatomica Veterinaria (International Committees on Veterinary Gross Anatomical Nomencalture, 1994) rather than on the external appearance of the lung. We accomplished this by examination of tracheobronchial casts to identify the lobar bronchi which supply the lung. We were unable to locate data on the branching pattern of the bronchial tree for other marsupials for comparison.

CHAPTER V

MACROSCOPIC ANATOMY OF THE LOWER RESPIRATORY TRACT OF THE NORTH AMERICAN OPOSSUM (*Didelphis virginiana*)

ABSTRACT:

This study documents the macroscopic anatomy of the lower respiratory tract of the North American opossum (*Didelphis virginiana*). The trachea consists of approximately 28 c-shaped cartilages and extends from the larynx to its bifurcation into right and left principal bronchi. The right lung consists of cranial, middle, caudal and accessory lobes which are separated from one another by interlobar fissures. The left lung consists of cranial and caudal lobes which are not separated by interlobar fissures. Lobation of the right and left lungs was verified from tracheobronchial casts.

INTRODUCTION:

The North American opossum (*Didelphis virginiana*), has become more prominent as a patient in veterinary medicine due to advancements in wildlife rehabilitation. Therefore, it is essential to have an available source on the normal macroscopic anatomy of all the organ systems of the North American opossum especially when evaluating pathological changes.

Additionally, the North American opossum has been used in biomedical research for over twenty-five years. It has served as a model for embryogenesis (Klima, 1987;

Renfree, 1990; Szalay, 1994), cytogenetic studies (Oswaldo-Cruz, 1968) and physiological studies (Suzuki *et al*., 1988; Leichus *et al*., 1997). The first anatomical descriptions on the osteology, myology (Coues, 1872) and general visceral topography (Tyson, 1698) of the North American opossum date back three hundred years. Subsequent anatomical descriptions of the North American opossum have briefly described the lung (Brewer, 1923) and general visceral topography (Sonntag, 1921a and 1921b; Ellsworth, 1966 and 1976). However, none provide a complete description or photographic record of the lower respiratory tract. To benefit research and medicine involving the North American opossum, complete anatomical records of the various organ systems are a necessity.

MATERIALS AND METHODS:

Eighteen North American opossums (9 males and 9 females) of various ages were used to study lower respiratory tract anatomy. The lower respiratory tracts from 6 animals were removed and air-dried with laboratory air for 48 hours after which RTV silicone (Silicone Inc. P.O. Box 363, 211 Woodbine High Point, NC, 27261) was injected into the trachea to produce tracheobronchial casts (Henry, 1992). The lower respiratory tracts from the remaining 12 animals were dissected and examined *in situ* and *ex vivo*. Some lungs were inflated *in situ* to mimic the inspiratory phase for documentation of intercostal landmarks of the individual lobes.

RESULTS:

Trachea:

The cervical trachea (pars cervicalis trachea) is located along the ventral midline of the cervical region with the esophagus (pars cervicalis esophagus) lying dorsal and to the left. The cervical trachea is covered ventrally by the right and left sternohyoideus muscles (musculi sternohyoideus) and laterally by the sternothyroideus muscles (musculi sternothyroideus). After passing through the thoracic inlet (apertura thoracis cranialis), the thoracic trachea (pars thoracica trachea) continues caudally along the dorsal midline and terminates at the tracheal bifurcation (bifurcation tracheae). The trachea maintains its orientation to the esophagus similar to that in the cervical region. The trachea bifurcates dorsal to the base of the heart (basis cordis) at the level of the third intercostal space (spatium intercostale) into the right and left principal bronchi (bronchus principalis dexter et sinister) (Figure 5 - 1). The average distance from the first tracheal cartilage (cartilaginous tracheales) to the tracheal bifurcation *in situ* is 70.0 ± 1.28 mm. The tracheal cartilages are c-shaped and incomplete dorsally with the ends of the tracheal cartilages joined by smooth muscle (musculus tracheales). The North American opossum has 25 to 29 cartilages with the most frequent number being 28 (57% of animals). Tracheal cartilage anastomosis occurs in the middle one-third of the trachea and can involve two or three adjacent cartilages.

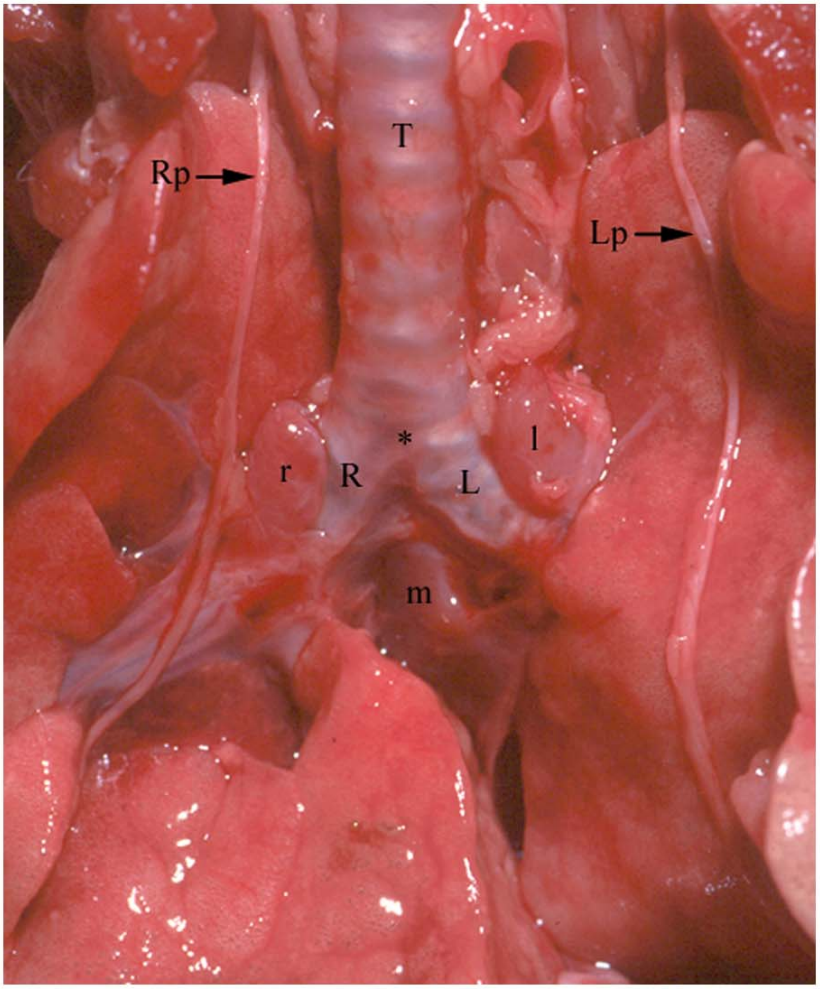

Figure 5 - 1. Ventral view of thoracic respiratory tract (heart and great vessels removed). Thoracic trachea (T), tracheal bifurcation (*), right principal bronchus (R), left principal bronchus (L), right tracheobronchial lymph node (r), left tracheobronchial lymph node (l), middle tracheobronchial lymph node (M), right phrenic nerve (Rp), left phrenic nerve (Lp).

Lungs:

Each lung (pulmo) has a costal (facies costalis), medial (facies mediales) and diaphragmatic surface (facies diaphragmatica) along with dorsal and ventral margins (margo dorsalis et ventralis). The costal surfaces are smooth, convex and in contact with the thoracic wall. The medial surfaces of the lungs are smooth and concave. Present on the medial surface of each lung is a cardiac impression (impressio cardiaca) which is created by the heart. The diaphragmatic surfaces of the lungs are smooth and concave (Figure 5 - 2). This concavity results from the base of the lungs (basis pulmonis) lying against the convex surface of the diaphragm. The dorsal margins of the lungs are rounded and located along the ventrolateral surfaces of the thoracic vertebral bodies (corpus vertebrae thoracicae). The ventral margin of the right lung (pulmo dexter) is thin and interrupted by interlobar fissures (fissura interlobaris). The ventral margin of the cranial lobe (lobus cranialis) extends to the midline. However the ventral margin of the middle lobe (lobus medius) crosses to the left of the midline and terminates at the left fourth costochondral junction. The ventral margin of the left lung (pulmo sinister) is thin with 1 to 2 small fissures. The ventral margin of this lung does not cross the midline and only extends ventrally to the first through sixth costochondral junctions due to the ventral attachment of the mediastinal pleura to the left of the midline.

Pleura lines the thoracic wall and covers the lungs and other mediastinal structures within the thoracic cavity (cavum thoracis). The mediastinal pleura attaches dorsally along the vertebral bodies. Cranially its ventral attachment is along the midline and caudally it angles toward the left sixth costochondral junction (Figure 5 - 3). The visceral

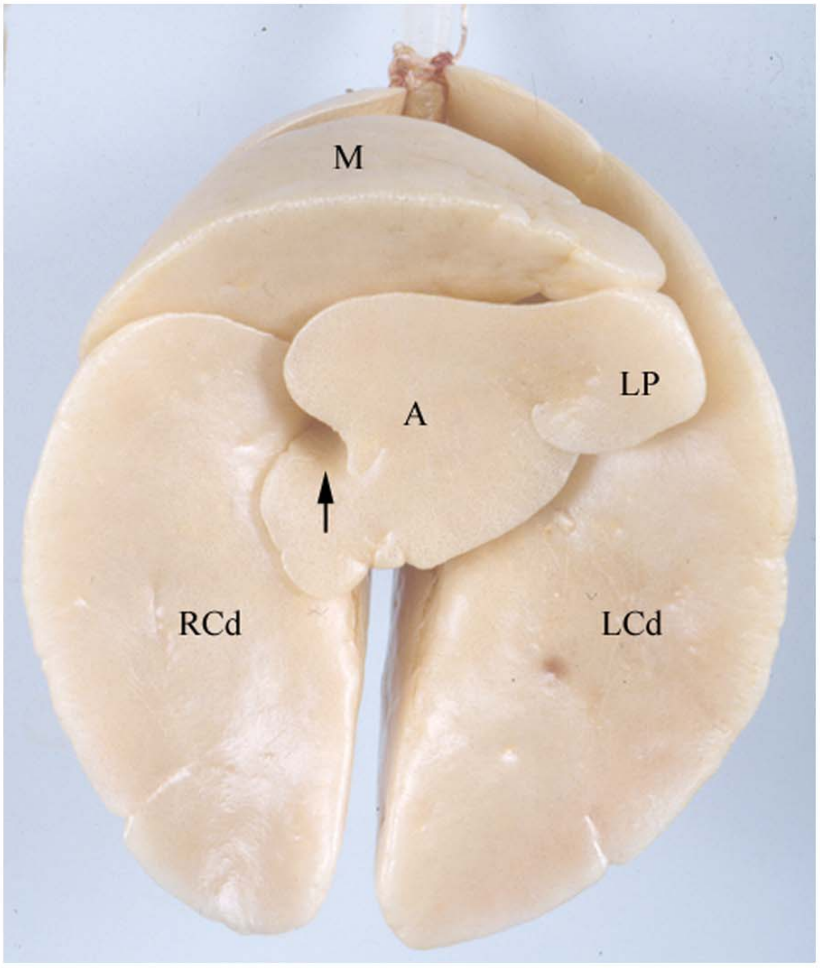

Figure 5 - 2. Caudal view of lungs. Middle lobe of right lung (M), caudal lobe of right lung (RCd), accessory lobe (A), notch for the caudal vena cava (arrow), left process of the accessory lobe (LP), caudal lobe of the left lung (LCd).

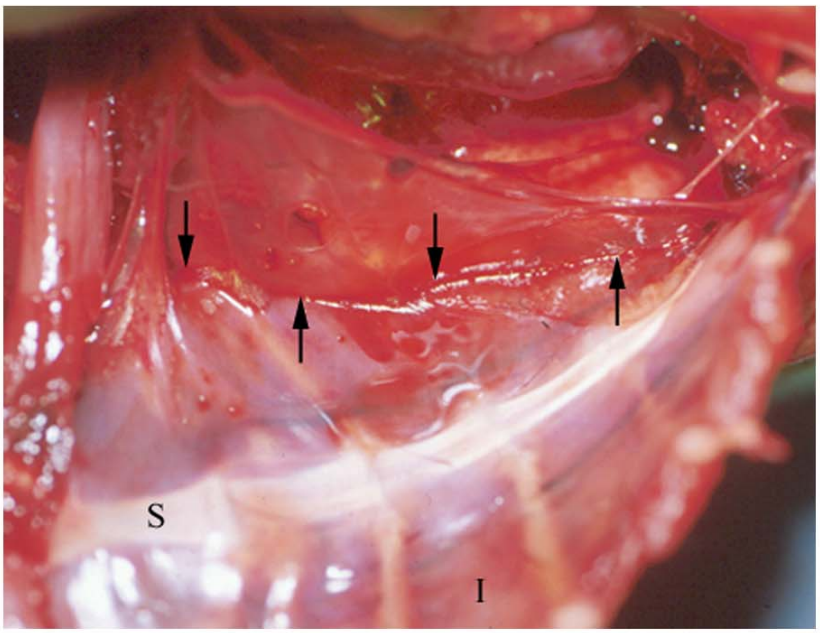

Figure 5 - 3. Dorsal view of the ventral thoracic cavity and sternum. Ventral attachment of the mediastinum (arrows), right third intercostal space (I), fifth sternabra (S).

pleura (pleura pulmonalis) is tightly adhered to the lungs. The parietal pleura (pleura parietalis) covers the medial surfaces of the ribs (costae), the internal intercostal muscles (musculi intercostales), the thoracic part of the sympathetic trunks (truncus sympathicus), the cranial surface of the diaphragm and numerous mediastinal structures. Attaching the dorsomedial border of each lung to the middle and caudal mediastinal pleura (pleura mediastinalis) is a pulmonary ligament (ligamentum pulmonale). Each pulmonary ligament extends along the medial surface of the lung from the hilus (hilus pulmonis) in a caudal direction.

The right lung consists of a cranial lobe, middle lobe, caudal lobe (lobus caudalis) and an accessory lobe (lobus accessorius). The cranial lobe extends from the first through fourth intercostal spaces in the inspiratory phase. The medial surface of this lobe covers the right cranial vena cava (vena cava cranialis) and the cranial part of the right atrium (atrium dextrum) of the heart.

The middle lobe of the right lung extends from the second through fifth intercostal spaces in the inspiratory phase. It is separated from the cranial lobe by an oblique fissure (Figure 5 - 4). The cranial extent of the middle lobe covers the caudal part of the right atrium of the heart. This lobe curves caudoventrally around the right ventricle (ventriculus dexter) and extends past the apex of the heart (apex cordis) to the left of the median plane. Upon crossing the dorsal surface of the sternum, this elongated portion of the middle lobe inclines dorsally and terminates at the level of the left fourth costochondral junction. A small cardiac notch (incisura cardiaca) may be present between the cranial and middle lobes of the right lung opposite the right second

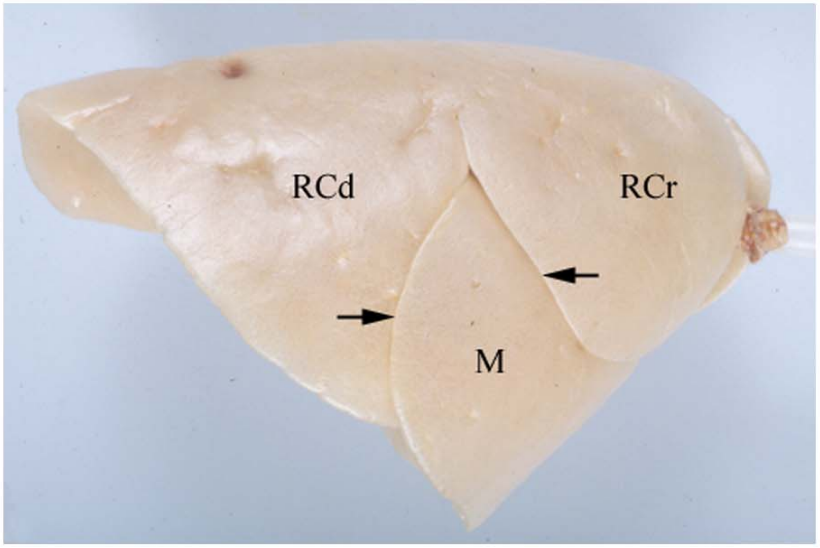

Figure 5 - 4. Lateral view of right lung. Cranial lobe (RCr), middle lobe (M), caudal lobe (RCd), interlobar fissures (arrows).

intercostal space. However the ventral surface of the heart is exposed to the left ventral thoracic wall between the right and left lungs from the first to fifth intercostal spaces. The apex of the heart is directed caudoventrally and to the left of the midline (33-37°) toward the left fourth intercostal space. A sternopericardial ligament (ligamentum sternopericardiacum), which is continuous with the fibrous pericardium and the pericardial mediastinal pleura, extends from the apex of the heart to the endothoracic fascia (fascia endothoracica) and the parietal pleura at the left fifth to sixth costochondral junctions.

The caudal lobe of the right lung extends from the fourth to eighth intercostal spaces in the inspiratory phase. This lobe is approximately twice as large as the middle lobe of the right lung. The caudal lobe is separated from the middle lobe by a vertical fissure (Figure 5 - 4). Laying medial to the caudal lobe is the caudal vena cava (vena cava caudalis) and the accessory lobe of the right lung (Figure 5 - 2).

The accessory lobe is the smallest lobe of the right lung and is shaped like an irregular pyramid. This lobe lies medial to the caudal lobes of the right and left lungs (Figure 5 - 2). The cranial surface of this lobe rests on the caudodorsal aspect of the heart resulting in a prominent cardiac impression. The caudal surface of this lobe is molded against the convex surface of the diaphragm. The right surface of the accessory lobe has a notch (sulcus venae cava caudalis) through which the caudal vena cava passes (Figure 5 - 2). The left process of the accessory lobe is elongated and rests within the mediastinal recess (recessus mediastini) which is a space between the plica vena cava (plica venae cavae) of the caudal vena cava and the caudal mediastinal pleura (pleura mediastinalis).

The left lung consists of cranial and caudal lobes. This lung extends from the first to eighth intercostal spaces in the inspiratory phase. The ventral margin of this lung has 1 to 2 small fissures. These fissures are located on the cranial lobe of the left lung and do not coincide with the lobar division (Figure 5 - 5). The medial surface of this lung covers the entire left atrium (atrium sinistrum) and a portion of the left ventricle (ventriculus sinister) of the heart.

Bronchial Tree:

Bifurcation of the trachea into the right and left principal bronchi marks the beginning of the bronchial tree (arbor bronchalis) (Figure 5 - 6). The right principal bronchus is on average 13.08 ± 1.61 mm in length and the left principal bronchus is on average 11.73 ± 2.03 mm in length. The right and left principal bronchi enter the hilus of the lungs at which point they divide into lobar bronchi (bronchi loabres).

The right principal bronchus divides into cranial, middle, caudal and accessory lobar bronchi (Figure 5 - 7). The cranial lobar bronchus originates from the dorsolateral surface of the right principal bronchus and gives off six to seven segmental bronchi (bronchi segmentales) which radiate in cranial, caudal and dorsal directions. The middle lobar bronchus originates from the ventral surface of the right principal bronchus cranial to the origin of the accessory and caudal lobar bronchi. The middle lobar bronchus gives off ten segmental bronchi which radiate cranially, caudally and laterally. The accessory lobar bronchus originates ventromedially from the right principal bronchus cranial to the origin of the caudal lobar bronchus. The accessory lobar bronchus gives off eight



Figure 5 - 5. Lateral view of left lung. Cranial lobe (LCr), caudal lobe (LCd), marginal fissure (arrow).

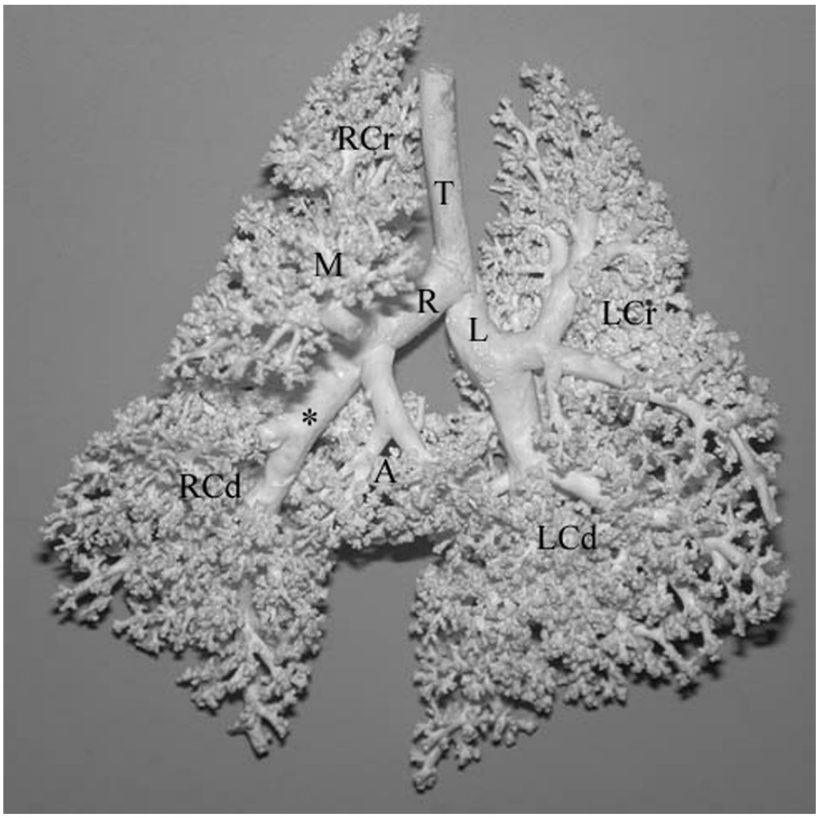

Figure 5 - 6. Ventral view of lower respiratory system cast. Trachea (T), right principal bronchus (R), right cranial lobe (RCr), middle lobe (M), right caudal lobe (RCd), right caudal lobar bronchus (*), accessory lobe (A), left principal bronchus (L), left cranial lobe (LCr), left caudal lobe (LCd).

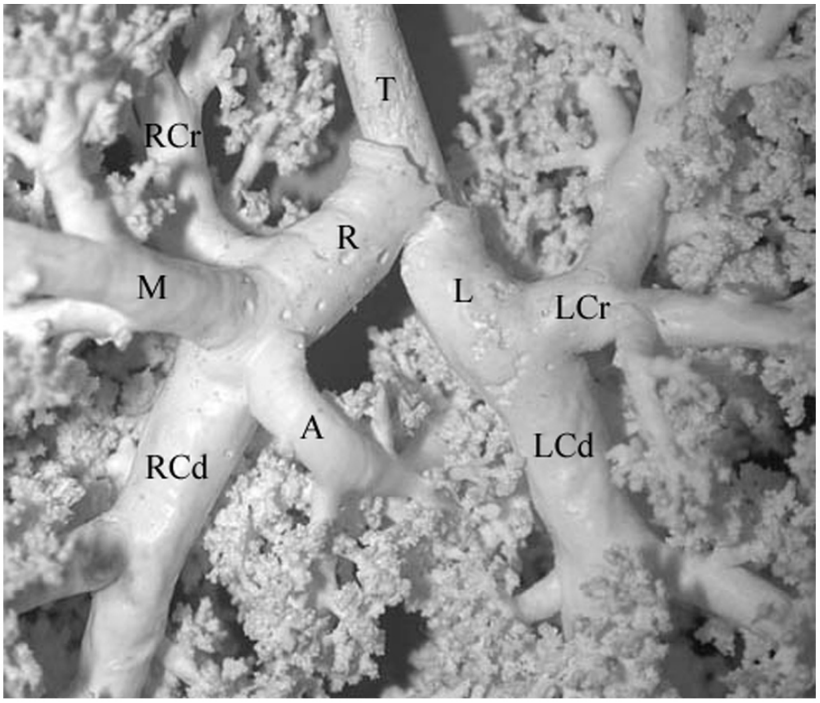

Figure 5 - 7. Ventral view of bronchial cast. Trachea (T), right principal bronchus (R), right cranial lobar bronchus (RCr), middle lobar bronchus (M), right caudal lobar bronchus (RCd), accessory lobar bronchus (A), left principal bronchus (L), left cranial lobar bronchus (LCr), left caudal lobar bronchus (LCd).

segmental bronchi which radiate cranially, caudally, dorsally and ventrally. The caudal lobar bronchus continues the right principal bronchus caudally and gives off nine to ten segmental bronchi which radiate into the parenchyma.

The left principal bronchus divides into cranial and caudal lobar bronchi (Figures 5 - 6 and 5 - 7). The cranial lobar bronchus originates ventrolaterally from the left principal bronchus. The cranial lobar bronchus divides into two bronchi, cranial and caudal branches, which supply cranial and caudal parts of the left cranial lung lobe (Figure 5 - 7). The cranial and caudal branch each give rise to four or five segmental bronchi which radiate dorsally, cranially and caudally. The caudal lobar bronchus originates caudal to the origin of the cranial lobar bronchus. Arising from the caudal lobar bronchus are six segmental bronchi which radiate into the parenchyma.

DISCUSSION:

Tracheal cartilage anastomoses, as seen in the North American opossum, has also been reported by Sisson and Grossman (Getty, 1975) to occur in domestic mammals. However, tracheal cartilage anastomosis in these mammals occurs randomly throughout the length of the trachea as opposed to only the middle third of the opossum trachea. The free ends of each tracheal cartilage in the North American opossum are joined by the trachealis muscle to form a complete ring which is also similar to many domestic mammals (Evans, 1993; Dyce *et al*., 1996).

The earliest reports on the respiratory anatomy of the North American opossum (Tyson, 1698; Owen, 1868) state the right lung consist of three lobes. However a

subsequent description of the lobation of the right lung of the Didelphyidae (Sonntag, 1921a) reports four lobes. We found that the right lung of the North American consists of four lobes which are separated from one another by deep interlobar fissures. In addition to what we observed in the North American opossum, several of the smaller marsupials such as the brush-tailed opossum (*Trichosurus vulpecula*) (Sonntag, 1921b), Phalangeridae and Phalangers (Owen, 1868; Sonntag, 1921a), mulgara (*Dasycercus cristicauda*) (Jones, 1948), long nosed bandicoot (*Perameles obesula*) (Sonntag, 1921a), Perameles, Petaurists and Dasyures (Owen, 1868) have similar lobation of the right lung. Variation in the North American opossum lung lobation in previous articles (Tyson, 1698; Owen, 1868; Sonntag, 1921a) may have resulted from using superficial features of the lung rather than the branching of the bronchial tree to determine lung lobation. This method of naming lobes was a common practice in previous anatomy texts and articles and has led to considerable confusion in determining lung lobation (Dyce *et al*., 1996).

The left lung of the North American opossum extends from the first through eighth intercostal spaces and consists of a cranial and caudal lobe. Interestingly the left lung does not have interlobar fissures demarcating the division of cranial and caudal lobes. This description of lobation of the left lung (as well as the right) is based upon the division of the bronchial tree as described by Nomina Anatomica Veterinaria (International Committee on Veterinary Gross Anatomical Nomenclature, 1994). Hence tracheobronchial casts were utilized to determine lobation since naming lobes based on superficial features is not reliable and should not be done (Dyce *et al*., 1996). A previous description of the North American opossum (Owen, 1868) indicates a similar lobation of

the left lung. As well, the Phalangeridae, mouse opossum (*Marmosa elegans*) (Sonntag, 1921a), brush-tailed opossum (Sonntag, 1921b), Petaurists, Phalangers, Dasyures (Owen, 1868) and mulgara (Jones, 1948) have a similar lobation of the left lung to the North American opossum. However, no mention is made of how Owen (1868), Sonntag (1921a and 1921b) or Jones (1948) determined lobation of the lungs. The variability in presence and location of small fissures on the ventral margin makes it difficult to accurately approximate the intercostal landmarks for the cranial and caudal lobes of the left lung in the North American opossum.

The right and left principal bronchi of the North American opossum divide into lobar bronchi to supply each lobe of the right and left lungs respectively. Within the lobe of each lung, the lobar bronchi give off numerous segmental bronchi. However the left cranial lobar bronchus divides into a cranial and caudal branch prior to the emergence of the segmental bronchi. These two branches supply the cranial and caudal parts of the left cranial lobe. Previous investigators describe a similar pattern of branching for the left cranial lobar bronchus in the canine (Getty, 1975; Evans, 1993; Dyce *et al*., 1996), feline (Adrian, 1964; Nickel *et. al*, 1979), sheep (Hare, 1955) and bovine (Stamp, 1948). However, Hare (1955), Adrian (1964), Getty, (1975) and Nickel *et. al* (1979) refer to these branches of the left cranial lobar bronchus as cranial and caudal segmental bronchi. In addition, Adrian (1964) and Getty (1975) state these segmental bronchi which ventilate the cranial and caudal bronchopulmonary segments, also give off numerous subsegmental bronchi. In earlier literature, Hare (1955), Adrian (1964) and Ishaq (1980) conclude there is lack of agreement on the definition of a bronchopulmonary segment.

Kramer and Glass (1932), Hare (1955), Getty, (1975), Nickel (1979), Ishaq (1980) and Schaller (1992) define a segmental bronchus as that which ventilates a bronchopulmonary segment and is a self-contained or independent section of lung tissue within a lobe. Also, Kramer and Glass (1932) and Getty (1975) state the segmental bronchus supplying a bronchopulmonary segment originates from a lobar bronchus. Then, according to Nickel (1979), the segmental bronchi dispatch bronchioles. Based on these definitions, the use of cranial and caudal segmental bronchi does not seem appropriate in the canine, feline, sheep or the North American opossum. Stamp's (1948) suggestion concerning the cranial and caudal branches of the left cranial lobar bronchus of the bovine lung seems to be the best description. According to him, these branches dispatch numerous segmental bronchi to supply the bronchopulmonary segments of the left cranial lobe. In addition, previous articles on the bronchial tree of domestic animals (Hare, 1955; Adrian, 1964) state that the nomenclature used in these species attempted to follow that established for human anatomy. However, Hare (1955) states that the nomenclature adopted for humans is not comparable when in fact it, along with Stamp's (1948), seems to be the best description for the branching pattern of the left cranial lobar bronchus. According to human anatomy terminology (Woodburne, 1973; Netter, 1989; Federative Committee on Anatomical Terminology, 1998) the left superior lobar bronchus divides into a superior division and an inferior division from which segmental bronchi are dispatched to the bronchopulmonary segments. This pattern is similar to what was observed in the North American opossum.

CHAPTER VI

ANATOMY OF STRUCTURES ASSOCIATED WITH THE LOWER RESPIRATORY TRACT OF THE GRAY SHORT-TAILED OPOSSUM (*Monodelphis domestica*).

ABSTRACT:

The present study documents the macroscopic anatomy of structures associated with the lower respiratory tract of the gray short-tailed opossum (*Monodelphis domestica*). Vascularization of lung parenchyma is via the bronchoesophageal artery which originates from the right fourth dorsal intercostal artery. The right and left pulmonary arteries divide into pulmonary lobar arteries which are located dorsal to the lobar bronchi and deliver blood to the lungs. Pulmonary lobar veins are located ventral to the lobar bronchi and return blood from the lungs to the heart. Cranial deep cervical, cranial mediastinal and tracheobronchial lymph nodes are located along the trachea and at the tracheal bifurcation. Sympathetic fibers leave the sympathetic trunks as thoracic splanchnic nerves to reach the lungs. Parasympathetic innervation to the lungs originates from branches of the vagus nerves.

INTRODUCTION:

Over the past twenty years, numerous scientific papers have been published describing the gray short-tailed opossum (*Monodelphis domestica*) as an ideal model for

research (Hubbard, 1997). These marsupials have been used to study embryogenesis (Baggott and Moore, 1990; Selwood and Vandeberg, 1992; Kuehl-Kovarik, 1995); reproduction, sexual differentiation, behavior and chemical communication (Vandeberg, 1983 and 1995); and nervous system development, DNA repair mechanisms and cytogenetic and biochemical genetics (Vandeberg, 1990). Despite the wide use of the gray short-tailed opossum in research, we were unable to locate any descriptions of normal anatomical structures associated with the respiratory tract of this opossum. The focus of this study will be to document the normal macroscopic anatomy of structures associated with the lower respiratory tract of the gray short-tailed opossum.

MATERIALS AND METHODS:

Ten, 2 - year - old, sexually mature gray short-tailed opossums (*Monodelphis domestica*) of both sexes were used for this study. Following anesthesia and exsanguination, all animals were embalmed with 10% buffered formalin and injected with epoxy or latex to aid in the visualization and dissection of the lower respiratory tract vasculature. Two of the ten opossums were used for tracheobronchial vascular casts (Henry, 1992a and 1992b). The trachea was exposed and transected caudal to the larynx. A plastic cannula was inserted and ligated in place. Silicone was injected into the trachea and airways via the plastic cannula. After hardening, the tracheobronchial vascular cast was removed from the animal and boiled to remove the parenchyma.

RESULTS:

Pulmonary Vasculature and Bronchoesophageal Artery:

The pulmonary trunk (truncus pulmonalis) bifurcates into right and left pulmonary arteries (arteria pulmonalis dextra et sinistra). The right and left pulmonary arteries cross the ventral surface of the respective principal bronchi (bronchus principalis) and curve laterally then dorsally to attain a position dorsal to each bronchi. As the right and left principal bronchi divide into lobar bronchi (bronchi lobares), the right and left pulmonary arteries divide into corresponding pulmonary lobar arteries. The right pulmonary artery divides into a cranial lobar branch (ramus lobi cranialis), a middle lobar branch (ramus lobi medii), a caudal lobar branch (ramus lobi caudalis) and an accessory lobar branch (ramus lobi accessorii). The left pulmonary artery divides into cranial and caudal lobar branches. The cranial lobar branch bifurcates into an ascending branch (ramus ascendens) and a descending branch (ramus descendens) to supply the cranial and caudal parts of the left cranial lung lobe. In general, the lobar arteries course along the dorsal surface of the lobar bronchi with the exception of the accessory lobar branch. This artery passes between the middle and caudal lobar bronchi of the right lung to course along the ventral surface of the accessory lobar bronchus (Figure 6 - 1).

A pulmonary lobar vein (venae pulmonalis lobi) originates from each lobe of the right and left lungs (pulmo). These veins lay along the ventral surface of the corresponding lobar bronchi except for the accessory pulmonary lobar vein which is dorsal to the accessory lobar bronchus (Figure 6 - 1). The right cranial pulmonary lobar vein (venae

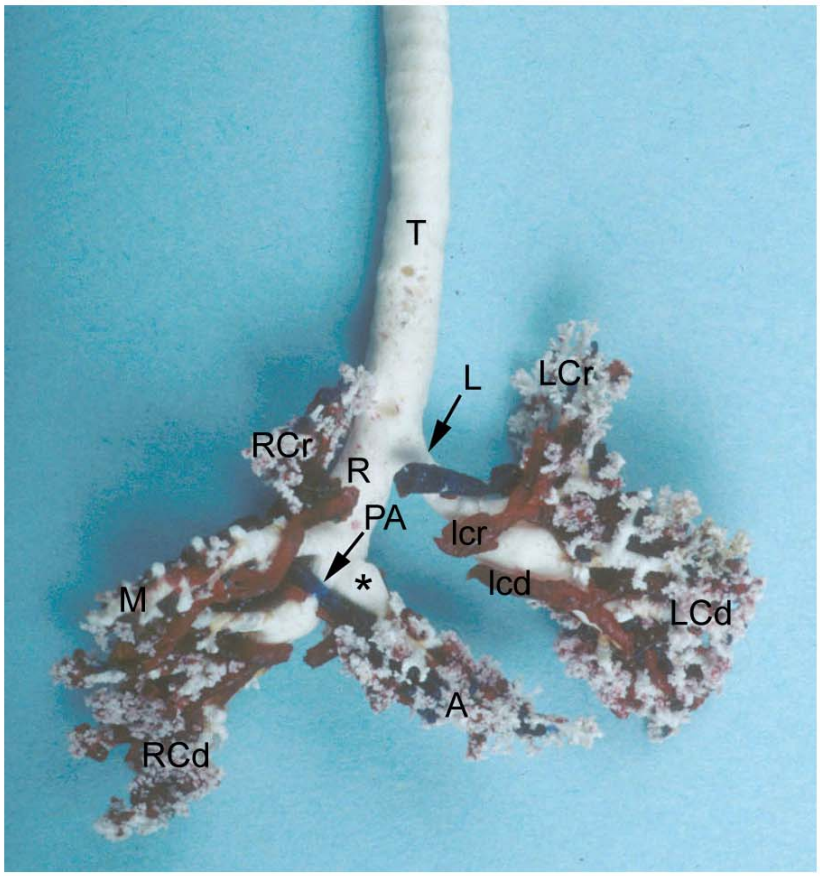

Figure 6 - 1. Tracheobronchial vascular cast- ventral view. Trachea (T), right principal bronchus (R), left principal bronchus (L), accessory lobar bronchus (*), left cranial lobe (LCr), left caudal lobe (LCd), right cranial lobe (RCr), middle lobe (M), right caudal lobe (RCd), accessory lobe (A), accessory pulmonary lobar artery (PA), left cranial pulmonary lobar vein (lcr), left caudal pulmonary lobar vein (lcd).

pulmonalis lobi cranialis dextra) and the right middle pulmonary lobar vein (venae pulmonalis lobi medii) join to form a right pulmonary vein. The left cranial pulmonary lobar vein (venae pulmonalis lobi cranialis sinistri) is formed by a branch from the cranial part of the left cranial lobe and a branch from the caudal part of the left cranial lobe (Figure 6 - 2). The left cranial and caudal pulmonary lobar veins (venae pulmonalis lobi caudalis sinistri) join to form a left pulmonary vein. The right caudal pulmonary lobar vein (venae pulmonalis lobi caudalis dextra) and the accessory pulmonary lobar vein (ramus lobi accessorii) may join the left pulmonary vein or the left caudal pulmonary vein prior to the formation of the left pulmonary vein. The right and left pulmonary veins join to form a pulmonary venous trunk that opens into the left atrium (atrium sinistrum) of the heart.

On the right side of the mediastinum, the bronchoesophageal artery (arteria broncho-esophagea) originates from the right, fourth dorsal intercostal artery (arteria intercostales dorsales) (Figure 6 - 3). The bronchoesophageal artery courses ventrally through the mediastinum to the right side of the esophagus where it divides into a bronchial branch (ramus bronchalis) and an esophageal branch (ramus esophageus) (Figure 6 - 4). The bronchial branch courses ventrally through the middle mediastinal pleura (mediastinalis pleura) and divides into branches to the right and left lungs. The right branch courses through the mediastinum, medial to the right vagus nerve (nervus vagus) to lay along the dorsal surface of the right principal bronchus. The left branch continues through the mediastinum to the left side. Here it anastomoses with an aortic mediastinal branch (rami mediastinales) before coursing along the dorsal surface of the left principal bronchus

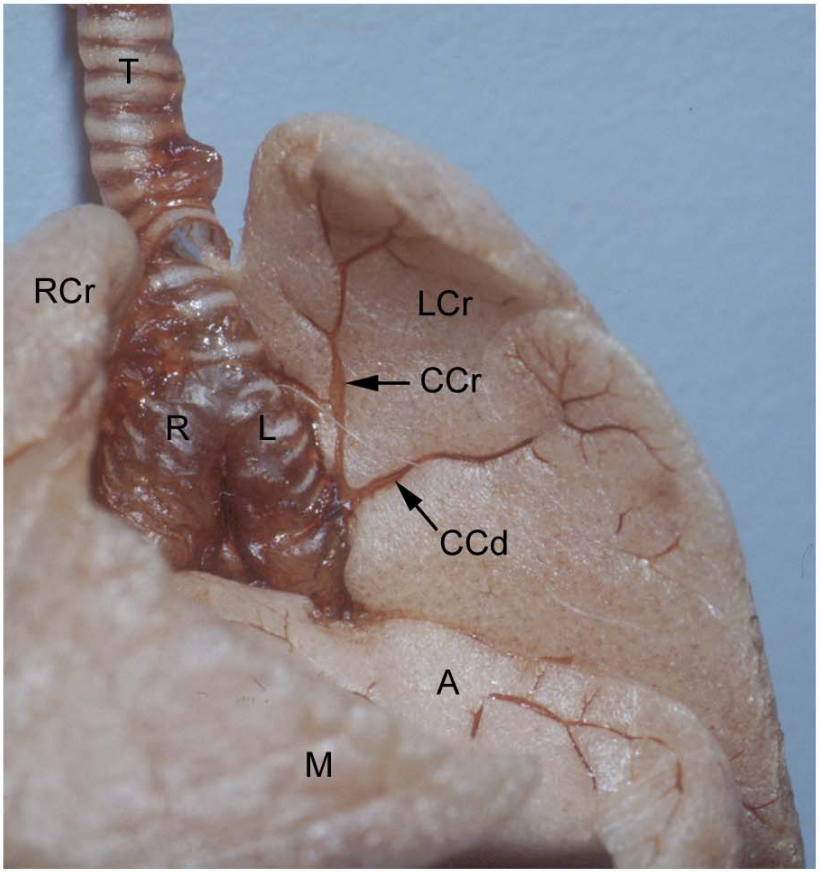

Figure 6 - 2. Ventral view of cranial portion of lungs. Left cranial lung lobe (LCr), right cranial lung lobe (RCr), middle lobe of right lung (M), accessory lobe (A), trachea (T), right principal bronchus (R), left principal bronchus (L), venous return from cranial part of the left cranial lung lobe (CCr), venous return from caudal part of the left cranial lung lobe (CCd).

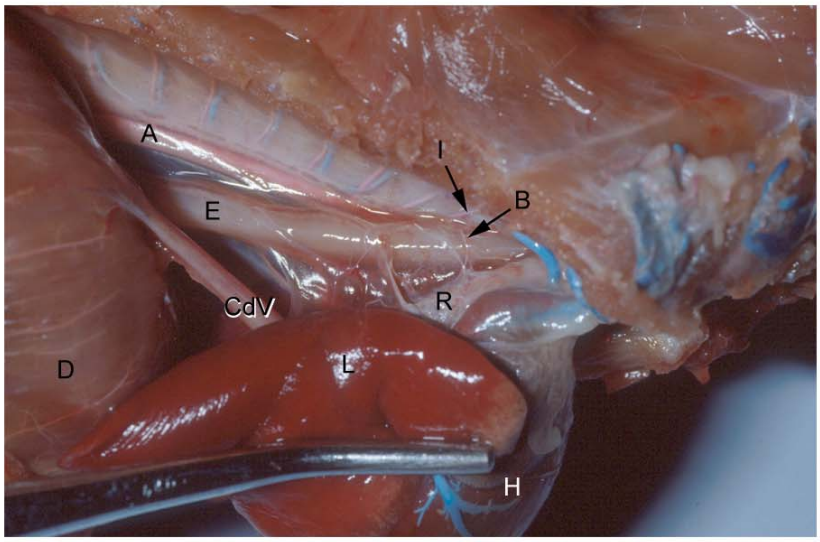

Figure 6 - 3. Right view of thoracic cavity (right lung (L) reflected ventrally). Aorta (A), esophagus (E), right principal bronchus (R), fourth dorsal intercostal artery (I), bronchoesophageal artery (B), caudal vena cava (CdV), diaphragm (D), heart (H).

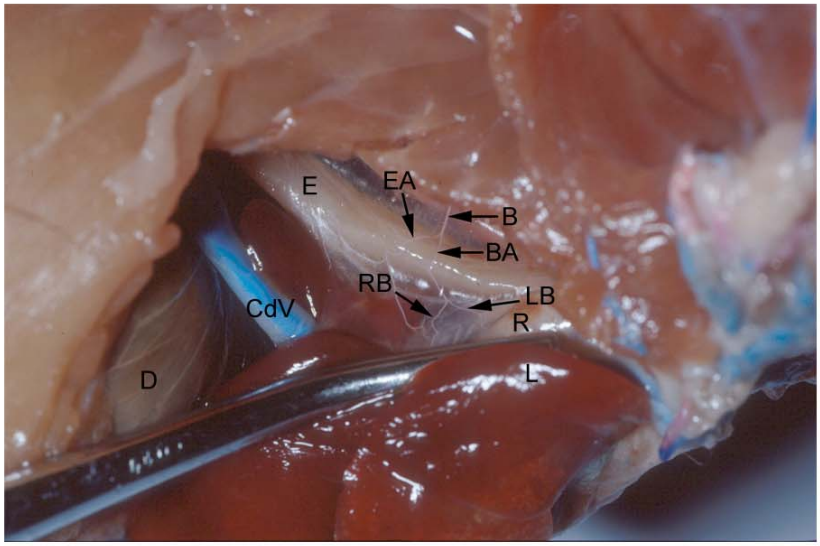

Figure 6 - 4. Right view of thoracic cavity (right lung (L) reflected). Right principal bronchus (R), esophagus (E), bronchoesophageal artery (B), esophageal artery (EA), bronchial artery (BA), right bronchial branch (RB), left bronchial branch (LB), caudal vena cava (CdV), diaphragm (D).

(Figure 6 - 5). The mediastinal branch originates from the descending aorta (aorta descendens) at the second intercostal space (spatium intercostale). After the anastomosis of the left branch and the mediastinal branch, the mediastinal branch continues in a caudal direction. It parallels the left vagus nerve and supplies the ventral surface of the esophagus for approximately 3.0 mm before attaining a more dorsal position.

Caudal to the division of the bronchoesophageal artery into a bronchial branch and an esophageal branch, the esopahgeal branch continues in a caudal direction along the dorsal surface of the esophagus with the right vagus nerve. Approximately 5.0 mm from the diaphragm this esophageal branch divides into the dorsal and ventral esophageal branches (ramus esophageus). Approximately 2.0 mm from the diaphragm the mediastinal branch anastomoses with the dorsal esophageal branch. The dorsal esophageal artery parallels the dorsal vagal trunk (truncus vagalis dorsalis) which is formed by the right vagus nerve and the dorsal branch of the left vagus nerve. The ventral esophageal artery parallels the ventral vagal trunk (truncus vagalis ventralis) which is formed by the ventral branch of the left vagus nerve only.

Dorsal to the bifurcation of the bronchoesophageal artery, a small branch is dispatched and courses with one of the vagal branches through the pulmonary ligament (ligamentum pulmonale) to the hilus of the right lung (hilus pulmonis). Also originating from the right third dorsal intercostal artery is a branch that supplies the esophagus and the right side of the trachea cranial to its bifurcation (bifurcation tracheae).

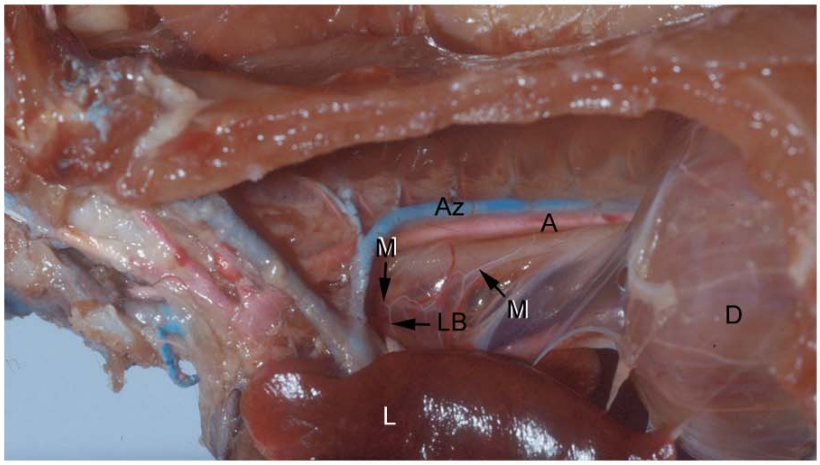

Figure 6 - 5. Left view of thoracic cavity (left lung (L) reflected ventrally). Azygous vein (Az), aorta (A), mediastinal branch (M), left bronchial branch (LB), diaphragm (D).

Lymph Nodes of the Lower Respiratory Tract:

Two cranial deep cervical lymph nodes are associated with the cervical part of the trachea. They are located on the left and right side of the laryngotracheal junction lateral to the longus capitis muscle. They measure 1.51 ± 0.14 mm in length. Cranial mediastinal lymph nodes (lymphonodi mediastinales craniales) and tracheobronchial lymph nodes (lymphonodi tracheobronchales) are associated with the thoracic part of the lower respiratory tract. Two cranial mediastinal lymph nodes are located on the right and left ventrolateral surfaces of the trachea, approximately 3.0 mm cranial to the base of the heart (basis cordis) (Figure 6 - 6). These lymph nodes are oval shaped and measure 1.33 ± 0.58 mm in length. Three tracheobronchial lymph nodes are located at the tracheal bifurcation (Figure 6 - 7). The right and left tracheobronchial lymph nodes [lymphonodi tracheobronchales bifurcationis (dexter et sinister)] measure 2.31 ± 0.32 mm in length, are oval shaped and lay on the lateral side of the right and left principal bronchi. The middle tracheobronchial lymph node (lymphonodi tracheobronchales bifurcationis medii) is the largest lymph node associated with the lower respiratory system of the gray short-tailed opossum. It measures 3.62 ± 0.3 mm in length and lies in the angle of the tracheal bifurcation.

Innervation of the Trachea, Lungs and Diaphragm:

The lower respiratory tract of the gray short-tailed opossum receives innervation from the sympathetic trunks and the vagus nerves. The right and left sympathetic trunks (truncus sympathicus) lay behind the costal pleura (costalis pleura) lateral to the thoracic

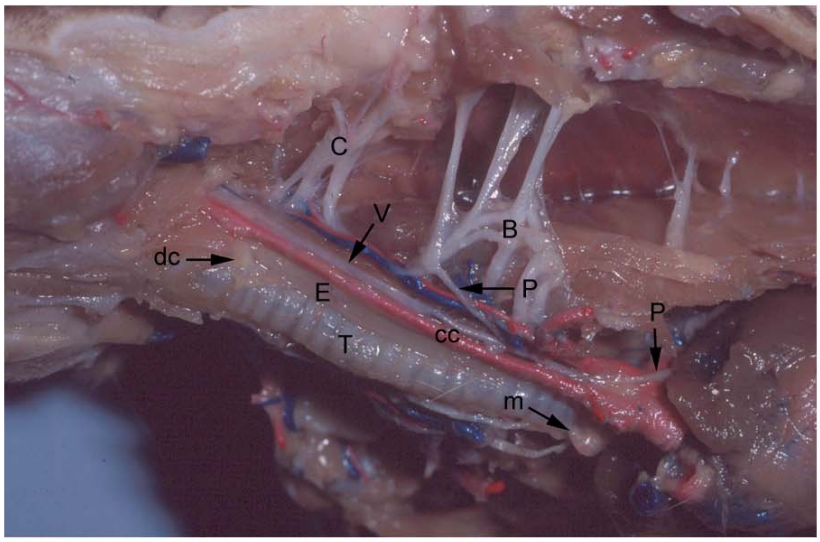

Figure 6 - 6. Left ventral view of cervical region. Trachea (T), left phrenic nerve (P), cervical plexus (C), brachial plexus (B), left cranial mediastinal lymph node (m), cranial deep cervical lymph node (dc), common carotid artery (cc), vagosympathetic trunk (V), esophagus (E).

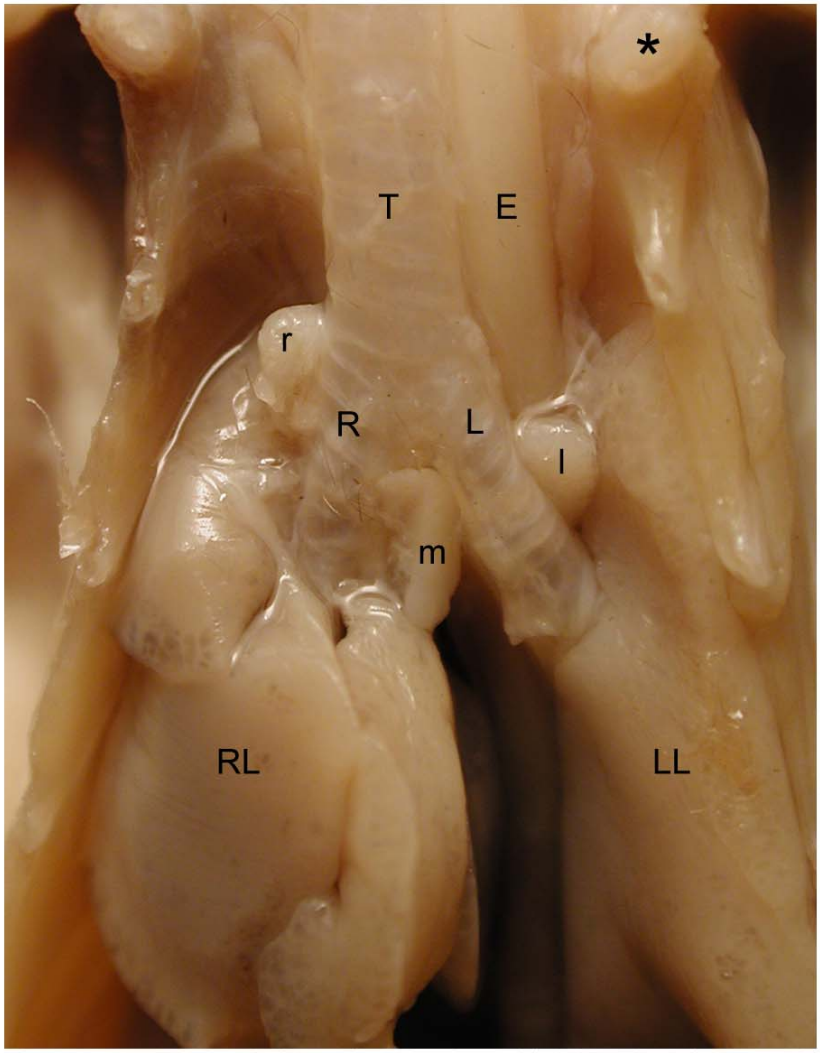

Figure 6 - 7. Ventral view of tracheobronchial lymph nodes. Trachea (T), right principal bronchus (R), left principal bronchus (L), esophagus (E), right tracheobronchial lymph node (r), left tracheobronchial lymph node (l), middle tracheobronchial lymph node (m), right lung (RL), left lung (LL), transected left first rib (*).

vertebral bodies (corpus vertebrae). They cross the lateral surfaces of the dorsal intercostal vessels to reach their ipsilateral cervicothoracic ganglion (ganglion cervicothoracicum). The right and left cervicothoracic ganglia lay in deep grooves bordered medially by the ipsilateral longus colli muscle (musculi longus colli) and laterally by ribs (costae) one and two with their associated intercostal muscles (musculi intercostales). The sympathetic trunk joins the vagus nerve by the cranial and caudal loops of the ansa subclavia which emerge from the ventral margin of the cervicothoracic ganglion as a common trunk. The caudal loop of the ansa courses ventrally to join the vagus nerve caudal to the subclavian artery (arteria subclavia) thus forming the vagosympathetic trunk. The cranial loop courses in a cranial direction, dorsal to the internal jugular vein (venae jugularis interna), and parallels the vagosympathetic trunk (truncus vagosympathicus) for approximately 4.0 mm before joining it. Cardiac nerves also emerge from the cervicothoracic ganglion and parallel the caudal loop of the ansa subclavia for a short distance. These cardiac nerves provide sympathetic innervation to the heart. Originating from the thoracic part of each sympathetic trunk are two to three thoracic splanchnic nerves. These nerves course ventrally through the mediastinal pleura and pulmonary ligament to the hilus of each lung.

As the right vagus nerve crosses the ventrolateral surface of the subclavian artery, the right recurrent laryngeal nerve (nervus laryngeus recurrens) leaves the vagus nerve, curves ventromedially around the right subclavian artery and continues cranially along the right ventral aspect of the trachea. At the thoracic inlet (apertura thoracis cranialis), the right recurrent laryngeal nerve moves to a dorsal position on the cervical trachea.

Near the aortic arch (arcus aortae), the left recurrent laryngeal nerve leaves the left vagus nerve and curves medially then cranially around the arch to continue along the left ventral aspect of the trachea. At the thoracic inlet, it attains a position dorsal to the trachea and continues in a cranial direction.

Caudal to the principal bronchus of the right and left lungs, three to six vagal branches leave each vagus nerve and course to the hilus of the lung through the pulmonary ligament. Caudal to the hilus of the right lung, the right vagus nerve continues caudally along the right dorsal surface of the esophagus. Caudal to the hilus of the left lung and approximately 6.0 mm from the diaphragm, the left vagus nerve divides into dorsal and ventral branches which continue caudally along the left dorsal and ventral surfaces of the esophagus. The right vagus nerve and the dorsal branch of the left vagus nerve join 1.0 cm cranial to the diaphragm and parallel the dorsal esophageal artery as the dorsal vagal trunk. Only the ventral branch of the left vagus nerve continues caudally as the ventral vagal trunk along the ventral surface of the esophagus paralleling the ventral esophageal artery.

Coursing medial to the right and left lungs are the respective phrenic nerves (nervus phrenicus). The right and left phrenic nerves are formed by components of the ventral branches (rami ventrales) of cervical nerves (nervi cervicales) 3, 4, 5, and 6 (Figure 6 - 6). The contributions of cervical nerves 3 and 4 to the phrenic nerve pass through the cervical plexus. The contribution of cervical nerves 5 and 6 to the phrenic nerve pass through the brachial plexus (plexus brachialis). In the cervical region, the right and left phrenic nerves are located immediately lateral to the ipsilateral internal jugular vein. As

they course caudally toward the thoracic inlet (apertura thoracis cranialis), they are medial to the ipsilateral brachial plexus. After passing through the thoracic inlet, the right phrenic nerve passes ventrolateral to the right subclavian artery and lateral to the right cranial vena cava (vena cava cranialis). As the nerve continues caudally, it inclines over the dorsal aspect of the right atrium (atrium dextrum) to continue along the lateral margin of the caudal vena cava (vena cava caudalis) on its course to the right costal part (pars costalis) of the diaphragm. The right phrenic nerve is anchored by the mediastinal pleura to the parietal pericardium of the heart and the caudal vena cava. The left phrenic nerve follows a course similar to that of the right phrenic nerve in the ventral cervical region. After passing through the thoracic inlet, the left phrenic nerve passes ventral to the left subclavian artery, dorsal to the left cranial vena cava and along the left ventral margin of the heart where it is anchored to the parietal pericardium by the mediastinal pleura. At the apex of the heart (apex cordis), the left phrenic nerve travels caudodorsally in the caudal mediastinal pleura en route to the left costal part of the diaphragm (Figure 6 - 8).

The arterial and nervous distribution, as well as lymph node location and number, described above were seen in all animals studied.

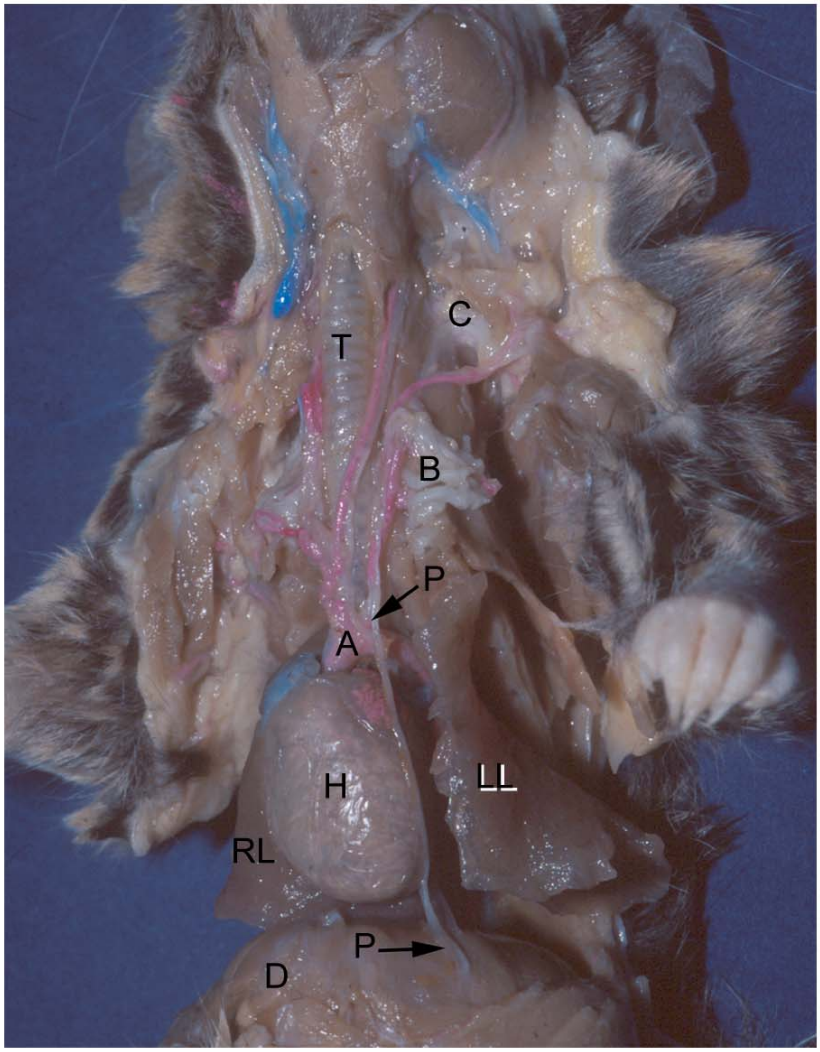

Figure 6 - 8. Ventral view of cervical and thoracic region. Trachea (T), heart (H), left lung (LL), right lung (RL), left phrenic nerve (P), aortic arch (A), left cervical plexus (C), left brachial plexus (B), diaphragm (D).

DISCUSSION:

The branching pattern of the pulmonary lobar arteries as well as their location as related to the bronchi in the gray short-tailed opossum is similar to that of domestic mammals (Nickel *et al*., 1981; Evans, 1993). Descriptions of the distribution of pulmonary lobar arteries in other marsupials could not be located for further comparison.

Right and left pulmonary veins joining to form a common pulmonary venous trunk as occurs in the gray short-tailed opossum has also been reported in the North American opossum (McClure, 1903; Wade and Neely, 1949), the brush-tail opossum (*Trichosurus vulpecula)* (Dowd, 1969) and the native cat (*Dasyurus viverrinus)* (Hill, 1955). The common pulmonary vein seems to be a distinct characteristic of marsupials whereas domestic animals exhibit a pattern characterized by multiple pulmonary veins opening directly into the left atrium.

The bronchial artery of the gray short-tailed opossum is small and its course is difficult to follow macroscopically beyond the hilus of the lung. Earlier reports on the bronchial artery in mammals state that the distribution will vary depending on the thickness of the pleura, the presence of interlobular septa and the presence of bronchial - pulmonary artery anastomoses (McLaughlin, 1983).

The lymph nodes draining the lower respiratory tract of the gray short-tailed opossum include the cranial deep cervical lymph nodes, cranial mediastinal lymph nodes and tracheobronchial lymph nodes. An earlier report on the lymphatic system of two species of South American opossums, *Didelphys azarae* and *Didelphys marsupislis*, describe

deep cervical lymph nodes, anterior mediastinal lymph nodes, posterior cranial mediastinal lymph nodes, a posterior middle mediastinal lymph node and bronchial lymph nodes (Azzali and Didio, 1965). In the gray short-tailed opossum and *Didelphys* (Azzali and Didio, 1965), the cranial deep cervical lymph nodes are located immediately lateral to the laryngotracheal junction and the longus capitis muscles. Azzali and Didio (1965) describe two sets of mediastinal lymph nodes as right and left anterior mediastinal lymph nodes and right and left posterior cranial mediastinal lymph nodes. The anterior mediastinal lymph nodes were located ventral to the subclavian artery, medial to the brachiocephalic vein and sometimes found buried in the perithymic fat. These lymph nodes were not observed in the gray short-tailed opossum. The posterior cranial mediastinal lymph nodes were described as lying ventral to the longus colli muscle and medial to the first intercostal space. These lymph nodes are similar in location to the cranial mediastinal lymph nodes of the gray short-tailed opossum. Azzali and Didio (1965) describe a single posterior middle mediastinal lymph node located near the arch of the left azygous vein. Middle mediastinal lymph nodes were not observed in the gray short-tailed opossum. In the gray short-tailed opossum and the North American opossum, the tracheobronchial lymph nodes are located at the tracheal bifurcation and on each side of the right and left principal bronchi. The bronchial lymph nodes of *Didelphys* as described by Azzali and Didio (1965) seem to be similar to the tracheobronchial lymph nodes of the gray short-tailed opossum. One bronchial lymph node of *Didelphys* is located cranial to the tracheal bifurcation and the second is located just caudal to the

tracheal bifurcation. The South American opossums evidently possess one fewer tracheobronchial lymph node than the gray short-tailed opossum.

The pattern of innervation to the lung of the gray short-tailed opossum is not comparativley different from that of domestic animals.

The phrenic nerves of the gray short-tailed opossum are formed by components of ventral branches of cervical nerves as is seen in domestic animals (Nickel *et al*., 1981; Evans, 1993).

The gray short-tailed opossum appears to have a respiratory system less closely resembling that of other opossums and marsupials previously described. Further studies would need to be undertaken on these other marsupials to definitively determine this assumption.

CHAPTER VII

ANATOMY OF STRUCTURES ASSOCIATED WITH THE LOWER RESPIRATORY TRACT OF THE NORTH AMERICAN OPOSSUM (*Didelphis virginiana*)

ABSTRACT:

This study documents the macroscopic anatomy of the associated structures of the lower respiratory tract of the North American opossum (*Didelphis virginiana*). Cranial deep cervical, cranial mediastinal and tracheobronchial lymph nodes drain the lower respiratory tract. Vascularization of the lungs is via the bronchial artery a branch of the bronchoesophageal artery. The bronchial artery divides into right and left bronchial arteries which follow the branches of the bronchial tree. The pulmonary arteries divide into pulmonary lobar arteries which follow the bronchial division. Pulmonary lobar veins from each lobe of the right and left lungs join to form three pulmonary veins (right, left and middle). The three pulmonary veins join to form a common pulmonary venous trunk that opens into the left atrium of the heart. Sympathetic innervation to the lungs comes from the ipsilateral sympathetic trunks through the mediastinal pleura and pulmonary ligaments as thoracic splanchnic nerves. Parasympathetic innervation to the lungs is via branches from the ipsilateral vagus nerves. The right and left phrenic nerves are formed by components of ventral branches of cervical nerves 2 - 6 which pass through the cervical (C_2-C_4) and brachial (C_5-C_6) plexuses.

INTRODUCTION:

For twenty-five years, the North American opossum has been used in biomedical research in the United States. The extensive use of this marsupial in research has yielded numerous papers in the area of embryogenesis (Klima, 1987; Renfree, 1990; Szalay, 1994) and yet there have been relatively few anatomical descriptions of macroscopic anatomy. Two sources provide a detailed description on the origin and development of the lymphatic system of the North American opossum (Zimmerman, 1940; Kampmeier, 1969). McClure (1903) and Wade and Neely (1949) each briefly describe the pulmonary vasculature while Bernard's (1996) work provides a brief description of the bronchial artery. The goal of the present study is to provide a description of the structures associated with the respiratory system of the North American opossum.

MATERIALS AND METHODS:

Fourteen (7 females and 7 males) North American opossums (*Didelphis virginiana*) were used to study structures associated with the lower respiratory tract. Three of these opossums were used to produce tracheobronchial vascular casts and one was used for a whole body arterial injection. The tracheobronchial vascular casts were produced by injection of latex into the pulmonary vasculature followed by injection of silicone into the airways (Henry, 1992a and 1992b). Prior to arterial injection, the opossum was embalmed with 10% buffered formalin. Twenty-four hours after embalming, latex was injected into the common carotid artery to aid visualization and dissection of the lower respiratory tract vasculature.

RESULTS:

Pulmonary Vasculature and Bronchoesophageal Artery:

The pulmonary trunk (truncus pulmonalis) bifurcates into right and left pulmonary arteries (arteria pulmonalis dextra et sinistra). The right and left pulmonary arteries cross the ventral surface of their respective principal bronchi (bronchus principalis) and curve laterally then dorsally to attain a position dorsal to each bronchus. As the right and left principal bronchi (bronchus principalis dexter et sinister) divide into lobar bronchi (bronchi lobares), the right and left pulmonary arteries divide into branches that follow the bronchial division. The right pulmonary artery divides into a cranial lobar branch (ramus lobi cranialis), a middle lobar branch (ramus lobi medii), a caudal lobar branch (ramus lobi caudalis) and an accessory lobar branch (ramus lobi accessorii). The left pulmonary artery divides unevenly into three branches. Two smaller branches arise from the left pulmonary artery to supply the cranial and caudal parts of the cranial lobe. The large, third branch of the left pulmonary artery enters the caudal lobe as the caudal lobar branch and sends branches along the caudal lobar bronchial division. In general, the lobar arteries course along the dorsal surface of the lobar bronchi with the exception of the accessory lobar artery. This artery passes between the middle and caudal lobar bronchi of the right lung (pulmo dexter) to course along the ventral surface of the accessory lobar bronchus.

The right, middle and left pulmonary veins, which return blood from the lungs to the left atrium (atrium sinistrum) of the heart (cordis), are formed by the pulmonary lobar

veins (Figure 7 - 1). The pulmonary lobar veins lay along the ventral surface of the corresponding lobar bronchi except for the accessory pulmonary lobar vein which is dorsal to the accessory lobar bronchus. The right pulmonary vein is formed by the right cranial pulmonary lobar vein (venae pulmonalis lobi cranialis dextra) and the right middle pulmonary lobar vein (venae pulmonalis lobi medii). In addition, an extra vein from the cranial part of the right caudal lobe may contribute to the right pulmonary vein. The right caudal pulmonary lobar vein (venae pulmonalis lobi caudalis dextra) and the accessory pulmonary lobar vein (ramus lobi accessorii) join to form a middle pulmonary vein. The left pulmonary vein is formed by a branch from the cranial part of the cranial lobe and a branch from the caudal part of the cranial lobe which join the left caudal pulmonary lobar vein (venae pulmonalis lobi caudalis sinistri) (Figure 7 - 1). The right, left and middle pulmonary veins join to form a common pulmonary venous trunk that opens into the left atrium of the heart.

On the right side of the mediastinum, the bronchoesophageal artery (arteria broncho-esophagea) originates from the right, third dorsal intercostal artery (arteria intercostales dorsales) (Figure 7 - 2). The bronchoesophageal artery courses ventrally through the mediastinum across the right side of the esophagus and divides into a bronchial artery (ramus bronchalis) and a common trunk that divides into the esophageal artery (ramus esophageus) and an artery that supplies the right side of the trachea, right vagus nerve (nervus vagus) and right tracheobronchial lymph node (lymphonodi tracheobronchales dexter) (Figure 7 - 2). Before the bronchial artery divides into right and left bronchial arteries, a common branch is given off which passes through the hilus of the right lung

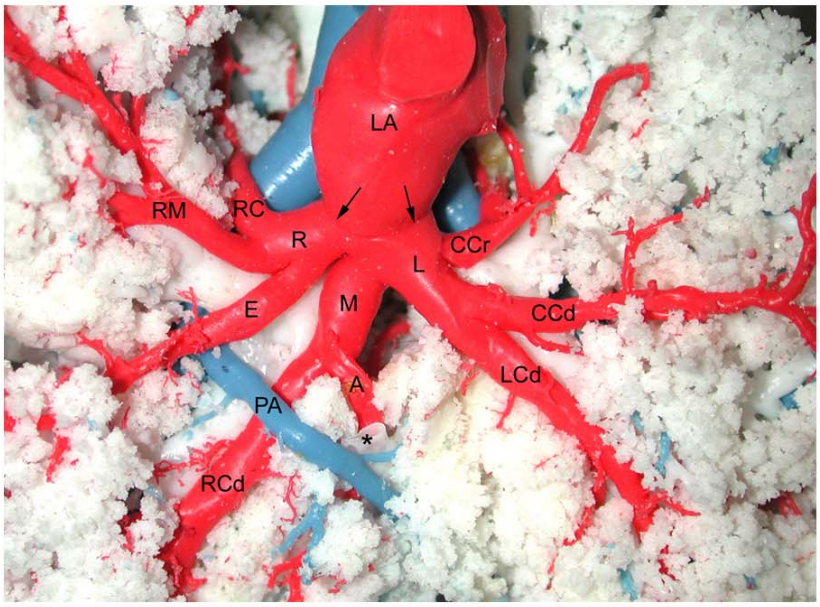

Figure 7 - 1. Ventral view of tracheobronchial vascular cast. Right pulmonary vein (R), middle pulmonary vein (M), left pulmonary vein (L), right cranial pulmonary lobar vein (RC), right middle pulmonary lobar vein (RM), extra v in from the caudal lobe contributing to the right pulmonary vein (E), right caudal pulmonary lobar vein (RCd), accessory pulmonary lobar vein (A), venous return from the cranial part of the left cranial lobe (CCr), venous return from the caudal part of the left cranial lobe (CCd), left caudal pulmonary lobar vein (LCd), left atrium (LA), junction of common pulmonary trunk with left atrium (arrows), accessory pulmonary lobar artery (PA), transected accessory lobar bronchus (*).

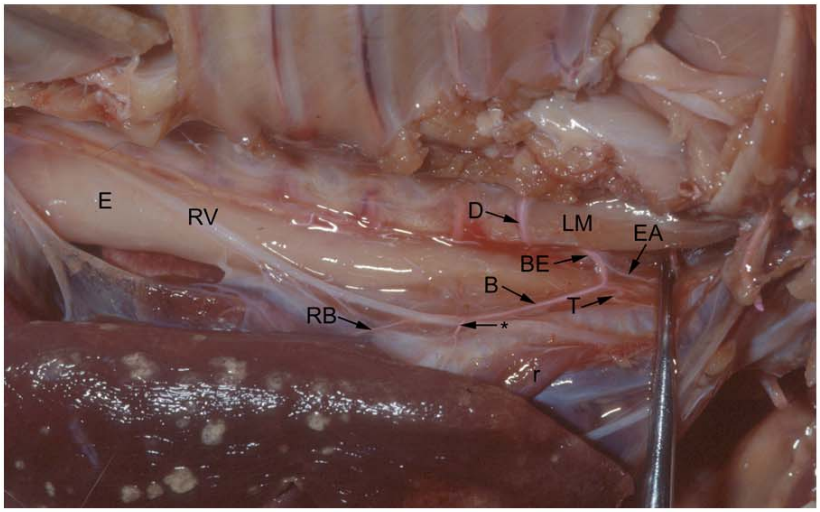

Figure 7 - 2. Right lateral view of dorsal mediastinal structures (ribs reflected dorsally). Bronchoesophageal artery (BE), third dorsal intercostal artery (D), esophageal artery (EA), tracheal branches (T), bronchial artery (B), common branch to right cranial and middle lobar bronchi (*), right bronchial artery (RB), right vagus nerve (RV), esophagus (E), right tracheobronchial lymph node (r), longus colli muscle (LM).

(hilus pulmonis) and divides to follow the cranial and middle lobar bronchi and their branches (Figure 7 - 2). After this, the bronchial artery continues caudoventrally through the middle mediastinal pleura (mediastinalis pleura) and divides caudal to the tracheal bifurcation (bifurcatio tracheae) into branches to the right and left lungs (pulmo sinister) (Figure 7 - 3a). The right bronchial artery courses ventrally toward the hilus of the lung through the mediastinal pleura, medial to the right vagus nerve. The right bronchial artery enters at the hilus caudal to the right principal bronchus, divides, and follows the branches of the caudal lobar bronchus. The left bronchial artery continues through the mediastinum to the left side of the thoracic cavity (Figures 7 - 3a and 7 - 3b). Caudal to the left principal bronchus it anastomoses with a mediastinal artery (rami mediastinales) and continues ventrally toward the hilus of the left lung. Here the left bronchial artery enters the lung and sends branches to the left bronchial division. The mediastinal artery originates from the caudal surface of the aortic arch (arcus aortae) at the second intercostal space (spatium intercostale). After the anastomosis of the left bronchial artery and the mediastinal artery, a small artery arises from the left bronchial artery just prior to its passage through the hilus of lung. This small artery continues in a caudal direction through the mediastinal pleura and divides into two branches which parallel the right and left vagus nerves (Figure 7 - 3a).

Lymph Nodes of the Lower Respiratory Tract:

Cranial deep cervical lymph nodes (lymphonodi cervicales profundi craniales) are present lateral to the laryngotracheal junction and ventral to the longus capitis muscle

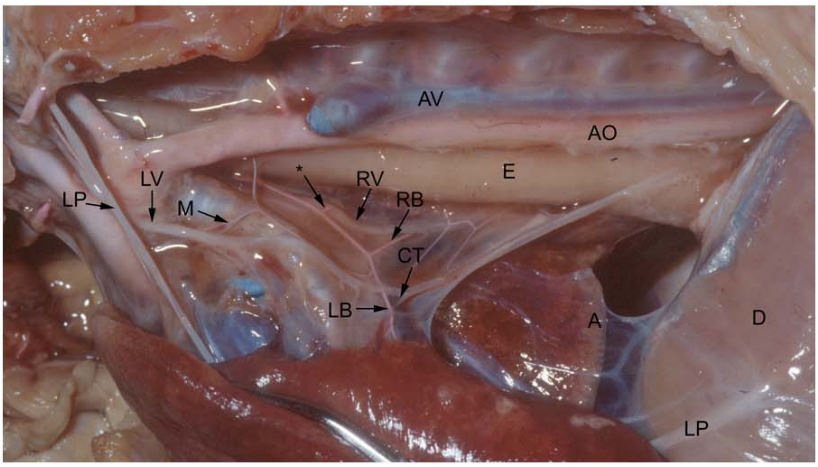

Figure 7 - 3. Dorsal mediastinal structures (lateral view): a. Left lateral view of dorsal mediastinal structures (dorsal aspect of left lung pulled ventrally). Left bronchial artery (LB), right bronchial artery (RB), common branch to right cranial and middle lobar bronchi (*), mediastinal artery (M), common trunk for small artery from left bronchial artery that divides to follow right and left vagus nerves (CT), left vagus nerve (LV), right vagus nerve (RV), accessory lobe of right lung (A), left phrenic nerve (LP), diaphragm (D), esophagus (E), transected azygous vein (AV), aorta (AO).

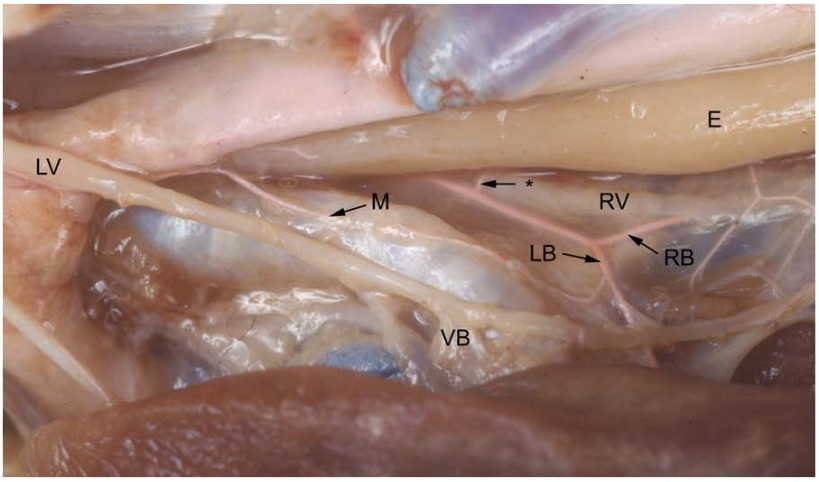

Figure 7 - 3. Continued: b. Close up of lateral view of dorsal mediastinal structures (dorsal aspect of left lung retracted ventrally). Vagal branches (VB) from left vagus (LV) to lung, mediastinal artery (M), common branch to right cranial and middle lobar bronchi (*), left bronchial artery (LB), right bronchial artery (RB), right vagus nerve (RV), esophagus (E).

(Figure 7 - 4). Each lymph node is oval and is 4.31 ± 0.9 mm wide by 11.78 ± 1.3 mm long. Cranial mediastinal lymph nodes (lymphonodi mediastinales craniales) and tracheobronchial lymph nodes (lymphonodi tracheobronchales bifurcationis) are present along the thoracic trachea. The two cranial mediastinal lymph nodes, which lie cranial to the base of the heart (basis cordis) in adipose tissue, are located respectively one each on the right and left ventrolateral surfaces of the trachea at the level of the first to second intercostal spaces (Figure 7 - 5). The cranial mediastinal lymph nodes measure 4.9 ± 0.65 mm in width and 17 ± 0.86 mm in length. The right and left phrenic nerves (nervus phrenicus) course across these lymph nodes. Three tracheobronchial lymph nodes are located in the region of the tracheal bifurcation at the level of the third to fourth intercostal spaces (Figure 7 - 6). The right and left tracheobronchial lymph nodes are 4.84 ± 0.62 mm wide and 9.54 ± 1.69 mm long, oval shaped and lay on the lateral side of the right and left principal bronchi respectively. The middle tracheobronchial lymph node (lymphonodi tracheobronchales bifurcationis medii) is the largest of the three lymph nodes. It is oval shaped and measures 6.3 ± 0.57 mm in width and 14.6 ± 0.54 mm in length. It is located in the angle of the tracheal bifurcation.

Innervation of the Trachea, Lungs and the Diaphragm:

The lower respiratory tract of the North American opossum receives innervation from the sympathetic trunks (truncus sympathicus) and the vagus nerves. The right and left sympathetic trunks lay behind the costal pleura (costalis pleura) lateral to the thoracic vertebral bodies (corpus vertebrae thoracicae). The sympathetic trunks cross the lateral

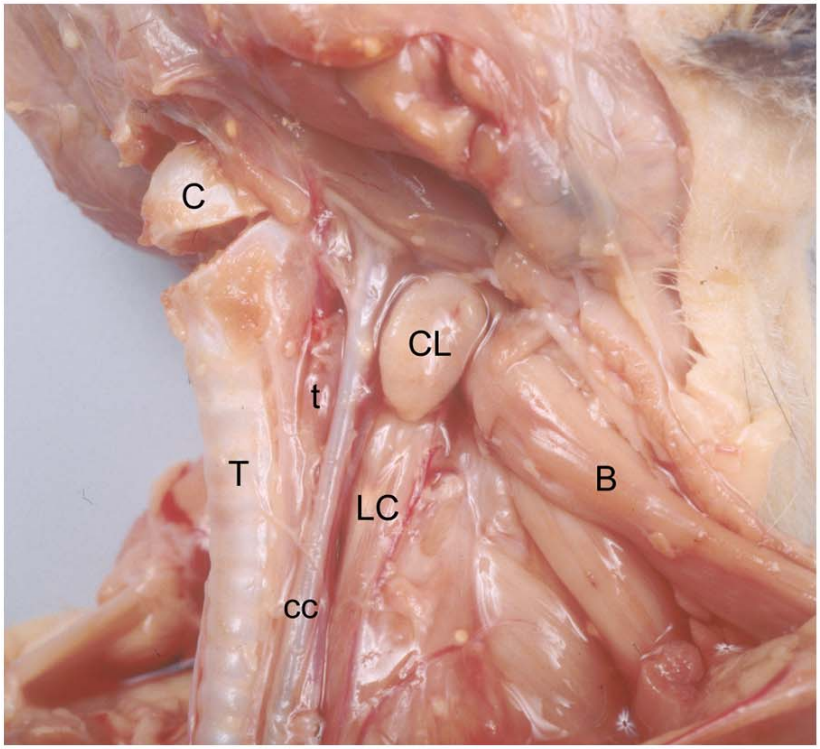

Figure 7 - 4. Left ventrolateral view of cranial cervical region. Cranial deep cervical lymph node (CL), transected laryngeal cartilage (C), common carotid artery (cc), thyroid gland (t), brachiocephalicus muscle reflected (B), longus capitis muscle (LC), cervical trachea (T).

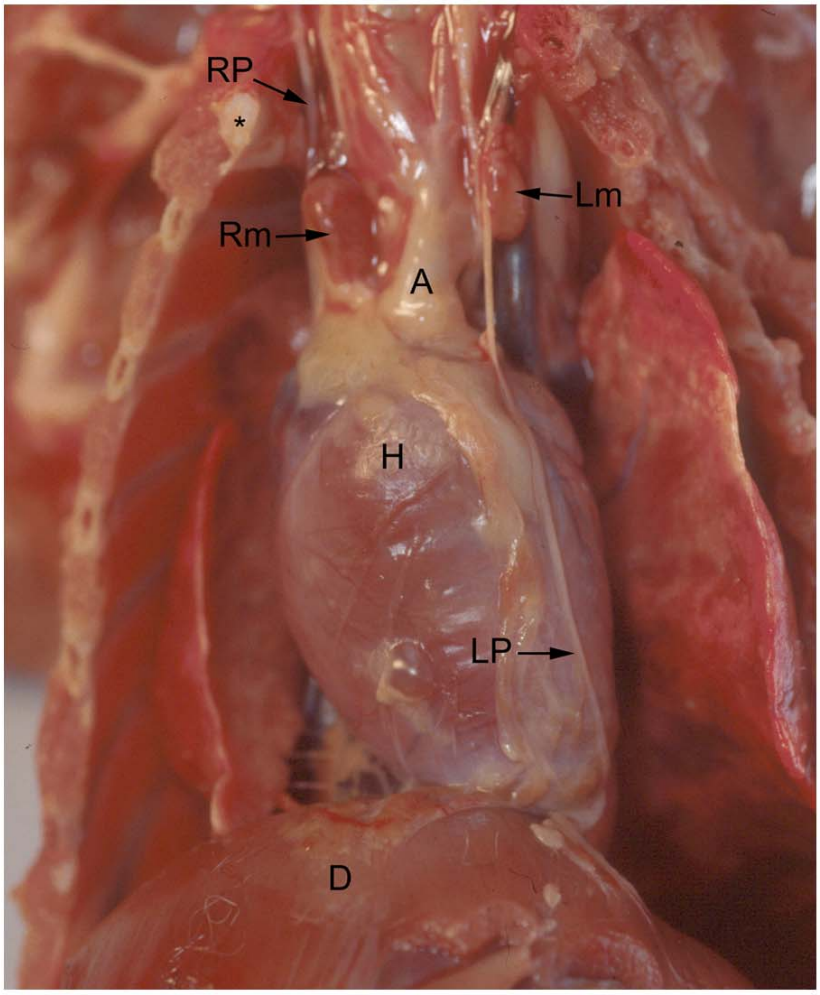

Figure 7 - 5. Ventral view of cranial mediastinal lymph nodes. Right cranial mediastinal lymph node (Rm), left cranial mediastinal lymph node (Lm), ascending aorta (A), first rib (*), heart (H), diaphragm (D), right phrenic nerve (RP), left phrenic nerve (LP).

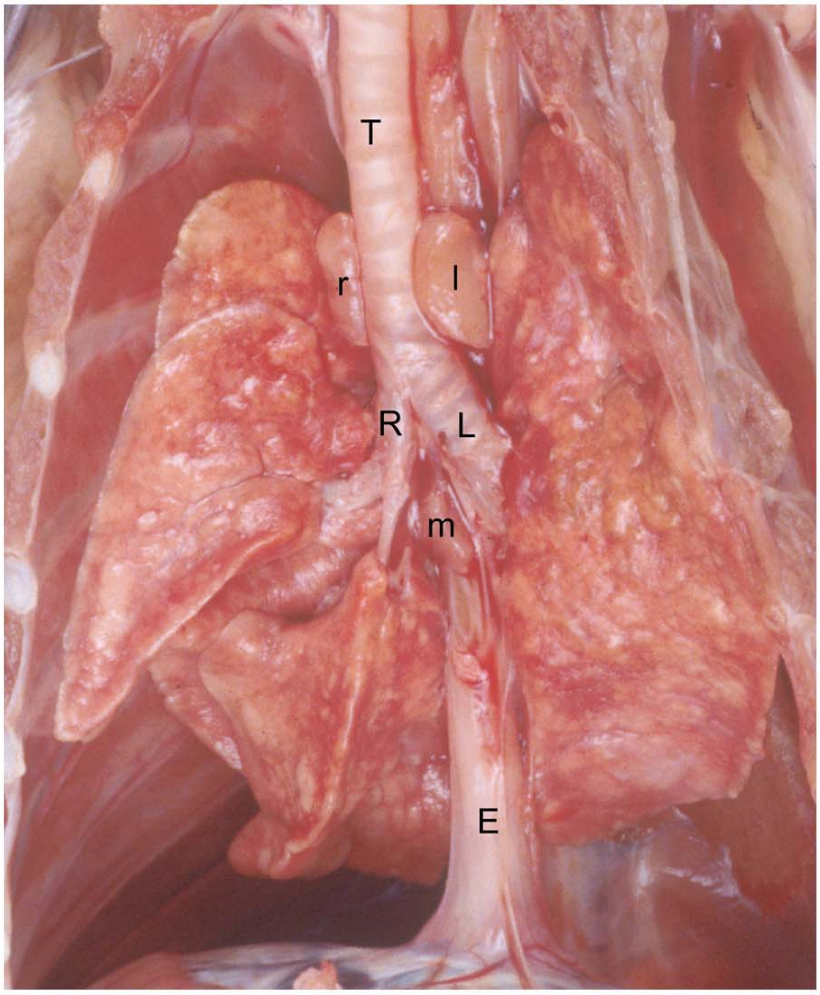

Figure 7 - 6. Tracheobronchial lymph nodes. Right tracheobronchial lymph node (r), middle tracheobronchial lymph node (m), left tracheobronchial lymph node (l), trachea (T), right principal bronchus (R), left prinicipal bronchus (L), esophagus (E).

surfaces of the dorsal intercostals vessels (arteriae intercostalis dorsalis) to reach their ipsilateral cervicothoracic ganglion (ganglion cervicothoracicum). The right and left cervicothoracic ganglia each lay deep within the groove formed medially by the ipsilateral longus colli muscle (musculi longus colli) and laterally by ribs (costae) one and two and their associated intercostals muscles (musculi intercostals). The sympathetic trunk continues from the ventral margin of the cervicothoracic ganglion and bifurcates into cranial and caudal loops of the ansa subclavia. The ansa subclavia joins the vagus nerve to form the vagosympathetic trunk (truncus vagosympathicus). From the ganglia of the sympathetic trunk of each side, thoracic splanchnic nerves (nervus splanchnicus) course ventrally through the mediastinal pleura (mediastinalis pleura). Near the hilus, they deviate laterally into the pulmonary ligaments (ligamentum pulmonale) and enter each lung.

As the right vagus nerve crosses the ventral surface of the subclavian artery (arteria subclavia), the right recurrent laryngeal nerve (nervus laryngeus recurrens) leaves the vagus nerve and curves ventromedially to continue cranially along the right side of the trachea. The left recurrent laryngeal nerve leaves the left vagus nerve near the aortic arch and curves medially then cranially around the aortic arch to continue cranially along the left side of the trachea. After the right and left recurrent laryngeal nerves are dispatched, the ipsilateral vagus nerves continue caudally along the dorsal aspect of the thoracic trachea. Caudal to the principal bronchus of the right and left lungs, three to six vagal branches leave each vagus nerve (Figure 7 - 3b). These vagal branches course through the pulmonary ligament to the hilus of each lung. Caudal to the hilus of the lungs, the

right and left vagus nerves continue caudally along the dorsal surface of the esophagus. Approximately 10.0 mm from the diaphragm the left vagus nerve divides into dorsal and ventral branches which course caudally along the esophagus. The right vagus nerve remains undivided. Approximately 6.0 mm from the diaphragm, the right vagus nerve and the dorsal branch of the left vagus nerve join along the dorsal esophageal surface to form the dorsal vagal trunk (truncus vagalis dorsalis). The ventral branch of the left vagus nerve continues caudally along the ventral esophageal surface as the ventral vagal trunk (truncus vagalis ventralis).

Coursing medial to the right and left lungs are the ipsilateral phrenic nerves. The right and left phrenic nerves are formed by components of the ventral branches (rami ventrales) of cervical nerves (nervi cervicales) 2 through 6 which pass through the cervical and brachial plexuses. The contribution of cervical nerves 2, 3 and 4 to the phrenic nerve pass through the cervical plexus. The contribution of cervical nerves 5 and 6 to the phrenic nerve pass through the brachial plexus. As the phrenic nerves course caudally toward the thoracic inlet (apertura thoracis cranialis), they are located medial to the brachial plexus. After passing through the thoracic inlet, the right phrenic nerve inclines over the dorsal aspect of the right atrium (dextrum atrium) to continue along the right side of the caudal vena cava (vena cava caudalis) on its course to the right costal part (pars costalis) of the diaphragm. The right phrenic nerve is anchored by the mediastinal pleura to the parietal pericardium of the heart and the caudal vena cava. The left phrenic nerve, after passing through the thoracic inlet courses, dorsal to the left cranial vena cava (vena cava cranialis). It continues caudally along the left ventral

margin of the heart where it is anchored by the mediastinal pleura to the parietal pericardium (Figure 7 - 5). At the apex (apex cordis) of the heart, the left phrenic nerve continues caudodorsally in the caudal mediastinal pleura en route to the left costal part of the diaphragm.

The arterial and nervous supply to the lungs as described was observed in all animals. Additionally, lymph node location and numbers were consistent among all animals.

DISCUSSION:

The division of the pulmonary arteries into pulmonary lobar arteries in the North American opossum is similar to that of many domestic mammals as the branching pattern follows that of the bronchi (Nickel *et al*., 1981; Evans, 1993). The location of the pulmonary lobar arteries in relation to the bronchi as well as the branching pattern within each lung lobe in the North American opossum is similar to that of the canine (Evans, 1993).

In the North American opossum, pulmonary lobar veins from both lungs join to form three pulmonary veins. These three veins then unite to form a common pulmonary venous trunk before emptying into the left atrium. Previous descriptions of the pulmonary vasculature of the North American opossum report finding a common pulmonary venous trunk in some specimens (Owen, 1868; McClure, 1903; Wade and Neely, 1949). These articles do not describe the vessels which form the common pulmonary venous trunk. Wade *et al*. (1949) did identify two specimens which had two veins from each lung that joined and formed only two pulmonary veins and in other

specimens four pulmonary veins directly entering the left atrium. Hill (1955) and Dowd (1969) report that the native cat *(Dasyurus viverrinus)* and the brush-tail opossum *(Trichosurus vulpecula)* also have a common pulmonary venous trunk which is formed by a common right and common left pulmonary vein. Pulmonary venous return as described in marsupials involves some degree of common pulmonary vein formation. These common veins then unite to form a common pulmonary venous trunk. The actual pattern varies slightly among species. We did not find any descriptions which matched that which we observed in the North American opossum.

Concerning blood supply to the lung parenchyma of the North American opossum, Bernard *et al*. (1996) state that either a distinct bronchoesophageal or common bronchial artery originates from the thoracic aorta at the fifth intercostal space. We observed only the former description during this study. In either case, the bronchial artery then divides into right and left branches at the tracheal bifurcation. This division of the bronchial artery described by Bernard *et al*. (1996) is similar to that which we observed in the North American opossum as well as that of many mammalian species (Nickel *et al*., 1981; Schaller, 1992; Evans, 1993). The anastomosis of the left bronchial artery with a mediastinal artery before the former enters the lung is also seen in the canine (Auton *et al*., 2000).

The superior cervical lymph nodes identified by Zimmerman (1940) and Kampmeier (1969) are likely the cranial deep cervical lymph nodes we observed in the North American opossum. In both cases these lymph nodes are described as lying along the larynx, medial to the cleido-mastoid, cleido-occipital and sterno-mastoid muscle groups.

The location of the cranial deep cervical lymph nodes in the North American opossum is similar to those of many domestic carnivores (Nickel *et al*., 1981; Evans, 1993).

The location of the cranial mediastinal lymph nodes in the North American opossum is similar to the findings of Zimmerman (1940) and Kampmeier (1969) who refer to these as anterior mediastinal lymph nodes. Kampmeier (1969) and Azzali and Didio (1965) describe posterior cranial mediastinal lymph nodes in North American opossum and large American opossums of South America (*Didelphis marsupialis* and *Didelphis azarae*). These nodes were not observed in North American opossums utilized in this study.

The three tracheobronchial lymph nodes of the North American opossum are positioned one each respectively on the lateral side of the right and left principal bronchi and in the angle of the tracheal bifurcation. This positioning is similar that found in many domestic species (Nickel *et al*., 1981; Schaller, 1992; Evans, 1993). However, in previous reports on the North American opossum (Kampmeier, 1969) and the large American opossums of South America (Azzali and Didio, 1965), only two bronchial lymph nodes were found. One lymph node was cranial to the tracheal bifurcation and one caudal to the bifurcation.

The innervation to the lung of the North American opossum is unremarkable as it is similar to that of many domestic mammals (Nickel *et al*., 1981; Evans, 1993).

CHAPTER VIII

MICROSCOPIC ANATOMY OF THE LOWER RESPIRATORY TRACT OF THE GRAY SHORT-TAILED OPOSSUM (*Monodelphis domestica*)

ABSTRACT:

This portion of the present study describes the microscopic anatomy of the lower respiratory tract of the gray short-tailed opossum (*Monodelphis domestica*). The trachea and right and left principal bronchi are lined with pseudostratified ciliated columnar epithelium. Only a few goblet cells are seen and localized to the trachea. The secondary and tertiary bronchi and the primary and secondary bronchioles are lined by a ciliated simple columnar epithelium. The terminal bronchioles and a portion of the respiratory bronchioles are lined by ciliated simple cuboidal epithelium. The terminal portion of the respiratory bronchioles and the alveolar ducts are lined with simple squamous epithelium. Alveoli are lined by type I and type II pneumocytes. Compound acinar seromucous tracheal glands are present in the tela submucosa. The fibromusculocartilaginous tunic of the trachea consists of c-shaped hyaline cartilge rings and the trachealis muscle. A lamina muscularis mucosae is not present in the extrapulmonary portion of the principal bronchus. However, it appears in the intrapulmonary portion of the principal bronchus and continues into the respiratory bronchioles. The compound acinar seromucous bronchial glands are present in the propria submucosa and tela submucosa of the principal bronchi. The bronchial glands do not extend beyond the principal bronchi. The

musculocartilaginous tunic is present only in the extrapulmonary portion of the principal bronchus. The bronchial cartilages are irregular shaped plates and do not extend past the extrapulmonary portion of the principal bronchus. The visceral pleura is a layer of simple squamous mesothelium covering the outer surface of the lung. Deep to this layer is the tunica subserosa, a layer of loose collagenous connective tissue, which gives off septa into the parenchyma of the lung lobes.

INTRODUCTION:

During the past century, microscopic anatomy of the lower respiratory tract of the rat (Loosli, 1938; Jeffery, 1975, 1983; Spicer *et al.,* 1982; Scheuermann *et al.*, 1988), hamster (Becci *et al.*, 1978; Jeffery, 1983), mouse (Hansell and Moretti, 1969; Greenwood and Holland, 1972; Pack *et al.*, 1981; Jeffery, 1983), rabbit and guinea pig (Loosli, 1938; Jeffery, 1983), canine (Loosli, 1938; Tucker, 1974; Jeffery, 1983), feline (Jeffery, 1983; Al-Tikriti *et al*., 1991), sheep (Alcorn *et al.,* 1981), pig (Clements, 1938; Ham and Baldwin, 1941; Jeffery, 1983), ox (Tucker, 1974) and nonhuman primates (Loosli, 1938; Castleman *et al.*, 1975; Jeffery, 1983; Tyler and Plopper, 1985) has been studied extensively using light and electron microscopy. During the same period, only seven articles were located on the microscopic anatomy of the lower respiratory tract of all marsupials such as the North American opossum (*Didelphis virgianana*) (Bremer, 1904; Sorokin, 1962, 1965; Krause and Leeson, 1973, 1975; Krause *et al.,* 1976), koala (*Phascolarctos cinereus*) and phalanger (*Trichosurus vulpecula*) (Tucker, 1974). These previous descriptions do not provide many details on the histologic features of the lower

respiratory tract of these marsupials. Hence a detailed description documenting the normal histologic features of the lower respiratory tract of a marsupial would benefit future researchers. Therefore, this study will provide a more complete description of the histologic features of the lower respiratory tract of the gray short-tailed opossum (*Monodelphis domestica*).

MATERIALS AND METHODS:

Seven gray short-tailed opossums were used to study the microscopic anatomy of the lower respiratory tract. Each opossum was administered 500 IU of heparin sodium solution (Heparin Sodium Injection 1,000 units per 1.0 ml, Elkins-Sinn Inc. Cherry Hill, NJ 08003) by intraperitoneal (IP) injection to facilitate exsanguination. Eighteen hours later, the opossums were anesthetized with an IP injection of 50 mg of Nembutal (Nembutal Sodium Solution, Pentobarbital Sodium Injection, Abbott Laboratories, North Chicago, IL 60064) per 100.0 grams of body weight. When a stage 3 plane of anesthesia was reached, the left common carotid artery and external jugular vein were catheterized. The opossums were exsanguinated via these catheters. After euthanasia, *in situ* fixation of the trachea and lungs of six of the opossums by intratracheal perfusion was performed with 10% buffered formalin via a canula from a height of 5.0 cm for 5 minutes. Following fixation, the trachea and lungs were removed and placed in 10% buffered formalin for an additional 24-48 hours before sectioning. Tissue samples were taken from all six lung lobes from four animals for study of the lung parenchyma. The four tracheas from these animals were divided into cranial, middle and caudal thirds prior to

sectioning. The right and left lungs were removed from two opossums for serial sectioning of the conducting components of the respiratory system and parenchyma of the lung. All samples were processed for light microscopy using a Tissue TEK VIP 1000 (Floor Model, Mode #4617, Serial #8811895, Ames Division, Miles Laboratories Inc., P.O. Box 70, Elkhart, IN 46515) through a series of dehydration and infiltration. The tissues were dehydrated in a graded series of ethanol (80%, 95%, 95%, 100%, 100%, 100%) followed by two series of xylene under pressure (.35 kg cm^2) and vacuum cycle (50.0 cm Hg) at 40° C for one hour. The samples were infiltrated with paraffin (Paraplast Tissue embedding Medium, Oxford Labware, Division of Sherwood Medical St. Louis, MO 63103) under pressure (0.35 kg cm^2) and vacuum cycle (50.0 cm Hg) at 60° C for one hour (repeated twice). Samples were then embedded in paraffin and positioned in tissue molds to obtain blocks which would yield transverse sections through the trachea and the bronchi when cut. Random sections 5.0 µm in thickness were taken at 75.0 µm intervals from the blocks containing the trachea and bronchi. Serial sections (5.0 µm thick) were made from both lungs. All sections were mounted on glass slides and stained with either hematoxylin and eosin or Acid Orcein Giemsa (Luna, 1968).

The trachea and lungs of the seventh gray short-tailed opossum were fixed *in situ* by perfusion of 2.5% gluteraldehyde (25% Gluteraldehyde EM Grade, Electron Microscopy Sciences, PO Box 251, 321 Morris Road, Ft. Washington, PA 19034) in 0.1M cacodylate buffer (pH = 7.4) (Sodium Cacodylate Trihydrate, Electron Microscopy Sciences, PO Box 251, 321 Morris Road, Ft. Washington, PA 19034) via the catheterized left common

carotid artery. The opossum was placed in the cooler at $5^{o}C$ for 24 hours after which the thoracic cavity was opened and the trachea and lungs removed and placed in new 2.5% gluteraldehyde in 0.1M cacodylate buffer. It was returned to the cooler until samples were taken. Tissue samples were taken from the trachea and lungs, cut into 1.0 mm cubes and washed three times each in distilled water. Samples were post - fixed in a 1:1 mixture of 2% aqueous osmium tetroxide and 3% aqueous potassium ferrocyanide at room temperature for 2 hours or longer until the tissue became dark brown or black in color. The samples were then removed from the osmium ferrocyanide and were again washed three times for ten minutes in distilled water. Following this, the samples were dehydrated for ten minutes each in 50%, 70%, 80% and 90% ethanol followed by two washes in 100% ethanol for 60 minutes each. Samples were then removed from the 100% ethanol and washed two times, fifteen minutes each, in propylene oxide (Polysciences Inc. Warrington, PA 18976). After the final washing, the tissue samples were placed in tissue micromolds (Polysciences Inc. Warrington, PA 18976) and embedded in epon araldite (Russell and Burguet, 1977). Random sections of 1.0 – 2.0 μm were cut, mounted on glass slides and stained with a mixture of 1:1 mixture of methylene blue (Methylene Blue, Sigma Chemical Company, PO Box 14508, St. Louis, MO 63178) and azure blue (Azure II, Sigma Chemical Company, PO Box 14508, St. Louis, MO 63178).

All sections from the seven gray short-tailed opossum were examined by light microscopy using an Olympus CH-2 binocular microscope.

RESULTS:

Trachea:

The cervical and thoracic parts of the trachea (pars cervicalis et thoracica trachea) of the gray short-tailed opossum are lined by a low pseudostratified ciliated columnar epithelium (epithelium pseudostratificatum columnare ciliatum) (Figure 8 - 1). The height of this epithelium from the basal to the apical surface of the columnar cells is 14 µm. It consists of three cell types including columnar cells (epitheliocytus columnaris ciliatus), basal cells (epitheliocytus basalis) and goblet cells (exocrinocytus caliciformis). The columnar cells have a large, round-oval, basophilic staining, vesicular nucleus. The nucleus is centrally located and surrounded by a foamy and sometimes vacuolated cytoplasm. These cells rest on the basement membrane (membrana basalis) of the epithelial layer and their apical surface reaches the lumen of the trachea and is covered with cilia. Basal cells are wedged between adjacent columnar cells. The shape of the basal cells is not distinct because the margins of these cells are not visible with routine H&E staining. These cells are not ciliated and the shape of the nucleus varies from flattened to round or triangular. The nucleus of the basal cell stains more basophilic than those of the columnar cells and often has a prominent nucleolus. Only an occasional goblet cell was found among the epithelial cells. The apical cytoplasm of the goblet cell is foamy and distended so that its apical surface appears domed and bulges into the lumen of the trachea. The base of the goblet cell is narrow and occupied by a flattened, basophilic staining nucleus.

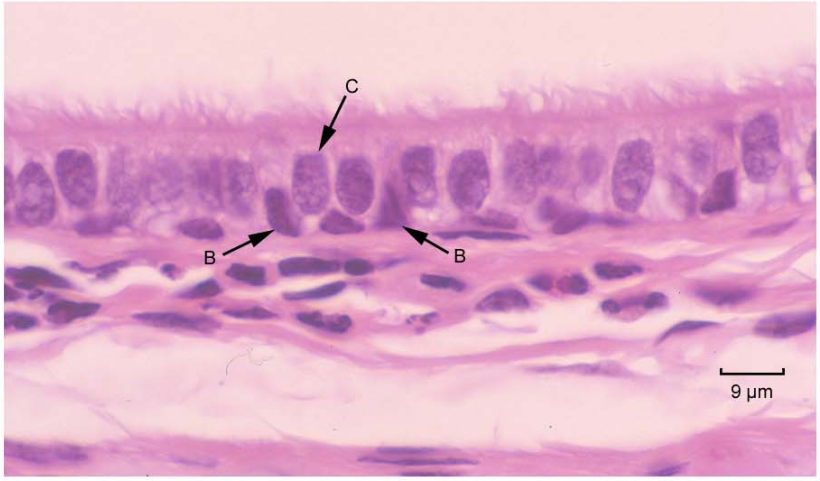

Figure 8 - 1. Cross section through the tunica mucosa of the trachea. Nucleus of ciliated columnar cell (C), nucleus of basal cell (B). (Hematoxylin and Eosin).

Beneath the epithelial layer is the lamina propria mucosae which consists of elastic fibers (fibra elastica) and fibroblasts (fibroblastocytus) (Figure 8 - 2). Deep to the lamina propria mucosae is the loose connective tissue (textus connectivus collagenosus laxus) of the tela submucosa. This layer contains numerous small blood vessels and compound acinar seromucous tracheal glands (glandulae tracheales) (Figures 8 - 2 and 8 - 3). The tracheal glands are located on the luminal side of the cartilage rings (cartilagines tracheales) along the right, left and ventral regions of the trachea. The excretory ducts of the tracheal glands (glandulae tracheales) open onto the luminal surface of the trachea. These ducts are lined by a simple columnar epithelium (Figure 8 - 4). These columnar cells have a centrally placed basophilic nucleus which is surrounded by foamy basophilic cytoplasm. The mucous adenomeres of the tracheal glands consist of pyramidal shaped mucous cells (exocrinocytus granulum mucigeni) with a foamy cytoplasm and a small, round to flattened basal nucleus (Figures 8 - 3 and 8 - 5). The serous cells (exocrinocytus granulum zymogeni) are located both around the periphery of the mucous adenomeres and form crescent shaped serous demilunes (semiluna serosa) or are individually interposed between mucous cells. The serous cells have a granular, eosinophilic staining cytoplasm with a round, basally placed nucleus. The secretory product of the serous demilunes reaches the lumen of the mucous adenomeres by secretory canaliculi (canaliculus intercellularis) that extend between adjacent mucous cells (Figure 8 - 5). Myoepithelial cells (myoepitheliocytus stellatus) are located between the base of the secretory cells of the tracheal gland adenomeres and the underlying basement membrane (Figure 8 - 5). The fibromusculocartilaginous tunic (tunica fibromusculocartilaginea) of

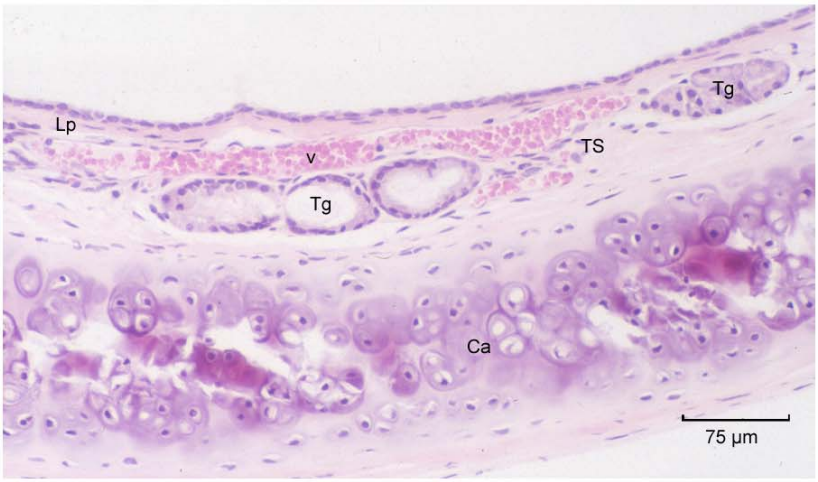

Figure 8 - 2. Cross section of the trachea. Note the decreased epithelial height. Lamina propria mucosae (Lp), tela submucosa (TS) with small blood vessels (v) and tracheal glands (Tg) , hyaline cartilage of the tracheal ring (Ca). (Hematoxylin and Eosin).

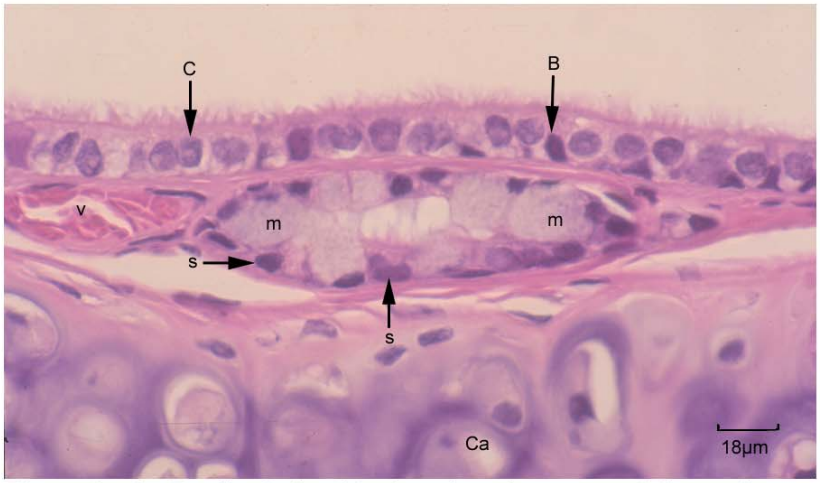

Figure 8 - 3. Tracheal gland in the tela submucosa of the trachea. Nucleus of ciliated columnar cell (C), nucleus of basal cell (B), mucous cell (m), serous cell (s), small blood vessel (v), hyaline cartilage (Ca). (Hematoxylin and Eosin).

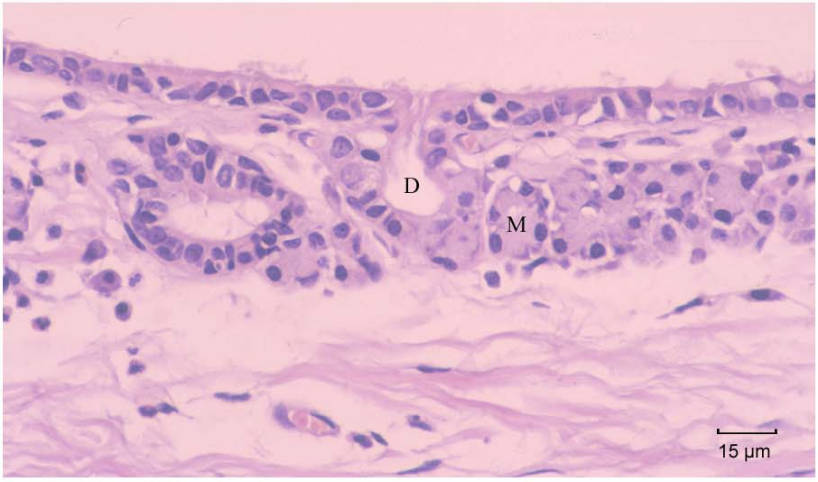

Figure 8 - 4. Tracheal gland duct (D). Mucous adenomere (M) of tracheal gland. (Hematoxylin and Eosin).

Figure 8 - 5. Tracheal gland. Mucous cells (m), serous cells (s) forming a serous demilune, secretory canaliculus (sc), nucleus of myoepithelial cell (my), capillary (c). (Hematoxylin and Eosin).

the trachea consists of a membranous part (paries membranaceus) and a cartilaginous part. The cartilaginous portion of the fibromusculocartilaginous tunic consists of the incomplete rings of c-shaped hyaline cartilage (cartilago hyaline). The hyaline cartilage rings consists of an inner and outer zone (region). The inner zone is basophilic and formed by clusters of chondrocytes (chondrocytus) and their surrounding matrix (matrix cartilaginea). The outer zone is the perichondrium. This region stains a pale eosinophilia and consists of a fibrous and cellular portion. The fibrous portion (stratum fibrosum) is a layer of dense collagenous connective tissue with fibroblasts. The cellular portion (stratum chondrogenicum) is composed of chondroblasts. The membranous portion consists of the transverse bands of smooth muscle cells (myocytus nonstriatus) of the trachealis muscle (musculus trachealis) (Figure 8 - 6). This muscle is on average eight cell layers thick. It attaches to the fibrous part of the perichondrium inside the free ends of each tracheal cartilage. Deep to the trachealis muscle is a layer of dense irregular collagenous connective tissue (textus connetivus collagenous compactus irregularis) in which small blood vessels and lymphatic vessels are located. This layer along with the trachealis muscle bridges the dorsal gap left by the incomplete cartilage rings. The connective tissue of the membranous portion blends with the tunica adventitia of the trachea (Figure 8 - 6). The tunica adventitia of the trachea is dense irregular collagenous connective tissue in which small blood vessels are located.

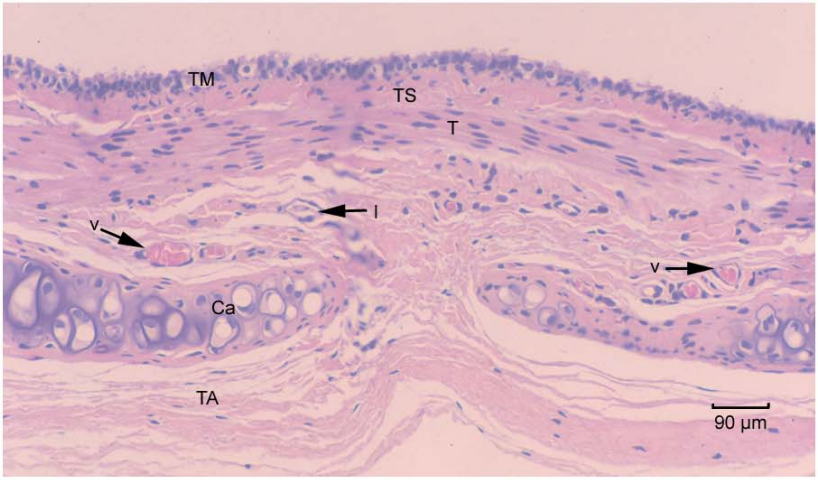

Figure 8 - 6. Trachealis muscle (T) attaching to the luminal side of the tracheal cartilage. Tunica mucosa (TM), tela submucosa (TS), connective tissue with small blood vessels (v) and lymphatic vessel (l) deep to the trachealis muscle, tunica adventitia (TA). (Hematoxylin and Eosin).

Bronchial Tree

Projecting into the tracheal lumen at its bifurcation (bifurcation tracheae) into right and left principal bronchi (bronchus principalis dexter et sinister) are two ridges of tissue. These ridges are located opposite from one another on the dorsal and ventral aspects of the tracheal lumen. Each ridge is covered with an epithelium similar to that of the trachea; however, the ciliated cells appear to be cuboidal (epitheliocytus cuboideus). Each ridge of tissue has two layers of smooth muscle deep to the tunica mucosa which are derived from the trachealis muscle. The two ridges unite and form a vertical membranous tracheal carina (carina tracheae) which marks the bifurcation of the trachea into right and left principal bronchi (Figure 8 - 7). The carina is covered by a pseudostratified ciliated cuboidal epithelium with two layers of smooth muscle fibers deep to the epithelium. These two layers of smooth muscle are separated by a layer of loose connective tissue (Figure 8 - 7). Within this connective tissue layer are small blood vessels and compound acinar bronchial glands (glandulae bronchiales). The excretory ducts of these glands are lined with a simple columnar epithelium (epithelium simplex columnare). These ducts open into the lumen of the cranial most portion of the principal bronchi. These bronchial glands consist of mucous cells which have a foamy cytoplasm and a basally located basophilic staining nucleus. No serous cells are observed in these glands. Located on the ventral surface of the trachea prior to its bifurcation and dorsal to the pulmonary trunk (truncus pulmonalis) is an autonomic nervous system ganglion (ganglion autonomicum) (Figure 8 - 8). The nerve cell bodies (corpus neuroni) of the ganglion are round and surrounded by satellite cells that are intimately adjacent to

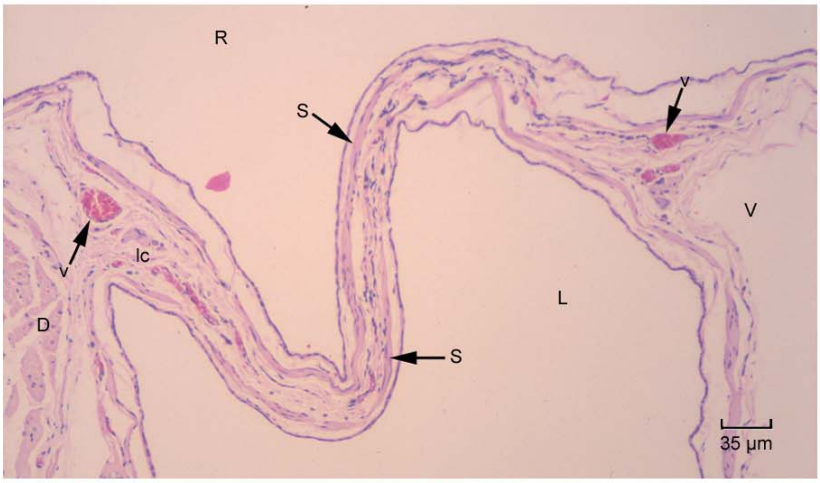

Figure 8 - 7. Membranous carina of the tracheal bifurcation. Smooth muscle fibers (S), loose connective (lc) tissue with small blood vessels (v) between the two layers of smooth muscle, dorsal (D) and ventral (V) surfaces of tracheal bifurcation, lumen of right (R) and left (L) principal bronchi. (Hematoxylin and Eosin).

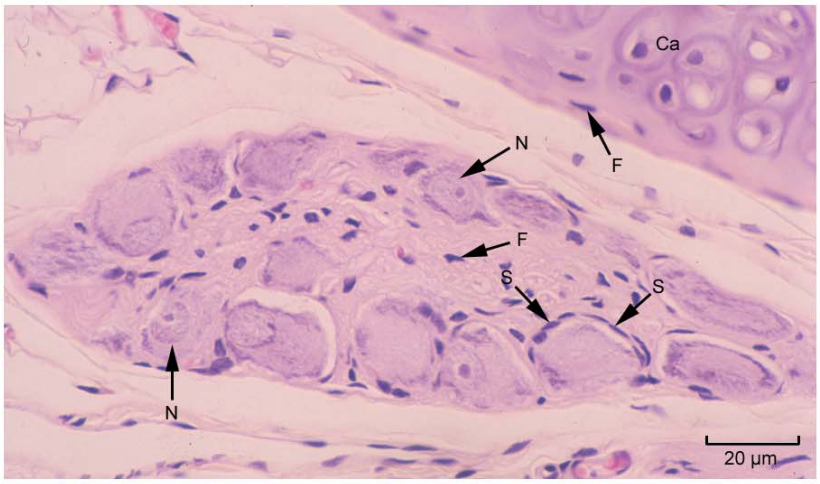

Figure 8 - 8. Autonomic ganglion. Nerve cell body with prominent nucleus (N) and nucleolus, satellite cells (S), fibroblast (F), tracheal cartilage (Ca). (Hematoxylin and Eosin).

the nerve cell bodies. The nuclei of the nerve cell bodies are eccentrically placed, large, round and often have a prominent central nucleolus (Figure 8 - 8). The nuclei of the nerve cell bodies are surrounded by a granular, basophilic cytoplasm. The nerve cell bodies are surrounded by a layer of connective tissue which blends with the surrounding tunica adventitia of the pulmonary trunk and trachea.

The extrapulmonary portion of the principal bronchus is lined by a pseudostratified ciliated columnar epithelium which is 21.0 μm in height (Figure 8 - 9). This epithelial layer consists of columnar and basal cells similar to those of the trachea. The columnar cells have an oval shaped basophilic staining vesicular nucleus and cilia covering the apical margin (Figure 8 - 9). The basal cells are found between the adjacent columnar cells and the shape of the nucleus varies. Mucous secreting goblet cells are not observed in the bronchial epithelium. The propria submucosa is a layer of loose connective tissue deep to the epithelium of the principal bronchi (Figures 8 - 9 and 8 - 10). This layer contains compound acinar seromucous bronchial glands. The bronchial glands are present within the propria submucosa of this portion of the principal bronchus. However, they are also seen between adjacent bronchial cartilage plates (cartilagines bronchiales) and peripheral to them (Figure 8 - 10). The excretory ducts of the bronchial glands open into the lumen of the principal bronchi. The epithelium of this duct is simple columnar epithelium. The columnar cells are non-ciliated and have a centrally located basophilic staining vesicular nucleus surrounded by a vacuolated cytoplasm. The bronchial glands are composed mainly of mixed adenomeres; however, an occassional serous adenomere is also seen. The mixed adenomeres consist of mucous and serous

Figure 8 - 9. Cross section of tunica mucosa of principal bronchus. Nucleus of ciliated columnar cells (C), nucleus of basal cells (B), lamina propria mucosae (Lp). (Hematoxylin and Eosin).

Figure 8 - 10. Extrapulmonary part of principal bronchus. Pseudo-stratified ciliated columnar epithelium (E), bronchial glands (Bg), cartilage plates (Ca), smooth muscle (S) of musculocartilaginous tunic connecting two dorsal cartilage plates. (Hematoxylin and Eosin).

cells. The mucous cells are pyramidal shaped, have a foamy cytoplasm and a small round or sometimes flattened, basally positioned basophilic nucleus. The serous cells have a granular, pale staining eosinophilic cytoplasm with a round, basally located nucleus. These cells are located in the adenomeres among the mucous cells or around the periphery of the mucous adenomeres as serous demilunes or form adenomeres themselves. The musculocartilaginous tunic (tunica musculocartilaginea) consists of a smooth muscle layer and a cartilaginous part. The cartilaginous part consists of bronchial cartilage plates that are localized to the extrapulmonary portion of the principal bronchus. The smooth muscle layer is approximately seven cell layers thick, circularly oriented and attaches to the inside of the dorsal most right and left bronchial cartilage plates (Figure 8-10).

The intrapulmonary portion of the principal bronchus is lined by an epithelium similar to that of the extrapulmonary portion. Additionally, goblet cells are not observed in the epithelium of this portion of the bronchus. The lamina prorpia mucosae in this region is a layer of loose connective tissue deep to the epithelium (Figure 8 - 11). It is separated from the tela submcuosa by the lamina muscularis mucosae. This layer is a continuation of the smooth muscle of the musculocartilaginous tunic and is arranged as individual bundles of circularly oriented smooth muscle which are five to six cell layers thick. The tela submucosa is a layer of loose connective which contains small blood vessels, compound branched acinar seromucous bronchial glands, lymphatic vessels and an occasional autonomic ganglion (Figure 8 - 11). The bronchial glands and

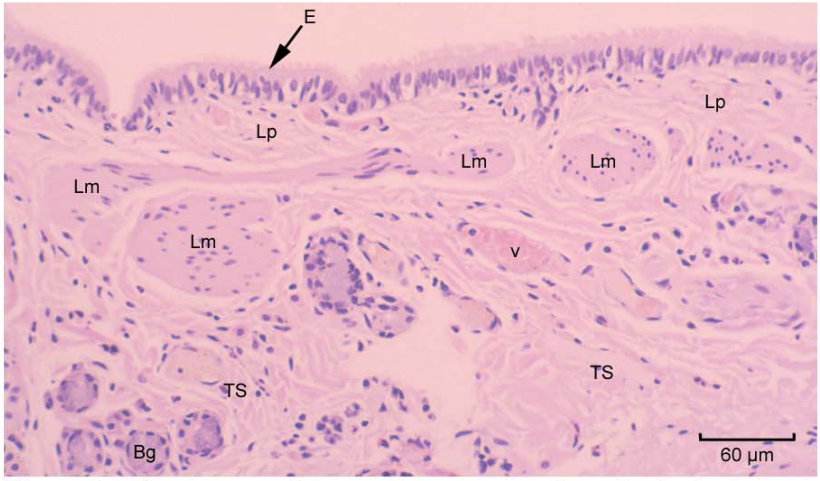

Figure 8 - 11. Layers of intrapulmonary portion of principal bronchus. Pseudostratified ciliated columnar epithelium (E), lamina propria mucosae (Lp), lamina muscularis mucosae (Lm), tela submucosa (TS) with bronchial glands (Bg) and small blood vessel (v). (Hematoxylin and Eosin).

their associated excretory ducts are similar to those in the extrapulmonary portion of the principal bronchus.

The secondary and tertiary bronchi are lined by a ciliated simple columnar epithelium (epithelium simplex columnare ciliatum). The nuclei in the columnar cells of the secondary bronchi are oval shaped and centrally placed (Figure 8 - 12) while those in the columnar cells of the tertiary bronchi are round and basally located (Figure 8 - 13). A thin lamina propria mucosae of loose connective tissue is present beneath the epithelial layer with fibroblasts and small blood vessels. Deep to the lamina propria mucosae is the lamina muscularis mucosae. This layer of circularly oriented smooth muscle is four to five cell layers thick in the secondary bronchus and three to four cell layers thick in the tertiary bronchus. A tela submucosa and musculocartilaginous tunic do not exist in the secondary and tertiary bronchi resulting in the lamina muscularis mucosae lying adjacent to alveoli of the lung (pulmo).

The tertiary bronchi branch into primary bronchioles (bronchiolus) which then subdivide into secondary bronchioles. These primary and secondary bronchioles are lined by a ciliated simple columnar epithelium (Figures 8 - 14 and 8 - 15). The lamina propria mucosae is a thin layer of loose connective tissue deep to the epithelium. The lamina muscularis mucosae is a circular layer of smooth muscle which is three cell layers thick. A tela submucosa and tunica muscularis are not present. The lamina muscularis mucosae is adjacent to the alveoli of the lung similar to the secondary and tertiary bronchi.

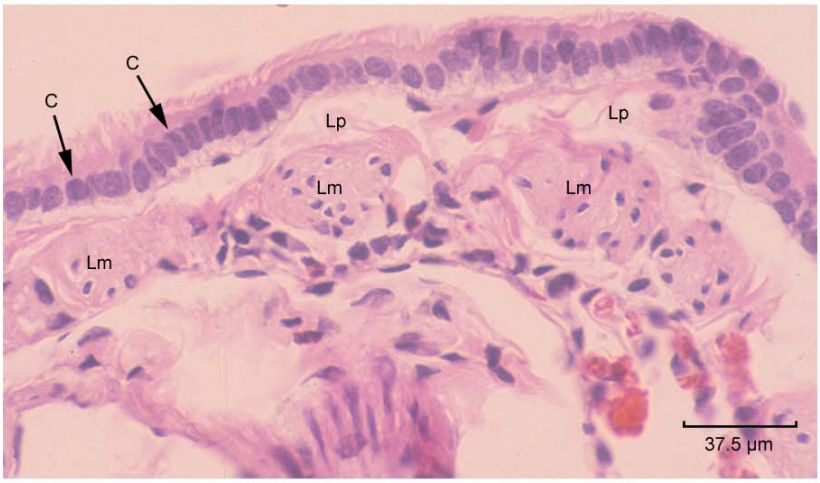

Figure 8 - 12. Longitudinal section of secondary bronchus. Ciliated columnar cells (C), lamina propria mucosae (Lp), lamina muscularis mucosae (Lm). (Hematoxylin and Eosin).

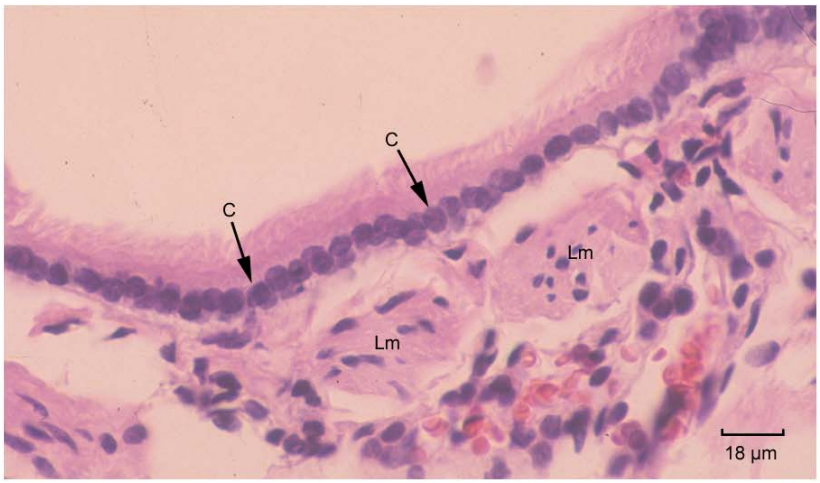

Figure 8 - 13. Longitudinal section of tertiary bronchus. Ciliated columnar cells (C), lamina muscularis mucosae (Lm). (Hematoxylin and Eosin).

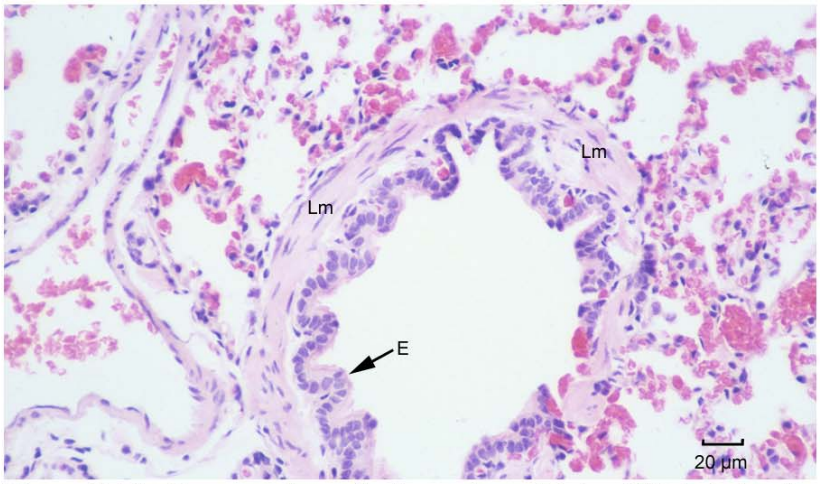

Figure 8-14. Cross section of primary bronchiole. Ciliated simple columnar epithelium (E), lamina muscularis mucosae (Lm). (Hematoxylin and Eosin).

Figure 8-15. Tunica mucosa of primary bronchiole. Ciliated simple columnar epithelium (E), lamina propria mucosae (Lp), lamina muscularis mucosae (Lm). (Hematoxylin and Eosin).

The terminal bronchioles are lined by a ciliated simple cuboidal epithelium (epithelium simplex cuboideum ciliatum) (Figure 8 - 16). The cuboidal cells have a round basophilic staining nucleus and the apical surface of the cells is covered with cilia. Deep to the epithelium is a sparse layer of loose connective tissue called the lamina propria mucosae. The lamina muscularis mucosae is a layer of smooth muscle which is at least three cell layers thick and oriented circular to the lumen of the bronchiole. A tela submucosa and tunica muscularis is not present.

The terminal bronchioles branch into respiratory bronchioles (bronchiolus respiratorius) (Figure 8 - 16). The respiratory bronchioles have alveoli (alveolus pulmonis) interrupting the epithelial layer and smooth muscle of the lamina muscularis mucosae. The lamina muscularis mucosae is two cell layers thick and oriented in a circular fashion (Figure 8 - 17). The respiratory bronchioles are lined by a ciliated simple cuboidal epithelium similar to that of the terminal bronchioles (Figure 8 - 18). However, in the terminal portion of the respiratory bronchiole before opening into an alveolar duct, there is a transition in the epithelium from ciliated simple cuboidal to simple squamous (epithelium simplex squamosum).

The alveolar ducts (ductus alveolaris) are outlined by smooth muscle bundles which are covered by a simple squamous epithelium (Figure 8 - 16). The smooth muscle bundles are one to two cell layers thick and oriented circular to the longitudinal axis of the alveolar duct. The alveolar ducts have alveoli opening into the lumen of the duct. The alveolar ducts lead into alveolar sacs (sacculus alveolaris) which consist of clusters of alveoli (Figure 8 - 16).

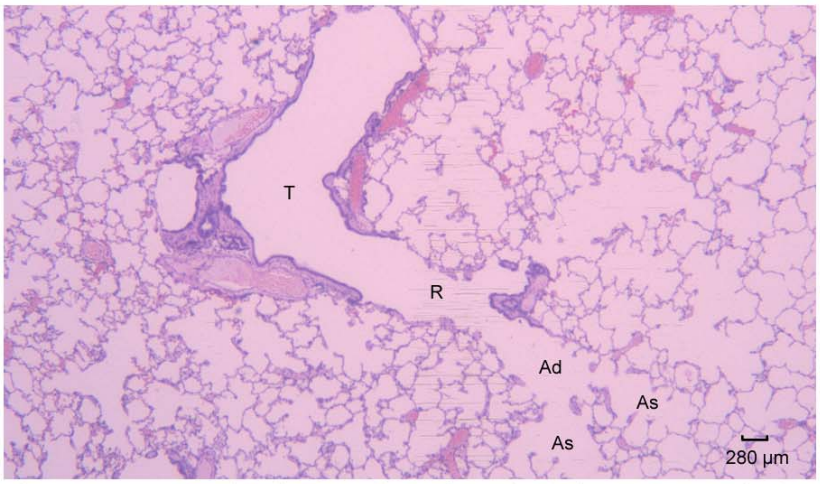

Figure 8-16. Longitudinal section of terminal airways. Terminal bronchiole (T), respiratory bronchiole (R), alveolar duct (Ad), alveolar sac (As). (Hematoxylin and Eosin).

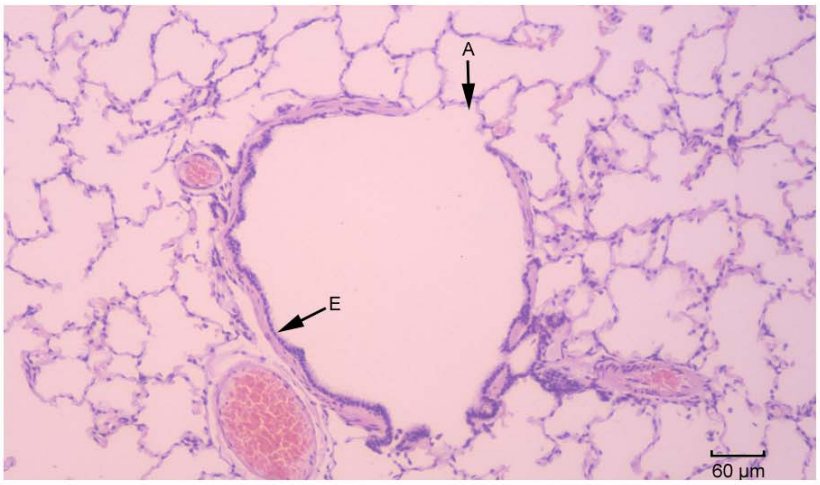

Figure 8-17. Cross section of respiratory bronchiole. Ciliated simple cuboidal epithelium (E), alveolus (A), lamina muscularis mucosae (Lm). (Hematoxylin and Eosin).

Figure 8-18. Tunica mucosa of the respiratory bronchiole. Ciliated simple cuboidal epithelium (C), lamina muscularis mucosae (Lm). (Hematoxylin and Eosin).

The alveoli are lined by two types of epithelial cells. The type I pneumocytes (epitheliocytus respiratorius) are simple squamous with a flattened central nucleus that protrudes into the alveolar lumen (Figure 8 - 19). The type I pneumocytes are the most abundant cell of the alveoli. Type II pneumocytes [epitheliocytus magnus (granularis)] are round to pyramidal shaped cells and are found among the type I pneumocytes (Figure 8 - 20). The type II pneumocytes have a larger centrally placed nucleus with a prominent nucleolus and a slightly vacuolated, foamy, basophilic cytoplasm. The nucleus of these cells also has a nucleolus.

Adjacent alveoli are separated from one another by an interalveolar septum (septum interalveolare). This septum is a thin layer of collagenous connective tissue with intervening capillaries (Figure 8 - 21). Alveolar pores (porus septi) are present in the interalveolar septa of adjacent alveoli. These pores disrupt the epithelial lining of the alveoli and allow the passge of alveolar macrophages (macrophagocytus alveolaris) from one alveolus to another (Figure 8 - 21).

Pleura:

The visceral pleura (tunica serosa) is a layer of simple squamous mesothelium covering the outer surface of the lung (Figure 8 - 22). Supporting this mesothelial layer is the tunica subserosa which is a thin layer of loose collagenous connective tissue. Extending from the tunica subserosa are connective tissue septa which penetrate the parenchyma of the lung lobe dividing it in lobules (Figure 8 - 22).

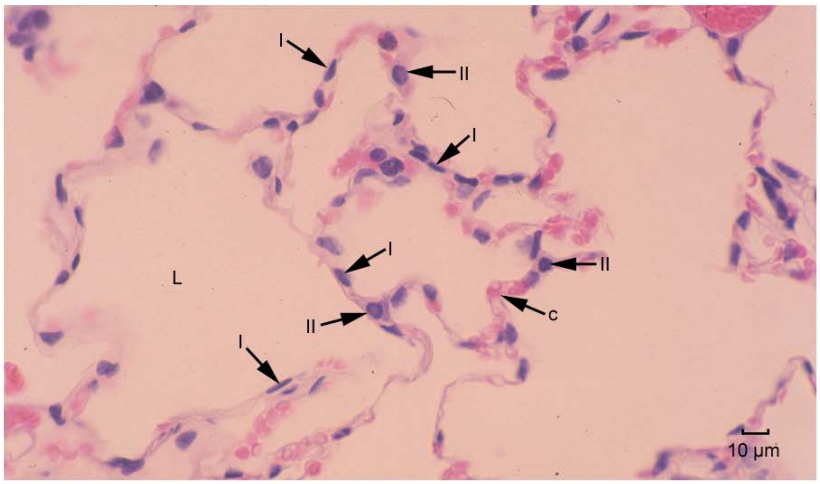

Figure 8 - 19. Lung parenchyma. Lumen of an alveolus (L), nucleus of type I pneumocyte (I), nucleus of type II pneumocyte (II), capillary (c). (Hematoxylin and Eosin).

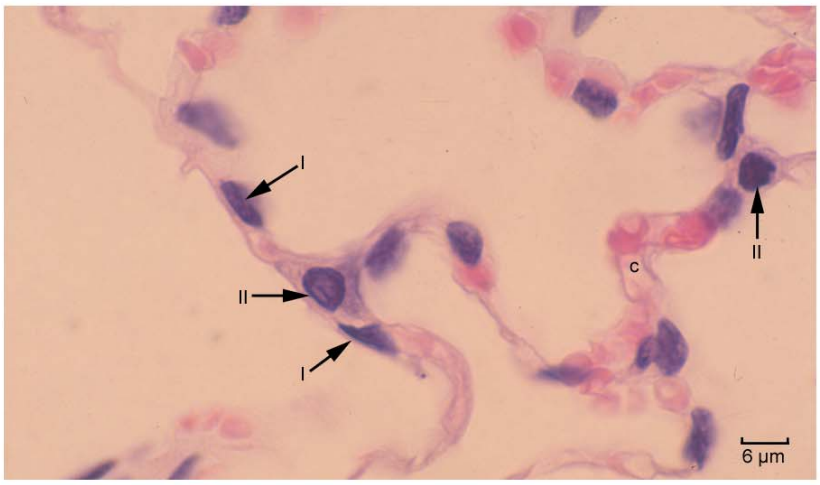

Figure 8 - 20. Alveolar cells. Nucleus of type I pneumocyte (I), nucleus of type II pneumocyte (II), capillary (c). (Hematoxylin and Eosin).

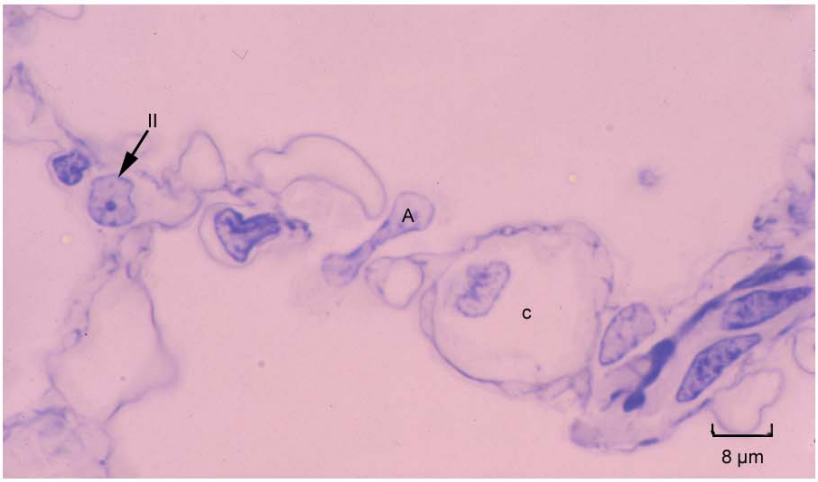

Figure 8 - 21. Alveolar macrophage passing through alveolar pore. Nucleus of alveolar macropahge (A), capillary (c), type II pneumocyte (II). (Methylene and Azure Blue).

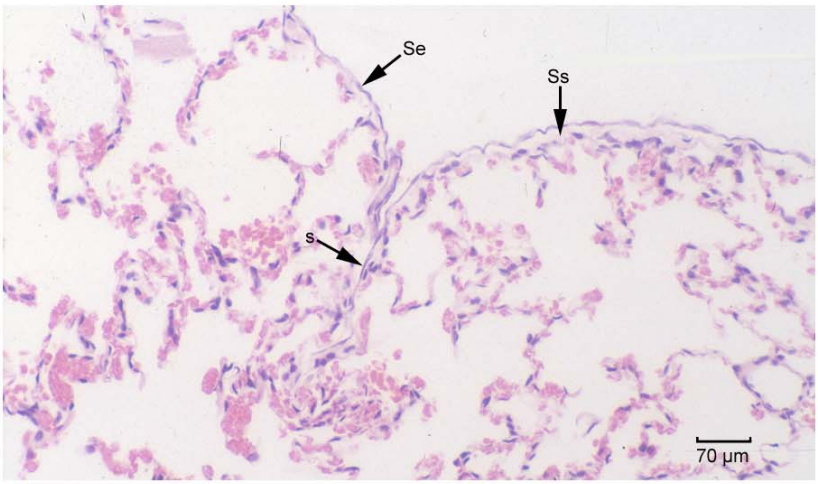

Figure 8 - 22. Visceral pleura of the lung. Simple squamous mesothelium of the tunica serosa (Se), tunica subserosa (Ss), connective tissue septa (s). (Hematoxylin and Eosin).

DISCUSSION:

The epithelium lining the trachea and the principal bronchi of the adult gray short-tailed opossum *(Monodelphis domestica)* is classified as pseudostratified ciliated columnar with goblet cells which is similar to domestic mammals (Banks, 1993; International Committee on Veterinary Gross Anatomical Nomenclature, 1994; Dellmann and Eurell, 1998). The height of the epithelium between these two regions of the gray short-tailed opossum shows some variation which may be a result of the pressure of intratracheal perfusion. However, samples were taken at various regions of the trachea and principal bronchi of all animals and all sites yielded consistent results which suggest a regional difference in the epithelial height of this opossum between the trachea and principal bronchi.

Three cell types (columnar cells, basal cells and goblet cells) have been identified by light microscopy in the tracheal epithelium of the gray short-tailed opossum. These cells are morphologically similar to those described in domestic carnivores (Breeze and Wheeldon, 1977; Dellmann and Eurell, 1998). In the gray short-tailed opossum, few goblet cells are observed among the columnar cells in the trachea as compared to domestic carnivores in which they are found throughout the length of the trachea (Breeze and Wheeldon, 1977; Dellmann and Eurell, 1998). Similarly Hansell (1968), Jeffery (1975), Becci (1978) and Pack *et al.* (1981) also documented decreased numbers of goblet cells in the tracheal epithelium of the mouse, rat and hamster.

The columnar and basal cells of the principal bronchial epithelium are similar to those found in the tracheobronchial tree of domestic carnivores (Banks, 1993; Dellmann and Eurell, 1998). However, the goblet cells described in the bronchi of domestic carnivores are not observed in the principal bronchi of this opossum.

Numerous small blood vessels are observed within the tela submucosa of the gray short-tailed opossum. A similar observation is also described in the trachea of the koala (*Phascolarctos cinereus*) and phalanger (*Trichosurus vulpecula*) (Tucker, 1974). According to Tucker (1974), a vascular layer, comprised of two to three rows of capillaries, lies deep to the epithelium. Also, deeper within the tracheal wall and around the tracheal glands, numerous arterioles and venules are present. Based on Tucker's (1974) description it is difficult to determine if the capillaries are within the lamina propria mucosae or the tela submucosa. However, we believe the arterioles and venules Tucker (1974) describes may be similar to the small blood vessels seen in the tela submucosa of the gray short-tailed opossum. The tracheal glands of the gray short-tailed opossum are similar to those of domestic carnivores (Banks, 1993; Dellmann and Eurell, 1998) in that they consist of mucous and serous cells. Previous descriptions on domestic carnivores classify the tracheal glands as compound tubuloacinar. However, in the gray short-tailed opossum, these glands are classified as compound acinar. The tracheal glands are numerous in the ventral and lateral walls of the trachea similar to domestic carnivores (Getty, 1975). The tracheal glands of the gray short-tailed opossum open into the tracheal lumen by excretory ducts similar to that of the North American opossum (Krause and Leeson, 1973) and domestic carnivores (Dellmann and Eurell, 1998). In the

gray short-tailed opossum, these excretory ducts are lined by a simple columnar epithelium. The previous article by Krause and Leeson (1973) does not provide a detailed description on the epithelium of these excretory ducts except to state mucous secreting cells are often present among the epithelial cells. In addition to Krause and Leeson's (1973) observation in the North American opossum, the mucous secreting cells have also been described in the excretory ducts of domestic carnivores (Dellmann and Eurell, 1998). Mucous secreting cells are not observed in the excretory ducts of the tracheal glands of the gray short-tailed opossum.

The carina of the gray short-tailed opossum is membranous in nature. It lacks the cartilaginous support found in the carina of domestic carnivores (Getty, 1975). Located within the carina of the gray short-tailed opossum are mucous secreting bronchial glands. These glands lack the serous components found within the tracheal and bronchial glands of the principal bronchi of the gray short-tailed opossum, North American opossum (Krause and Leeson, 1973) and domestic carnivore (Getty, 1975; Banks, 1993; Burkitt *et al.,* 1993; Dellmann and Eurell, 1998).

The extrapulmonary and intrapulmonary portions of the principal bronchi of the gray short-tailed opossum have some unique variations in their histologic organization when compared to that of domestic carnivores (Getty, 1975; Banks, 1993; Dellmann and Eurell, 1998). The extrapulmonary portion of the principal bronchus has a combined propria submucosa because of the lack of a lamina muscularis mucosa between these two layers as in domestic mammals. In the gray short-tailed opossum, this smooth muscle layer does not appear until the intrapulmonary portion of the principal bronchus.

Additionally, the lamina muscularis mucosae of the gray short-tailed opossum is a discontinuous layer of circularly oriented smooth muscle bundles around the bronchus in contrast to domestic mammals where the smooth muscle is arranged in a helical fashion (Getty, 1975; Banks, 1993; Burkitt *et al.,* 1993; Dellmann and Eurell, 1998). The bronchial glands of the gray short-tailed opossum are found, as they are in the North American opossum (Krause and Leeson, 1973) and domestic carnivores, in the tela submucosa. These glands are localized in the principal bronchi only. This differs from the North American opossum (Sorokin, 1965b; Jeffery, 1983) and domestic feline (Getty, 1975; Jeffery, 1983) in which these glands have been found extending into the bronchiolar tree while those of other domestic mammals (Getty, 1975; Banks, 1993) only extend as far caudally as the tertiary bronchi. Similar to the North American opossum (Krause and Leeson, 1973) and domestic carnivores (Getty, 1975; Banks, 1993; Burkitt *et al.,* 1993; Dellmann and Eurell, 1998), the bronchial glands of the gray short-tailed opossum are composed of mucous and serous cells. Through routine staining with H&E and light microscopy, the mucous and serous cells in the bronchial glands of the gray short-tailed opossum appear similar to those of domestic carnivores (Banks, 1993; Burkitt *et al.,* 1993; Dellmann and Eurell, 1998). In addition, a previous article on the bronchial glands of the North American opossum (Sorokin, 1965b) indicates the mucous cells in these glands are similar to those of the gray short-tailed opossum. However, this article also indicates the serous cells of these glands are different from those of domestic mammals. According to Sorokin (1965b), these serous cells lack the cytoplasmic secretory granules found in those of domestic mammals. Also, the predominant cellular

organelle in these serous cells is the mitochondria and the cell surface has microvilli. Therefore, these modifications give the serous cells of the North American opossum bronchial glands characteristics similar to cells involved in ion secretion. Therefore, a more detailed study of the serous cells in the gray short-tailed opossum bronchial glands would be needed to determine if these modifications are present. The musculocartilaginous tunic of the extrapulmonary portion of the principal bronchi of the gray short-tailed opossum consists of a muscular part and a cartilaginous part. This layer is present only in the extrapulmonary portion of the principal bronchus. Additionally, the muscular part is localized dorsally thus attaching to the most dorsal right and left bronchial cartilage plates similar to the attachment of the trachealis muscle to the dorsal ends of the tracheal cartilages. The bronchial cartilages of the gray short-tailed opossum are irregular shaped plates that only surround the perimeter of the extrapulmonary portion of the principal bronchi. This differs from the pattern in domestic carnivores in which the extrapulmonary portion of the principal bronchus has cartilaginous rings similar to those of the trachea while the intrapulmonary bronchial cartilages are irregular shaped plates (Getty, 1975).

The ciliated simple columnar epithelium of the secondary and tertiary bronchi of the gray short-tailed opossum differs from the pseudostratified ciliated columnar epithelium described in domestic carnivores (Getty, 1975; Banks, 1993; Dellmann and Eurell, 1998). In addition, other variations in the organization of these bronchi in the gray short-tailed opossum include the lack of bronchial glands within the tela submucosa and the absence of a distinct musculocartilaginous tunic as described in domestic carnivores (Getty, 1975;

Banks, 1993; Burkitt *et al.,* 1993; Dellmann and Eurell, 1998). Therefore, the absence of these layers results in the alveoli of the lung contacting the lamina muscularis mucosae of the secondary and tertiary bronchi.

The epithelium of the primary and secondary bronchioles of the gray short-tailed opossum are lined by an epithelium similar to the large bronchioles of domestic mammals (Banks, 1993; Dellmann and Eurell, 1998). Previous descriptions of domestic carnivores describe a tunica submucosa and tunica muscularis in these bronchioles. However, in the gray short-tailed opossum, the tunica submucosa does not exist and the only smooth muscle layer present is the lamina muscularis mucosae.

In domestic carnivores, the epithelium of the respiratory bronchioles is classified as nonciliated simple cuboidal (Banks, 1993; Dellmann and Eurell, 1998). Previous descriptions of these nonciliated cuboidal cells in domestic mammals refer to them as bronchiolar exocrine cells. Additionally, ultrastructural studies on this cell indicate it has a secretory function. However, this cell is not seen in the terminal or respiratory bronchioles of the gray short-tailed opossum. Also the epithelium of the terminal portion of the respiratory bronchiole makes a transition from the ciliated simple cuboidal to simple squamous. Descriptions documenting this transition in the epithelium of this region of other marsupials or domestic mammals could not be found for comparison.

The alveolar ducts and type I and type II pneumocytes lining the alveoli and the alveolar pores in the gray short-tailed opossum are unremarkable as they are similar to those of the North American opossum (Sorokin, 1967; Krause *et al.,* 1976) and domestic carnivores (Banks, 1993; Dellmann and Eurell, 1998).

The visceral pleura covering the lung of the gray short-tailed opossum is similar to that of the North American opossum (Krause and Leeson, 1973, 1975) and domestic carnivores (Banks, 1993; Burkitt, 1993). In all three species, the visceral pleura (tunica serosa) is supported by the loose collagenous connective tissue of the tunica subserosa. Previous descriptions by Krause and Leeson (1973, 1975), Banks (1993) and Burkitt (1993) state the tunica subserosa of the North Ameican opossum and domestic carnivore is also rich in elastic fibers. Using an Acid Orcein Giemsa stain, no elastic fibers were observed in the tunica subserosa of the gray short-tailed opossum. In addition, the tunica subserosa of the gray short-tailed opossum gives off septa into the lung similar to the North American opossum and domestic carnivore.

CHAPTER IX

CONCLUSION:

The lobation of the right and left lungs of the gray short-tailed opossum and the North American opossum is similar to previous descriptions of several small marsupials and domestic carnivores. However, the variations described in the lung lobation in the previous chapters among some of the marsupials may in fact be attributed to the use of the superficial features of the lung instead of tracheobronchial cast examination or bronchial tree dissection. The division of the pulmonary arteries into pulmonary lobar arteries and their location in relation to the lobar bronchi are similar to domestic mammals. The pulmonary veins joining to form a common pulmonary venous trunk in the gray short-tailed opossum and the North American opossum is also reported in previous descriptions on the native cat, brush-tailed opossum and the North American opossum. The formation of a common pulmonary venous trunk seems to be characteristic of marsupials and differs from the pattern of domestic mammals in which multiple pulmonary veins open into the left atrium. The bronchial artery of the gray short-tailed opossum and the North American opossum originates from the bronchoesophageal artery and divides into right and left branches similar to domestic mammals. The location of the cranial deep cervical lymph nodes, cranial mediastinal lymph nodes and tracheobronchial lymph nodes of both opossums are similar to those of domestic carnivores. The pattern of innervation to the lower respiratory tract of the gray

short-tailed opossum and the North American opossum is similar to that described in domestic mammals.

The trachea and principal bronchi of the gray short-tailed opossum are lined by pseudostratified ciliated columnar epithelium. The columnar cells and basal cells of this epithelial layer are similar to those previously described domestic mammals. Goblet cells are only present in the epithelium of the trachea and similar to those of domestic carnivores. The tracheal and bronchial glands of the gray short-tailed opossum are composed of mucous and serous cells similar to those of domestic mammals. Additionally, the bronchial glands of this opossum do not extend the length of the bronchial tree as they do in domestic mammals. These glands, along with the bronchial cartilage plates, are localized to the principal bronchi of the gray short-tailed opossum. The secondary and tertiary bronchi are lined by ciliated simple columnar epithelium. The primary, secondary and terminal bronchioles are lined by ciliated simple cuboidal epithelium. The terminal bronchioles open into respiratory bronchioles. These respiratory bronchioles are lined by ciliated simple cuboidal epithelium in their proximal portion and simple squamous in their terminal portion. This epithelial pattern differs from that of domestic carnivores in which the epithelium of the respiratory bronchiole is described as simple cuboidal. The alveolar ducts, alveolar sacs, alveoli, type I and type II pneumocytes are similar to those described in the North American opossum and domestic carnivores.

REFERENCES

Adrian, R.W. 1964. Segmental Anatomy of the Cat's Lung. *American Journal of Veterinary Research* 25: 1724-1733.

Alcorn, D.G.; Adamson, T.M.; Maloney, J.E.; Robinson, P.M. 1981. A morphologic and morphometeric analysis of fetal lung development in sheep. *Anaomical Record* 201: 655-667.

Al-Tikriti, M.S.; Henry, R.W.; Eiler, H.; Schultz, T.W.; Breider, M.A.; Cullens, W.C. 1991. Fine structural aspects of postnatal development of feline lung. *Anatomia, Histologia, Embryologia* 20: 311-319.

Ashman, R.B. and J.M. Papadimitriou. 1975. Development of lymphoid tissue in a marsupial *Setonix brachyurus* (quokka). *Acta Anatomica* 91: 594-611.

Auton, J.M.; G.R Zarzosa; F.G. Cano; R.L. Reviriego; F.M. Medina; O.L. Albors and M.O Hernandez. *Atlas De Anatomica Clinica*. pp.13-24. Las Palmas De Gran Canaria: U.D. De Anatomía Y Embriología De La Facultad De Veterinaria, 2000.

Azzali, Giacomo and Liberato J. DiDio. 1965. The lymphatic system of *Didelphys azarae* and *Didelphys marsupialis*. *American Journal of Anatomy* 116: 449-470.

Baggott, L.M. and H.D.M. Moore. 1990. Early development of the gray, short-tailed opossum. (*Monodelphis domestica*) in vivo and in vitro. *Journal of Zoology* 222: 623-639.

Banks, William J. 1993. *Textbook of Veterinary Anatomy.* pp.390-407. 3rd edition. St. Louis: Mosby Year Book.

Basden, K.; D.W. Cooper and E.M. Deane. 1997. Development of the lymphoid tissues of the tammar wallaby *(Macropus eugenii)*. *Reproduction Fertility and Development* 9: 243-254.

Becci, Peter J.; Elizabeth McDowell and Benjamin F. Trump. 1978. The respiratory epithelium II. Hamster Trachea, Bronchus and Bronchioles. *Journal of National Cancer Institute* 61(2):551-561.

Bernard, S.L.; D.L. Luchtel; R.W. Glenny and S. Lakshimarayan. 1996. Bronchial circulation in the marsupial opossum, Didelphis marsupialis. *Respiratory Physiology* 105: 77-83.

Bremer, J.L. 1904. On the lung of the opossum. *American Journal of Anatomy* 3: 67-73.

Breeze, Roger G. and Eric B. Wheeldon. 1977. The cells of the pulmonary airways. *American Review Respiratory Diseases* 116: 705-777

Breeze , Roger and Margaret Turk. 1984. Cellular structure, function and organization in the lower respiratory tract. *Environmental Health Perspectives* 55: 3-24.

Brewer, A. 1923. Lung of the opossum. *Anatomical Record* 8: 431-440.

Burkitt, H.G.; B. Young and J.W. Heath. 1993. *Wheater's Functional Histology*. 3rd edition. New York: Churchill Livingstone Inc. pp.76-92, 220-234.

Cisternas, P.A. and P.J. Armati. 1999. Development of the thymus, spleen, lymph nodes and liver in the marsupial, *Isoodon macrourus* (Northern brown bandicoot, Peramelidae). *Anatomy and Embryology* 200: 433-443.

Clements, L.P. 1937-38. Embryonic development of the respiratory portion of the pig lung's. *Anatomical. Record* 70: 575-595.

Coues, E. 1872. Osteology and Myology of Didelphis virginana. *Memoirs of Boston Society of Natural History* 2: 41-149.

Dellmann, H. Dieter and Joann Eurell. 1998. *Textbook of Veterinary Histology*. pp.19-31, 148-163. 5th edition. Baltimore: Williams and Wilkins.

Dowd, David. 1969. Gross features of the heart of a marsupial Trichosurus vulpecula. *Acta Anatomica* 74: 454-471.

Dyce, K.M.; W.O. Sack and C.J.G. Wensing. 1996. *Textbook of Veterinary Anatomy*. pp.159-167, 403-15. 2nd edition. Philadelphia: W. B. Saunders Company.

Ellsworth, A. *Didelphis marsupialis virginiana*. Dissections. Master's Thesis. University of Connecticut, Storrs. 1966.

Ellsworth, A.F. 1976. *The North American Opossum An Anatomical Atlas*, New York: Robert Krieger Publishing Company; Huntington, 209p.

Evans, H.E. 1993. *Miller's Anatomy of the Dog*. pp.479-493, 602, 783-795. 3rd edition. Philadelphia: W. B. Saunders Company.

Fadem, B.H.; G.L. Trupin; E. Maliniak; J.L. VandeBerg and V. Hayssen. 1982. Care and Breeding of the Gray Short-tailed Opossum (*Monodelphis domestica). Laboratory Animal Science* 32(4): 405-409.

Federative Committee on Anatomical Terminology. 1998. *Terminologia Anatomica*. pp.60. Germany: Druckhaus Thomas Muntzer.

Filan, S. L. 1991. Development of the middle ear region in *Monodelphis domestica*: Marsupial solutions to an early birth. *Journal Zoology* 225:557-588.

Fobres, W.A. 1881. On some points in the anatomy of the koala (*Phascolarctos cinercus*). *Proceedings of the Zoological Society of London* 40: 180-188.

Getty, Robert. 1975. *Sisson and Grossman's The Anatomy of the Domestic Animals* Vol. 1. pp.128-144. 5th edition. Philadelphia: W.B. Saunders Company.

Greenwood, M.F. and Holland, P. 1972. The mammalian respiratory tract surface. *Laboratory Investigations* 27: 296-304.

Ham, A.W. and Baldwin, K.W. 1941. A histological study of the development of the lung with particular reference to the nature of the alveoli. *Anatomical Record* 81: 363-379.

Hansell, Margaret and Richard Moretti. 1968. Ultrastructure of the mouse tracheal epithelium. *Journal of Morphology* 128:159-170.

Hare, W.C.D. 1955. The broncho-pulmonary segments in the sheep. *Journal of Anatomy* 89: 387-402.

Haynes, Julie I. 1991. Cervical lymph nodes and mast cells in the marsupial *Sminthopsis crassicaudata*. *The Anatomical Record* 231: 7-13.

Henry, R.W. Silicone tracheobronchial casts. 1992. *Journal International Society of Plastination* 6 (1): 38-40.

Henry, R.W. Silicone pulmonary vascular casts with attached tracheobronchial cast. 1992. *Journal International Society of Plastination* 6 (1): 41-44.

Hill, J.P and W.C. Osman Hill. 1955. The growth stages of the pouch young of the Native cat (*Dasyurus vverinus)* together with observations on the anatomy of new-born. *Transactions of the Zoological Society of London* 28 (5): 389-425.

Hubbard, G. B.; D.G. Saphire; S. M. Hackelmann. 1991. Ontogeny of the thymus gland of a marsupial (*Monodelphis domestica)*. *Lab Animal Science* 41:227-232.

Hubbard, G.B.; M.C. Mahaney; C.A. Gleiser; D.E. Taylor and J.L. Vandeberg. 1997 Spontaneous Pathology of the Gray Short-Tailed Opossum (*Monodelphis domestica*), *Laboratory Animal Science* 47(1): 19-26.

International Committee on Veterinary Gross Anatomical Nomenclature. 1994. *Nomina Anatomica Veterinaria*. pp. 17-18, 51-52, 61, 65, 77, 85. 4th edition. Ithaca, New York: International Committees on Veterinary Gross Anatomical Nomenclature, Veterinary Histological Nomenclature and Veterinary Embryological Nomenclature.

Ishaq, M. 1980. A morphological study of the lungs and bronchial tree of the dog: with a suggested system of nomenclature for bronchi. *Journal of Anatomy* 131(4): 589-610.

Jeffery, P.K. and Lynne Reid. 1975. New observations of rat airway epithelium: a quantitative and electron microscopic study. *Journal of Anatomy* 120 (2): 295-320.

Jeffery, P.K. 1983. Morphologic features of airway surface epithelial cells and glands. *American Review of Respiratory Diseases (Supplement)* 128 (2): S14-S20.

Jones, Frederic Wood. 1949. The study of a generalized marsupial (*Dasycercus cristicauda*). *Zoological Society London.* 26 (1): 31-48.

Kampmeier, Otto Frederic. 1969. *Evolution and Comparative Morphology of the Lymphatic System*. pp.421-433. Springfield, Illinois: Charles C. Thomas Publisher.

Klima, Milan. 1987. *Early development of the shoulder girdle and sternum in marsupials*. New York: Springer-Verlag.

Koch, R.; H. Gasse and H. Wilkens. 1990. Die Topographie der Bauchorgane von *Monodelphis domestica* (Marsupialia). *Zeitschrift fuer Versuchstierkunde*. 33: 251-258.

Kramer, R.; Glass, A. 1932. Bronchoscopic localization of lung abscess. *Annals of Otology, Rhinology, Laryngology* 41: 1210-1240.

Krause, William J. and C. R. Leeson. 1973. The postnatal development of the respiratory system of the opossum. I. Light and scanning electron microscopy. *American Journal of Anatomy* 137: 337-356.

Krause, William J. and C.R. Leeson. 1975. Postnatal development of the respiratory system of the opossum. II. Electron microscopy of the epithelium and pleura. *Acta Anatomica* 92: 28-44.

Krause, William J.; Harry Cutts and C. R. Leeson. 1976. Type II pulmonary epithelial cells of the newborn opossum lung. *American Journal of Anatomy* 146:181-188.

Krause, William J. 1992. A scanning electron microscopic study of the opossum nasal cavity prior to or shortly after birth. *Anatomy and Embryology* 185: 281-289.

Kuehl-Kovarik, C.; D.S. Sakaguchi and J. Igabal. 1995. The gray short-tailed opossum: a novel for mammalian development. *Lab Animal* 24:24-29.

Kusewitt, D.F.; L.A. Applegate and R.D. Ley. 1991. Ultravioloet radiation induced skin tumors in a South American opossum (*Monodelphis domestica*). *Veterinary Pathology* 28: 55-65.

Kusewitt, D.F.; V.A. White; M Rodriguez and R.D. Ley. December 1994. Congestive Heart Failure in a Marsupial (*Monodelphis domestica*). *Laboratory Animal Science* 44: 633-639.

Leichus, L.S.; R.M. Thomas; J.A. Murray and J.L. Conklin. 1997. Effects of oxygen radicals and radical scavenging on opossum lower esophageal sphincter. *Digestive Diseases and Sciences* 42(3): 592-596.

Ley, R.D.; L.A. Applegate and R.J.M. Fry. 1991. Photoreactivity of ultraviolet radiation-induced skin and eye tumors of *Monodelphis domestica*. *Cancer Research* 55: 417-424.

Loosli, C.G. 1938. The structure of the respiratory portion of the mammalian lung with notes on the lining of the frog lung. *American Journal of Anatomy* 62 (3): 375-415.

Luna, Lee G. 1968. *Manual of Histologic Staining Methods of the Armed Forces Institute of Pathology.* pp.38-39, 77. 3rd edition. New York: McGraw-Hill Book Company.

McClure, Charles. F. 1903. A contribution to the anatomy and development of the venous system of *Didelphys marsupialis*- Part I, Anatomy. *American Journal of Anatomy:* 372-403.

McLaughlin, Richard F., Walter S. Tyler and Robert O. Canada. 1961. A study of the subgross pulmonary anatomy in various mammals. *American Journal of Anatomy* 108: 149-65.

McLaughlin, R.F. 1983. Bronchial artery distribution in various mammals and in humans. *American Review Respiratory Diseases* 128 (2): S57-S58.

Morohunfola, K.A., T. E. Jones and B.L. Munger. 1992. The differentiation of the skin and its appendages. I. Normal development of the papillary ridges. *Anatomical Record* 232: 587-598.

Netter, Frank H. 1989. *Atlas of Human Anatomy*. pp.190-191. First Print, Summit, New Jersey: Ciba-Geigy Corporation,

Nickel, R.; A. Schummer and E. Seiferle. 1979. *The Viscera of the Domestic Mammals*. pp. 238-254. 2nd edition. Berlin: Verlag Paul Parey.

Nickel, R.; A. Schummer and E. Seiferle. 1981. *The Anatomy of the Domestic Animals* Vol. 3-*The Circulatory System, the Skin and the Cutaneous Organs of the Domestic Mammals*. pp.70, 71-72, 123-24, 126, 131, 184-185, 278-280, 313, 320-321, 341, 342, 344-346. 2nd edition. Berlin: Verlag Paul Parey.

Oorschot van, R.A.H.; Sarah Williams-Blangero and J.L. VandeBerg. 1992. Genetic diversity of laboratory gray short-tailed opossums (*Monodelphis domestica*): effect of newly introduced wild-caught animals. *Laboratory Animal Science* 42 (3): 255-260.

Osgood, Wilfred Hudson. 1921. *A Monographic Study of the American Marsupial, Caenolestes*. pp. 76-77. The University of Chicago Libraries, Chicago, Illinois.

Oswaldo-Cruz, E. and C.E. Miranda Rocha. 1968. *The brain of the opossum: a cytoarchitectonic atlas in sterotaxic coordinates.* Rio de Janeiro: Instituto de Biofisica, Universidade Federal de Rio de Janeiro.

Owen, F.R.S. 1852. Notes on the anatomy of the tree-kangaroo (*Dendrolagus inustus*). *Proceedings of the Zoological Society of London:* 103-107.

Owen, Richard. 1868. *On the anatomy of vertebrates.* Vol. III-*Mammals.* pp. 513-603. London: Longmans, Green and Co.

Pack, R.J.; Layla H. Al-Ugaily and G. Morris. 1981. The cells of the tracheobronchial epithelium of the mouse: a quantitative light and electron microscope study. *Journal of Anatomy* 132 (1): 71-84.

Parsons, F.G. 1903. On the anatomy of the pig-footed bandicoot (*Choeropus castanotis*). *Journal of Linnean Society of London* 29: 64 – 80.

Peukert-Adam, V.I.; H. Gasse and G. Wirth September 1994. Untersuchungen zur Topographie des Pankreas von *Monodelphis domestica* (Marsupialia). *Deutsche. Tieraerztliche. Wochenschrift* 101: 341-380.

Plopper, Charles; Andrew T. Mariassy and Lila H. Hill, 1980. Ultrastructure of the nonciliated epithelial (clara) cell of mammalian lung: I. A comparison of the rabbit, guinea pig, rat, hamster and mouse. *Experimental Lung Research* 1:139-154.

Plopper, Charles; Andrew T. Mariassy and Lila H. Hill. 1980. Ultrastructure of the nonciliated bronchiolar epithelial (clara) cell of the mammalian lung. II. A comparison of horse, steer, sheep, dog and cat. *Experimental Lung Research* 1:155-169.

Plopper, Charles; Lila H. Hill and Andrew T. Mariassy. 1980. Ultrastructure of the nonciliated epithelial (clara) cell of mammalian lung: III. A study of man with comparison of 15 mammalian species. *Experimental Lung Research* 1:171-180.

Plopper, Charles G. 1983. Comparative Morphologic features of bronchiolar epithelial cells. The Clara cell. *American Review of Respiratory Diseases* 128 (2): S37-S41.

Renfree, M.B.; E.S. Robinson; R.V. Short and J.L. VandeBerg. 1990 Mammary glands in male marsupials: Primordia in neonatal opossums *Didelphis virginiana* and *Monodelphis domestica*. *Development* 110(2): 385-390.

Robinson, R.S.; J.L. Vandeberg and G.B. Hubbard. 1994. Malignant melanoma in U-V irradiated laboratory opossum, initation in suckling young, metastasis in adults and xenograft behavior in nude mice. *Cancer Research*. 54: 5986-5991.

Russell, L.; S. Burguet. 1977. Ultrastructure of Leydig cells as revealed by secondary tissue treatment with a forrocyanide-osmium mixture. *Tissue Cell* 9: 751-756.

Sabourin, C.L.K.; A.G. Freeman and D.F. Kusewitt. 1992. Identification of transforming ras oncogene in an ultraviolet radiation- induced corneal tumor of Monodelphis domestica. *Photochemistry* 55: 417-424.

Schaller, Oskar. 1992. *Illustrated Veterinary Anatomical Nomenclature.* pp.187-190. Ferdinand Enke Verlag Stuttgart.

Selwood, L. and J.L. VandeBerg. 1992. The influence of incubation temperature on oocyte maturation, parthenogenetic and embryonic development in vitro of the marsupial (Monodelphis domestica). *Animal Reproduction Science* 29: 99-116.

Sonntag, Charles F. 1921a. Contributions to the visceral anatomy and myology of the marsupialia. *Proceedings of Zoological Scoiety of London*: 851-82.

Sonntag, Charles F. 1921b. The comparative anatomy of the koala (Phascolarctos cinereus) vulpine phalanger (Trchosurus vulpecula). *Proceedings of Zoological Scoiety of London*:. 547-577.

Sorokin, Sergei. 1962. A note on the histochemistry of the opossum's lung. *Acta Anatomica* 50: 13-21.

Sorokin, Sergei P. 1965b. On the cytology and cytochemistry of the opossum's bronchial glands. *American Journal of Anatomy* 117: 311-338.

Sorokin, Sergei. 1967. A Morphologic and Cytochemical Study on the Great Alveolar Cell. *The Journal of Histochemistry and Cytochemistry* 14 (12): 884-897.

Spicer, S.S.; Setser, M.E.; Mochizuki, I.; Simson, J.A.V. 1982. The histology and fine structure of glands in the rat respiratory tract. *Anatomical Record* 202: 33-43.

Scheuermann, D.W.; Van Meir, F.; Adriaensen, D.; Timmermans, J.P.; De Groodt-Lasseel, M.H.A. 1988. Development of alveolar septa and formation of alveolar pores during the early postnatal period in the rat lung. *Acta Anatomica* 131: 249-260.

Stamp, J.T. 1948. The distribution of the bronchial tree in the Bovine Lung. *Journal of. Comparative Pathology* 58: 1-8.

Suzuki, T.; W.J. Dodds; S.K. Sarna; W.J. Hogan; R.A. Komorowski and Z. Itoh. 1988 Control mechanisms of sphincter of Oddi contraction rate in the opossum. *American Journal of Physiology* 255 (5): 619-626.

Szalay, Frederick S. 1994. *Evolutionary history of the marsupial and an analysis of ostelogical characters,* Cambride, NY: Cambridge Univ. Press.

Tucker, R. 1974. Surfaces and Cleansing Mechanism of the Trachea and Bronchi. *Anatomia, Histologia, Embryologia* 3: 123-141.

Tyler, N.K. and Plopper, C.G. 1985. Morphology of the distal conducting airways on rhesus monkey lungs. *Anatomical. Record* 211: 295-303.

Tyson, E. 1698. Anatomy of an opossum Didelphys. *Philosophical Transactions of Royal Society of London* 20: 105-164.

VandeBerg, J.L. 1983. The gray short-tailed opossum: a new laboratory animal. *ILAR News* 26: 9-12.

Vandeberg, J.L. 1990. The gray short-tailed opossum (*Monodelphis domestica*) as a model didelphid species for marsupial genetic research. *Australian. Journal Zoo*logy 37: 235-247.

VandeBerg, J.L.; E.S. Robinson and S. Williams-Blangero. 1992. A new animal model (*Monodelphis domestica*) for genetic research on skin and eye cancers. *Brazilian Journal of Genetics* 15 (1): 301-304.

Vandeberg, J.L. 1995. *Annual Report of Southwest Foundation for Biomedical Research*. pp.19-20. Duely Graphics, San Antonio, Texas.

Wade, O. and P. Neely. 1949. The heart attached vessels of the opossum, a marsupial. *Journal of Mammol*ogy 30: 111-116.

Woodburne, Russell T. 1973. *Essentials of Human Anatomy*. pp.343-350. New York: Oxford University Press.

Zimmerman, Arnold A. 1940. *Origin and Development of the Lymphatic System in the Opossum*. pp 164-197. Urbana: The University of Illinois Press.

VITA

Lee Anne Cope graduated from Cullowhee High School in May, 1988. She entered Western Carolina University, Cullowhee, North Carolina in August 1988 and graduated in May 1993 with a Bachelor of Science in Biology and a minor in Chemistry. In August 1994, she entered the Master's program in Animal Science at The University of Tennessee in Knoxville where she concentrated in Comparative and Veterinary Anatomy. Following completion of her Master's, Lee Anne returned to North Carolina to teach Biology and Anatomy and Physiology at Southwestern Community College. In January 1998, she returned to The University of Tennessee to pursue a Doctorate in Animal Science with a concentration in Comparative and Veterinary Anatomy.