# Applying a One Health approach to expand disease surveillance in eastern wildlife

**A Dissertation Presented for the**
**Doctor of Philosophy**
**Degree**
**The University of Tennessee, Knoxville**

**Eliza L Baker**
**May 2024**

Copyright © 2024 by Eliza L. Baker
All rights reserved.

# ACKNOWLEDGEMENTS

I would like to thank the UTCVM Histopathology, Virology, and Microbiology laboratories for their assistance with my work. I am thankful for Dr. Rajeev and Dr. Abouelkhair for their guidance and letting me use their laboratory space. Jake, Seth, Keith, and Brad from TWRA were instrumental in helping me collect samples. Finally, I would like to thank USDA-APHIS, particularly Kevin, for helping me collect raccoon samples.

# ABSTRACT

Urban wildlife carry numerous diseases of veterinary and human health importance. Many of these diseases are emerging into new geographic areas, including the southeastern United States, due to a combination of climate change, urbanization, and migration. Urban wildlife can act as excellent sentinels for these diseases, providing doctors and veterinarians with a better understanding of the risks to their patients. We sought to better understand a variety of diseases of human and animal concern via urban wildlife surveillance. We found a high prevalence of numerous zoonotic and companion animal diseases in wildlife, both with and without significant health impacts on the wildlife itself.

# TABLE OF CONTENTS


INTRODUCTION: Critical review of coyote pathogens through a one health lens ..... 1
Background ..... 1
Parasites of Coyotes ..... 2
Cardiopulmonary parasites of coyotes ..... 2
*Dirofilaria immitis* (Heartworm) ..... 2
*Angiostrongylus vasorum* ..... 4
*Paragonimus kellicoti* ..... 5
Other Lungworms ..... 6
Hemoparasites ..... 6
*Hepatozoon* ..... 6
*Trypanosoma cruzi* ..... 8
*Babesia* ..... 10
Gastrointestinal parasites ..... 11
*Echinococcus* ..... 11
Other gastrointestinal parasites ..... 13
Miscellaneous parasites ..... 14
*Toxoplasma gondii* ..... 14
*Trichinella* ..... 15
Viruses of Coyotes ..... 17
Rabies Virus ..... 17
Canine Distemper Virus ..... 18
Canine Parvovirus ..... 19
Bacterial Diseases of Coyotes ..... 20
*Leptospira* ..... 20
*Borrelia burgdorferi* ..... 22
Conclusion ..... 25
References ..... 26
CHAPTER I *Hepatozoon* spp. infection in wild canids in the eastern United States ..... 47
Abstract ..... 48
Background ..... 49
Methods ..... 50
Results ..... 51
Discussion ..... 53
Conclusion ..... 56
References ..... 57
Appendix ..... 60
CHAPTER II Prevalence and diversity of *Babesia* in the eastern United States ..... 65
Abstract ..... 66
Background ..... 66
Methods ..... 68
Results ..... 69
Discussion ..... 71

Conclusion ..... 73
References ..... 74
Appendix ..... 78
CHAPTER III ..... 82
Health survey of southeastern coyotes ..... 82
Abstract ..... 83
Background ..... 83
Materials and Methods ..... 84
Sample collection ..... 84
Autopsy ..... 84
Serology ..... 85
Molecular Diagnostics ..... 85
Parasitology ..... 86
Results ..... 87
Autopsy ..... 87
Histopathology ..... 87
*Urinary system:* ..... 87
*Pulmonary:* ..... 88
*Dermatologic:* ..... 88
*Gastrointestinal:* ..... 89
*Musculoskeletal:* ..... 89
*Miscellaneous:* ..... 89
Serology and Molecular Diagnostics ..... 90
*Leptospirosis:* ..... 90
*Toxoplasma gondii:* ..... 90
*Trypanosoma cruzi:* ..... 90
*Distemper (CDV):* ..... 90
*Parvovirus (CPV):* ..... 91
*Idexx 4dx SNAP tests:* ..... 91
*Ticks:* ..... 91
*Fecal flotation:* ..... 91
Discussion ..... 92
Autopsy and Histopathology ..... 92
*Leptospira:* ..... 92
*Trichinella:* ..... 92
Virology ..... 93
*Trypanosoma* ..... 93
Ticks and Tick-borne Diseases ..... 94
Fecal Flotation ..... 95
Limitations ..... 96
Conclusion ..... 96
References ..... 97
Appendix ..... 103
CONCLUSION ..... 114

Urban wildlife make excellent sentinels for diseases of human and animal concern. 114
References ..... 116
VITA ..... 117

# LIST OF TABLES

Table 1. Prevalence of *Hepatozoon* spp. in wild canids ..... 60
Table 2. Prevalence of *Babesia* spp. infections in the eastern United States..... 78
Table 3. PCR Protocols..... 103
Table 4. Histopathologic lesions found in coyotes ..... 104
Table 5. Serology results from coyotes from TN and SC..... 105
Table 6. PCR results from coyotes from TN and SC..... 105
Table 7. Fecal flotation results from coyotes from Tennessee (TN) and South Carolina (SC) ..... 106
Table 8. Tick species collected from coyotes from TN and SC ..... 106

# LIST OF FIGURES

Figure 1. *Hepatozoon* prevalence map..... 61
Figure 2. *Hepatozoon americanum* cysts..... 62
Figure 3. Inflammation associated with *Hepatozoon* spp. infection..... 63
Figure 4. Phylogenetic tree of *Hepatozoon* spp. in coyotes..... 64
Figure 5. Phylogeny of partial 18S Babesia sequences ..... 79
Figure 6. Phylogeny of partial cox1 babesia sequences ..... 80
Figure 7. *Hepatozoon procyonis* photomicrographs from raccoons..... 81
Figure 8. Sampling locations of coyotes..... 107
Figure 9. Nephritis and cystitis in coyotes..... 108
Figure 10. *Paragonimus kellicotti* cysts in a coyote..... 109
Figure 11. Photomicrographs of *Paragonimus kellicotti* in a coyote ..... 110
Figure 12. Parasitic pulmonary changes in coyotes..... 111
Figure 13. Parasitic dermatitis in coyotes..... 112
Figure 14. Examples of parasites found in coyotes ..... 113

# INTRODUCTION: CRITICAL REVIEW OF COYOTE PATHOGENS THROUGH A ONE HEALTH LENS

## Background

The coyote (*Canis latrans*) is a generalist mesocarnivore found throughout North America. Though coyotes historically preferred the dry, open deserts and plains of the western United States, they have migrated as far south as Panama and across the eastern United States in the last several decades [1]. Their success is largely due to their adaptability and opportunistic nature, allowing them to take advantage of the deforestation and urbanization that opened up new habitats and led to a decline in competitors like wolves and mountain lions [2]. Coyotes have colonized rural, suburban, and urban areas as densely populated as New York City and Chicago [3,4]. Their expansion has not only led to ecological changes in their newly acquired habitats but has also increased human and domestic animal interactions with the species [5]. This is demonstrated not only from the increased reports of coyote sightings but also from the distinct genetics of eastern coyotes, which often contain high levels of domestic dog and wolf DNA [6,7]. The hybridization of coyotes with dogs and wolves has impacted both physical and behavioral characteristics with the hybridized eastern coyotes growing to larger sizes and utilizing a larger home range [8,9]. With thriving populations and a range expansion over twice that of any other North American carnivore, coyotes have become ubiquitous throughout the eastern United States [1].

The impact of coyotes on their new eastern environment is not yet clear. They have replaced wolves and mountain lions as the top mammalian predator in many eastern states, and therefore fill many of the same ecological roles [2]. Some researchers hypothesize increasing predator abundance will decrease rodent activity, thereby leading to fewer tick-borne diseases [10,11]. Some suggest coyotes will compete with other predators, leading to no effect or even increased rodent density [2,5]. Other researchers sharply oppose frameworks that assume coyotes will have a broad impact in either direction on the abundance of ticks and tick-borne disease [12]. Currently, the role of coyotes' expansion on diseases of veterinary and human health importance in the eastern United States is unclear. Further investigation is vital to understand their impact.

Sentinel surveillance is a form of data collection that focuses on a specific species or subgroup to improve detection rates or the cost-effectiveness of surveillance [13]. What characteristics create a good sentinel depends on the purpose of surveillance and the disease system involved, and there are no agreed-upon attributes of a sentinel. In some cases, like the classic canary in the coal mine, a rapid and obvious response to disease is desired. This type of sentinel is important when swift detection of a threat is necessary. In other cases, sentinel characteristics are based on the cost-effectiveness of surveillance. Ideal sentinel species in these cases are species that are widely distributed, easily sampled, and have a high likelihood of exposure to pathogens of interest [13].

Coyotes act as cost-effective sentinels for diseases of wildlife, domestic animal, and public health importance. Their status as scavengers increases their exposure to a variety of diseases via the bioaccumulation effect and consumption of a wide variety of

plants and animals [13]. Their close genetic relationship to domestic dogs means that they are suitable hosts for most of the diseases that impact dogs and are therefore good markers for general risk. Veterinarians can use the prevalence of disease in coyote populations to better understand the risk in their area and to educate pet owners. In addition, conflict between coyotes and domestic animals occurs frequently in areas where the two intersect [14]. Coyotes may use domestic cats and small dogs as food sources, and some studies have found free-roaming cat abundance as much as 300 times lower in areas with coyotes [15]. Coyote conflict with dogs or humans appears less common than in cats, but there are still dozens of reports of conflict every year [6,16]. Therefore, in addition to serving as sentinels for diseases of veterinary and human health importance, coyotes may also serve as sources of infection for people or pets during times of conflict. A thorough understanding of these diseases is vital for doctors and veterinarians to properly educate and assess their patients. The remainder of this review seeks to condense the primary infectious agents of concern in coyotes.

## Parasites of Coyotes

### Cardiopulmonary parasites of coyotes

#### *Dirofilaria immitis* (Heartworm)

In the United States, heartworm disease is caused by the filarial nematode *Dirofilaria immitis.* Vectored by numerous mosquito species, *D. immitis* is found most frequently in the southeastern United States, though it is present in every state [17].

**Lifecycle:** The lifecycle of *D. immitis* is complex [18]. Canids, both wild and domestic, are the definitive host for *D. immitis,* and may act as both reservoirs and sentinels for the disease [19–25]. Canids are infected via the bite of a mosquito, which deposits L3 larvae into the bloodstream during feeding. These microfilariae will live in the bloodstream as they undergo two more molts into L4 larvae and adults. Adults live in the pulmonary arteries and right heart where they reproduce. Females produce microfilaria which are found in the peripheral blood. If a mosquito takes a bloodmeal from a microfilaria-positive dog, the microfilaria will travel to the mosquito's midgut where they develop from L1 to L3 larvae. The L3 larvae are the infectious stage of the disease. Complicating this lifecycle is the presence of *Wolbachia*, bacterial endosymbionts that can elicit their own inflammatory response in dogs in addition to supporting the *D. immitis* they occupy [26].

**Clinical signs:** Heartworm disease remains a significant cause of respiratory and cardiac disease in domestic dogs and cats, despite the availability of safe and effective preventions. Signs can range from asymptomatic, particularly in early infections, to sudden death due to thromboembolic events [18]. Chronic cough and exercise intolerance are common in affected dogs, and radiographs often show evidence of eosinophilic infiltrates and right-sided heart enlargement. Pulmonary venous distension may also occur. Histopathology of the lungs may reveal inflammatory infiltrates, intimal proliferation, fibrosis, and thrombi [27,28].

**Diagnosis:** If carcasses are available, presumptive diagnosis is made via visualization of adult worms in the pulmonary arteries and right heart. Females are 25-31cm long with a tapered tail, and males are 12-20cm long with a corkscrew-shaped tail [18]. Antemortem, diagnosis can be achieved with a combination of commercially available antigen tests and assessment of blood for microfilaria via a Knott's test [18]. The in-house tests assess for the presence of the female worm's uterine antigen, so false negatives may occur in immature (<6 months) or male-only infections. Microfilaria tests similarly may give false negatives in the case of single sex infections. False positives may occur on Knott's analysis if the examiner does not assess morphology to distinguish *D. immitis* from other, less pathogenic infections, particularly *Acanthocheilonema reconditum* [29]. PCR of blood can be done to confirm species.

***Dirofilaria immitis* in coyotes:** The role of coyotes in the parasite's epidemiology is not fully understood, particularly as coyotes' range expands. However, coyotes are considered an important reservoir for *D. immitis*. Prevalence in coyotes varies depending on the state, with infection sometimes exceeding 50% in the south [22,30]. The average worm burden in coyotes is variable, with most studies finding less than two dozen adult worms in a typical infected coyote, though one study found as many as 176 adult worms [31].

There has been one report of fatal disease in coyotes. A coyote from South Carolina was found dead, and autopsy revealed a ruptured aortic aneurysm secondary to heartworm infection [32]. Other reports of significant clinical signs due to heartworms are rare in coyotes. However, histopathology can show similar lesions to what is found in affected dogs including villous intimal proliferation, subintimal fibrosis, alveolar epithelialization, thromboembolisms, hemosiderosis, and periarterial inflammation [28,31].

Despite the availability of safe and effective prevention, cases of canine heartworm disease have been increasing [33,34]. It is possible that this increase can be attributed to improved screening and diagnosis. However, a survey in Chicago from 2001 to 2016 documented an increasing prevalence of *D. immitis* in coyotes not impacted by increases in testing [35]. The cause of this rise is likely multifactorial, with expansion of mosquito's abundance and range due to climate change and urbanization likely playing a primary role [36]. Studies have documented that the presence of even one heartworm-positive dog is enough to significantly increase the prevalence of *D. immitis* larvae in mosquitos in the area [37]. As coyotes continue to move into urban and suburban areas, prevalence of *D. immitis* in peridomestic mosquitos will likely rise in kind, increasing the risk to dogs and cats.

Understanding trends in prevalence is challenging in domestic dogs due to the numerous variables like use of preventative medicines, veterinary care, and which diagnostic tests were employed. However, surveillance in coyotes can provide true temporal trends and accurate estimates of transmission rates. In addition, prevalence in coyotes makes an excellent proxy for the risk to companion animals and can be used by veterinarians to encourage their clients to continue using prevention. Further work is necessary to understand how and why heartworm infection is increasing in the United States.

***Angiostrongylus vasorum***

*Angiostrongylus vasorum,* or the French heartworm, is a metastrongylid nematode known to infect the cardiopulmonary system of canids [38]. Foxes are the primary definitive host, but domestic dogs and coyotes are also susceptible. It is considered one of the most pathogenic parasites in dogs. Other mammals can serve as atypical hosts, including red pandas (*Ailurus fulgens*), Eurasian otters (*Lutra lutra*), and meerkats (*Suricata suricatta)* [39–41]. Native to South America, Africa, and Europe, the parasite has recently been introduced to North America and is now endemic in Newfoundland, Canada [38]. The range of *A. vasorum* has expanded in North America in recent years with cases reported on Prince Edward Island and Nova Scotia [42,43]. There have been two recent reports of the parasite in the United States with a fox from West Virginia in 2014 and two cases in Tennessee, one in a bear and one in a coyote in 2022 [44, unpublished data from Gerhold lab].

**Lifecycle:** The life cycle of *A. vasorum* is complex and relies on gastropods as intermediate hosts [45]. Canids become infected when they ingest L3 larvae inside a slug or snail. In addition, there is some evidence that frogs may serve as either intermediate or paratenic hosts [46,47]. The larvae then penetrate the gut tissue and travel through the portal vasculature to the pulmonary arteries and right ventricle. Worms mate and lay eggs which lodge in the pulmonary capillaries. Larvae will hatch from the eggs where they are coughed up and swallowed before being passed in the feces. The prepatent period in dogs is between one and three months, and adult worms can live as long as 5 years [48].

**Clinical signs:** Clinical signs in both dogs and coyotes can range from mild to fatal. Interstitial and granulomatous pneumonia leading to chronic cough, dyspnea, and weight loss are common. Intimal proliferation, similar to *D. immitis* infection, may develop in pulmonary vasculature [38]. In addition, vascular events like pulmonary thromboembolism may occur, leading to sudden death. Canids that survive early infection will eventually develop right-sided congestive heart failure [49]. Infection can also lead to coagulopathies and severe hemorrhage, typically due to disseminated intravascular coagulation [50]. Rarely, this uncontrolled hemorrhage may be the primary clinical sign without evidence of respiratory distress [51].

**Diagnosis:** Diagnosis can be achieved in several ways. Larvae may be shed in the feces and identifiable on Baermann tests or fecal floatation. Larvae can be distinguished from other metastrongylid parasites by their kinked tail and dorsal spine. *Crenosoma vulpis,* another metastrongylid lungworm of canids, has a smooth-tapered tail with no kink, and *Oslerus [Filaroides] osleri* have a small kink but no dorsal spine [52]. The larvae cannot be distinguished the cat lungworm, *Aelurostrongylus abstrus,* but this pathogen has not been documented in coyotes. Radiographic evidence shows alveolar to mixed patters in the peripheral lung fields [53]. On histopathology, the lungs typically contain solidified masses of plasma cells and macrophages with occasional thrombi and granulomas surrounding eggs and larvae [54]. Adult worms can be identified in the right heart or pulmonary arteries, although they are small (around 14-20mm by 0.2-0.3mm) and easy to miss unless a thorough examination of the heart and pulmonary arteries is performed [38].

***Angiostrongylus vasorum* in coyotes:** Reports in coyotes are rare but will likely become more common as the parasite continues to spread into North America. The first published report in a coyote in North America was in 2005 where *A. vasorum* was found in a road killed coyote in Newfoundland [42]. The coyote suffered the typical granulomatous pneumonia with intralesional nematode eggs and larvae, and it had adult *A. vasorum* in its pulmonary arteries. In addition, granulomas containing nematode eggs and larvae were also found in its brain and kidneys. The second report in coyotes was in Nova Scotia, Canada [55]. This study surveyed helminths from the trachea, heart, and lungs of 284 coyotes and found four infected (1.4%). Finally, there has been one report of *A. vasorum* in a coyote in Tennessee, United States in 2022 (unpublished data from Gerhold lab). This coyote was trapped as part of a predator control program by the state wildlife agency and submitted for autopsy, where the lungs were firm and mottled with numerous *Paragonimus* spp. cysts within the lung lobes. Histopathology also revealed granulomatous and eosinophilic pneumonia with intralesional metastrongylid eggs and larvae that were identified as *A. vasorum* via PCR. The rapid expansion of *A. vasorum* from its initial introduction to Newfoundland until present means further expansion is likely. Coyotes can serve as sentinels for the spread of this often-lethal canid parasite, and surveillance is vital to help prepare veterinarians for the likely spread of this pathogen.

### *Paragonimus kellicoti*

*Paragonimus* is a genus of trematode parasites that infects the lungs of a wide variety of mammal species including humans [56]. In the United States, *P. kellicotti* is the only species known to occur. Adults reside within cysts in the pulmonary parenchyma of definitive hosts, typically in pairs. Mink (*Mustela vision)* are considered the primary definitive host, but many other mammals including domestic and wild cats, domestic and wild canids, raccoons (*Procyon lotor)*, skunks (*Mephitis mephitis*), mustelids, and humans can maintain patent infections [56].

**Lifecycle:** Large, operculated eggs are shed in the feces of definitive hosts, and miracidium slowly develop inside the eggs over the course of several days to weeks. If rain or flooding washes the feces into water, the miracidium can fully develop and hatch, where they infect freshwater snails. Inside the snail, they develop into cercaria, which leave the snail and penetrate their second intermediate host, crayfish. The cercaria develop into the infectious metacercaria stage within crayfish. If a susceptible definitive host consumes an infected crayfish, the metacercaria will penetrate the intestine and diaphragm, enter the lungs, and slowly mature into adult flukes over the course of one month [56].

**Clinical signs:** Clinical disease can range from asymptomatic to severe. In dogs and cats, coughing is the most common sign, though wheezing, hemoptysis, anorexia, vomiting, and sudden death have been reported [56–59]. The cough is typically chronic and has been reported to last for up to a year. Acute respiratory distress can also occur and is usually associated with pneumothorax [60].

**Diagnosis:** Definitive diagnosis is made by visualization of the distinctive eggs in the feces. Eggs are large and operculated, ranging from 80-100 µm long and 50-60µm wide [56]. In addition, radiographic findings are often distinct, with multiple multiloculated, thin-walled cysts ranging from 2-5cm in diameter that are often referred to as "links of chain" [60]. The nodules may appear solid rather than cystic early in the course of infection. Gross examination of the lungs will reveal firm, distinct cysts, and the flukes are easily visualized within the cut section of the cysts.

***Paragonimus* in coyotes:** Reports in coyotes are rare compared to mink, which frequently have infection rates of greater than 20% [61,62]. There have been four reports in coyotes: one autopsy survey in Ontario that found a 3.2% prevalence (1/31), an autopsy survey in Illinois that found a 2.3% prevalence (8/347), a fecal floatation survey in Alberta that found a 0.43% prevalence (2/460), and a fecal flotation survey in Florida that reported a 6.7% prevalence (6/90) [63–66]. It is unclear whether the lower prevalence in coyotes is due to lower susceptibility, differences in diet between coyotes and smaller mesocarnivores, or a lack of surveillance in coyotes. Further evaluation of coyotes, particularly in areas near water or prone to flooding, may help elucidate this discrepancy.

## Other Lungworms

In addition to *A. vasorum* and *P. kellicotti,* coyotes are susceptible to many other lungworms including *Capillaria* spp, *Crenosoma vulpis,* and *Filaroides [Oslerus] osleri* [64,67,68]. The latter nematode is easily diagnosed via visualization of small worms within nodules in the trachea or bronchi. *Capillaria* species have easily identifiable eggs with asymmetric bipolar plugs that can be found on fecal float, while *C. vulpis* shed L1 larvae in the feces. *Crenosoma vulpis* is also known as the fox lungworm. Unlike *A. vasorum, C. vulpis* is found in the bronchioles and bronchi rather than the heart and pulmonary arteries [69]. Most infections in coyotes are asymptomatic and discovered incidentally on fecal floatation or autopsy [64,67]. However, like most parasites, at high levels of infection or in immune-compromised animals, infection can lead to severe and life-threatening pneumonia.

## Hemoparasites

### *Hepatozoon*

*Hepatozoon* is a genus of apicomplexan parasite that can cause musculoskeletal disease in a variety of mammals. In canids, the two species of concern are *H. canis* and *H. americanum.*

**Lifecycle:** The lifecycle of this parasite is unique, with the tick vector serving as the definitive host and the canid as the intermediate host. Canids become infected after ingestion of sporulated oocysts in the tick, *Rhipicephalus sanguineus* in the case of *H. canis* and *Ambylomma maculatum* in the case of *H. americanum* [70]. Alternate pathways

of infection including vertical transmission of *H. canis* and ingestion of *H. americanum* cystozoites via predation of small mammals are suspected to play an important role in transmission as well [71,72]. After ingestion, the sporozoites enter host tissues and undergo merogony. Merozoites are released from meronts in the host and enter leukocytes where they transform into gamonts. If a susceptible tick feeds on the infected canid, gametogenesis and sporogony will occur within the tick [70].

Geographic distribution differs between the two species. *Hepatozoon canis* has been documented worldwide, likely because of the wide range of its vector, the brown dog tick (*R. sanguineus*). It was not documented in the United States until 2008, and has only been reported sporadically since then [73,74]. *Hepatozoon americanum* is more common in the United States, though geographically restricted to the range of the Gulf Coast tick (*A. maculatum*), which historically was found in a limited area surrounding the Gulf Coast. First discovered in 1978 in coyotes in Texas, *H. americanum* has since been reported in fourteen states: Alabama, California, Georgia, Kentucky, Mississippi, Nebraska, North Carolina, Oklahoma, Texas, Vermont, Virginia, and Washington [74–76]. The Gulf Coast tick has expanded in recent years and has now been documented in states as north as Delaware and Illinois [77,78]. The range of *H. americanum* will likely follow its vector, making it an emerging threat in many states.

**Clinical Signs:** The two species of *Hepatozoon* in canids differ in numerous ways including definitive host, tissue tropisms, clinical signs, histologic appearance, genetic sequences, and geographic distribution. *Hepatozoon canis* is often asymptomatic but can lead to fever, malaise, and anemia, particularly in cases of immunosuppression or co-infection with other blood pathogens [70,79,80]. *Hepatozoon americanum* leads to more severe disease, causing myalgia, muscle wasting, fever, and often death in affected dogs [81]. It can cause a distinctive periosteal proliferation, particularly around the long bones, which can help increase the clinical suspicion if seen on radiographs [81].

**Diagnosis:** Diagnosis can be achieved via visualization of gamonts in leukocytes, PCR of blood or tissue, or histology. Parasitemia is different between the two species, with up to 100% of neutrophils containing gamonts in *H. canis* infections, while as few as 0.1% of neutrophils contain gamonts in *H. americanum* infections [82]. Due to *H. americanum*'s low parasitemia in the blood, histology is considered the gold standard for diagnosis. For *H. canis* infections, merogony usually occurs within the spleen or bone marrow and most often appears as a "wheel-spoked" configuration in the tissue which consists of twenty or more zoites formed in a circle [83]. *Hepatozoon americanum*, however, prefers the heart and skeletal muscle for merogony and forms an "onion skinned" configuration with concentric strata of mucopolysaccharide-rich material surrounding the parasitized cells. PCR can also screen blood or tissue for infection. Studies in wildlife have shown that PCR is able to diagnose the majority of infections, and some PCR-positive animals may have no cysts on histology [76]. The combination of both PCR testing and histology has the greatest sensitivity for diagnosing infection.

***Hepatozoon* spp. in coyotes:** Coyotes appear to play a significant role in the maintenance of *H. americanum* in the United States. Studies in the south-central United

States have found PCR prevalences greater than 75% in apparently asymptomatic coyotes [76,84,85]. To date, no studies outside of the southern-central U.S. have been conducted, so prevalence in coyotes in the eastern United States is unknown. Mild myocarditis and myositis have been reported in infected coyotes, and experimental infections demonstrated that coyotes can experience the osteoproliferation common in domestic dogs, but no studies have reported adverse clinical signs or fatalities in free-ranging coyotes [85,86]. One experimental infection found that periosteal lesions and muscle granulomas were more common in juvenile coyotes than adult coyotes infected with the parasite, though the average number of muscle cysts did not differ between ages [86].

Molecular studies have found numerous sequences of the 18S rRNA gene in individual animals, which may represent paralogues or mixed infections [84]. In addition, some studies have demonstrated mixed infections with both *H. americanum* and *H. canis* species [76,87]. Phylogenetic analysis shows that there are intermediary sequences that are more closely related to *H. americanum* than *H. canis* but do not resolve into the *H. americanum* clade [76]. Differences in virulence or muscle lesions between these strains have not yet been established.

Hepatozoon is still a rare diagnosis in domestic dogs in the United States, but it is unclear whether that is because the disease is truly rare or because veterinarians are unfamiliar with the parasite, clinical signs can be vague, and diagnosis is challenging. The true prevalence and geographic spread of this parasite is still unclear, and further surveillance in wild canids, particularly in the eastern U.S. and areas where the Gulf Coast tick is newly endemic, is vital. Rural dogs with poor access to veterinary care are more likely to be infected than city or suburban dogs. Therefore, case reports are likely an underestimate of the true prevalence of this pathogen in the dog population. Since coyotes are infected at higher rates than domestic dogs, they can serve as markers for disease spread and relative risk.

***Trypanosoma cruzi***

*Trypanosoma cruzi*, the protozoan agent of Chagas disease, is a zoonotic pathogen that can affect both humans and domestic animals. This parasite is spread via triatomine vectors and historically has been found in the tropical climates of Central and South America. However, endemic cases have been reported in domestic dogs and humans in the southern United States [88,89]. *Trypanosoma cruzi* has been divided into seven discrete typing units (DTU I-VI and TcBat), which vary in their geographic range and host susceptibility [90].

**Lifecycle:** Transmission can occur via numerous routes. Classically, the parasite is spread when trypomastigotes from the vector's feces enter the bite wound of a susceptible host. This route is often referred to as stercorarian transmission [91]. However, other methods including contamination of food sources with triatomine feces, congenital, and blood or organ donation are possible. In animals, oral ingestion of the triatomine bugs themselves may play an important role [92]. Once inside the host, trypomastigotes travel through the bloodstream to a variety of organs, particularly the

heart and gastrointestinal tract, and transform into amastigotes. These amastigotes will undergo asexual replication within the tissue, and eventually transform back into trypomastigotes and enter the bloodstream, where they can be ingested by a feeding triatomine bug [93].

**Clinical signs:** There are three phases of infection: acute, latent, and chronic. In the acute phase, signs of inflammation including malaise, lymph node enlargement, decreased capillary refill time, and hepatosplenomegaly may occur [94]. Acute cardiomyopathy may also occur during this phase. Symptoms typically begin about two weeks post infection and last up to a month. The majority of both canines and humans are asymptomatic or mildly symptomatic during this phase [91,94]. Latent infection may last for months in canids or decades in humans. In humans, about 10-30% of cases will eventually progress heart failure or gastrointestinal dysfunction [95]. The likelihood of progression to chronic disease is not known in dogs, but a small percentage will eventually develop dilated cardiomyopathy and chronic myocarditis between 8 months and 1.5 years after exposure [94]. Arrythmias and heart failure can lead to exercise intolerance, ascites, hepatomegaly, or sudden death. To date, there have been no reports of clinical illness in coyotes.

**Diagnosis:** Diagnosis can be done via serology, histopathology, or molecular detection. Though there is no laboratory validated test in wildlife, both IFA and commercially available immunochromatographic tests (ICT) have been used in dogs and coyotes for antibody detection [88,96]. PCR is the preferred method for detection of active infection. It can be performed on blood, although testing of heart tissue is more sensitive once the acute phase of infection has passed. There are numerous ways to assess DTU, with multiplex PCR assays and sequencing of certain informative areas of the genome the most common [97,98]. Recent work in raccoons demonstrated that coinfection with numerous different DTUs is common, and therefore deep sequencing may be required to fully assess infection [99].

***Trypanosoma cruzi* in coyotes:** Though this disease is rare in humans in the United States, it is frequently found in wildlife. Raccoons and opossums have the highest prevalence, with over 50% positive via serology or PCR in southern states like Texas and Louisiana [100,101]. Numerous other wild mammals in the United States have been shown to harbor infection including striped skunks (*Mephitis mephitis)*, nine-banded armadillos (*Dasypus novemcinctus)*, wood rats (*Neotoma* spp.), red and gray foxes (*Urocyon cinereoargenteus* and *Vulpes vulpes*), bobcats (*Lynx rufus),* and feral swine (*Sus scrofa*) [102].

Coyotes can carry this parasite as well, though at lower rates than raccoons. Unsurprisingly, southern states have a higher prevalence, with Texas having almost double the seroprevalence (12.8-14.3%) of the most northern state assessed, Virginia (3.8%) [103,104]. Infection is associated with few clinical signs in coyotes, although studies differ in whether lymphoplasmacytic myocarditis is more likely in infected coyotes [97,100]. Coyotes usually carry a different strain than raccoons. Raccoons carry DTU IV almost exclusively, while coyotes typically carry DTU I [97]. This matters because the majority of autochthonous human cases in the United States that have been typed were DTU I [105]. Therefore, although raccoons are one of the most important

reservoirs in the sylvatic lifecycle of the parasite, coyotes and other mammals that typically carry DTU I like Virginia opossums provide more information on the risk for human infection. Though raccoons have the highest prevalence, if they rarely carry the genotype associated with most human infections, they may play little role in the disease's emergence. However, species like coyotes that carry genotypes more commonly associated with human infection may be better indicators of human risk, even though their relative prevalence is lower. Further work to assess the DTU and geographic distribution of infection in coyotes is important to fill in these knowledge gaps, particularly since research outside of Texas and Oklahoma is lacking.

***Babesia***

*Babesia* is a genus of apicomplexan parasites that live in erythrocytes. Before molecular tests were widely available, *Babesia* was classified based on its size into large (2.5-5μm) *Babesia* species (referred to as *Babesia canis* in dogs) and small (<2.5μm) *Babesia* species (referred to as *Babesia gibsoni* in dogs). With the improvement of molecular tests, it has become clear that there are at least five species that infect canids in the United States: three small *Babesia* species consisting of *B. conradae, B. gibsoni, B. vulpes,* and two large *Babesia* species consisting of *B. vogeli* and *Babesia* sp. "Coco" [106]. *Babesia vulpes* has historically also been referred to as *B. microti*-like, *Theileria annae,* and *B. gibsoni,* and *B. vogeli* was historically considered *B. canis* and is sometimes still referred to as *B. canis vogeli* [106]. Although other species of *Babesia* can infect humans, none of the canid pathogens are known to be zoonotic. However, they are important pathogens in domestic dogs and wildlife that can cause severe clinical signs and even death.

**Lifecycle:** *Babesia* spp. are vectored by ticks, although the tick vector is not known in all cases. *Rhipicephalus sanguineus* vectors *B. vogeli,* and *Haemaphysalis longicornis* vectors *B. gibsoni.* The tick vector for *B. vulpes, B. conradae,* and *Babesia* sp. "Coco" are not known in the United States, though *Amblyomma americanum* is the suspected host for the latter [107]. After a canid is bitten by an infected tick definitive host, the *Babesia* organisms travel to the capillaries, infect red blood cells, and undergo asexual reproduction via binary fission [106]. Eventually the piroplasms rupture out of the erythrocytes, at which point a tick that ingests the infected blood can become infected.

In addition to ticks, *Babesia* can also be spread through blood transfusion, dog fighting, and vertically via the placenta. Dog fighting is an important route of transmission for *B. gibsoni,* which was maintained via dog fighting rings in the United States even before the introduction of a competent tick vector [108]. Bite wounds may also be an important transmission method for *B. conradae,* which has been found primarily in coyote-hunting dogs and coyotes in the western United States [109,110].

**Clinical signs:** Clinical signs vary from asymptomatic to lethal. Some species of *Babesia* only cause signs in immunocompromised dogs. For example, all known cases of

clinical *Babesia* sp. “Coco” have occurred in dogs lacking a spleen or undergoing chemotherapy [107]. Typical changes include splenomegaly, enlarged lymph nodes, anorexia, and lethargy. There may be evidence of icterus and hemoglobinuria as well [107]. Bloodwork may be normal or show evidence of azotemia and thrombocytopenia with or without intravascular hemolytic anemia. Severe cases may present in shock or even acute death [106].

**Diagnosis:** Diagnosis can be achieved via blood smear evaluation, PCR, or serology. Historically, discovering piroplasms in erythrocytes was the primary method of diagnosis. However, this method has several drawbacks including low levels of visible piroplasms in the smear and the potential misdiagnosis of cytologic artifact as piroplasms. PCR, which is both sensitive and specific, has become the predominant method in recent years. Serology, typically IFA, is available for common *Babesia* species, though it is rarely relevant in acute disease due antibody lag time [106].

***Babesia* spp. in coyotes:** Only two of the five pathogens that affect canids in North America (*B. conradae* and *B. vogeli*) have been documented in naturally infected coyotes, though coyotes have been shown to be susceptible to *B. gibsoni* in experimental infections [110–112]. Despite their close relationship with domestic dogs, which can be infected with all five species, there is no evidence of *B. vulpes* or *Babesia* sp. “Coco” in coyotes. However, these pathogens are rare in domestic canids, and few surveys have been done in coyotes outside of California. Therefore, the true prevalence and diversity of *Babesia* in coyotes is unclear. Thus far, no clinical signs have been reported in coyotes, despite the severe symptoms that *B. conradae* can cause in domestic dogs. Surveys in United States, particularly outside of California, are vital to better understand the disease ecology of these parasites.

## Gastrointestinal parasites

### *Echinococcus*

*Echinococcus* is a zoonotic genus of cestode parasites that occurs globally. Canids are the primary definitive hosts, and intermediate hosts can range from small rodents to cervids. The parasite causes at least 19,000 deaths and 871,000 disability adjusted life years annually according to the WHO [113]. In addition, carcass condemnation and impaired growth in infected livestock costs an estimated $2 billion every year [114]. In humans, the fatality rate can reach up to 70% if left untreated [115]. There are two main species of concern: *E. granulosus*, the cause of cystic echinococcosis, and *E. multilocularis*, the cause of alveolar echinococcosis.

Historically, this disease has been restricted to the mid-northern states and occasional outbreaks in sheep farmers in the western U.S. However, there is evidence that the disease is expanding to new states and territories [116–118]. Little is known about the extent of this geographic expansion, or the potential impact it may have on wildlife, domestic animals, and humans. In recent years, there has been an increase in *Echinococcus* cases in endemic areas like Switzerland, which has seen a doubling of its

annual cases, as well as an expansion into new territories [119]. Veterinarians in Canada diagnosed a case of alveolar echinococcus in a canine patient in British Columbia, a province not known to have *Echinococcus* in 2009 [118]. Molecular diagnostics revealed that the dog was infected with the European strain, suggesting the disease was imported. Since then, at least three other dogs have died from the parasite in British Columbia. Human cases historically follow animal cases, and Canada was no exception. In the fifty years between 1950 and 2000, there were only three locally acquired human cases, but at least six locally acquired human cases were reported between 2016 and 2019 [117,120]. The case rate in Canada is now on-par with that of endemic countries in Europe.

The United States has similarly seen an expansion of the range of the parasite. Elk were transported from Alberta to the Cumberland Wildlife Management Area as part of a reintroduction program in Tennessee from 2000-2008. A retrospective study examining banked histology slides found four elk PCR positive for *Echinococcus canadensis,* a subtype of *E. granulosus* [116]. One of the elk was believed to have been born in the park, suggesting a sylvatic life cycle has been established. In addition, a Virginia dog that was born in Mississippi but had no other travel history was diagnosed with alveolar echinococcus in 2018 [121].

**Life cycle:** Canids shed the thick-walled eggs of *Echinococcus* in their feces, which are immediately infectious upon ingestion. A wide variety of mammals, including humans and canids, can serve as intermediate or dead-end hosts. Once a susceptible host ingests the eggs, oncosphere larvae from the egg will penetrate the intestinal wall and travel to a variety of organs, primarily the liver and lung [122]. From there, they will develop into metacestode larvae, either in hydatid cysts in the case of *E. granulosus* or alveolar cysts in the case of *E. multilocularis.* These cysts can grow and develop over the course of months to years. If a canid predates the infected animal and ingests the cysts, the larvae will develop into adults within the small intestine, mate, and produce eggs.

**Clinical signs:** Clinical signs vary by species. In *E. granulosus,* the cysts act as space occupying masses but do not directly efface the organs they occupy. Therefore, clinical signs are related to the pressure of the enlarged organs pressing on surrounding tissues. In addition, anaphylactic shock can result when cysts rupture [122]. Alveolar *Echinococcus* (*E. multilocularis*) on the other hand, acts almost like a cancer, directly invading and destroying surrounding tissues. It also can spread to distant organs including the brain, and clinical signs will depend on the location of the cysts. In definitive hosts, clinical signs are rare, though mild vomiting or diarrhea can occur. Rarely, dogs can act as both definitive and intermediate hosts. In those cases, they may have severe vomiting and weight loss, or may even present with sudden death [118,121].

**Diagnosis:** Currently, diagnosis of the disease in intermediate hosts requires either autopsy or ultrasound with aspiration of cystic material. Diagnosing definitive hosts can also be a challenge, since the eggs of *Echinococcus* sp. are identical in appearance to *Taenia* eggs, a much more common cestode in the United States. PCR of feces, or fecal floatation followed by PCR, is one of the most common methods of diagnosis. However, the proglottids of cestodes must break down for eggs to be shed in feces, making the fecal float technique a poorly sensitive diagnostic. Autopsy with sieving of the intestinal contents and examination under a microscope is the gold standard

for diagnosis in definitive hosts. A sensitive and specific serologic test is a much-needed diagnostic tool to better assess the spread of this parasite.

***Echinococcus* in coyotes:** Coyotes are definitive hosts for this parasite and are important sentinels for the geographic spread of *Echinococcus. Echinococcus granulosus* has been present in the wolf, coyote, and ungulate population for decades, particularly in the western and southwestern states [123–126]. Wolves are the primary definitive host in the sylvatic lifecycle of *E. granulosus*, particularly in the case of the northern biotype, *E. canadensis,* while coyotes are competent but less frequently infected [124]. Likewise, foxes were traditionally believed to be the primary definitive host of *E. multilocularis,* but high levels in coyotes have been documented in several Canadian provinces and in several northern US states, suggesting they may play a more important role than previously realized [123,126].

In the last several years, infections in people, pets, and wildlife have been found in states not known to harbor the parasite. *Echinococcus multilocularis,* for example, was believed to be endemic only to the northern tundra zone of Alaska and Canada for decades [123]. By the mid to late 1900s, *E. multilocularis* had been reported in six northern U.S. states: Montana, North and South Dakota, Iowa, Minnesota, and Alaska [127]. By the end of the twentieth century, *E. multilocularis* had been reported in nine US states, still primarily in the north with the exception of Nebraska [127]. Recently, researchers documented the European strain in coyotes in New York at a prevalence of 7%, increasing concerns of the spread of this variant [128]. To date, the species has been found in at least 13 US states, and that number is likely an underestimate due to the scarcity of research in wildlife [129]. With the recent emergence of the European strain of *E. multilocularis* causing deaths in both people and dogs, further work evaluating the spread as well as the genotype of this pathogen in coyotes and foxes is vital [117,121].

Cystic *Echinococcus* has historically been more widespread in the United States, with sylvatic and domestic cycles present in the western, midwestern, and Mississippi Valley states for decades [127]. Though coyotes are not the primary definitive host in states where wolves are present, recent emergence of the *E. canadensis* strain of *E. granulosus* into Tennessee, a state without wolves, proves that coyotes can maintain a sylvatic lifecycle in the absence of wolves [116]. Further work assessing *E. canadensis* in coyotes, particularly in states without wolves, can help elucidate the spread of this pathogen.

**Other gastrointestinal parasites**

Coyotes can carry virtually all intestinal parasites of domestic dogs including hookworms (primarily *Ancylostoma* and *Uncinaria* spp.), roundworms (*Toxocara canis, Toxascaris leonina,* and *Baylisascaris procyonis),* tapeworms (*Taenia* spp., *Dipylidium* spp., *Spirometra* spp., and *Diphyllobothrium* spp.), trematodes (*Alaria* spp., *Nanophyetus salmincola,* and *Eurytrema procyonis*), whipworms (*Trichuris vulpis*), the stomach worm (*Physaloptera* spp.), and protozoan parasites like *Cystisospora* spp., *Sarcocystis* spp., and *Neospora caninum.* Several surveys of intestinal parasites via either intestinal content examination or fecal floatation have been done in coyotes, with most finding parasites in

>80% of samples assessed [130–133]. The relative abundance of each species is dependent on the state and local geography.

Intestinal parasitism is generally asymptomatic in coyotes. However, *Ancylostoma caninum*, which can cause lethal anemia in pups, has been proposed as a potential population regulator in coyotes [134]. One study assessing the relative prevalence of parasites before and after a two-year period of coyote removal found that several parasite species including *A. caninum* were significantly lower after removal [135]. In addition, coyote populations are resilient to most lethal management techniques, likely due to a combination of compensatory breeding and immigration [136]. Therefore, lethal management strategies may have the opposite of the intended effect. Further studies assessing changes in parasite prevalence in response to management techniques are important to better guide local wildlife officials.

## Miscellaneous parasites

### *Toxoplasma gondii*

*Toxoplasma gondii* is a common zoonotic pathogen and is considered one of the most successful human parasites in the world [137]. Infecting an estimated 30% of the population, *T. gondii* has established itself in both humans and wildlife across the globe [138].

**Life cycle:** The lifecycle of *T. gondii* is complex, with numerous different stages including the oocyst, sporozoite, tachyzoite, and bradyzoite. Felids are the only definitive host for *T. gondii*, while virtually all warm-blooded animals can serve as intermediate hosts [139]. An infected cat will shed oocysts in its feces, which will sporulate and become infectious within one to two days [140]. Intermediate hosts can become infected by eating these sporozoites (or food contaminated with them) as well as by consuming tissue cysts (bradyzoites) present in other intermediate hosts [141]. Tachyzoites, or the fast-replicating phase of the parasite, are also infectious, with transmission occurring transplacentally or via transfusion or organ donation [142]. Once inside an intermediate host, the sporozoites or bradyzoites will transform into tachyzoites, which penetrate the host cell and undergo rapid division. Eventually, the tachyzoites rupture out of the host cell and can infect other cells or can develop into the chronic stage of the parasite: bradyzoites. Bradyzoites form tissue cysts within numerous different organs in the host, which can reactivate into tachyzoites if the host immune system is suppressed or if they are consumed by a different host.

**Clinical signs:** Clinical signs vary significantly depending on species, immune status, and life stage of the host. Cats acting as definitive hosts rarely have any clinical signs, though mild diarrhea is possible. Intermediate hosts, which can include cats, also frequently remain asymptomatic or experience only mild flu-like signs at the beginning of infection but minimal long-term consequences from the parasite. However, if the host is immune compromised or a highly susceptible species, infection can be fatal.

Tachyzoites are the phase responsible for clinical symptoms, and the duration and severity of illness depends on the hosts ability to suppress tachyzoite replication. There is no definitive tissue tropism for *T. gondii,* with the parasite able to cause a wide variety of symptoms including chorioretinitis, encephalitis, pneumonia, myocarditis, and hepatitis [143]. Abortion or fetal abnormalities are a common sequelae of infection while pregnant, though this is most common in humans and livestock [139].

**Diagnosis:** Since *T. gondii* is a lifelong infection, seropositivity is also a sign of active infection. Therefore, serology is the most used diagnostic method, particularly for wildlife surveys. The modified agglutination test (MAT) is considered the gold standard for serology, with titers ≥1:25 considered positive in mammals. PCR of brain or heart tissue can also be performed, though false negatives are likely except in cases of disseminated *T. gondii,* since cysts are often sporadically located. Visualization of tachyzoites or bradyzoites in the organs, particularly the brain or heart, can increase the index of suspicion.

***Toxoplasma gondii* in coyotes:** Seroprevalence of *T. gondii* in coyotes varies depending on the state sampled, with typical seroprevalence between 30-60% . Prevalence may be higher in the southern United States, with seroprevalence exceeding 90% in certain states [30]. Coyotes' omnivorous diets make them excellent sentinels for this pathogen since their exposure rate to both bradyzoites and sporocysts is high. Their seroprevalence is higher than other common wildlife species like white tailed deer, feral hogs, and raccoons [147]. However, they are more resistant to clinical disease with *T. gondii* than other carnivores, particularly mustelids and foxes [148]. Clinical symptoms are rare in coyotes, with most seropositive coyotes appearing clinically normal [30,145]. In fact, a review of *T. gondii* in wild canids in 2021 found no report of clinical *T. gondii* in coyotes within the last six decades [149]. Though other carnivores often experience clinical *T. gondii* alongside immune-suppression, particularly infection with canine distemper virus (CDV), there have been no reports of this phenomenon in coyotes. Their high seroprevalence in comparison to other animals makes them excellent sentinels, particularly in areas where prevalence is low, though the pathogen does not likely play a significant role in their population health.

### *Trichinella*

*Trichinella* is a genus of zoonotic nematode parasites that live in muscle cysts in their host. Though human infections have historically been associated with undercooked pork, cases related to wildlife, particularly from consumption of bear or walrus meat, do occur [150,151]. There are at least ten different genotypes of *Trichinella,* with some genotypes still debated [152]. *Trichinella spiralis* is the most common species associated with human infections and is typically found in pigs. In the United States and Canada, there are six documented genotypes: *T. spiralis, T. pseudospiralis, T. murrelli, T. nativa, T. chanchalensis,* and *Trichinella* T6 [153]. Though zoonotic infection from pigs declined rapidly after the United States implemented control mechanisms for *T. spiralis,*

cases of *Trichinella* from game meat have increased in recent years, leading some to consider it a reemerging pathogen [153]. Most research in North America took place in Canada or over three decades ago, meaning updated prevalence and genotypic information is needed.

**Lifecycle:** *Trichinella* has both a sylvatic and domestic lifecycle, with *T. spiralis* maintained primarily in domestic pigs and all other species of *Trichinella* maintained by wildlife. Scavenging is responsible for the majority of transmission in the sylvatic life cycle, with some studies finding viable *Trichinella* larvae in decayed meat for over four months [154]. When a susceptible host ingests meat containing viable *Trichinella*, the larvae are released during digestion and burrow into the lamina propria of the intestine. They will molt four times to reach sexual maturity, at which point they will mate. This process can take as little as 30 hours to complete [152]. Larvae migrate through the circulatory system to striated muscle, often in the tongue, diaphragm, or intercostal muscles. The larvae are able to manipulate the muscle cell to form a protective capsule referred to as a nurse cell [152]. After about two weeks, the larvae become infective, and the cycle can continue with predation or scavenging.

**Clinical signs:** In humans, symptoms can range from mild to life-threatening. During the enteral phase of infection, which occurs from weeks 2-6 post ingestion, symptoms can include myalgia, periorbital edema, fever, conjunctivitis, headache, and skin rash. In more severe cases, high fever and severe eosinophilia often develop, and neurologic manifestations including vertigo, reflex abnormalities, meningitis, and behavioral changes can develop [155]. Experimental infections in dogs have shown gastrointestinal disturbances and eosinophilia are common, while hypercalcemia occurs only with severe infection [156].

**Diagnosis:** In wildlife, diagnosis is typically achieved by recovering larvae after digestion of muscle in an acidic solution [157]. Larva can also be visualized within the muscle itself by pressing a thin piece of muscle between two slides. In addition, the larvae are identifiable via the characteristic nurse cell they occupy on histology. Numerous PCR primers, both traditional and quantitative, are available for molecular diagnosis as well. Genotyping is typically achieved with a multiplex PCR protocol, though next generation sequencing is becoming more common [158].

***Trichinella* in coyotes:** Few surveys have been performed in coyotes, likely since they are not a game species, and therefore have low zoonotic risk. However, coyotes consume a wide range of game species in their diet, and therefore can serve as sentinels for the prevalence of the parasite in the local ecosystem. Of the surveys that have been done, prevalence typically ranges between 4% and 11%, with one study in Wisconsin finding a 26% (11/42) prevalence via digestion of tongue [150,159,160]. Older studies refer to the species in coyotes as *T. spiralis*, but reports that utilized multiplex PCR or sequencing have found that *T. murrelli* is the most common sylvatic genotype in the United States and in coyotes [159,161,162]. To date, *Trichinella* has primarily been found in coyotes in the southwest and midwestern United States, with few surveys in the

eastern parts of the country. The last study assessing for *Trichinella* in the southeast was a 1987 survey of 267 coyotes in Tennessee, which did not find evidence of *Trichinella* in any of the diaphragms examined [163]. However, coyotes' range and abundance have expanded significantly since then, and further work in the eastern United States are needed.

## Viruses of Coyotes

### Rabies Virus

Rabies virus is a bullet-shaped lyssavirus that causes encephalomyelitis in mammals globally [164]. Its fatality rate is nearly 100% after the onset of clinical signs, making it one of the deadliest infectious diseases in the world [165]. However, the advent of post-exposure prophylaxis and the rabies vaccine for domestic animals has dropped annual cases significantly [164]. An estimated 55,000 people die from rabies every year, with most cases in Asia and Africa [166]. In the United States, only 125 human rabies cases have been reported in the last 70 years [167]. Foxes, skunks, and bats are the primary reservoirs in the United States, though all mammalian species can harbor the pathogen. In the United States, more than 4,000 cases of animal rabies are reported each year, with about 90% in wildlife and 10% in domestic animals [168].

**Lifecycle:** Rabies virus is spread through the saliva of affected hosts, almost exclusively via biting. If an infected animal bites a susceptible host, the virus travels from the saliva, into the bite wound, and eventually makes its way to the neurons. From there, it will slowly travel (about 12-14mm/day) from the peripheral nerves to the spinal ganglia [169]. Once at the spinal cord, the virus can travel faster, as much as 400mm/day, until it reaches the brain and the salivary glands [169]. Once in the brain and salivary glands, the pathogen can be spread via biting, corneal transplant, or salivary contamination onto a wound [170].

**Clinical signs:** After inoculation, hosts can remain asymptomatic for weeks or months while the virus travels to the spinal cord [167]. The length of this asymptomatic phase is directly correlated with the distance of the inoculation site from the spinal cord. A bite on a far extremity will have a longer incubation period than a bite to the face. Once at the spinal ganglion, patients may experience paresthesia or malaise [166]. When the virus reaches the brain, the disease can have two primary syndromes: furious (aka, classical) or numb (aka, dumb). In the furious form the host develops hydrophobia, excitation, spasms, and aggression, while patients experiencing the numb form have flaccid paralysis [171]. Death occurs within ten days of clinical sign onset.

**Diagnosis:** In wildlife surveillance studies, diagnosis is typically achieved via the direct fluorescent antibody test (DFAT). The ideal sample is brainstem and cerebellum at the level of the pons, medulla, and midbrain [172]. The DFAT has a sensitivity between 95-100%. Confirmatory techniques are still recommended for clinical cases. This can be done via viral isolation in cell culture or in mice. There are also rtPCR primers available

for sequence confirmation and genotyping [173]. Characteristic intracytoplasmic eosinophilic inclusion bodies called Negri bodies can be seen in the brain on histopathology, which can increase suspicion for the disease as well [174].

**Rabies in coyotes:** With the eradication of canine variant rabies from the United States in 2007, large outbreaks in coyotes are rare [175]. The last outbreak of canine rabies in coyotes in the United States was in 2004 in southern Texas [176]. Since then, cases in coyotes are rare, with only 11 positive cases documented in the 2020 surveillance [177]. In the eastern United States, raccoons are the primary reservoir, with some skunk variant rabies documented in Tennessee and Kentucky [177]. Bat variant rabies is also found throughout the United States. Canine variant rabies is still present in coyotes in Mexico, and continued monitoring and oral vaccination programs are vital to keep the variant from spreading back to the United States [176].

**Canine Distemper Virus**

Canine distemper virus (CDV), or canine morbillivirus, is an enveloped RNA virus that causes multisystemic disorders in both domestic dogs and wildlife. A wide variety of North American wildlife are susceptible, including raccoons, foxes, skunks, wild felids, bears, marine mammals, and mustelids [178,179]. The pathogen is distributed globally, and though many species have endemic low levels of exposure, periodic epidemics can occur that result in significant mortality. Globally, one of the best known epidemics occurred in the Serengeti National Park and killed a third of the lion (*Panthera leo*) population [180]. In the United States, gray foxes and black footed ferrets are some of the most susceptible species, with mortality often approaching 100% [181]. In fact, an epidemic of distemper virus is responsible for the extirpation of black-footed ferrets from the wild, though they have since been reintroduced [182]. There are several different strains in the United States, and outbreaks in domestic dogs and wildlife in east Tennessee were linked to a novel strain of the virus in 2012 [183]. Some wildlife species, like raccoons and foxes, appear capable of carrying the virus asymptomatically and may be reservoirs for infection [178]. Transmission appears to occur both from domestic dogs to wildlife and vice versa, with outbreaks occurring sporadically in each direction [181,184].

**Lifecycle:** Transmission occurs primarily via inhalation of infectious respiratory secretions from an infected animal. Once inhaled, the virus first replicates in monocytes and macrophages during a one to four week incubation period [181]. An initial viremic stage results in profound immunosuppression related to leukocyte necrosis and apoptosis. The virus can then travel to various tissue throughout the body, primarily epithelial, neurologic, and lymphoid tissues. The virus can be shed from an infected host for at least 22 days in urine and 41 days in saliva [185]. Some studies have found that persistence of viral antigen in the brain and uvea can last for over two months [185,186].

**Clinical signs:** Clinical signs are directly related to the species, age, and immune status of the host. In addition, the viral tropism for immune and epithelial cells

determines the target organs. There are two viremic phases, characterized by a biphasic fever. Initially, lymphopenia and a transient or low-grade fever occur, and later a high fever associated with infection of parenchymal tissues occurs [181]. Other clinical symptoms in this second stage are associated with the target organ – conjunctival and nasal discharge, interstitial pneumonia, diarrhea, anorexia, crusting of paw pads, and neurologic deficits can all occur. Neurologic symptoms due to meningoencephalitis vary from vestibular signs to seizures or paresis. Secondary infections are also common, resulting from the severe immunosuppression of CDV [187]. In rare cases, viral antigen can persist in dogs infected with CDV, and lead to chronic demyelination or encephalomyelitis as the dog ages, referred to as old dog  encephalitis [188]. Cases are rare, and though CDV is presumed to be the cause, a clear link has not yet been fully established.

**Diagnosis:** Diagnosis is typically achieved via either real-time reverse-transcription PCR (rt-qPCR) of affected tissues or respiratory secretions, IHC on histology slides, or IFA on frozen tissue [189]. Histologically, eosinophilic inclusion bodies in the cytoplasm or nuclei can be seen in many cells including epithelial cells of the gastrointestinal tract, respiratory epithelium, axons, or transitional epithelium of the bladder [190]. Virus neutralization antibody tests and ELISAs are also commonly performed, though it cannot differentiate active infection from exposure [189].

**CDV in coyotes:** Coyotes are commonly infected with CDV, with between 20-50% antibody positive on most serologic surveys. Though distemper can be fatal in coyotes, they appear capable of either clearing the infection or living asymptomatically with CDV, since most antibody-positive coyotes do not exhibit clinical signs [191–195]. However, few surveys have assessed for active infection or viral DNA, so determining whether high antibodies are due to asymptomatic active infection or a past clinical infection is challenging. The presence of a carrier state of CDV in wild canids is also unknown. Regardless, coyotes are one of the most exposed species, and likely play a significant role, alongside domestic dogs and raccoons, in the maintenance of distemper virus in the United States. Further work investigating the prevalence of active infection could help elucidate transmission dynamics.

### Canine Parvovirus

Canine parvovirus, or CPV, is a DNA virus that affects a wide variety of mammal species. First discovered in the 1970s, it is distributed globally and causes severe, often fatal, diarrhea and myocarditis in susceptible hosts. Parvoviruses are extremely stable in the environment, resistant to most disinfectants, and can remain infectious for months [196]. Two parvoviruses are known to infect dogs: CPV-1 and CPV 2, which is divided into three subspecies (2a, 2b, and 2c).

**Lifecycle:** CPV is spread primarily via the fecal-oral route. Once a susceptible host encounters the virus, it replicates inside rapidly dividing cells, particularly the intestinal crypts of the small intestine. Damage to the crypts, which are responsible for generating the intestinal villi, results in necrosis and blunting of the villi [197]. This leads

to an inability for the intestines to absorb water and nutrients, leading to severe, bloody diarrhea. The virus is shed within the fecal contents and can remain viable in the environment for long periods of time. If another susceptible animal ingests fecal particles, they can become infected and start showing symptoms within 3-7 days [197].

**Clinical signs:** Severe bloody diarrhea and vomiting occur because of the necrosis of the intestinal crypt cells in the small intestine. Life-threatening dehydration can occur within days, and mortality can reach as high as 90% in puppies without supportive care [197]. In young puppies, myocarditis with subsequent heart failure and death can occur [198]. Adult dogs are less susceptible to infection, with only a 10% mortality rate without treatment [197].

**Diagnosis:** Diagnosis of clinical cases is typically achieved with an antigen-detecting SNAP test performed on a fecal sample [199]. In-house SNAP tests are highly specific (92-100%), but only moderate sensitive (30-80%) [199–201]. Therefore, in cases where parvovirus is suspected but the in-house test is negative, quantitative PCR should be performed, as it has a significantly higher sensitivity and is considered the gold standard [201]. Serology is rarely performed in diagnostic cases but is frequently used in wildlife surveys. ELISAs are commonly used since there is a commercially available kit, but Latex Agglutination Tests (LATs) and Fluorescent Antibody Tests (FATs) are also available [197].

**CPV in coyotes:** Studies across the United States have shown a remarkably high prevalence of antibodies to CPV in coyotes, often reaching as high as 100% [30,192,194,202]. Though serologic studies of CPV are common, detection of active infection is less frequently reported. A 2014 study in Georgia found 32% (n=31) of coyotes positive for CPV via real-time PCR of the stool [30]. A similar study in Minnesota found 15% of fecal samples positive in wolves during winter, but 0% of samples collected during the spring were positive, despite a 100% antibody prevalence [202]. This suggests a seasonality to viral shedding, potentially related to younger age of pups in winter or decreased immune function during the colder months. Aside from the 2014 Georgia study, research into this disease in the southeast is limited. There are no studies on record analyzing CPV in coyotes from Tennessee or South Carolina.

## Bacterial Diseases of Coyotes

### *Leptospira*

Leptospirosis is a bacterial disease that affects many species of mammals including humans. There are numerous serovars, many of which are pathogenic to both humans and animals. Though often subclinical, leptospirosis can cause reproductive failure, particularly in livestock, as well as hepatorenal inflammation and even death [203]. Rodents and livestock are the most important reservoirs for human infection, but the disease has been found in almost all mammals. The pathogen has even been isolated in some species of frogs and toads [204].

Though the burden of disease in the United States is lower than in developing nations, it is still a significant concern for Americans, particularly given the high associated costs and relatively young age of most hospitalized individuals. In fact, leptospirosis is considered one of the top 35 zoonotic diseases of high priority by the CDC [205]. Surveillance of local wildlife populations can help determine circulating serovars and the risk of environmental contamination [206]. In addition, cases have been increasing in both domestic dogs and humans in the United States over the last several decades, making monitoring for *Leptospira* sp. important for both animal and human health [207].

**Lifecycle:** *Leptospira* is an aerobic, gram negative, motile, spirochete bacteria which is shed in the urine of infected hosts. There are numerous serovars with varying levels of host specificity and pathogenicity. In dogs in the United States, Canicola and Grippotyphosa are the most common infecting serovars [208]. For most serovars, dogs will only shed the pathogen for a few days to a few weeks post infection. However, dogs are the maintenance host of Canicola and can shed for up to two years [208].

The pathogen lives in the proximal tubules of the kidney in its maintenance hosts, which typically do not develop clinical signs. The urine can contaminate local water sources, which can infect any susceptible animal that consumes the water. In humans, flooding is highly correlated with outbreaks of leptospirosis, since flooding can contaminate drinking water [203]. In dogs, infection is strongly correlated with lifestyle, with dogs that frequently swim in lakes or go on hikes, as well as farm dogs that have free roam of a wide property, infected far more frequently than primarily indoor dogs [208]. Cases are more common in late summer and early autumn, when both rainfall and outdoor activities are high [209]. Rarely, transplacental, venereal, and bite-wound related transmission can occur [210].

Once the pathogen is ingested, it rapidly travels to the bloodstream where it persists for about 10 days after the onset of clinical signs [209]. The pathogen will migrate to the proximal renal tubules of the kidney, where it will replicate and be shed in the urine of the host. It can also travel to the liver, the pregnant uterus, or the spleen [209].

**Clinical signs:** Infection can range from asymptomatic to lethal. Dogs infected with the Canicola serovar rarely suffer any clinical symptoms, while the serovars Icterohaemorrhagiae, Copenhageni, and Pomona often induce significant hepatic necrosis [209]. Peracute and acute leptospirosis are rarely diagnosed, but often lead to sudden death due to leptospiremia, with death occurring before the development of liver or kidney failure. Subacute leptospirosis is the most diagnosed form. Fever, icterus, vomiting, and dehydration are common symptoms, though rarely coagulopathies due to liver failure, intussusception due to diarrhea and vomiting, and dyspnea may occur [209]. Eventually, necrosis of the liver and kidneys can result in liver or renal failure, typically resulting in death. In addition, many animals can become chronic carriers after initial infection, where they are able to shed *Leptospira* without overt clinical signs [211].

Chronic leptospirosis has been identified as a potential cause of chronic kidney disease in both dogs and people, and tubulointerstitial nephritis is often found on histopathology in these cases [212].

**Diagnosis:** Diagnosis is challenging due to the nonspecific clinical signs, relatively brief period of leptospiremia, and inconsistent shedding in the urine. In clinical cases, PCR on both blood and urine is recommended, since urine will be negative in acute phases, while blood will be negative in the chronic phase. In addition, a microscopic agglutination test can be used to determine serovar and titers [213]. Histopathology may show hepatic or renal necrosis characterized by lymphocytic infiltration [214]. Silver staining can be used to visualize the spirochete bacteria within the affected organ.

***Leptospira* in coyotes:** Seroprevalence in coyotes ranges between 4-30% in most states, placing them above opossums but below rodents in seroprevalence [195,206,215,216]. Studies vary significantly in how many serovars they test for, but Autumnalis, Bratislava, Grippotyphosa, and Pomona appear to be the most common [206,216,217]. In previous decades, Canicola was most commonly detected [218,219]. However, some older studies only tested for three serovars (Canicola, Icterohaemorrhagiae, and Pomona) which makes direct comparison challenging [218].

Most studies in coyotes focused exclusively on exposure, with few studies on active infection. One study in Ontario tested five coyotes by IHC and PCR and found no positives [220]. A larger survey in California found a 3.7% real-time PCR-positivity rate on homogenized urine and kidney samples [206]. Like antibody positivity, this value was found to be intermediate between low-positivity animals like opossums (0.8% positivity) and high-positivity animals like skunks (15% positivity). This demonstrates that coyotes may be sources of infection for people and pets but are not the primary reservoirs. Rodents, skunks, and raccoons are significantly more likely to shed the pathogen than coyotes [206].

### *Borrelia burgdorferi*

Lyme borreliosis is the most common vector-borne disease in the United States. Though the CDC reports about 30,000 cases per year, insurance claims consistently reveal upwards of 300,000 cases diagnosed each year [221]. Symptoms can range from mild flu-like signs to severe renal, cardiac, and even neurologic disease. Due to the wide range of symptoms, up to 90% of Lyme disease cases remain unreported [222]. Even when the condition is accurately diagnosed, certain individuals can remain symptomatic for months despite appropriate antibiotic therapy in a condition called post-treatment Lyme disease syndrome [223]. The economic burden of Lyme borreliosis in the United States is estimated at $786 million annually [224].

*Borrelia burgdorferi*, the bacterial agent of the disease, is vectored by the black-legged tick (*Ixodes scapularis)* in the eastern United States and *I. pacificus* in the West. Though historically restricted to the colder climates in the northeast, the black-legged tick has expanded its boundaries southward and is now found frequently throughout the southeast [225]. As the vector migrated south, so did *B. burgdorferi.* Reported cases of

Lyme disease in Virginia, a state previously considered low incidence, increased by almost 50% from 2007 to 2014 [222]. Other southeastern states like North Carolina have also seen upticks in their annual cases in recent decades [226]. Tennessee is still considered a nonendemic state [225,227]. However, recent research demonstrated not only that *I. scapularis* is fully established in eastern Tennessee but also found ticks infected with *B. burgdorferi* in three counties surrounding Knoxville [225]. This work calls into question Tennessee's nonendemic status. Given the potential debilitating side effects of undiagnosed Lyme disease, it is vital to obtain an accurate understanding of prevalence in our area to assist doctors and veterinarians in risk assessment in their patients.

**Lifecycle:** *Borrelia burgdorferi* sensu stricto is the only genotype of *B. burgdorferi* to cause Lyme disease in the United States, though there are several other related genotypes that can cause disease in other parts of the world [228]. A related but distinct species, *B. mayoni*, has been found in black-legged ticks from Wisconsin and Minnesota, and it can also cause Lyme disease [229]. When an infected black-legged tick bites a susceptible host, certain lipoproteins are activated that help transition the pathogen, which typically resides in the midgut of the tick, to the salivary glands where it can enter the host. When an infected tick takes a blood meal, the nutrients in the blood also allow the pathogen to switch from a latent phase to a phase of replication and dissemination. There is debate on whether the lipoprotein OspA is downregulated to allow greater motility during this phase [229]. Regardless of the mechanism, the spirochetes move to the salivary gland of the tick within the first 24-48 hours of feeding. The lipoprotein OspC, which is an important determinant of virulence and infectivity, is also upregulated during this time [228]. *Borrelia burgdorferi* is highly motile and can travel up to 4μm/sec in tissue, which allows it to escape slower phagocytes [229]. The pathogen remains within the local tissue for several days to weeks before reaching the blood stream and disseminating to other organs in the body. pathogen can travel to numerous tissues, although cardiac, synovial, neurologic, and renal tissue are most common.

Though many mammals can become infected with the pathogen, white-footed mice and other small rodents are considered some of the most important reservoirs for the pathogen in the United States. White tailed deer, which are the primary host for adult *I. scapularis* ticks, are also considered vital for the maintenance of tick populations, although they are reservoir incompetent and do not maintain infections with *B. burgdorferi* [230,231]. High deer populations lead to an increase in the vector, and high mouse populations increase the prevalence of the pathogen itself. In states where skinks and other small lizards are common, particularly in the south, the opposite effect occurs. Small lizards are inefficient reservoirs for *B. burgdorferi,* and may even be able to clear nymphal ticks of their infection, leading to a reduction in the pathogen [232,233].

**Clinical signs:** Though most people and pets infected with *B. burgdorferi* will clear the infection with few clinical symptoms, Lyme disease can cause chronic and even fatal neurologic, cardiac, and synovial manifestations. In humans, one of the first signs of infection is the erythema migrans rash, which is a bullseye rash that often appears over the back of the knees or armpits 7-14 days after a bite and spreads across the patient

[228]. Canids do not appear to develop the rash [234]. Fever, lymphadenopathy, and fatigue may occur during this period as well in the acute phase. Neurologic abnormalities like facial palsy and meningitis occur in about 15% of symptomatic but untreated patients, while carditis occurs in 4-8% [228]. Asymmetrical arthritis occurs in 60% of patients that are untreated, typically about 6 months after the onset of disease.

Lyme disease can cause debilitating and even life-threatening clinical signs in dogs. Though the majority of dogs (about 90-95%) will remain asymptomatic after infection, about 5-10% will develop arthritis which can affect one or many joints [235,236]. Fever, lymphadenopathy, and anorexia may also occur, and dogs will often not become symptomatic until several weeks or months after exposure. The majority of cases respond rapidly to a course of antibiotics, with doxycycline the antibiotic of choice due to the likelihood of co-infection with other tick-borne pathogens [237]. In about 1-2% of seropositive dogs, antigen-antibody complexes will develop resulting in a life-threatening protein-losing nephropathy (PLN), which is referred to as Lyme nephritis [236]. Despite its name, the link between Lyme disease and Lyme nephritis remains controversial, with PCR and immunohistochemistry (IHC) of kidneys often negative [238]. There is no validated test or experimental model for Lyme nephritis, and it is unclear how beneficial antibiotics are at improving prognosis since most dogs diagnosed with Lyme nephritis will die regardless of treatment [236,237]. It is unclear if earlier, less severe stages of Lyme nephritis exist before the development of PLN and if treatment during those stages could prevent progression [236]. Regardless, expert consensus still recommends antibiotic treatment in seropositive dogs with protein-losing nephropathy since exposure to Lyme disease is the only common link identified thus far [237].

**Diagnosis:** Although it is one of the most common vector-borne diseases, diagnosis is challenging. Currently, Lyme disease is diagnosed via a combination of positive antibody tests, a history of tick exposure, and clinical signs [237]. However, these diagnostic criteria can be unreliable since antibody tests can have false negatives during acute infection and may remain positive for years after initial infection. In addition, many owners will not notice ticks underneath the coat of their dog, and clinical signs are often enigmatic. There are quantitative antibody tests (IDEXX's Quant $C_6$) available, but high titers are not correlated with symptoms, and there is little evidence to demonstrate this test's usefulness in determining the likelihood of clinical symptoms [237]. PCR tests of blood, urine, or cerebral spinal fluid are often negative, even in dogs with severe clinical symptoms [235]. PCR of skin biopsies from the tick attachment site or from affected synovial tissue may be positive, but this is rarely feasible [239]. Even in autopsy cases, diagnosis can be challenging since intact *B. burgdorferi* DNA is rarely found even in severely affected animals [240].

***Borrelia burgdorferi* in coyotes:** Most studies in coyotes have focused on serology. Unsurprisingly, coyotes in highly endemic areas have high exposure, while coyotes in southern or midwestern states have low seroprevalence. The exception is a study in Texas, which surprisingly found numerous coyote kidneys and placentas IFA positive for *Borrelia* [241] . However, Lyme is nonendemic in Texas, and it is more likely that the

coyotes were infected with a related species like *B. turicatae,* which is found in Texas and has been documented in coyotes in the area [242,242,243]. Otherwise, seroprevalence in coyotes is closely correlated with the burden of human and canine infection [244–247]. This close correlation makes coyotes excellent sentinels for the spread of the pathogen, since they have higher exposure rates than people or pets. Few studies have been done in the southern United States, despite the increasing prevalence of *Borrelia* in these areas. Assessment of exposure in coyotes can give public health officials earlier indicators of spread.

Coyotes may play an important role in the maintenance of tick vectors, similar to white-tailed deer. *Ixodes scapularis* adults are consistently documented on coyotes [254]. Understanding the role coyotes play in the black-legged tick life cycle, particularly the eastern United States where coyotes have only recently migrated, is vital to help wildlife managers make informed decisions. Many states have proposed deer culling as a method to reduce the incidence of Lyme disease, though evidence for effectiveness of this method is lacking [252,253]. Some of this failure may be due to coyotes' ability to act as maintenance hosts. Further work is necessary to determine the impact of coyotes on the abundance of black-legged ticks.

## Conclusion

Coyotes can carry numerous diseases that affect humans, pets, and livestock. Though more is known about their health status and disease burdens in the western United States, little disease surveillance has been done on eastern coyotes. In addition, most of the coyote research to date has focused on serology, which only provides evidence of exposure. Further work assessing the prevalence of disease can help us better understand whether coyotes are contributing to the spread of the diseases they are exposed to. Many of the diseases that impact coyotes are also expanding geographically, and surveillance of coyotes can help elucidate these trends. A thorough understanding of the prevalence, geographic spread, and impact of the diseases of coyotes is vital to prepare vets, doctors, and wildlife biologist to best manage their patients and habitats.

# References

1. Hody JW, Kays R. Mapping the expansion of coyotes (*Canis latrans*) across North and Central America. ZooKeys. 2018;81–97.

2. Gompper ME. Top Carnivores in the Suburbs? Ecological and Conservation Issues Raised by Colonization of North-eastern North America by Coyotes: The expansion of the coyote's geographical range may broadly influence community structure, and rising coyote densities in the suburbs may alter how the general public views wildlife. BioScience. 2002;52:185–90.

3. Gehrt S, Brown J, Anchor C. Is the Urban Coyote a Misanthropic Synanthrope? The Case from Chicago. Cities Environ CATE. 2011;4. Available from: https://digitalcommons.lmu.edu/cate/vol4/iss1/3

4. Henger CS, Herrera GA, Nagy CM, Weckel ME, Gormezano LJ, Wultsch C, et al. Genetic diversity and relatedness of a recently established population of eastern coyotes (*Canis latrans*) in New York City. Urban Ecosyst. 2020;23:319–30.

5. Levi T, Kilpatrick AM, Mangel M, Wilmers CC. Deer, predators, and the emergence of Lyme disease. Proc Natl Acad Sci. 2012;109:10942–7.

6. Baker R O, Timm R M. Coyote Attacks on Humans, 1970-2015. Proc Vertebr Pest Conf. 2016;27. Available from: https://escholarship.org/uc/item/0qz6c152

7. Monzón J, Kays R, Dykhuizen DE. Assessment of coyote–wolf–dog admixture using ancestry-informative diagnostic SNPs. Mol Ecol. 2014;23:182–97.

8. Ellington EH, Murray DL. Influence of hybridization on animal space use: a case study using coyote range expansion. Oikos. 2015;124:535–42.

9. Thurber JM, Peterson RO. Changes in Body Size Associated with Range Expansion in the Coyote (*Canis latrans*). J Mammal. 1991;72:750–5.

10. Hofmeester TR, Jansen PA, Wijnen HJ, Coipan EC, Fonville M, Prins HHT, et al. Cascading effects of predator activity on tick-borne disease risk. Proc R Soc B Biol Sci. 2017;284:20170453.

11. Tsao JI, Hamer SA, Han S, Sidge JL, Hickling GJ. The Contribution of Wildlife Hosts to the Rise of Ticks and Tick-Borne Diseases in North America. J Med Entomol. 2021;58:1565–87.

12. Way JG, White BN. Coyotes, Red Foxes, and the Prevalence of Lyme Disease. Northeast Nat. 2013;20:655–65.

13. Halliday JEB, Meredith AL, Knobel DL, Shaw DJ, Bronsvoort BM de C, Cleaveland S. A framework for evaluating animals as sentinels for infectious disease surveillance. J R Soc Interface. 2007.

14. Poessel SA, Gese EM, Young JK. Environmental factors influencing the occurrence of coyotes and conflicts in urban areas. Landsc Urban Plan. 2017;157:259–69.

15. Kays R, Costello R, Forrester T, Baker MC, Parsons AW, Kalies EL, et al. Cats are rare where coyotes roam. J Mammal. 2015;96:981–7.

16. Alexander SM, Quinn MS. Coyote (*Canis latrans*) Interactions With Humans and Pets Reported in the Canadian Print Media (1995–2010). Hum Dimens Wildl. 2011;16:345–59.

17. Ledesma N, Harrington L. Mosquito Vectors of Dog Heartworm in the United States: Vector Status and Factors Influencing Transmission Efficiency. Top Companion Anim Med. 2011;26:178–85.

18. Bowman DD, Atkins CE. Heartworm Biology, Treatment, and Control. Vet Clin Small Anim Pract. 2009;39:1127–58.

19. Aher AM, Caudill D, Caudill G, Butryn RS, Wolf D, Fox M, et al. Prevalence, genetic analyses, and risk factors associated with heartworm (*Dirofilaria immitis*) in wild coyotes (*Canis latrans*) from Florida, USA. J Wildl Dis. 2016;52:785–92.

20. Fryxell RTT, Lewis TT, Peace H, Hendricks BBM, Paulsen D. Identification of Avian Malaria (*Plasmodium* Sp.) and Canine Heartworm (*Dirofilaria immitis*) in the Mosquitoes of Tennessee. J Parasitol. 2014;100:455–62.

21. Kazacos KR, Edberg EO. *Dirofilaria immitis i*nfection in foxes and coyotes in Indiana. J Am Vet Med Assoc. 1979;175:909–10.

22. King AW, Bohning AM. The incidence of heartworm *Dirofilaria immitis* (Filarioidea), in the wild canids of northeast Arkansas. Southwest Nat. 1984;89–92.

23. Sacks BN, Caswell-Chen EP. Reconstructing the spread of *Dirofilaria immitis* in California coyotes. J Parasitol. 2003;89:319–23.

24. Sobotyk C, Nguyen N, Negrón V, Varner A, Saleh MN, Hilton C, et al. Detection of *Dirofilaria immitis* via integrated serological and molecular analyses in coyotes from Texas, United States. Int J Parasitol Parasites Wildl. 2022;18:20–4.

25. Wixsom MJ, Green SP, Corwin RM, Fritzell EK. *Dirofilaria immitis* in Coyotes and Foxes in Missouri. J Wildl Dis. 1991;27:166–9.

26. Kozek WJ. What is new in the *Wolbachia*/*Dirofilaria* interaction? Vet Parasitol. 2005;133:127–32.

27. Savadelis MD, Coleman AE, Rapoport GS, Sharma A, Sakamoto K, Keys DA, et al. Clinical assessment of heartworm-infected Beagles treated with a combination of imidacloprid/moxidectin and doxycycline, or untreated. J Vet Intern Med. 2020;34:1734–45.

28. Sutton RH, Atwell RB. Lesions of Pulmonary Pleura Associated with Canine Heartworm Disease. Vet Pathol. 1985;22:637–9.

29. Dantas-Torres F, Otranto D. Overview on Dirofilaria immitis in the Americas, with notes on other filarial worms infecting dogs. Vet Parasitol. 2020;282:109113.

30. Gates M, Gerhold RW, Wilkes RP, Gulsby WD, Maestas L, Rosypal A, et al. Parasitology, Virology, and Serology of Free-Ranging Coyotes (*Canis latrans*) from Central Georgia, USA. J Wildl Dis. 2014;50:896–901.

31. Custer JW, Pence DB. Dirofilariasis in wild canids from the Gulf coastal prairies of Texas and Louisiana, U.S.A. Vet Parasitol. 1981;8:71–82.

32. Miller DL, Schrecengost J, Kilgo J, Ray HS, Miller KV. Ruptured Aortic Aneurysm in a Coyote (*Canis latrans)* from South Carolina. J Zoo Wildl Med. 2007;38:492–4.

33. Little S, Braff J, Place J, Buch J, Dewage BG, Knupp A, et al. Canine infection with *Dirofilaria immitis, Borrelia burgdorferi, Anaplasma* spp., and *Ehrlichia* spp. in the United States, 2013–2019. Parasit Vectors. 2021;14:1–16.

34. Self SW, Pulaski CN, McMahan CS, Brown DA, Yabsley MJ, Gettings JR. Regional and local temporal trends in the prevalence of canine heartworm infection in the contiguous United States: 2012–2018. Parasit Vectors. 2019;12:380.

35. Worsley-Tonks KEL, Gehrt SD, Anchor C, Escobar LE, Craft ME. Infection risk varies within urbanized landscapes: the case of coyotes and heartworm. Parasit Vectors. 2021;14:464.

36. Hahn MB, Eisen L, McAllister J, Savage HM, Mutebi J-P, Eisen RJ. Updated Reported Distribution of *Aedes* (Stegomyia) *aegypti* and *Aedes* (Stegomyia) *albopictus* (Diptera: Culicidae) in the United States, 1995–2016. J Med Entomol. 2017;54:1420–4.

37. Mckay T, Bianco T, Rhodes L, Barnett S. Prevalence of Dirofilaria immitis (Nematoda: Filarioidea) in Mosquitoes From Northeast Arkansas, the United States. J Med Entomol. 2013;50:871–8.

38. Conboy GA. Canine angiostrongylosis: The French heartworm: An emerging threat in North America. Vet Parasitol. 2011;176:382–9.

39. Gillis-Germitsch N, Manser MB, Hilbe M, Schnyder M. Meerkats (*Suricata suricatta)*, a new definitive host of the canid nematode *Angiostrongylus vasorum*. Int J Parasitol Parasites Wildl. 2017;6:349–53.

40. Patterson-Kane JC, Gibbons LM, Jefferies R, Morgan ER, Wenzlow N, Redrobe SP. Pneumonia from *Angiostrongylus Vasorum* Infection in a Red Panda (Ailurus Fulgens Fulgens). J Vet Diagn Invest. 2009;21:270–3.

41. Takeuchi-Storm N, Al-Sabi MNS, Chriel M, Enemark HL. Systematic examination of the cardiopulmonary, urogenital, muscular and gastrointestinal parasites of the Eurasian otters (*Lutra lutra*) in Denmark, a protected species recovering from a dramatic decline. Parasitol Int. 2021;84:102418.

42. Bourque A, Whitney H, Conboy G. Angiostrongylus vasorum Infection in a Coyote (*Canis latrans*) from Newfoundland and Labrador, Canada. J Wildl Dis. 2005;41:816–9.

43. Mahjoub HA, Robbins WT, Galeuzzi O, Graham KF, Jones MEB, Buote MA, et al. First report of *Angiostrongylus vasorum* (French heartworm) in red foxes (*Vulpes vulpes*) on Prince Edward Island. Can Vet J. 2022;63:637–40.

44. Kistler WM, Brown JD, Allison AB, Nemeth NM, Yabsley MJ. First report of *Angiostrongylus vasorum* and *Hepatozoon* from a red fox (*Vulpes vulpes*) from West Virginia, USA. Vet Parasitol. 2014;200:216–20.

45. Rosen L, Ash LR, Wallace GD. Life history of the canine lungworm *Angiostrongylus vasonim* (Baillet). Am J Vet Res. 1970;31:131–43.

46. Bolt G, Monrad J, Frandsen F, Henriksen P, Dietz HH. The common frog (*Rana temporaria*) as a potential paratenic and intermediate host for *Angiostrongylus vasorum*. Parasitol Res. 1993;79:428–30.

47. Morgan ER, Shaw SE, Brennan SF, Waal TDD, Jones BR, Mulcahy G. *Angiostrongylus vasorum*: a real heartbreaker. Trends Parasitol. 2005;21:49–51.

48. G Bolt, J Monrad, J Koch, A Jensen. Canine angiostrongylosis: a review. Vet Rec. 1994;135:447–52.

49. Koch J, Willesen JL. Canine pulmonary angiostrongylosis: An update. Vet J. 2009;179:348–59.

50. Cury MC, Lima WS, Guimarães MP, Carvalho MG. Hematological and coagulation profiles in dogs experimentally infected with *Angiostrongylus vasorum* (Baillet, 1866). Vet Parasitol. 2002;104:139–49.

51. Denk D, Matiasek K, Just FT, Hermanns W, Baiker K, Herbach N, et al. Disseminated angiostrongylosis with fatal cerebral haemorrhages in two dogs in Germany: A clinical case study. Vet Parasitol. 2009;160:100–8.

52. Taubert A, Pantchev N, Vrhovec MG, Bauer C, Hermosilla C. Lungworm infections (*Angiostrongylus vasorum, Crenosoma vulpis, Aelurostrongylus abstrusus*) in dogs and cats in Germany and Denmark in 2003–2007. Vet Parasitol. 2009;159:175–80.

53. Morgan E, Shaw S. *Angiostrongylus vasorum* infection in dogs: continuing spread and developments in diagnosis and treatment. J Small Anim Pract. 2010;51:616–21.

54. Schnyder M, Fahrion A, Riond B, Ossent P, Webster P, Kranjc A, et al. Clinical, laboratory and pathological findings in dogs experimentally infected with *Angiostrongylus vasorum.* Parasitol Res. 2010;107:1471–80.

55. Priest JM, Stewart DT, Boudreau M, Power J, Shutler D. First report of *Angiostrongylus vasorum* in coyotes in mainland North America. Vet Rec. 2018;183.

56. Dubey JP. Endemic *Paragonimus kellicotti* infections in animals and humans in USA and Canada: Review and personal perspective. Food Waterborne Parasitol. 2023;30:e00184.

57. Harrus S, Nyska A, Colorni A, Markovics A. Sudden death due to *Paragonimus kellicotti* infection in a dog. Vet Parasitol. 1997;71:59–63.

58. Herman LH, Helland DR. Paragonimiasis in a cat. J Am Vet Med Assoc. 1966;149:753–7.

59. Swerczek TW, Lyons ET. Paragonimiasis in a cat in Kentucky. Vet Med. 2000;95:909–11.

60. Pechman JR RD. Pulmonary paragonimiasis in dogs and cats: a review. J Small Anim Pract. 1980;21:87–95.

61. Beckett JV, Gallicchio V. Occurrence of the Lung Fluke, *Paragonimus kellicotti* Ward, 1908, in Ohio Mink. J Parasitol. 1966;52.

62. Gesinski RM, Thomas RE, Gallicchio V. Survey of *Paragonimus* in Ohio Mink. J Parasitol. 1964;50.

63. Grigione MM, Burman P, Clavio S, Harper SJ, Manning DL, Sarno RJ. A comparative study between enteric parasites of Coyotes in a protected and suburban habitat. Urban Ecosyst. 2014;17:1–10.

64. Nelson TA, Gregory DG, Burroughs C, Laursen JR. Prevalence of lungworms in Illinois Coyotes. Trans Ill State Acad Sci. 2007;100:89–96.

65. Ramsden RO, Presidente PJ. *Paragonimus kellicotti* infection in wild carnivores in southwestern Ontario: I. Prevalence and gross pathologic features. J Wildl Dis. 1975;11:136–41.

66. Watts A, Alexander S. Community Variation of Gastrointestinal Parasites Found in Urban and Rural Coyotes (*Canis latrans)* of Calgary, Alberta. Cities Environ CATE. 2012;4.

67. Morrison EE, Gier HT. Lungworms in coyotes on the Great Plains. J Wildl Dis. 1978;14:314–6.

68. Bridger KE, Baggs EM, Finney-Crawley J. Endoparasites of the Coyote (*Canis latrans*), a Recent Migrant to Insular Newfoundland. J Wildl Dis. 2009;45:1221–6.

69. Barutzki D, Schaper R. Natural Infections of *Angiostrongylus vasorum* and *Crenosoma vulpis* in Dogs in Germany (2007–2009). Parasitol Res. 2009;105:39–48.

70. Allen KE, Johnson EM, Little SE. *Hepatozoon* spp infections in the United States. Vet Clin Small Anim Pract. 2011;41:1221–38.

71. Johnson EM, Panciera RJ, Allen KE, Sheets ME, Beal JD, Ewing SA, et al. Alternate pathway of infection with *Hepatozoon americanum* and the epidemiologic importance of predation. J Vet Intern Med. 2009;23:1315–8.

72. Johnson EM, Allen KE, Panciera RJ, Little SE, Ewing SA. Infectivity of *Hepatozoon americanum* cystozoites for a dog. Vet Parasitol. 2008;154:148–50.

73. Allen KE, Li Y, Kaltenboeck B, Johnson EM, Reichard MV, Panciera RJ, et al. Diversity of *Hepatozoon* species in naturally infected dogs in the southern United States. Vet Parasitol. 2008;154:220–5.

74. Li Y, Wang C, Allen KE, Little SE, Ahluwalia SK, Gao D, et al. Diagnosis of canine *Hepatozoon* spp. infection by quantitative PCR. Vet Parasitol. 2008;157:50–8.

75. Davis DS, Robinson RM, Craig TM. Naturally occuring Hepatozoonosis in a coyote. J Wildl Dis. 1978;14:244–6.

76. Starkey LA, Panciera RJ, Paras K, Allen KE, Reiskind MH, Reichard MV, et al. Genetic diversity of *Hepatozoon* spp. in coyotes from the south-central United States. J Parasitol. 2013;99:375–8.

77. Phillips VC, Zieman EA, Kim C-H, Stone CM, Tuten HC, Jiménez FA. Documentation of the expansion of the Gulf Coast tick (*Amblyomma maculatum*) and *Rickettsia parkeri*: first report in Illinois. J Parasitol. 2020;106:9–13.

78. Maestas LP, Reeser SR, McGay PJ, Buoni MH. Surveillance for *Amblyomma maculatum* (Acari: Ixodidae) and *Rickettsia parkeri* (Rickettsiales: Rickettsiaceae) in the state of Delaware, and their public health implications. J Med Entomol. 2020;57:979–83.

79. Craig TM, Smallwood JE, Knauer KW, McGrath JP. *Hepatozoon canis* infection in dogs: clinical, radiographic, and hematologic findings. J Am Vet Med Assoc. 1978;173:967–72.

80. Morgado FN, Cavalcanti A dos S, Miranda LH de, O'Dwyer LH, Silva MRL da, Menezes RC, et al. *Hepatozoon canis* and *Leishmania* spp. coinfection in dogs diagnosed with visceral leishmaniasis. Rev Bras Parasitol Veterinária. 2016;25:450–8.

81. Coy CL, Evans JB, Lee AM, Dugat DR, Levine JM, Griffin JF. American Canine Hepatozoonosis Causes Multifocal Periosteal Proliferation on CT: A Case Report of 4 Dogs. Front Vet Sci. 2022;9:872778.

82. Ewing SA, Panciera RJ. American Canine Hepatozoonosis. Clin Microbiol Rev. 2003;16:688–97.

83. Baneth G, Samish M, Shkap V. Life cycle of *Hepatozoon canis* (Apicomplexa: Adeleorina: Hepatozoidae) in the tick *Rhipicephalus sanguineus* and domestic dog (*Canis familiaris*). J Parasitol. 2007;93:283–99.

84. Allen KE, Yabsley MJ, Johnson EM, Reichard MV, Panciera RJ, Ewing SA, et al. Novel *Hepatozoon* in vertebrates from the southern United States. J Parasitol. 2011;97:648–53.

85. Kocan AA, Cummings CA, Panciera RJ, Mathew JS, Ewing SA, Barker RW. Naturally Occurring and Experimentally Transmitted *Hepatozoon americanum* in Coyotes from Oklahoma. J Wildl Dis. 2000;36:149–53.

86. Garrett JJ, Kocan AA, Reichard MV, Panciera RJ, Bahr RJ, Ewing SA. Experimental Infection of Adult and Juvenile Coyotes with Domestic Dog and Wild Coyote Isolates of *Hepatozoon americanum* (Apicomplexa: Adeleorina). J Wildl Dis. 2005;41:588–92.

87. Allen KE, Li Y, Kaltenboeck B, Johnson EM, Reichard MV, Panciera RJ, et al. Diversity of *Hepatozoon* species in naturally infected dogs in the southern United States. Vet Parasitol. 2008;154:220–5.

88. Meyers AC, Purnell JC, Ellis MM, Auckland LD, Meinders M, Hamer SA. Nationwide exposure of US working dogs to the Chagas disease parasite, *Trypanosoma cruzi*. Am J Trop Med Hyg. 2020;102:1078.

89. Montgomery SP, Parise ME, Dotson EM, Bialek SR. What Do We Know About Chagas Disease in the United States? Am J Trop Med Hyg. 2016;95:1225–7.

90. Zingales B, Miles MA, Campbell DA, Tibayrenc M, Macedo AM, Teixeira MMG, et al. The revised *Trypanosoma cruzi* subspecific nomenclature: Rationale, epidemiological relevance and research applications. Infect Genet Evol. 2012;12:240–53.

91. Bern C, Kjos S, Yabsley MJ, Montgomery SP. *Trypanosoma cruzi* and Chagas' disease in the United States. Clin Microbiol Rev. 2011;24:655–81.

92. Roellig DM, Ellis AE, Yabsley MJ. Oral transmission of *Trypanosoma cruzi* with opposing evidence for the theory of carnivory. J Parasitol. 2009;95:360–4.

93. Busselman RE, Hamer SA. Chagas Disease Ecology in the United States: Recent Advances in Understanding *Trypanosoma cruzi* Transmission Among Triatomines, Wildlife, and Domestic Animals and a Quantitative Synthesis of Vector–Host Interactions. Annu Rev Anim Biosci. 2022;10:325–48.

94. Barr SC. Canine Chagas' disease (American trypanosomiasis) in North America. Vet Clin Small Anim Pract. 2009;39:1055–64.

95. Guarner J. Chagas disease as example of a reemerging parasite. Semin Diagn Pathol. 2019;36:164–9.

96. Rosypal AC, Smith T, Alexander A, Weaver M, Stewart R, Houston A, et al. Serologic survey of antibodies to *Trypanosoma cruzi* in coyotes and red foxes from Pennsylvania and Tennessee. J Zoo Wildl Med. 2014;45:991–3.

97. Hodo CL, Bañuelos RM, Edwards EE, Wozniak EJ, Hamer SA. Pathology and discrete typing unit associations of *Trypanosoma cruzi* infection in coyotes (*Canis latrans*) and raccoons (*Procyon lotor*) of Texas, USA. J Wildl Dis. 2020;56:134–44.

98. Aliaga C, Brenière SF, Barnabé C. Further interest of miniexon multiplex PCR for a rapid typing of *Trypanosoma cruzi* DTU groups. Infect Genet Evol. 2011;11:1155–8.

99. Pronovost H, Peterson AC, Chavez BG, Blum MJ, Dumonteil E, Herrera CP. Deep sequencing reveals multiclonality and new discrete typing units of *Trypanosoma cruzi* in rodents from the southern United States. J Microbiol Immunol Infect. 2020;53:622–33.

100. Curtis-Robles R, Lewis BC, Hamer SA. High *Trypanosoma cruzi* infection prevalence associated with minimal cardiac pathology among wild carnivores in central Texas. Int J Parasitol Parasites Wildl. 2016;5:117–23.

101. Majeau A, Pronovost H, Sanford A, Cloherty E, Anderson AN, Balsamo G, et al. Raccoons as an important reservoir for *Trypanosoma cruzi*: a prevalence study from two metropolitan areas in Louisiana. Vector-Borne Zoonotic Dis. 2020;20:535–40.

102. Hodo CL, Hamer SA. Toward an Ecological Framework for Assessing Reservoirs of Vector-Borne Pathogens: Wildlife Reservoirs of *Trypanosoma cruzi* across the Southern United States. ILAR J. 2017;58:379–92.

103. Brown EL, Roellig DM, Gompper ME, Monello RJ, Wenning KM, Gabriel MW, et al. Seroprevalence of *Trypanosoma cruzi* Among Eleven Potential Reservoir Species from Six States Across the Southern United States. Vector-Borne Zoonotic Dis. 2010;10:757–63.

104. Burkholder JE, Allison TC, Kelly VP. *Trypanosoma cruzi* (Chagas) (Protozoa: Kinetoplastida) in invertebrate, reservoir, and human hosts of the lower Rio Grande valley of Texas. J Parasitol. 1980;66:305–11.

105. Roellig DM, Savage MY, Fujita AW, Barnabé C, Tibayrenc M, Steurer FJ, et al. Genetic Variation and Exchange in *Trypanosoma cruzi* Isolates from the United States. PLOS ONE. 2013;8:e56198.

106. Dear JD, Birkenheuer A. *Babesia* in North America: An Update. Vet Clin North Am Small Anim Pract. 2022;52:1193–209.

107. Zygner W, Gójska-Zygner O, Bartosik J, Górski P, Karabowicz J, Kotomski G, et al. Canine Babesiosis Caused by Large *Babesia* Species: Global Prevalence and Risk Factors—A Review. Anim Basel. 2023;13:2612-.

108. Yeagley TJ, Reichard MV, Hempstead JE, Allen KE, Parsons LM, White MA, et al. Detection of *Babesia gibsoni* and the canine small *Babesia* 'Spanish isolate' in blood samples obtained from dogs confiscated from dogfighting operations. J Am Vet Med Assoc. 2009;235:535–9.

109. Dear JD, Owens SD, Lindsay LL, Biondo AW, Chomel BB, Marcondes M, et al. *Babesia conradae* infection in coyote hunting dogs infected with multiple blood-borne pathogens. J Vet Intern Med. 2018;32:1609–17.

110. Javeed NN, Shultz L, Barnum S, Foley JE, Hodzic E, Pascoe EL, et al. Prevalence and geographic distribution of *Babesia conradae* and detection of *Babesia vogeli* in free-ranging California coyotes (*Canis latrans*). Int J Parasitol Parasites Wildl. 2022;19:294–300.

111. Dp R, Jf A, Sw N. Experimental babesiosis in coyotes and coydogs. Am J Vet Res. 1985;46:256–62.

112. Evers HV, Kocan AA, Reichard MV, Meinkoth JH. Experimental *Babesia gibsoni* Infection in Coyotes (*Canis latrans*). J Wildl Dis. 2003;39:904–8.

113. World Health Organization. Echinococcosis [Internet]. 2021 [cited 2023 Sep 24]. Available from: https://www.who.int/news-room/fact-sheets/detail/echinococcosis

114. Budke CM, Deplazes P, Torgerson PR. Global Socioeconomic Impact of Cystic Echinococcosis. Emerg Infect Dis. 2006;12:296–303.

115. Eckert J, Deplazes P. Biological, Epidemiological, and Clinical Aspects of Echinococcosis, a Zoonosis of Increasing Concern. Clin Microbiol Rev. 2004;17:107–35.

116. Dell B, Newman SJ, Purple K, Miller B, Ramsay E, Donnell R, et al. Retrospective investigation of *Echinococcus canadensis* emergence in translocated elk (*Cervus canadensis*) in Tennessee, USA, and examination of canid definitive hosts. Parasit Vectors. 2020;13:330.

117. Massolo A, Klein C, Kowalewska-Grochowska K, Belga S, MacDonald C, Vaughan S, et al. European *Echinococcus multilocularis* Identified in Patients in Canada. N Engl J Med. 2019;381:384–5.

118. Peregrine AS, Jenkins EJ, Barnes B, Johnson S, Polley L, Barker IK, et al. Alveolar hydatid disease (*Echinococcus multilocularis*) in the liver of a Canadian dog in British Columbia, a newly endemic region. Can Vet J. 2012;53:870–4.

119. Schweiger A, Ammann RW, Candinas D, Clavien P-A, Eckert J, Gottstein B, et al. Human Alveolar Echinococcosis after Fox Population Increase, Switzerland. Emerg Infect Dis. 2007;13:878–82.

120. Al Saghier M, Taylor MC, Greenberg HM. Canadian-Acquired Hydatid Disease: A Case Report. Can J Infect Dis Med Microbiol. NaN/NaN/NaN;12:178–82.

121. Zajac A, Fairman D, McGee E, Wells B, Peregrine A, Jenkins E, et al. Alveolar echinococcosis in a dog in the eastern United States. J Vet Diagn Invest. 2020;32:742–6.

122. McManus DP, Zhang W, Li J, Bartley PB. Echinococcosis. Lancet Br Ed. 2003;362:1295–304.

123. Santa MA, Pastran SA, Klein C, Duignan P, Ruckstuhl K, Romig T, et al. Detecting co-infections of *Echinococcus multilocularis* and *Echinococcus canadensis* in coyotes and red foxes in Alberta, Canada using real-time PCR. Int J Parasitol Parasites Wildl. 2018;7:111–5.

124. Pipas MJ, Fowler DR, Bardsley KD, Bangoura B. Survey of coyotes, red foxes and wolves from Wyoming, USA, for *Echinococcus granulosus* s. l. Parasitol Res. 2021;120:1335–40.

125. ROMANO MN, BRUNETTI OA, SCHWABE CW, ROSEN MN. Probable transmission of *Echinococcus granulosus* between deer and coyotes in California. J Wildl Dis. 1974;10:225–7.

126. Hildreth MB, Sriram S, Gottstein B, Wilson M, Schantz PM. Failure to identify alveolar Echinococcosis in trappers from South Dakota in spite of high prevalence of *Echinococcus multilocularis* in wild canids. J Parasitol. 2000;86:75–7.

127. Cerda JR, Buttke DE, Ballweber LR. *Echinococcus* spp. Tapeworms in North America. Emerg Infect Dis. 2018;24:230–5.

128. Conlon CL, Schuler KL, Lejeune M, Whipps CM. Novel report of the European variant of *Echinococcus multilocularis* in coyotes (*Canis latrans*) in New York state. J Parasitol. 2023;109:357–61.

129. Massolo A, Liccioli S, Budke C, Klein C. *Echinococcus multilocularis* in North America: the great unknown. Parasite. 2014;21:73.

130. Franson JC, Jorgenson RD, Boggess EK, Greve JH. Gastrointestinal Parasitism of Iowa Coyotes in Relation to Age. J Parasitol. 1978;64:303–5.

131. Redman WK, Bryant JE, Ahmad G. Gastrointestinal helminths of Coyotes (*Canis latrans*) from Southeast Nebraska and Shenandoah area of Iowa. Vet World. 2016;9:970–5.

132. Watts A, Alexander S. Community Variation of Gastrointestinal Parasites Found in Urban and Rural Coyotes (*Canis latrans*) of Calgary, Alberta. Cities Environ CATE [Internet]. 2012;4. Available from: https://digitalcommons.lmu.edu/cate/vol4/iss1/11

133. Gompper ME, Goodman RM, Kays RW, Ray JC, Fiorello CV, Wade SE. A Survey of the Parasites of Coyotes (*Canis latrans*) in New York based on Fecal Analysis. J Wildl Dis. 2003;39:712–7.

134. Pence DB, Knowlton FF, Windberg LA. Transmission of *Ancylostoma caninum* and *Alaria marcianae* in Coyotes (*Canis latrans*). J Wildl Dis. 1988;24:560–3.

135. Henke SE, Pence DB, Bryant FC. Effect of short-term coyote removal on populations of coyote helminths. J Wildl Dis. 2002;38:54–67.

136. Hinton JW, Chamberlain MJ. Evidence of reduced abundance, density, and survival of coyotes under federal management for red wolf recovery. Ecosphere. 2022;13:e4216.

137. Saadatnia G, Golkar M. A review on human toxoplasmosis. Scand J Infect Dis. 2012;44:805–14.

138. Matta SK, Rinkenberger N, Dunay IR, Sibley LD. *Toxoplasma gondii* infection and its implications within the central nervous system. Nat Rev Microbiol. 2021;19:467–80.

139. Aguirre AA, Longcore T, Barbieri M, Dabritz H, Hill D, Klein PN, et al. The One Health Approach to Toxoplasmosis: Epidemiology, Control, and Prevention Strategies. EcoHealth. 2019;16:378–90.

140. Dubey JP. History of the discovery of the life cycle of *Toxoplasma gondii.* Int J Parasitol. 2009;39:877–82.

141. S. Al-Malki E. Toxoplasmosis: stages of the protozoan life cycle and risk assessment in humans and animals for an enhanced awareness and an improved socio-economic status. Saudi J Biol Sci. 2021;28:962–9.

142. Attias M, Teixeira DE, Benchimol M, Vommaro RC, Crepaldi PH, De Souza W. The life-cycle of *Toxoplasma gondii* reviewed using animations. Parasit Vectors. 2020;13:588.

143. Calero-Bernal R, Gennari SM. Clinical Toxoplasmosis in Dogs and Cats: An Update. Front Vet Sci [Internet]. 2019 [cited 2023 Oct 3];6. Available from: https://www.frontiersin.org/articles/10.3389/fvets.2019.00054

144. Lindsay DS, Kelly EJ, McKown RD, Stein FJ, Plozer J, Herman J, et al. Prevalence of *Neospora caninum* and *Toxoplasma gondii* Antibodies in Coyotes (*Canis latrans*) and Experimental Infections of Coyotes with *Neospora caninum*. J Parasitol. 1996;82:657–9.

145. Dubey JP, Storandt ST, Kwok OCH, Thulliez P, Kazacos KR. *Toxoplasma gondii* Antibodies in Naturally Exposed Wild Coyotes, Red Foxes, and Gray Foxes and Serologic Diagnosis of Toxoplasmosis in Red Foxes Fed T. gondii Oocysts and Tissue Cysts. J Parasitol. 1999;85:240–3.

146. Dubey JP, Sundar N, Nolden CA, Samuel MD, Velmurugan GV, Bandini LA, et al. Characterization of Toxoplasma gondii from Raccoons (*Procyon lotor*), Coyotes (*Canis latrans*), and Striped Skunks (*Mephitis mephitis*) in Wisconsin Identified Several Atypical Genotypes. J Parasitol. 2007;93:1524–7.

147. Gerhold RW, Saraf P, Chapman A, Zou X, Hickling G, Stiver WH, et al. *Toxoplasma gondii* seroprevalence and genotype diversity in select wildlife species from the southeastern United States. Parasit Vectors. 2017;10:508.

148. Dubey JP, Murata FHA, Cerqueira-Cézar CK, Kwok OCH. Recent epidemiologic and clinical *Toxoplasma gondii* infections in wild canids and other carnivores: 2009–2020. Vet Parasitol. 2021;290:109337.

149. Dubey JP, Murata FHA, Cerqueira-Cézar CK, Kwok OCH. Recent epidemiologic and clinical *Toxoplasma gondii* infections in wild canids and other carnivores: 2009–2020. Vet Parasitol. 2021;290:109337.

150. Schellenberg RS, Tan BJK, Irvine JD, Stockdale DR, Gajadhar AA, Serhir B, et al. An Outbreak of Trichinellosis Due to Consumption of Bear Meat Infected with *Trichinella nativa* in 2 Northern Saskatchewan Communities. J Infect Dis. 2003;188:835–43.

151. Margolis HS, Middaugh JP, Burgess RD. Arctic Trichinosis: Two Alaskan Outbreaks from Walrus Meat. J Infect Dis. 1979;139:102–5.

152. Zarlenga D, Thompson P, Pozio E. *Trichinella* species and genotypes. Res Vet Sci. 2020;133:289–96.

153. Crisóstomo-Jorquera V, Landaeta-Aqueveque C. The genus *Trichinella* and its presence in wildlife worldwide: A review. Transbound Emerg Dis. 2022;69:e1269–79.

154. Madsen H. The principles of the epidemiology of trichinelliasis with a new view on the life cycle. Princ Epidemiol Trichinelliasis New View Life Cycle. 1974;615–38.

155. Capó V, Despommier DD. Clinical aspects of infection with *Trichinella* spp. Clin Microbiol Rev. 1996;9:47–54.

156. Beahm EH, Jorgensen MN. Some Effects of Experimental Trichinosis in the Dog. Proc Soc Exp Biol Med. 1941;47:294–9.

157. Forbes LB, Gajadhar AA. A Validated *Trichinella* Digestion Assay and an Associated Sampling and Quality Assurance System for Use in Testing Pork and Horse Meat. J Food Prot. 1999;62:1308–13.

158. Pozio E, La Rosa G. PCR-Derived Methods for the Identification of *Trichinella* Parasites from Animal and Human Samples. In: Sachse K, Frey J, editors. PCR Detect Microb Pathog. Totowa, NJ: Humana Press; 2003;p. 299–309.

159. Hill DE, Samuel MD, Nolden CA, Sundar N, Zarlenga DS, Dubey JP. *Trichinella murrelli* in scavenging mammals from south-central Wisconsin, USA. J Wildl Dis. 2008;44:629–35.

160. Zimmermann WJ, Hubbard ED, Schwarte LH, Biester HE. *Trichinella spiralis* in Iowa wildlife during the years 1953 to 1961. J Parasitol. 1962;429–32.

161. Pozio E, Pence DB, La Rosa G, Casulli A, Henke SE. *Trichinella* Infection in Wildlife of the Southwestern United States. J Parasitol. 2001;87:1208–10.

162. Reichard MV, Tiernan KE, Paras KL, Interisano M, Reiskind MH, Panciera RJ, et al. Detection of *Trichinella murrelli* in coyotes (*Canis latrans*) from Oklahoma and North Texas. Vet Parasitol. 2011;182:368–71.

163. Van Den Bussche RA, Kennedy ML, Wilhelm WE. Helminth Parasites of the Coyote (*Canis latrans*) in Tennessee. J Parasitol. 1987;73:327–32.

164. Velasco-Villa A, Reeder SA, Orciari LA, Yager PA, Franka R, Blanton JD, et al. Enzootic Rabies Elimination from Dogs and Reemergence in Wild Terrestrial Carnivores, United States. Emerg Infect Dis. 2008;14:1849–54.

165. Banyard AC, McElhinney LM, Johnson N, Fooks AR. Introduction History of rabies control by vaccination. Rev Sci Tech Int Off Epizoot. 2018;37:305–22.

166. Wallace RM, Gilbert A, Slate D, Chipman R, Singh A, Wedd C, et al. Right Place, Wrong Species: A 20-Year Review of Rabies Virus Cross Species Transmission among Terrestrial Mammals in the United States. PLOS ONE. 2014;9:e107539.

167. Pieracci EG, Pearson CM, Wallace RM, Blanton JD, Whitehouse ER, Ma X, et al. Vital Signs: Trends in Human Rabies Deaths and Exposures — United States, 1938–2018. Morb Mortal Wkly Rep. 2019;68:524–8.

168. Ma X, Monroe BP, Wallace RM, Orciari LA, Gigante CM, Kirby JD, et al. Rabies surveillance in the United States during 2019. J Am Vet Med Assoc. 2021;258:1205–20.

169. Maurya I, Vagholkar K, Patel B, Siddiqui M, Tiwari S, Maurya P. State of Globe: Rabies: The Lethality Since Antiquity! J Glob Infect Dis. 2015;7:1–2.

170. Takayama N. Rabies: a preventable but incurable disease. J Infect Chemother. 2008;14:8–14.

171. Schnell MJ, McGettigan JP, Wirblich C, Papaneri A. The cell biology of rabies virus: using stealth to reach the brain. Nat Rev Microbiol. 2010;8:51–61.

172. Mayes B, Rupprecht CE. Chapter Eight - Direct Fluorescent Antibody Test for Rabies Diagnosis. In: Rupprecht C, Nagarajan T, editors. Curr Lab Tech Rabies Diagn Res Prev Vol 2. Academic Press; 2015. p. 83–92.

173. Sacramento D, Bourhy H, Tordo N. PCR technique as an alternative method for diagnosis and molecular epidemiology of rabies virus. Mol Cell Probes. 1991;5:229–40.

174. Derakhshan I. Is the Negri Body Specific for Rabies?: A Light and Electron Microscopical Study. Arch Neurol. 1975;32:75–9.

175. Press Release - US Declared Canine-Rabies Free [Internet]. CDC Online Newsroom. 2007 [cited 2023 Sep 24]. Available from: https://www.cdc.gov/media/pressrel/2007/r070907.htm

176. Fehlner-Gardiner C. Rabies control in North America - past, present and future. Rev Sci Tech Int Off Epizoot. 2018;37:421–37.

177. Ma X, Bonaparte S, Toro M, Orciari LA, Gigante CM, Kirby JD, et al. Rabies surveillance in the United States during 2020. J Am Vet Med Assoc. 2022;260:1157–65.

178. Pope JP, Miller DL, Riley MC, Anis E, Wilkes RP. Characterization of a novel Canine distemper virus causing disease in wildlife. J Vet Diagn Invest. 2016;28:506–13.

179. Rendon-Marin S, da Fontoura Budaszewski R, Canal CW, Ruiz-Saenz J. Tropism and molecular pathogenesis of canine distemper virus. Virol J. 2019;16:30.

180. Roelke-Parker ME, Munson L, Packer C, Kock R, Cleaveland S, Carpenter M, et al. A canine distemper virus epidemic in Serengeti lions (Panthera leo). Nature. 1996;379:441–5.

181. Beineke A, Baumgärtner W, Wohlsein P. Cross-species transmission of canine distemper virus—an update. One Health. 2015;1:49–59.

182. Thorne ET, Williams ES. Disease and Endangered Species: The Black-footed Ferret as a Recent Example. Conserv Biol. 1988;2:66–74.

183. Riley MC, Wilkes RP. Sequencing of emerging canine distemper virus strain reveals new distinct genetic lineage in the United States associated with disease in wildlife and domestic canine populations. Virol J. 2015;12:1–10.

184. Kapil S, Yeary TJ. Canine Distemper Spillover in Domestic Dogs from Urban Wildlife. Vet Clin Small Anim Pract. 2011;41:1069–86.

185. Charles Povey R. Persistent Viral Infection: The Carrier State. Vet Clin North Am Small Anim Pract. 1986;16:1075–95.

186. Summers BA, Greisen HA, Appel MJG. Does virus persist in the uvea in multiple sclerosis, as in canine distemper encephalomyelitis? The Lancet. 1983;322:372–5.

187. Sykes JE, Vandevelde M. 22 - Canine Distemper Virus Infection. In: Sykes JE, editor. Greenes Infect Dis Dog Cat Fifth Ed. Philadelphia: W.B. Saunders; 2021. p. 271–88.

188. Headley SA, Amude AM, Alfieri AF, Bracarense APFRL, Alfieri AA, Summers BA. Molecular Detection of Canine Distemper Virus and the Immunohistochemical Characterization of the Neurologic Lesions in Naturally Occurring Old Dog Encephalitis. J Vet Diagn Invest. 2009;21:588–97.

189. Karki M, Rajak KK, Singh RP. Canine morbillivirus (CDV): a review on current status, emergence and the diagnostics. VirusDisease. 2022;33:309–21.

190. Kubo T, Kagawa Y, Taniyama H, Hasegawa A. Distribution of Inclusion Bodies in Tissues from 100 Dogs Infected with Canine Distemper Virus. J Vet Med Sci. 2007;69:527–9.

191. Guo W, Evermann JF, Foreyt WJ, Knowlton FF, Windberg LA. Canine distemper virus in coyotes: a serologic survey. J Am Vet Med Assoc. 1986;189:1099–100.

192. Kimpston CN, Hatke AL, Castelli B, Otto N, Tiffin HS, Machtinger ET, et al. High Prevalence of Antibodies against Canine Parvovirus and Canine Distemper Virus among Coyotes and Foxes from Pennsylvania: Implications for the Intersection of Companion Animals and Wildlife. Microbiol Spectr. 2022;10:e02532-21.

193. Davidson WR, Appel MJ, Doster GL, Baker OE, Brown JF. Diseases and parasites of red foxes, gray foxes, and coyotes from commercial sources selling to fox-chasing enclosures. J Wildl Dis. 1992;28:581–9.

194. Gese EM, Schultz RD, Rongstad OJ, Andersen DE. Prevalence of Antibodies against Canine Parvovirus and Canine Distemper Virus in Wild Coyotes in Southeastern Colorado. J Wildl Dis. 1991;27:320–3.

195. Malmlov A, Breck S, Fry T, Duncan C. Serologic Survey for Cross-Species Pathogens in Urban Coyotes (*Canis latrans*), Colorado, USA. J Wildl Dis. 2014;50:946–50.

196. Decaro N, Buonavoglia C. Canine parvovirus—A review of epidemiological and diagnostic aspects, with emphasis on type 2c. Vet Microbiol. 2012;155:1–12.

197. Nandi S, Kumar M. Canine Parvovirus: Current Perspective. Indian J Virol. 2010;21:31–44.

198. Ford J, McEndaffer L, Renshaw R, Molesan A, Kelly K. Parvovirus Infection Is Associated With Myocarditis and Myocardial Fibrosis in Young Dogs. Vet Pathol. 2017;54:964–71.

199. Decaro N, Desario C, Beall MJ, Cavalli A, Campolo M, DiMarco AA, et al. Detection of canine parvovirus type 2c by a commercially available in-house rapid test. Vet J. 2010;184:373–5.

200. Schmitz S, Coenen C, Matthias K, Heinz-Jürgen T, Neiger R. Comparison of Three Rapid Commercial Canine Parvovirus Antigen Detection Tests with Electron Microscopy and Polymerase Chain Reaction. J Vet Diagn Invest. 2009;21:344–5.

201. Walter-Weingärtner J, Bergmann M, Weber K, Truyen U, Muresan C, Hartmann K. Comparison of Eight Commercially Available Faecal Point-of-Care Tests for Detection of Canine Parvovirus Antigen. Viruses. 2021;13:2080.

202. Mech LD, Almberg ES, Smith D, Goyal S, Singer RS. Use of Real-time PCR to Detect Canine Parvovirus in Feces of Free-ranging Wolves. J Wildl Dis. 2012;48:473–6.

203. Haake DA, Levett PN. Leptospirosis in Humans. In: Adler B, editor. Leptospira Leptospirosis. Berlin, Heidelberg: Springer; 2015. p. 65–97.

204. Gravekamp C, Korver H, Montgomery J, Everard COR, Carrington D, Ellis WA, et al. Leptospires Isolated from Toads and Frogs on the Island of Barbados. Zentralblatt Für Bakteriol. 1991;275:403–11.

205. Centers for Disease Control. Prioritizing Zoonotic Diseases for Multisectoral, One Health collaboration in the United States. 2018 [cited 2023 Oct 3]. Available from: https://www.cdc.gov/onehealth/what-we-do/zoonotic-disease-prioritization/us-workshops.html

206. Helman SK, Tokuyama AFN, Mummah RO, Stone NE, Gamble MW, Snedden CE, et al. Pathogenic *Leptospira* are widespread in the urban wildlife of southern California. Sci Rep. 2023;13:14368.

207. Meites E, Jay MT, Deresinski S, Shieh W-J, Zaki SR, Tompkins L, et al. Reemerging Leptospirosis, California. Emerg Infect Dis. 2004;10:406–12.

208. Smith AM, Stull JW, Moore GE. Potential Drivers for the Re-Emergence of Canine Leptospirosis in the United States and Canada. Trop Med Infect Dis. 2022;7:377.

209. van de Maele I, Claus A, Haesebrouck F, Daminet S. Leptospirosis in dogs: a review with emphasis on clinical aspects. Vet Rec. 2008;163:409–13.

210. Dziezyc J. Canine Systemic Bacterial Infections. Vet Clin North Am Small Anim Pract. 2000;30:1103–17.

211. Monahan AM, Callanan JJ, Nally JE. Review Paper: Host-Pathogen Interactions in the Kidney during Chronic Leptospirosis. Vet Pathol. 2009;46:792–9.

212. Carrillo-Larco RM, Altez-Fernandez C, Acevedo-Rodriguez JG, Ortiz-Acha K, Ugarte-Gil C. Leptospirosis as a risk factor for chronic kidney disease: A systematic review of observational studies. PLoS Negl Trop Dis. 2019;13:e0007458.

213. Gautam R, Wu C-C, Guptill LF, Potter A, Moore GE. Detection of antibodies against *Leptospira* serovars via microscopic agglutination tests in dogs in the United States, 2000–2007. J Am Vet Med Assoc. 2010;237:293–8.

214. Gleiser CA. Experimental Canine Leptospirosis: III. Histopathologic Changes. J Infect Dis. 1957;100:249–56.

215. Chitwood MC, Swingen MB, Lashley MA, Flowers JR, Palamar MB, Apperson CS, et al. Parasitology and serology of free-ranging coyotes (*Canis latrans*) in North Carolina, usa. J Wildl Dis. 2015;51:664–9.

216. Miller DL, Schrecengost J, Merrill A, Kilgo J, Ray HS, Miller KV, et al. Hematology, Parasitology, and Serology of Free-Ranging Coyotes (*Canis latrans*) from South Carolina. J Wildl Dis. 2009;45:863–9.

217. Pedersen K, Anderson TD, Maison RM, Wiscomb GW, Pipas MJ, Sinnett DR, et al. *Leptospira* antibodies detected in wildlife in the USA and the US Virgin Islands. J Wildl Dis. 2018;54:450–9.

218. DREWEK J Jr, NOON TH, TRAUTMAN RJ, BICKNELL EJ. Serologic evidence of leptospirosis in a southern Arizona coyote population. J Wildl Dis. 1981;17:33–7.

219. Trainer DO, Knowlton FF. Serologic Evidence of Diseases in Texas Coyotes. J Wildl Manag. 1968;32:981–3.

220. Shearer KE, Harte MJ, Ojkic D, DeLay J, Campbell D. Detection of *Leptospira* spp. in wildlife reservoir hosts in Ontario through comparison of immunohistochemical and polymerase chain reaction genotyping methods. Can Vet J. 2014;55:240–8.

221. Kugeler KJ, Schwartz AM, Delorey MJ, Mead PS, Hinckley AF. Estimating the Frequency of Lyme Disease Diagnoses, United States, 2010–2018. Emerg Infect Dis. 2021;27:616.

222. Lantos PM, Nigrovic LE, Auwaerter PG, Fowler VG, Ruffin F, Brinkerhoff RJ, et al. Geographic Expansion of Lyme Disease in the Southeastern United States, 2000–2014. Open Forum Infect Dis. 2015;2:ofv143.

223. Wong KH, Shapiro ED, Soffer GK. A Review of Post-treatment Lyme Disease Syndrome and Chronic Lyme Disease for the Practicing Immunologist. Clin Rev Allergy Immunol. 2022;62:264–71.

224. Mac S, Silva SR da, Sander B. The economic burden of Lyme disease and the cost-effectiveness of Lyme disease interventions: A scoping review. PLOS ONE. 2019;14:e0210280.

225. Hickling GJ, Kelly JR, Auckland LD, Hamer SA. Increasing Prevalence of *Borrelia burgdorferi* sensu stricto–Infected Blacklegged Ticks in Tennessee Valley, Tennessee, USA. Emerg Infect Dis. 2018;24:1713–6.

226. Leber M, Moncrief ND, Gatens LJ, Michel M, Brinkerhoff RJ. Use of mammalian museum specimens to test hypotheses about the geographic expansion of Lyme disease in the southeastern United States. Ticks Tick-Borne Dis. 2022;13:102018.

227. Arsnoe IM, Hickling GJ, Ginsberg HS, McElreath R, Tsao JI. Different Populations of Blacklegged Tick Nymphs Exhibit Differences in Questing Behavior That Have Implications for Human Lyme Disease Risk. PLOS ONE. 2015;10:e0127450.

228. Marques AR. Lyme Disease: A Review. Curr Allergy Asthma Rep. 2010;10:13–20.

229. Pritt BS, Mead PS, Johnson DKH, Neitzel DF, Respicio-Kingry LB, Davis JP, et al. Identification of a novel pathogenic *Borrelia* species causing Lyme borreliosis with unusually high spirochaetaemia: a descriptive study. Lancet Infect Dis. 2016;16:556–64.

230. Radolf JD, Caimano MJ, Stevenson B, Hu LT. Of ticks, mice and men: understanding the dual-host lifestyle of Lyme disease spirochaetes. Nat Rev Microbiol. 2012;10:87–99.

231. Pearson P, Rich C, Feehan MJR, Ditchkoff SS, Rich SM. White-Tailed Deer Serum Kills the Lyme Disease Spirochete, *Borrelia burgdorferi*. Vector-Borne Zoonotic Dis. 2023;23:303–5.

232. Voordouw MJ. Co-feeding transmission in Lyme disease pathogens. Parasitology. 2015;142:290–302.

233. Ullmann AJ, Lane RS, Kurtenbach K, Miller M, Schriefer ME, Zeidner N, et al. Bacteriolytic Activity of Selected Vertebrate Sera for *Borrelia burgdorferi* Sensu Stricto and *Borrelia bissettii*. J Parasitol. 2003;89:1256–7.

234. Ginsberg HS, Hickling GJ, Burke RL, Ogden NH, Beati L, LeBrun RA, et al. Why Lyme disease is common in the northern US, but rare in the south: The roles of host choice, host-seeking behavior, and tick density. PLOS Biol. 2021;19:e3001066.

235. Fritz CL, Kjemtrup AM. Lyme borreliosis. J Am Vet Med Assoc. 2003;223:1261–70.

236. Parry N. Canine borreliosis: epidemiology, pathogenesis, clinical signs, and diagnostics. Companion Anim. 2016;21:323–31.

237. Littman MP. Lyme nephritis. J Vet Emerg Crit Care. 2013;23:163–73.

238. Littman MP, Gerber B, Goldstein RE, Labato MA, Lappin MR, Moore GE. ACVIM consensus update on Lyme borreliosis in dogs and cats. J Vet Intern Med. 2018;32:887–903.

239. Hutton T a., Goldstein R e., Njaa B l., Atwater D z., Chang Y-F, Simpson K w. Search for *Borrelia burgdorferi* in Kidneys of Dogs with Suspected “Lyme Nephritis.” J Vet Intern Med. 2008;22:860–5.

240. Susta L, Uhl EW, Grosenbaugh DA, Krimer PM. Synovial Lesions in Experimental Canine Lyme Borreliosis. Vet Pathol. 2012;49:453–61.

241. Chou J, Wünschmann A, Hodzic E, Borjesson DL. Detection of Borrelia burgdorferi DNA in tissues from dogs with presumptive Lyme borreliosis. J Am Vet Med Assoc. 2006;229:1260–5.

242. Burgess EC, Windberg LA. Borrelia sp. infection in coyotes, black-tailed jack rabbits and desert cottontails in southern Texas. J Wildl Dis. 1989;25:47–51.

243. Armstrong BA, Kneubehl A, Krishnavajhala A, Wilder HK, Boyle W, Wozniak E, et al. Seroprevalence for the tick-borne relapsing fever spirochete Borrelia turicatae among small and medium sized mammals of Texas. PLoS Negl Trop Dis. 2018;12:e0006877.

244. Yu S, Modarelli J, Tomeček JM, French JT, Hilton C, Esteve-Gasent MD. Prevalence of common tick-borne pathogens in white-tailed deer and coyotes in south Texas. Int J Parasitol Parasites Wildl. 2020;11:129–35.

245. Starkey LA, West MD, Barrett AW, Saucier JM, O'Connor TP, Paras KL, et al. Prevalence of antibodies to spotted fever group *Rickettsia* spp. and *Ehrlichia* spp. in coyotes (*Canis latrans*) in Oklahoma and Texas, USA. J Wildl Dis. 2013;49:670–3.

246. Pluemer M, Dubay S, Drake D, Crimmins S, Veverka T, Hovanec H, et al. Red foxes (*Vulpes vulpes*) and coyotes (*Canis latrans*) in an urban landscape: prevalence and risk factors for disease. J Urban Ecol. 2019;5:juz022.

247. Izac JR, Camire AC, Schuler EJ, Hatke AL, O'Bier NS, Oliver Jr LD, et al. Serologic evidence for the exposure of eastern coyotes (Canis latrans) in Pennsylvania to the tick-borne pathogens *Borreliella burgdorferi* and *Anaplasma phagocytophilum*. Msphere. 2020;5:e00544-20.

248. Banks A. Investigating the Role of Coyotes, Canis Latrans, in the Spread of Parasites and Arthropod-Borne Diseases in Georgia, USA. 2019;

249. Smith KA, Oesterle PT, Jardine CM, Dibernardo A, Huynh C, Lindsay R, et al. Tick infestations of wildlife and companion animals in Ontario, Canada, with detection of human pathogens in *Ixodes scapularis* ticks. Ticks Tick-Borne Dis. 2019;10:72–6.

250. Sidge JL, Foster ES, Buttke DE, Hojgaard A, Graham CB, Tsao JI. Lake Michigan insights from island studies: the roles of chipmunks and coyotes in maintaining *Ixodes scapularis* and *Borrelia burgdorferi* in the absence of white-tailed deer. Ticks Tick-Borne Dis. 2021;12:101761.

251. Kollars TM Jr, Oliver JH Jr, Kollars PG, Durden LA. Seasonal Activity and Host Associations of *Ixodes scapularis* (Acari: Ixodidae) in Southeastern Missouri. J Med Entomol. 1999;36:720–6.

252. Richardson M, Khouja C, Sutcliffe K. Interventions to prevent Lyme disease in humans: A systematic review. Prev Med Rep. 2019;13:16–22.

253. Kugeler KJ, Jordan RA, Schulze TL, Griffith KS, Mead PS. Will Culling White-Tailed Deer Prevent Lyme Disease? Zoonoses Public Health. 2016;63:337–45.

254. Bloemer SR, Zimmerman RH. Ixodid Ticks on the Coyote and Gray Fox at Land between the Lakes, Kentucky–Tennessee, and Implications for Tick Dispersal. J Med Entomol. 1988;25:5–8.

# CHAPTER I
# *HEPATOZOON* SPP. INFECTION IN WILD CANIDS IN THE EASTERN UNITED STATES

A version of this chapter was originally published by Eliza Baker, Alex Jensen, Debra Miller, Kayla Buck Garrett, Christopher A. Cleveland, Justin Brown, Kyle Van Why, and Richard Gerhold

Baker E, Jensen A, Miller D, Garrett KB, Cleveland CA, Brown J, Van Why K, Gerhold R. Hepatozoon spp. infection in wild canids in the eastern United States. Parasites & Vectors. 2023 Oct 19;16(1):372.

Author EB performed necropsies, histology, PCR, statistics, and writing. Author RG provided mentorship and editing. Author DM provided pathology assessment. Authors AJ, KG, CC, JB, and KVW provided samples.

## Abstract

*Hepatozoon* spp. are apicomplexan parasites known to cause musculoskeletal disease in a variety of animals. Two species are known to infect wild and domestic canids in the United States: *H. canis* and *H. americanum.* In this study, blood, heart, and/or spleen samples were collected from 278 wild canids (180 coyotes, 93 red foxes, and 5 gray foxes) in the eastern United States and tested via PCR for *Hepatozoon*. Histology slides of heart and skeletal muscle were assessed for *Hepatozoon* cysts and associated inflammation when fresh tissue was available (n=96). *Hepatozoon* spp. were found in 24.2% (59/278) of individuals, with *H. canis* in 14.0% (34/278) and *H. americanum* in 10.7% (26/278). One coyote was positive for both *H. canis* and *H. americanum.* Foxes were more likely to be positive for *H. canis* than coyotes (23% and 7% respectively, p=0.0008), while only coyotes were positive for *H. americanum.* Of the eight sampled states, *H. canis* was present in six (Louisiana, North Carolina, Pennsylvania, South Carolina, Tennessee, and Virginia) while *H. americanum* was found in two southern states (South Carolina and Louisiana). Infection status was positively correlated with myositis and myocarditis, and heart or muscle cysts were found in 83% (5/6) of *H. americanum*-positive coyotes. This survey showed a moderate prevalence of *H. canis* and *H. americanum* in states where the parasite was previously unrecorded including South Carolina and Pennsylvania.

## Background

*Hepatozoon* is a genus of apicomplexan parasites known to cause musculoskeletal disease in numerous terrestrial vertebrate species [1]. Hepatozoonosis is generally limited to the range of its tick definitive host, which varies by species and geographic area. Transmission occurs via ingestion of infected ticks or cystozoites in vertebrate hosts [2,3]. In canids, there are two species known to cause disease: *H. canis*, the agent of Old World hepatozoonosis, and *H. americanum*, the agent of American canine hepatozoonosis (ACH) [2]. *Hepatozoon canis,* though common in South America, southern Europe, Asia, and Africa, was not documented in the United States until 2008 [4]. Since then, it has been reported in seven southern states: Alabama, Georgia, Mississippi, Louisiana, Oklahoma, Virginia, and West Virginia [5,6]. *H. canis* typically causes mild disease in domestic dogs and may be discovered incidentally on blood smears or autopsy [2]. In patients with high levels of parasitemia, it can cause lethargy, fever, and anemia [2]. Little is known about transmission of *H. canis* in the United States. The brown dog tick (*Rhipicephalus sanguineus sensu lato*) is the accepted vector, though alternative methods of transmission may exist [6]. The Asian longhorned tick (*Haemaphysalis longicornis*), which has recently been introduced in the United States, has been suggested as a possible competent vector for *H. canis* as well, and researchers have found oocysts in *H. longicornis* ticks pulled from dogs with hepatozoonosis [7,8].

American canine hepatozoonosis is an emerging disease known to cause severe muscle pain, osteoproliferation, hyperesthesia, and death in domestic dogs [2,9]. The parasite was first discovered in 1978 in coyotes (*Canis latrans)* from Texas [10]. ACH is restricted to the range of its vector, the Gulf Coast tick (*Ambylomma maculatum*), which historically has been found in a 150-mile range around the Gulf of Mexico, ranging from southern Texas in the west to Virginia in the east [11]. However, in recent years, the tick has been documented as far north as Delaware and Illinois, and ACH has been documented as far from the Gulf as Vermont and California, though travel history for those cases in unknown [5,12].

There are several suggested mechanisms contributing to the geographic expansion of the Gulf Coast tick and *H. americanum,* including the movement of vertebrate hosts and climate change. The transport of cattle for agriculture is responsible for the initial expansion of *A. maculatum* to the central United States [13]. Migratory birds, which are known to host larval *A. maculatum* ticks, may also play a significant role in its spread [14]. In addition, climate modeling predicts that the tick's range will continue to expand northward as the climate warms, with suitable habitats predicted to extend as far north as Maine [15].

The role of wild canids in the epidemiology of ACH is poorly understood. Investigations into wildlife reservoirs have found a high prevalence in coyotes in the southern United States. For example, a 2013 study in Oklahoma and Texas showed a prevalence of 79.5% (35/44) when examining histology, whole blood PCR, and muscle PCR of the 18S ribosomal RNA gene [16]. Genetic diversity was high, with 19 distinct sequences and up to seven different haplotypes infecting an individual coyote. Only one *H. canis* infection was found, and the remaining genotypes were either *H. americanum* or an intermediate species between the two.

Coyotes appear more resistant to clinical disease than domestic dogs, though experimental infections have shown they can develop osteoproliferative lesions similar to dogs [17]. Investigations into wild canids in areas outside of the south-central United States are limited, and coyotes' role in the lifecycle is unclear. Some researchers believe that coyotes act as important wildlife reservoirs for the disease, while others believe both wild and domestic canids are accidental hosts, and there is an unknown intermediate host that serves as the primary reservoir [2]. Regardless, further research is necessary to understand the spread and potential impact of this disease on both domestic dogs and wild canids in the United States. We conducted a prevalence survey of wild canids throughout the eastern United States, a region that has not been assessed for this pathogen on a wide scale since 2008 [5]. We hypothesized that *H. americanum* would be prevalent in southern states and absent in the north and that *H. canis* would be found rarely in both foxes and coyotes. In addition, we hypothesized that infected canids would have higher rates of myositis and myocarditis compared to negative canids.

## Methods

We opportunistically collected a total of 278 coyote, red fox (*Vulpes vulpes*), and gray fox (*Urocyon cinereoargenteus)* tissue samples from a variety of sources and collaborators including rabies testing facilities, road-killed animals, and wildlife resources agencies (Table 1). Whole blood and/or heart tissue was collected between 2019-2023 from wild canids in South Carolina (n=59), Tennessee (n=73), and Virginia (n=15), and splenic samples were collected from wild canids between 2021-2022 from Louisiana (n=27), Pennsylvania (n=92), Georgia (n=3), North Carolina (n=7), and Maryland (n=2). We obtained 94 whole carcasses Tennessee (n=71), South Carolina (n=15), and Virginia (n=8). Heart tissue only was available from 2 Tennessee coyotes.

DNA was extracted from 100µl of whole blood (n=141), 10mg of spleen (n=131), and/or 25mg of heart (n=90) using DNeasy Blood and Tissue extraction kits following manufacturer's instructions (Qiagen Inc, Germantown, Maryland, USA). A negative water control was used during each extraction. PCR was performed using nested PCR primers targeting the 18S rRNA gene of all *Hepatozoon* spp. and other closely related apicomplexans, using both negative extraction and negative PCR controls [4,18]. Primers 5.1 (CCTGGTTGATCCTGCCAGTAGT) and 3.1 (CTCCTTCCTTTAAGTGATAAG) were used for the external reaction. Primary cycling conditions were as follows: initial denaturation for 5 minutes at 95°C followed by 35 cycles of 94°C for 1 minute, 56°C for 1 minute, and 72°C for 1.5 minutes, and a final annealing step of 72°C for 7 minutes. The internal reaction used primers RLB-F (GAGGTAGTGACAAGAAATAACAATA) and RLB-R (TCTTCGATCCCCTAACTTTC) and 1µL of the primary product. The secondary reaction cycling conditions were the same as the primary except the annealing temperature was lowered to 52°C. Extracted DNA from an *H. americanum* positive dog was used as the positive control. PCR products were visualized on 1.5% agarose gel and amplicon bands between 550-570bp were purified with ExoSAP-IT PCR Product Cleanup Reagent (Thermo Fisher Scientific, Waltham, MA) and sequenced with Sanger sequencing at the University of Tennessee, Knoxville's Division of Biological Sequencing.

Amplicon sequences were analyzed in Sequencher v. 5.4.6 (Gene Codes Corporation, Ann Arbor, MI) and those with multiple sequences were cloned using the pGEM-T Easy Vector System (Promega Corporation, Madison, WI) following manufacturer's instructions. Plasmids were purified using MiniPrep Plasmid Purification kits (Thermo Fisher Scientific, Waltham, MA) following manufacturer's instructions. Sequences were deposited in GenBank under accession numbers OQ592065-OQ592143. Sequences were aligned in BioEdit, and phylogenetic trees were made using the Neighbor-Joining algorithm with the Kimura 2-parameter model with 500 bootstrap replicates in MegaX (v10.1.7) [19]. We removed identical sequences to improve the readability of the tree.

We examined histopathology slides from tongue, heart, and gracilis muscle when tissue was available (n=96), with assistance from a veterinary pathologist (author DM). We classified the inflammation as mild if it was found rarely throughout the slide and did not disrupt surrounding tissues and moderate if it disrupted the surrounding tissues but was present only focally or multifocally. We considered the inflammation severe if it was found throughout the slide and disrupted the surrounding tissue. Statistical analysis was performed using SAS v9.4 (SAS Institute, Cary, North Carolina, USA). Chi-squared tests were used to assess statistical differences between species, infection status, and histopathologic inflammation.

## Results

Sixty-five percent of samples were from coyotes (n=180) and 35% from foxes (93 red foxes and 5 gray foxes). *Hepatozoon* spp. were detected via PCR in 21% (59/278) of the individuals tested; 9% (26/278) were positive for *H. americanum* and 12% (34/278) were positive for *H. canis* (Table 1). One coyote from South Carolina was co-infected with both species. All canids with cysts present on histology were also positive on PCR of blood or tissue. *Hepatozoon americanum* was exclusively found in coyotes, where it was present in 14% (26/180) of canids. *Hepatozoon canis* was found in both coyotes (7%, 13/180) and red foxes (22.5%, 21/93). All gray foxes were negative for *Hepatozoon* spp. (n=5). The likelihood of *H. canis* infection in red foxes was significantly higher than in coyotes ($X^2$=14.2, df=1, p=0.0008).

Infections with any species of *Hepatozoon* were identified in six of the eight tested states (Figure 1). *Hepatozoon americanum* was only found in two of the tested states: South Carolina (39% [23/59] of coyotes), and Louisiana, (12% [3/25] of coyotes). *Hepatozoon canis* was found in all tested states except for Georgia and Maryland (Table 1). However, these two states had less than four individuals each, making assessment of prevalence impossible. Paired blood and tissue samples were available for 86 of the canids. Blood and tissue PCR agreed 99% of the time, with only one canid from Virginia positive for *H. canis* on heart but negative on blood.

Phylogenetic alignment of the 18S rRNA gene performed using one sequence for each unique sequence group, along with related organisms and *Adelina bambarooniae* (AF494058) as the outgroup, resulted in a 488-bp alignment of which 390 were invariant and 32 of the 98 variable characters were parsimony informative. The top match in GenBank for each unique sequence was included in the tree for comparison. Sequence

analysis of the *Hepatozoon* sequences revealed 34 unique sequences. Cloning was performed on eleven PCR products, with up to four unique sequences present within an individual sample. One coyote was co-infected with both *H. americanum* and *H. canis.*

*Hepatozoon americanum* sequences were between 94.2%-100% similar to each other, with 46% (21/45) of *H. americanum* sequences >99.5% similar to several sequences from dogs (e.g. EU146062 and AY864676) and coyotes (e.g. JX415170-JX415174) in the southern United States. We found a second group of sequences (n=11) that aligned more closely with *H. americanum* than *H. canis* but did not fully resolve into the *H. americanum* clade. These sequences most closely aligned with several sequences in GenBank including a South American gray fox (*Lycalopex griseus*) from Argentina (MK049949) and a Pampas fox (*Lycalopex gymnocercus*) from Uruguay (MZ230033). We found minimal genetic diversity in the *H. canis* sequences, with sequences 98.2-100% similar to each other and 79% (27/34) of sequences aligning >99.5% with several sequences from around the world including foxes from France (MK673844-MK673850), gray wolves from Germany (MN791089), and a dog from Cuba (MN393911). We found another distinct genotype of *H. canis* in five canids from Virginia, Tennessee, and North Carolina (OQ592106-OQ592110) which aligned 99.78% with several sequences from around the world including dogs from Thailand (MK830996), Algeria (MK645969), Nigeria (OP837324) and India (JN584477). Two Louisiana canids (OQ592117 and OQ592118) aligned 100% with a coyote from Oklahoma (JX415165). Unlike *H. americanum,* we did not find any evidence of paralogues or coinfection with multiple genotypes of *H. canis.*

Histopathology was processed from 96 of the 248 total samples. Heart tissue was processed for 91 coyotes and 5 foxes; gracilis muscle was processed for 89 coyotes and 4 foxes; tongue was processed for 37 coyotes and 4 foxes; and spleen processed for 89 coyotes and 4 foxes. Cysts were found in the heart or skeletal muscle of five coyotes, all of which were positive for *H. americanum* on PCR (Figure 2). Eighty-three percent (5/6) of the *H. americanum*-positive specimens with histopathology had at least one cyst present in heart or skeletal muscle. Cysts were present by histology in both heart and skeletal muscle in two coyotes, in skeletal muscle alone in two coyotes, and in heart alone in one coyote. The *H. canis*-positive fox did not have cysts present on histology.

Two of the *Hepatozoon*-positive individuals had severe pathology. The *H. canis*-positive red fox also had sarcoptic mange that resulted in sepsis and severe suppurative myocarditis (Figure 3). One *H. americanum*-positive coyote had a regionally extensive abscess beneath its esophagus extending into the cervical bone and causing osteomyelitis. Evidence of sepsis and bacterial embolisms were present throughout most major organs. This coyote had the largest number of *Hepatozoon* cysts, with ten cysts in various stages of development found throughout the tongue, and occasional cysts found in the gracilis muscle and heart. In addition, two of the positive coyotes had limb abnormalities. One coyote was missing its back-left leg entirely after the mid-diaphysis of the femur, while the other had a shrunken back left leg about half the size of the right hind leg with the diaphysis of the femur replaced by dense connective tissue. The femur measured 7cm.

Myocarditis was present in 8.3% (8/96) of samples, and myositis was present in 10.8% (10/93) (Figure 3). The prevalence of myocarditis was statistically higher in

*Hepatozoon* spp.-positive canids than negative individuals ($X^2$=23.5, *df*=1, P<0.001), with myocarditis present in 57% (4/7) of positive cases compared to 4.5% (4/89) of negative cases. However, two myocarditis cases occurred in animals suffering from sepsis (the fox with sarcoptic mange and the coyote with osteomyelitis). Therefore, we re-assessed the statistical correlation between myocarditis and *Hepatozoon* status with those two cases removed, and the correlation remained ($X^2$=21.2, *df*=1, P=0.002). Likewise, myositis was found in 50% (3/6) of positive cases and only 8% (7/87) of negative cases ($X^2$=10.3, *df*=1, P=0.001). Skeletal muscle was not available from the sarcoptic fox or from two of the Tennessee coyotes. Both myositis and myocarditis were typically mild to moderate apart from the two septic animals (Figure 3).

## Discussion

*Hepatozoon* spp. infections are widespread in wild canids throughout the eastern United States. *Hepatozoon canis* was detected in six states in our study, while *H. americanum* was restricted to only two states in the south despite evidence that *A. maculatum* has spread as far north as Delaware [12]. Both foxes and coyotes were infected with *H. canis*, but *H. americanum* was detected exclusively in coyotes, potentially due to the low number of foxes sampled in the southern states. To the authors' knowledge, this is the first report of *H. canis* or *H. americanum* in South Carolina and Pennsylvania. Though evidence of infection was not found in two of the eight states (GA and MD), only three samples were collected from Georgia and only two from Maryland, making critical interpretation of prevalence in those states impossible.

There are limited studies on *Hepatozoon* spp. prevalence in the United States with which to compare our findings. A 2011 study published *Hepatozoon* spp. sequences from a variety of mammals in the southern United States, including five coyotes with *H. americanum* from Oklahoma and Texas and one gray fox with *H. canis* from Georgia [20]. Like our study, individual coyotes often had multiple different sequences of *H. americanum.* There are only two other surveys assessing prevalence in coyotes, both of which focused on the south-central United States. One survey reported *Hepatozoon* spp. prevalence of 40% in 20 coyotes in Oklahoma via histology, and a second study reported a prevalence of 80% in 44 coyotes in Oklahoma and Texas using a combination of histology and PCR [16,17]. Prevalence in the eastern United States was substantially lower. The cause for this lower prevalence is not fully clear. Coyotes only recently migrated across the eastern United States, beginning in the mid-1900s and not reaching the east coast until the late 1900s [21]. Although it is possible that *H. americanum* emerged in the east alongside this migration, further research is necessary to determine if the eastern migration of coyotes has impacted *H. americanum* prevalence.

A 2008 survey of *Hepatozoon* in the United States included samples from 614 domestic dogs with suspected hepatozoonosis, 455 of which were from the southeast [5]. It found *H. americanum* in 13 of 28 states, and 5 states had both *H. americanum* and *H. canis*. Unlike in our study, *Hepatozoon* was not found in Tennessee or Pennsylvania, and samples from South Carolina were not obtained. Positive cases were primarily found in the southeastern United States, though outliers with unknown travel history in Vermont, Washington, and California were detected [5].

Our study found a higher rate of *H. canis* than the domestic dog survey [5]. Only 4.6% (28/614) of domestic dogs were positive for *H. canis*, compared to the 12.4% (34/278) prevalence we found in wild canids. The relative percentages of each *Hepatozoon* species were also markedly different between domestic dogs and our study. Only 14.4% of *Hepatozoon* cases in domestic dogs were *H. canis* or mixed infections, while 57% of cases in wild canids from our study were *H. canis* or mixed infections. *H. canis* infections were rare in the Texas and Oklahoma coyote study as well, with only 2% (1/44) of coyotes positive [16]. The high prevalence of *H. canis* in our study is likely explained by our inclusion of foxes, which had a significantly higher prevalence than dogs or coyotes. Whether *H. canis* is more common in the east than the central United States remains to be seen, and future work assessing foxes in that area may clarify the question. Though the domestic dog study found a higher prevalence of *H. americanum* than we did (29.4% vs. 10.4%), a direct comparison cannot be made since the dog survey targeted suspected positive dogs, while ours sampled all individuals [5].

Despite the severe clinical signs of ACH in domestic dogs, infection did not appear to cause significant lesions in coyotes. However, infection status was positively correlated with risk of myocarditis and myositis. Myositis was six times more likely in positive individuals, while myocarditis was over ten times more likely. However, with only seven positive cases processed for histopathology, two of which had confounding factors, further research is necessary to determine the strength of this correlation. Even if the correlation persists in larger surveys, a causal connection could not be established from surveys alone given that *Hepatozoon* spp. infection is commonly associated with co-infections that may be the true cause of inflammation [22–25].

Though two of the six *H. americanum*-positive coyotes had limb abnormalities, this is not likely a result of ACH. ACH is known to cause osteoproliferation and musculoskeletal pain, but loss of limbs or severe limb deformities are not known symptoms. In addition, the coyote with the missing hind limb survived at least 1.5 years after initial sampling and was in good body condition at the time of autopsy. It is possible that *Hepatozoon* infection can be exacerbated by immunosuppression. Domestic dogs typically only develop clinical signs from *H. canis* if they are immunosuppressed or co-infected with other diseases like *Babesia, Leishmania,* or *Toxoplasma gondii* [2]. The coyote with sepsis had notably increased numbers of *Hepatozoon* cysts compared to all other positives, suggesting that replication may increase during times of stress or illness. The *H. canis*-positive red fox with sarcoptic mange unfortunately only had heart, skin, and kidney processed for histopathology, none of which are the typical locations to find meronts. Therefore, though we did not find meronts, we cannot assess the extent of its *H. canis* infection.

We found variable levels of genetic diversity (94.2%-100% similar) in the *H. americanum*-positive coyotes. Forty-two percent of the positive coyotes (11/26) had evidence of multiple different sequences of *H. americanum* present. Previous work on *Hepatozoon* in coyotes suggested these different sequences were evidence of coinfection with multiple related *Hepatozoon* species, but intraspecific variation of the 18S gene (paralogues) have been documented in *H. canis* and numerous other apicomplexan species [16,20,26]. Therefore, we cannot definitively say which is the case in these

samples. Though most sequences fully resolved into the *H. americanum* clade, a subset fell in between *H. canis* and *H. americanum* (Figure 4). Similar sequences were found previously in coyotes from Texas and Oklahoma [16].

We found lower genetic diversity (98.2-100%) in our *H. canis* sequences compared to *H. americanum*, with most sequences differing by less than three base pairs. This limited diversity has been documented in previous work, which classified *H. canis* 18S rRNA sequences into five genotypes, with each genotype differing by five base pairs or fewer [27]. A larger survey assessing various haplotypes of the 18S gene of *H. canis* worldwide found 76 total haplotypes [28]. However, of the 61 sequences they assessed from the Americas, they found over 50% of them differed by fewer than two base pairs, matching the results from our study. It is interesting that three different *H. canis* genotypes were documented in southern states while only one genotype was documented in the north. This suggests diversity may be higher in the south, although further research is necessary to verify this assessment.

This study provided a clearer understanding of the geographic distribution of *Hepatozoon* spp. in the eastern United States. Wild canids appear to play a significant role in maintaining the sylvatic lifecycle of *Hepatozoon*. A high prevalence in wildlife implies a high percentage of infected ticks in the area and can be used as a proxy for domestic dog risk. In addition, *Hepatozoon* prevalence can provide a better understanding of its vectors' prevalence in the area. The tick vectors of *Hepatozoon* may carry other pathogens including *Ehrlichia canis (R. sanguineus s.l.*), *Babesia vogeli* (*R. sanguineus s.l.*), *Francisella tularensis* (*A. maculatum*), *Rickettsia parkeri* (*A. maculatum*), and *Rickettsia rickettsii* (*R. sanguineus s.l.*) [15,29–32]. These pathogens may lead to severe disease in dogs on their own or contribute to the severity of coinfections, and both *Rickettsia* spp. pathogens can cause life-threatening disease in people [29,32]. Though hepatozoonosis is still considered rare in domestic dogs, the high prevalence in wild canids suggests a high potential rate of exposure, and the disease should be among the differentials for dogs presenting with muscle pain, fever, and neutrophilia.

Limitations of this study include the opportunistic nature of collection, the limited sample size in certain states, and the variability of available tissue samples from individual canids. Future work can help fill in the geographic gaps of this survey to better understand the distribution and impact of this pathogen. In addition, future studies should strive to use whole carcasses for analysis whenever possible to give a clearer picture of tissue tropisms and tissue responses. Though our study found a high agreement between histology and PCR results, a previous study showed disagreement between the two methods, and the gold standard for diagnosis is still considered muscle biopsy [2,16]. Therefore, assessment of *Hepatozoon* spp. prevalence ideally would always include both histology and PCR. Further research is necessary to assess this disparity, though PCR of whole blood may be a reasonable, less invasive alternative diagnostic tool in cases where obtaining a muscle biopsy is not practical. Finally, phylogenetic analysis using only a small section of the 18S rRNA gene may miss significant variation found elsewhere in the gene. Future studies can improve our understanding of canid *Hepatozoon* genotypes by using longer sequences or full genome sequencing.

## Conclusion

*Hepatozoon* is a widespread parasite infecting wild canids throughout the eastern United States. *H. canis* is far more common, particularly in foxes, than previously realized. Mild inflammation in both the skeletal muscle and the heart were more likely in infected individuals.

# References


1. Smith TG. The genus *Hepatozoon* (Apicomplexa: Adeleina). J Parasitol. 996;82:565–85.

2. Allen KE, Johnson EM, Little SE. *Hepatozoon* spp infections in the United States. Vet Clin Small Anim Pract.; 2011;41:1221–38.

3. Johnson EM, Allen KE, Panciera RJ, Little SE, Ewing SA. Infectivity of *Hepatozoon americanum* cystozoites for a dog. Vet Parasitol. 2008;154:148–50.

4. Allen KE, Li Y, Kaltenboeck B, Johnson EM, Reichard MV, Panciera RJ, et al. Diversity of *Hepatozoon* species in naturally infected dogs in the southern United States. Vet Parasitol. 2008;154:220–5.

5. Li Y, Wang C, Allen KE, Little SE, Ahluwalia SK, Gao D, et al. Diagnosis of canine *Hepatozoon* spp. infection by quantitative PCR. Vet Parasitol. 2008;157:50–8.

6. Kistler WM, Brown JD, Allison AB, Nemeth NM, Yabsley MJ. First report of *Angiostrongylus vasorum* and *Hepatozoon* from a red fox (*Vulpes vulpes*) from West Virginia, USA. Vet Parasitol. 2014;200:216–20.

7. Pritt BS. *Haemaphysalis longicornis* Is in the United States and Biting Humans: Where Do We Go From Here? Clin Infect Dis Off Publ Infect Dis Soc Am. 2020;70:317–8.

8. Murata T, Inoue M, Taura Y, Nakama S, Abe H, Fujisaki K. Detection of *Hepatozoon canis* oocyst from ticks collected from the infected dogs. J Vet Med Sci. 1995;57:111–2.

9. Coy CL, Evans JB, Lee AM, Dugat DR, Levine JM, Griffin JF. American canine hepatozoonosis causes multifocal periosteal proliferation on CT: A Case Report of 4 Dogs. Front Vet Sci. 2022;9:872778.

10. Davis DS, Robinson RM, Craig TM. Naturally occurring hepatozoonosis in a coyote. J Wildl Dis. 1978;14:244–6.

11. Phillips VC, Zieman EA, Kim C-H, Stone CM, Tuten HC, Jiménez FA. Documentation of the expansion of the Gulf Coast tick (*Amblyomma maculatum*) and *Rickettsia parkeri*: first report in Illinois. J Parasitol. 2020;106:9–13.

12. Maestas LP, Reeser SR, McGay PJ, Buoni MH. Surveillance for *Amblyomma maculatum* (Acari: Ixodidae) and *Rickettsia parkeri* (Rickettsiales: Rickettsiaceae) in the state of Delaware, and their public health implications. J Med Entomol. 2020;57:979–83.

13. Paddock CD, Goddard J. The Evolving Medical and Veterinary Importance of the Gulf Coast tick (Acari: Ixodidae). J Med Entomol. 2015;52:230–52.

14. Nadolny RM, Gaff HD. Natural history of *Amblyomma maculatum* in Virginia. Ticks Tick-Borne Dis. 2018;9:188–95.

15. Alkishe A, Peterson AT. Climate change influences on the geographic distributional potential of the spotted fever vectors *Amblyomma maculatum* and *Dermacentor andersoni*. PeerJ. 2022;10:e13279.

16. Starkey LA, Panciera RJ, Paras K, Allen KE, Reiskind MH, Reichard MV, et al. Genetic diversity of *Hepatozoon* spp. in coyotes from the south-central United States. J Parasitol. 2013;99:375–8.

17. Kocan AA, Cummings CA, Panciera RJ, Mathew JS, Ewing SA, Barker RW. Naturally occurring and experimentally transmitted *Hepatozoon americanum* in coyotes from Oklahoma. J Wildl Dis. 2000;36:149–53.

18. Yabsley MJ, Davidson WR, Stallknecht DE, Varela AS, Swift PK, Devos JJ, et al. Evidence of tick-borne organisms in mule deer (*Odocoileus hemionus*) from the western United States. Vector Borne Zoonotic Dis. 2005;5:351–62.

19. Hall TA. BioEdit: a user-friendly biological sequence alignment editor and analysis program for Windows 95/98/NT. Nucleic Acids Symp Ser. [London]: Information Retrieval Ltd., c1979-c2000.; 1999. p. 95–8.

20. Allen KE, Yabsley MJ, Johnson EM, Reichard MV, Panciera RJ, Ewing SA, et al. Novel *Hepatozoon* in vertebrates from the southern United States. J Parasitol. 2011;97:648–53.

21. Hody JW, Kays R. Mapping the expansion of coyotes (*Canis latrans*) across North and Central America. ZooKeys. 2018;81–97.

22. Sasanelli M, Paradies P, Lubas G, Otranto D, De Caprariis D. Atypical clinical presentation of coinfection with *Ehrlichia*, *Babesia* and *Hepatozoon* species in a dog. Vet Rec. 2009;164:22.

23. Andersson M, Turcitu MA, Stefanache M, Tamba P, Barbuceanu F, Chitimia L. First evidence of *Anaplasma platys* and *Hepatozoon canis* co-infection in a dog from Romania–a case report. Ticks Tick-Borne Dis. 2013;4:317–9.

24. Rojas A, Rojas D, Montenegro V, Gutiérrez R, Yasur-Landau D, Baneth G. Vector-borne pathogens in dogs from Costa Rica: first molecular description of *Babesia vogeli* and *Hepatozoon canis* infections with a high prevalence of monocytic ehrlichiosis and the manifestations of co-infection. Vet Parasitol. 2014;199:121–8.

25. Morgado FN, Cavalcanti A dos S, Miranda LH de, O'Dwyer LH, Silva MRL da, Menezes RC, et al. *Hepatozoon canis* and *Leishmania* spp. coinfection in dogs diagnosed with visceral leishmaniasis. Rev Bras Parasitol Veterinária. 2016;25:450–8.

26. Léveillé AN, Baneth G, Barta JR. Next generation sequencing from *Hepatozoon canis* (Apicomplexa: Coccidia: Adeleorina): Complete apicoplast genome and multiple mitochondrion-associated sequences. Int J Parasitol. 2019;49:375–87.

27. Hodžić A, Georges I, Postl M, Duscher GG, Jeschke D, Szentiks CA, et al. Molecular survey of tick-borne pathogens reveals a high prevalence and low genetic variability of *Hepatozoon canis* in free-ranging grey wolves (*Canis lupus*) in Germany. Ticks Tick-Borne Dis. 2020;11:101389.

28. Vásquez-Aguilar AA, Barbachano-Guerrero A, Angulo DF, Jarquín-Díaz VH. Phylogeography and population differentiation in *Hepatozoon canis* (Apicomplexa: Hepatozoidae) reveal expansion and gene flow in world populations. Parasit Vectors. 2021;14. https://doi.org/10.1186/s13071-021-04924-x.

29. Stiles J. Canine Rickettsial Infections. Vet Clin North Am Small Anim Pract. 2000;30:1135–49.

30. Lira J, Rojas C, Alvarez A, Pelaez A, Martinez Ibañez F, Perez D, et al. First molecular detection of *Babesia canis vogeli* in dogs and *Rhipicephalus sanguineus* from Mexico. Arch Palliat Care. 2017;2:1013.

31. Wikswo ME, Hu R, Metzger ME, Eremeeva ME. Detection of *Rickettsia rickettsii* and *Bartonella henselae* in *Rhipicephalus sanguineus* ticks from California. J Med Entomol. 2007;44:158–62.

32. Nicholson WL, Allen KE, McQuiston JH, Breitschwerdt EB, Little SE. The increasing recognition of rickettsial pathogens in dogs and people. Trends Parasitol. 2010;26:205–12.

# Appendix

**Table 1. Prevalence of *Hepatozoon* spp. in wild canids**

Total number positive is shown in each column, with the percent positives in parenthesis.

| State | Fox | | | Coyote | | |
|---|---|---|---|---|---|---|
| | Samples | *H. canis* (%) | *H. am* (%) | Samples | *H. canis* (%) | *H. am* (%) |
| GA | Spleen (n=3) | 0 | 0 | NA | - | - |
| LA | Spleen (n=2) | 1 (50) | 0 | Spleen (n=25) | 2 (8) | 3 (12) |
| MD | Spleen (n=1) | 0 | 0 | Spleen (n=1) | 0 | 0 |
| NC | Spleen (n=3) | 0 | 0 | Spleen (n=4) | 1 (25) | 0 |
| PA | Spleen (n=82) | 17 (21) | 0 | Spleen (n=10) | 7 (70) | 0 |
| SC | NA | - | - | Heart (n=9) | 0 | 2 (22) |
| | | | | Blood (n=59) | 2 (3) | 23 (39) |
| | | | | Histology (n=15) | 0 | 5 (33) |
| | | | | Total SC coyote (n=59) | 2 (3) | 23 (39) |
| TN | Heart (n=5) | 1 (20) | 0 | Heart (n=61) | 0 | 0 |
| | Blood (n=1) | 1 (100) | 0 | Blood (n=68) | 0 | 0 |
| | Histology (n=5) | 0 | 0 | Histology (n=66) | 0 | 0 |
| | Total TN fox (n=5) | 1 (20) | 0 | Total TN coyote (n=69) | 0 | 0 |
| VA | Heart (n=2) | 2 (100) | 0 | Heart (n=13) | 1 (8) | 0 |
| | Blood (n=2) | 1 (50) | 0 | Blood (n=13) | 1 (8) | 0 |
| | Total VA fox (n=2) | 2 (100) | 0 | Histology (n=8) | 0 | 0 |
| | | | | Total VA coyote (n=13) | 1 (8) | 0 |
| Total | Total fox (n=98) | 21 (21) | 0 | Total coyote (n=180) | 13 (7) | 26 (14) |

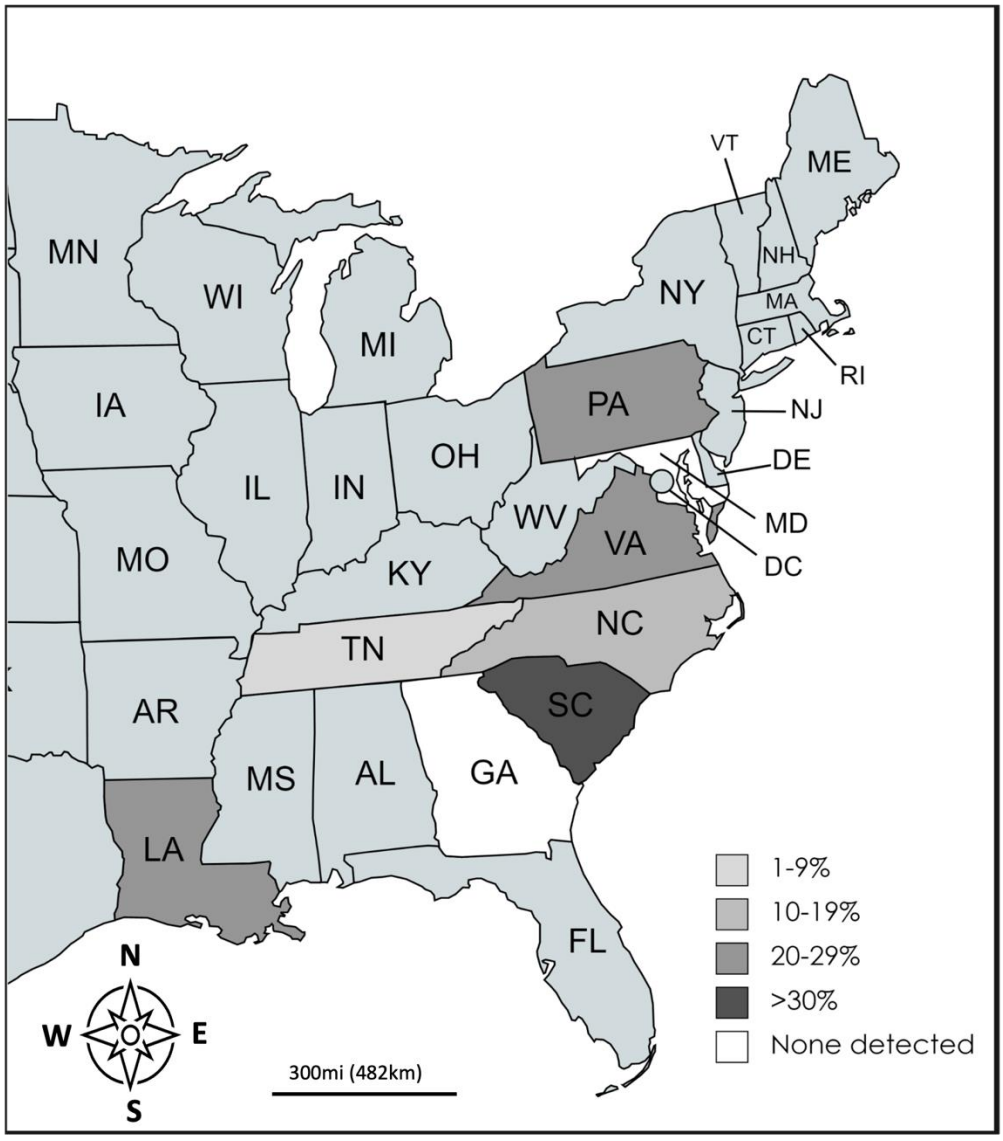


**Figure 1. *Hepatozoon* prevalence map.**

Prevalence of *Hepatozoon* spp. detected via PCR of heart, blood, and/or spleen in wild canids in the eastern United States.

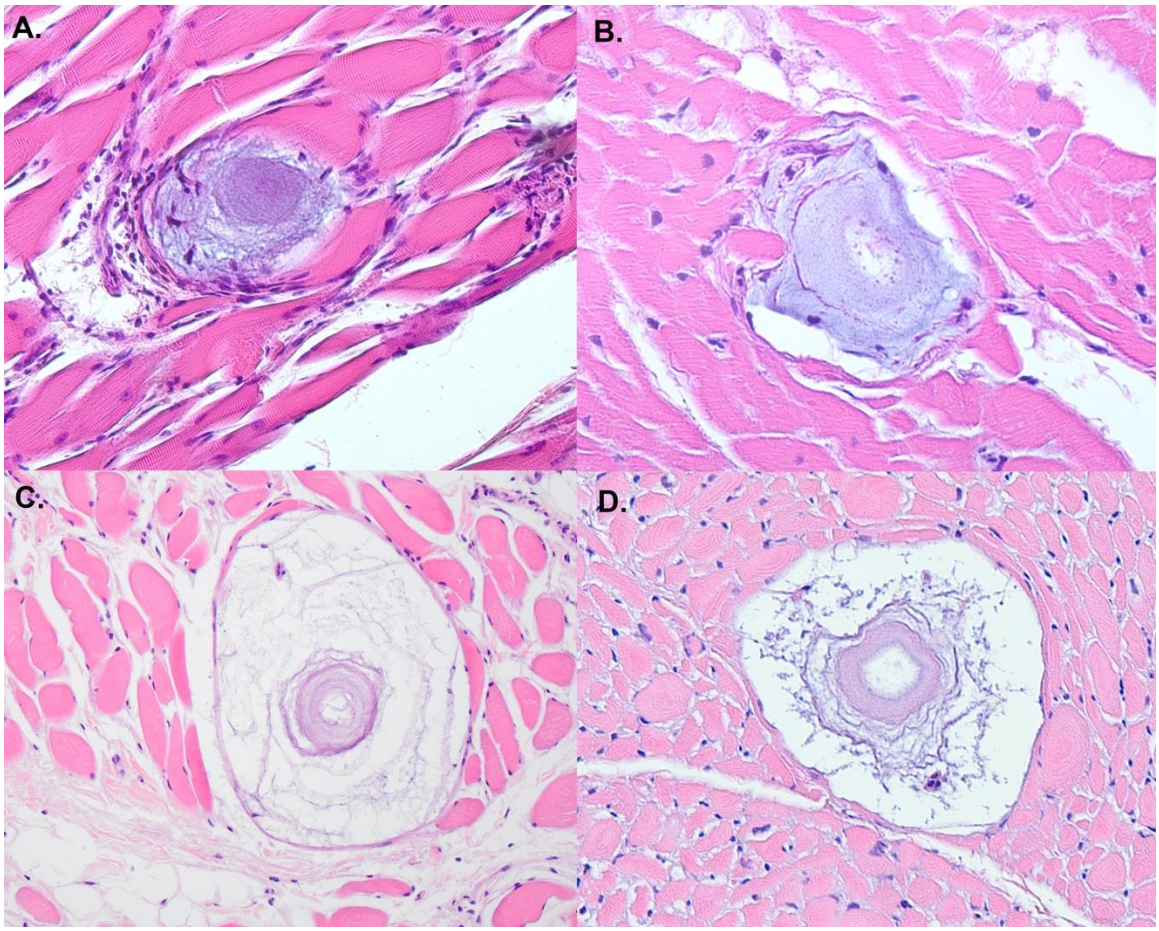


**Figure 2. *Hepatozoon americanum* cysts.**

Histology images of cysts in various stages of development from coyotes positive for *Hepatozoon* spp. collected in the eastern United States. *H. americanum* cysts were present in the gracilis muscle (A,D), heart (B), and tongue (C).

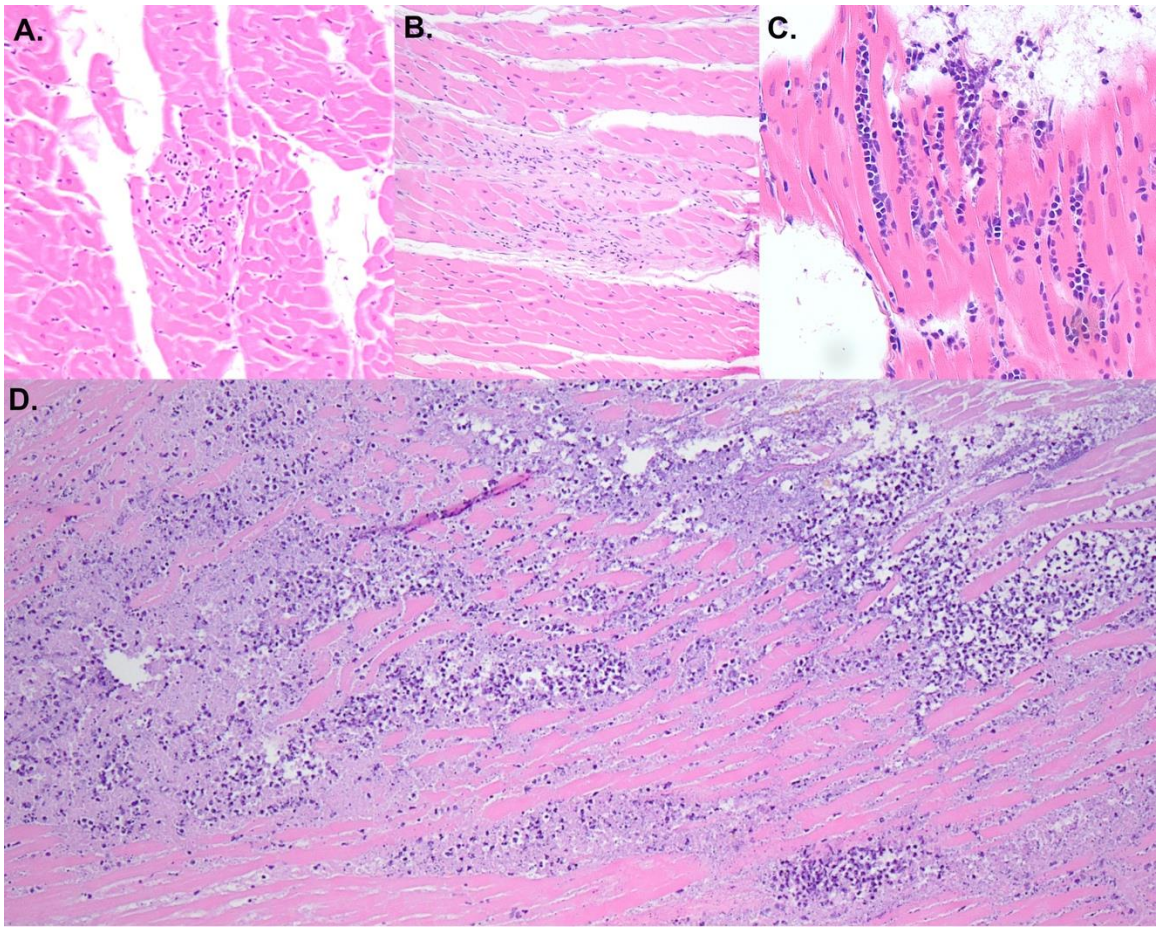


**Figure 3. Inflammation associated with *Hepatozoon* spp. infection.**

Histology images from *Hepatozoon*-positive coyotes showing examples of (A) mild, (B) moderate, and (C) severe myocarditis. The overwhelming suppurative myocarditis found in the red fox infected with both *Hepatozoon canis* and sarcoptic mange is shown in (D).

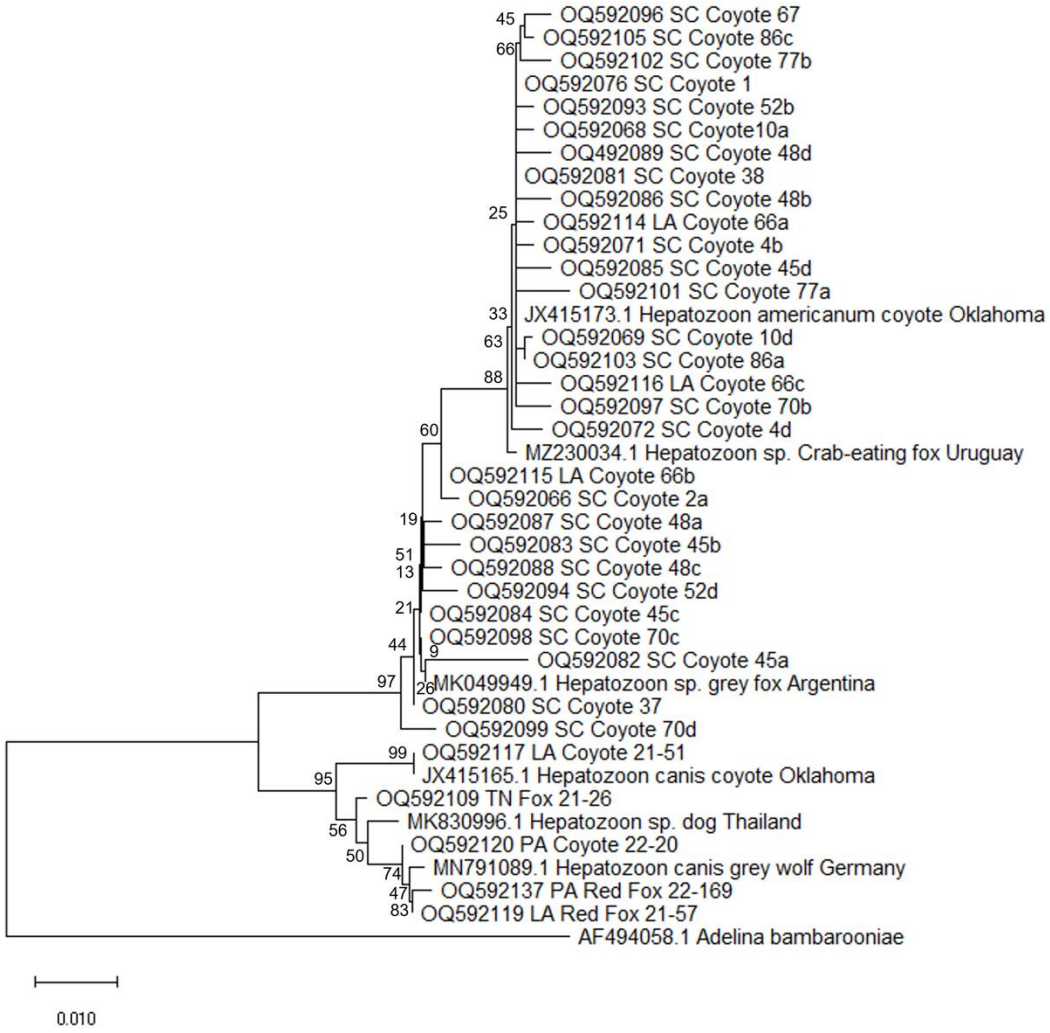


**Figure 4. Phylogenetic tree of *Hepatozoon* spp. in coyotes.**

Phylogeny of the partial 18s rRNA gene of *Hepatozoon* spp. found in wild canids in the eastern United States. *Adelina* was chosen as the outgroup. All unique sequences are shown. The phylogenetic tree was generated using the Neighbor-joining algorithm and a Kimura 2-parameter model in MegaX with (v10.1.7). The percentage of replicate trees in which the associated taxa clustered together in the bootstrap test (500 replicates) are shown next to the branches.

# CHAPTER II
# PREVALENCE AND DIVERSITY OF *BABESIA* IN THE EASTERN UNITED STATES

## Abstract

*Babesia* is a diverse genus of piroplasms that parasitize the red blood cells of a wide variety of mammals and avian species, including humans. A survey of 720 wild mammals found a high prevalence of infection in raccoons, foxes, and skunks, and low prevalence in Virginia opossums. No *Babesia* infection was found in coyotes, bears, groundhogs, muskrats, or mink. Skunks carried a diverse number of strains including a novel species of *Babesia* related to *B. gibsoni*, a strain closely related to a *B. microti*-like species known to cause disease in river otters, as well as a strain closely related to *B. microti*, which can infect humans. Raccoons primarily carried *B. microti*-like strains, though there was a high diversity of sequences including *Babesia* sp. *lotori*, *Babesia* sensu stricto MA230, and *Babesia* sp. 'Coco'. Foxes exclusively carried *B. vulpes.* In addition to *Babesia* spp., a high prevalence of *Hepatozoon* spp. infection was found in mink, while low prevalence was found in raccoons and muskrats.

## Background

Tick-borne diseases are on the rise in the United States due to a combination of factors including climate change, habitat fragmentation, and the expanding range of many tick vectors [1]. *Babesia*, an apicomplexan that parasitizes red blood cells in a wide variety of species, is no exception, with reported cases increasing by as much as 20-fold in certain parts of the country over the last two decades [2]. Although disease is generally mild in immunocompetent individuals, babesiosis can cause severe and even life-threatening hemolytic anemia in at-risk groups such as the young, elderly, splenectomized, and other immunocompromised individuals [3]. The taxonomy of *Babesia* and the entire order of Piroplasmida to which it belongs is under flux. However, currently the *Babesia* genus is classified into three primary clades: the western *Babesia* group, *Babesia* sensu stricto, and the *B. microti* complex [4–6]. Many researchers have argued that *B. microti* and *B. microti*-like organisms should be reclassified as a different genus to other *Babesia* species, but this change has yet to be made official [4–7]. *Babesia microti*, which is vectored by *Ixodes scapularis* (the black-legged tick), is the most common cause of human babesiosis in the United States, though infections with other species including *B. duncani* and *B. divergens* have been reported [8–10].

In addition to the potential negative impact on humans, *Babesia* spp. can cause severe illness in pets and livestock. Unlike human infections, which are diagnosed primarily in the Northeast and Midwest, canine babesiosis is most common in the southern and western United States. In dogs, *B. gibsoni*, which is commonly transmitted via blood contact (i.e., dog fighting), and *B. vogeli*, which is transmitted by the brown dog tick (*Rhipicephalus sanguineus*), are the most common causes of illness [11]. In addition, in recent years there have been several new species documented in dogs. *Babesia conradae*, which is closely related to species that affect livestock and humans, was first documented in 2006 and has since been associated with coyotes and coyote-hunting dogs in California [12,13]. It can cause severe hemolytic anemia and may be fatal without treatment [13]. *Babesia* sp. 'Coco' is a large *Babesia* species that was identified in 2004 and has since been sporadically identified as a cause of illness in splenectomized

and immunosuppressed dogs [14,15]. Finally, *Babesia vulpes*, which was reported in foxes in Spain before being documented in wild canids in the United States, has been found rarely as a cause of disease in dogs [16].

There are several species of *Babesia* documented in wild mesocarnivores in North America. Research in raccoons is perhaps the most robust, with a large-scale PCR survey in 2019 that assessed 699 raccoons from across the United States and Canada finding a 73% prevalence of infection [6]. PCR surveys in raccoons have also been performed in Florida, which found a 82% prevalence (14/17), and North Carolina, which found a 95% prevalence (39/41) [19,20]. At least three species have been documented in raccoons in the eastern United States: *B. lotori*, which is part of the *Babesia* sensu stricto (*B. s. s.*) clade, a different species in the *B. s. s.* clade that has been found in both Japanese and North American raccoons which we will refer to as *B. s. s.* MA230 in this paper based on the initial description, and *Babesia microti*-like, which is the nomenclature used to describe a diverse group of small *Babesia* species [6,17,18]. Though related to the zoonotic *B. microti*, *B. microti*-like species are not considered zoonotic. In fact, members of the *B. microti* clade are generally host specific, with the *B. microti*-like sequences found in raccoons distinct from those found in foxes [6]. Infection appears to be mild or subclinical in raccoons, and surveys have documented infection rates as high as 99% in certain southeastern states [6,17,19,20]. Coinfection with *Babesia microti*-like and *B. s. s.* species is common in raccoons, with studies finding coinfection rates ranging between 0% and 76% [6,19].

Foxes are also common carriers of *Babesia* species, typically *B. vulpes*, sometimes still referred to as *B. microti*-like or *Theileria annae*. A study in North Carolina and Canada found a prevalence of 39% (50/127) in red foxes and 26% (8/31) in gray foxes [21]. None of the twelve tested coyotes were found to be positive in that study. Little is known about *Babesia* species infecting wildlife other than rodents, foxes, and raccoons in the United States. Numerous species of *Babesia* have been documented in black bears (*Ursus americanus*), including sequences closely related to *B. microti*-like, *Babesia* sp. 'Coco', and *B. lotori* [22–24]. Prevalence in bears has varied dramatically by study, with reported prevalence ranging from 6% to 42% [22–24]. Skunks have been documented to carry several *Babesia* species including *B. mephitis* and an unclassified species very similar to human *B. microti*, but there are no molecular surveys assessing prevalence or genetic diversity in the species [25,26].

In addition to *Babesia* species, wildlife carry many other apicomplexan parasites that may cause disease in pets. Bobcats are known carriers of *Cytauxzoon felis*, a parasite often fatal in domestic cats [45]. *Hepatozoon* species can be either asymptomatic or a cause of severe muscle and heart inflammation in both wildlife and domestic animals [41-43]. Finally, *Besnoitia darlingi* is a cyst-forming protozoan that causes inflammation in Virginia opossums and uses both domestic and wild felids as definitive hosts [44].

Further research is necessary to understand the distribution, prevalence, and phylogenetics of *Babesia* spp. and other apicomplexans in wildlife. This information can then be used to inform diagnostic testing and risk to populations of interest like people and pets. Though previous surveys provide an excellent baseline, numerous states including Tennessee and Pennsylvania have not been assessed. In addition, surveys in

wildlife other than raccoons and rodents are rare. This study sought to fill in the knowledge gaps on the prevalence, distribution, and diversity of *Babesia* species that infect wildlife. We hypothesized that *Babesia* spp. infections would be common in raccoons and foxes, as previously documented, and present more rarely in other wildlife.

## Methods

Blood or tissue samples from wildlife were collected opportunistically from a variety of sources. In Tennessee, whole carcasses from rabies testing facilities or from animals that died in the University of Tennessee College of Veterinary Medicine's Wildlife and Exotics department were autopsied, and samples of blood and heart were saved frozen. In South Carolina, a collaborator performing a GPS collaring study on coyotes collected excess whole blood samples for testing. Finally, banked splenic samples from raccoons, skunks, mink, muskrats, bears, coyotes, foxes, and groundhogs were tested opportunistically from wildlife resources officers in various states.

DNA was extracted from 100µl of whole blood (n= 296), heart (n=58), and/or 10mg of spleen (n = 414) using DNeasy Blood and Tissue extraction kits following manufacturer's instructions (Qiagen Inc, Germantown, Maryland, USA). A negative nuclease-free water control was used during each extraction. PCR was performed using nested PCR primers targeting the 18S rRNA gene of all *Babesia* species and other closely related apicomplexans using both negative extraction and negative PCR controls. Primers 5.1 (CCTGGTTGATCCTGCCAGTAGT) and 3.1 (CTCCTTCCTTTAAGTGATAAG) were used for the external reaction [27]. Primary cycling conditions were as follows: initial denaturation for 5 minutes at 95°C followed by 35 cycles of 94°C for 1 minute, 58°C for 1 minute, and 72°C for 1.5 minutes, and a final annealing step of 72°C for 7 minutes. The internal reaction used primers RLB-F (GAGGTAGTGACAAGAAATAACAATA) and RLB-R (TCTTCGATCCCCTAACTTTC) and 1µL of the primary product [28]. The secondary reaction cycling conditions were the same as the primary except the annealing temperature was lowered to 54°C. Extracted DNA from a *Babesia microti*-like positive raccoon was used as the positive control. These primers can amplify other apicomplexan species including *Cytauxzoon* spp. and *Hepatozoon* spp. which also commonly infect wildlife.

A subset of positive samples representing at least one of each unique species found via 18S sequencing (n=35) were also assessed with primers targeting the cytochrome *c* oxidase subunit 1 gene of *Babesia* using primers Babcox F (GGAAGTGGWACWGGWTGGAC) and Babcox R (TTCGGTATTGCATGCCTTG) as previously described [4]. PCR products were visualized on 1.5% agarose gel and amplicon bands around 550bp for 18S and at 1080bp for *cox1* were purified with ExoSAP-IT PCR Product Cleanup Reagent (Thermo Fisher Scientific, Waltham, MA) and sequenced with Sanger sequencing at the University of Tennessee, Knoxville's Division of Biological Sequencing.

Amplicon sequences were analyzed in Sequencher v. 5.4.6 (Gene Codes Corporation, Ann Arbor, MI) and those with multiple sequences were cloned using the pGEM-T Easy Vector System (Promega Corporation, Madison, WI) following

manufacturer's instructions. Plasmids were purified using MiniPrep Plasmid Purification kits (Thermo Fisher Scientific, Waltham, MA) following manufacturer's instructions. Representatives of each unique sequence were deposited in GenBank, with 18S *Babesia* sequences under accession numbers PP231979-PP232025, 18S *Hepatozoon, Besnoitia,* and *Cytauxzoon* spp. under accession numbers PP234617-PP234624, and *Babesia* cox1 sequences under accession numbers PP253989-PP253997. Sequences were aligned in BioEdit, and phylogenetic trees were made using the Neighbor-Joining algorithm with the kimura 2-parameter model with 500 bootstrap replicates in MegaX (v10.1.7) [29]. Identical or near identical sequences (<2bp difference) were removed to improve the readability of the tree.

Histopathology was available from heart tissue from most Tennessee raccoons. Though *Babesia* infection is more likely to cause changes to the spleen, other apicomplexan species like *Hepatozoon* and *Besnoitia* may be identified in heart tissue [43,44]. During autopsy, pieces of left and right ventricle were placed in 10% buffered formalin and allowed to fix for 24-48 hours before trimming and embedding. Slides were stained with hematoxylin and eosin and reviewed with a board-certified pathologist (author MD) for inflammation and apicomplexan infection.

## Results

We processed a total of 720 samples: 185 coyotes (*Canis latrans*), 159 muskrats (*Ondatra zibethicus*), 123 raccoons (*Procyon lotor*), 94 red foxes (*Vulpes vulpes*), 64 striped skunks (*Mephitis mephitis*), 28 Virginia opossums (*Didelphis virginiana*), 28 black bears (*Ursus americanus*), 23 groundhogs (*Marmota monax*), 10 mink (*Neovison vison*), 5 gray foxes (*Urocyon cinereoargenteus*), and one bobcat (*Lynx rufus*). Samples were from 8 states: 375 from Pennsylvania, 233 from Tennessee, 58 from South Carolina, 27 from Louisiana, 15 from Virginia, 7 from North Carolina, 3 from Georgia, and 2 from Maryland. Summaries of which species from each state were positive for *Babesia* can be found in Table 2.

*Babesia* sp. infection was present in 19.2% (138/720) of samples. Raccoons had the highest prevalence of all wildlife species at 73.2% (90/123), while coyotes, mink, muskrat, bobcat, and bear all were PCR negative for *Babesia*. Of the remaining wildlife, 32.8% of skunks (21/64), 25.5% of red foxes (24/94), 40% of gray foxes (2/5), and 3.6% of Virginia opossums (1/28) were PCR positive for *Babesia* spp. The sequences from the foxes were 97-100% similar to each other and to *B. vulpes* sequences in GenBank (MT50998). The sequence from the Virginia opossum was 99.8% similar to *B. microti*-like sequences found in raccoons (MN011934). Skunks and raccoons had more diversity in the species they carried (Figure 5 and 6). Of the 90 positive raccoons, 58.4% (52/89) carried *B. microti*-like, 13.5% (12/89) carried *B. lotori*, 10.1% (9/89) carried *B. s. s.* MA230, 3.4% (3/89) carried *Babesia* sp. 'Coco', and 14.6% (13/89) had mixed infections. We identified three unique sequences from raccoons that were less than 97% similar to other 18S sequences available in GenBank. Of the novel sequences, two were most similar (94.6% and 96.2%) to *B. lotori* (MK580743) and one was 95.9% similar to *B. s. s.* MA230 (MK580742).

Skunks primarily carried a species only documented once before in skunks from Massachusetts that is highly related to the *B. microti* species that infect humans. Of the 21 positive skunks, 67% (n=14) were 99.4-100% similar to this sequence (AY144698). One skunk carried a sequence 100% similar to *B. s. s.* MA230 found in raccoons (MK580472), two were 98.7% similar to a *Babesia* species found previously in river otters (EF057099), and one was identical to *B. microti*-like sequences found in raccoons (MN011935). Two skunks, one each from Pennsylvania and Tennessee, carried unique sequences that were 95.3-95.6% similar to a species found in a fox from China (JX962779), which is related to *B. gibsoni.* Finally, one skunk had a mixed infection with one sequence 96.3% similar to the fox from China and one sequence 99.4% similar to the skunks from Massachusetts.

Red and gray foxes carried *B. vulpes* exclusively, and all sequences except two were identical to each other and to multiple *B. vulpes* sequences in GenBank. Prevalence was slightly higher in the southern U.S. with 100% of Tennessee gray foxes (2/2), 50% of TN red foxes (2/4), and 33.3% of Georgia red foxes (2/3) positive for *B. vulpes,* while only 24.4% (20/82) of Pennsylvania red foxes and 0% (0/2) of Virginia red foxes testing positive.

Sequencing with the COI primers was less sensitive than the 18S primers. Of the 35 samples we performed COI PCR on, we found clean sequences in only fourteen. PCR on animals carrying *B. vulpes, B. microti*-like, and *Babesia* sp. 'Coco' resulted in clean sequences, while those carrying novel sequences, *B. lotori,* or *B. s. s.* MA230 were less likely to be successfully amplified. We were unsuccessful in amplifying the COI gene of the novel sequence that most closely matched the fox from China, although we did amplify the COI gene in skunks that carried the *B. microti* sequence previously reported from MA. That COI sequence was novel and only 87.3% similar to other sequences in GenBank (KC207827). Unlike on the 18S gene, the skunk COI gene did not cluster with human *B. microti* sequences (Figure 6).

The primers used to amplify *Babesia* also amplify other apicomplexan species. *Hepatozoon* species were found in mink (70% [7/10]), muskrat (2.9% [4/140]), and raccoons (2.5% [3/122]). The sequences found in muskrats were identical to each other and 99.4% similar to *H. ophisauri,* which is a species that has been reported in lizards in Asia [30]. The *Hepatozoon* sequences in mink were identical to each other and 99% similar to a *Hepatozoon* species found in martens in Germany (OM256569). The *Hepatozoon* sequences in racoons were 97.5-98.5% similar to other *H. procyonis* sequences in GenBank. Of the 3 that were PCR positive, 2 had heart tissue histologically examined. Histologic findings revealed basophilic inclusions in leukocytes, moderate to severe myocarditis, and, in one case, a meront in the heart muscle (Figure 7). In addition, one raccoon that was PCR positive for *Babesia* on the 18S primers had evidence of *H. procyonis* infection in the heart including basophilic inclusion bodies and meronts. Despite cloning the PCR products, we only found *Babesia* sequences in this raccoon. It is likely that the raccoon was positive for *H. procyonis,* but the primers preferentially bound to the *Babesia* DNA.

*Hepatozoon canis* and *H. americanum* were found frequently in foxes and coyotes, and those results were detailed separately [31]. No coinfections with both

*Hepatozoon* spp. and *Babesia* spp. were detected. The bobcat was positive for *C. felis.* *Besnoitia darlingi* (2/28) was sequenced from heart tissue in two Virginia opossums.

## Discussion

A wide variety of *Babesia* species were found in wildlife in the eastern United States, including several novel sequences. Raccoons had a high prevalence of 73%, similar to what has been found in previous studies [6,19,20]. The most recent large-scale survey in the eastern United States, performed by Garrett et al, found a remarkably similar prevalence of 73.2% (512/699), while smaller surveys found higher prevalences of 95.1% (39/41) in NC and 82.4% (14/17) in FL [6,19,20]. Similar to the Garrett survey, we found *B. microti*-like sequences predominated in raccoons, while *B. lotori* and the *Babesia s. s.* MA230 were less frequent. Our 15% prevalence of mixed infection was lower than the 22% coinfection rate found in the previous survey. In addition to *B. microti*-like, *B. lotori,* and *B. s. s.* MA230, all of which have been frequently documented in the eastern United States, we also found *Babesia* sp. 'Coco' and 3 unique sequences that were <97% similar to any previously documented sequence in GenBank. Although *Babesia* sp. 'Coco' was not found in the Garrett survey, it has been found in raccoons in Texas [32]. All novel sequences in raccoons were found as part of mixed infections, and their significance is unclear. Further work assessing prevalence over time may help determine if these sequences are newly emerging or simply less common.

Minimal research on *Babesia* species in skunks has been performed in the past. *Babesia mephitis* was documented based on blood smear morphology in 1970, but no molecular data exists for this species [26]. *Babesia mephitis* is a large form *Babesia* (2.5μm x 4.75μm), and *B. microti, B. microti*-like, and *B. gibsoni,* the species which the skunk sequences are most similar to, are all small form *Babesia.* There is only one morphologic description of *Babesia s. s.* MA230, which was found in one skunk in our study, but that description also does not appear to match the description of *B. mephitis* [18]. Therefore, it is unlikely that any of the sequences found in our study are *B. mephitis.*

This study found that skunks primarily carry a species that is very closely related to zoonotic *B. microti,* though it is distinct from any sequence reported in humans. Its relationship to human *B. microti* was stronger at the 18S gene than the cox1 gene, suggesting a separate species whose zoonotic potential is unclear. In addition, skunks carried a novel sequence most closely related to *B. gibsoni.* However, the sequence was only 95% similar to the closest GenBank match and likely represents a novel species. This sequence was present in both skunks from Tennessee and Pennsylvania suggesting a wide geographic distribution. The potential zoonotic or domestic animal impacts are unclear, but given its relationship is to *B. gibsoni,* it may be capable of causing disease in domestic dogs. Skunks also carried a species that previously was documented in river otters. The skunk sequence was distinct from those in the river otter, but both are closely related to *B. vulpes* carried by foxes. This species has been shown to cause clinical symptoms in river otters, but its impact on skunks is not known [33].

None of the 145 coyotes tested positive for *Babesia,* even though both *B. vulpes* and *Babesia* sp. 'Coco' are known to infect domestic dogs and were found in this study in other wildlife [16,34]. In addition, *B. vogeli* is the most commonly reported large *Babesia*

species in domestic dogs in the United States and is found predominantly in the South [13]. It has been reported in coyotes from Texas, but surveillance in states further east is lacking [35]. One possible explanation for the lack of *B. vogeli* infection in coyotes is the tick vector, *R. sanguineus.* Although this vector is found frequently in the eastern U.S., its primary host is the domestic dog and is rarely found on coyotes. Numerous studies assessing ectoparasites on coyotes have failed to document infestation with *R. sanguineus* [36–38]. Though this study indicates that coyotes are likely not a common host for *B. vogeli*, further work, particularly in urban coyotes that may be more exposed to *R. sanguineus* vectors, is still necessary to understand the role coyotes may play in the disease ecology of this pathogen.

Foxes had a low level of *Babesia* diversity. All *B. vulpes* sequences except for two were identical to each other, and those that were not identical differed by only a few base pairs. Though the majority of research into *B. vulpes* has been in Europe, there are studies documenting *B. vulpes* in domestic dogs and foxes in the United States and Canada [16,21]. One study in Canada and North Carolina found a similar prevalence and also found low diversity in sequences [21]. Though *B. vulpes* is an important cause of morbidity in domestic dogs in Europe, cases in North America are still rare. However, some of this may be related to the diagnostics used in the United States, which typically test for *Babesia* sensu-stricto species (*B. gibsoni, B. vogeli, B. canis, B. rossi,* and *Babesia* sp. 'Coco') but not always *B. microti*-like or *B. vulpes.* A survey that tested for all *Babesia* species found a 0.5% (48/9367) prevalence of *B. vulpes* or *B. vulpes* co-infection in North American canids, suggesting this species is still less prevalent than the other common species in like *B. gibsoni*, which was found in 2% of samples [16].

Of note is the recent introduction of *Haemaphysalis longicornis* to the United States. Though the extent to which this tick will change the disease ecology of tick-borne parasites is not yet clear, studies assessing these ticks for the presence of pathogens have documented many of the species found in this study within *H. longicornis*, suggesting the tick may become an important vector for these pathogens [39].

The presence of a snake *Hepatozoon* (*H. ophisauri*) in 3% of muskrats was an interesting finding. This species has been found in rodents once previously in Borneo, and it was hypothesized that rodents may serve as paratenic hosts [40]. The life cycle of this parasite is not fully understood, but it is hypothesized that lizards are the intermediate host and snakes serve as the definitive host [30,40]. Because we only tested for the presence of DNA and did not attempt to complete the lifecycle, we cannot say whether the positives in muskrats indicate viable *Babesia* or simply DNA from killed *Babesia* passing through the muskrat. That said, recent research has documented other *Hepatozoon* spp. in both snake and prey, and some researchers hypothesize that predation may play an important role in the disease ecology snake *Hepatozoon* species [41]. *Hepatozoon ophisauri* has not been documented outside of Europe and Asia, but there is a paucity of research in this area in the United States, so it is possible this species has been present and simply not looked for.

Though *Hepatozoon* has not been found in United States in mink in the past, the species they carried was closely related to species found in martens in Germany. With a prevalence of 70%, it is unlikely that this species causes severe disease in healthy mink,

but its potential impacts in the face of co-infection or immune suppression are not known. Unlike the species found in mink, the *Hepatozoon* species in raccoons has been documented several times in the past in Texas and Oklahoma [42,43]. *Hepatozoon procyonis* causes significant myocarditis in raccoons, though its impact on overall health is unknown.

The two primary limitations of this study are the small sequence length of the 18S gene amplified and the lack of deep sequencing. The less than 600bp sequences amplified by the nested 18S primers were long enough to successfully separate the different clades of *Babesia* known to occur in wildlife but are still small compared to the full length 18S sequence. Several other studies on *Babesia* spp. in North American wildlife have used these primers due to their high sensitivity, and therefore this study is comparable to previous work [24,33]. In addition, these primers are not only able to amplify all *Babesia* species but also other closely related genera like *Hepatozoon*, *Cytauxzoon*, and *Besnoitia*. Some of these species, particularly *Hepatozoon* species, are understudied.

The second major limitation of this study was the lack of deep sequencing to assess the true rate of coinfections in wildlife. Though cloning of select sequences revealed a 15% coinfection rate in raccoons and a 5% co-infection rate in skunks, this is likely an underestimate. Studies that use deep sequencing or multiple rounds of species-specific PCR have found higher rates of coinfection, and further work utilizing these methods would help clarify the true diversity of *Babesia* in wildlife [19,33].

## Conclusion

Skunks, raccoons, and foxes are important reservoirs for *Babesia* in the eastern United States and carry a greater diversity of species than previously realized. Further research, particularly in skunks, is important to fully understand the transmission dynamics and risk to domestic animals and people. *Hepatozoon ophisauri* is present in the United States, though muskrats' role in the lifecycle is unclear.

# References


1. Tsao JI, Hamer SA, Han S, Sidge JL, Hickling GJ. The Contribution of Wildlife Hosts to the Rise of Ticks and Tick-Borne Diseases in North America. J Med Entomol. 2021;58:1565–87.

2. Joseph JT, Roy SS, Shams N, Visintainer P, Nadelman RB, Hosur S, et al. Babesiosis in Lower Hudson Valley, New York, USA. Emerg Infect Dis. 2011;17:843–7.

3. Bloch EM, Day JR, Krause PJ, Kjemtrup A, O'Brien SF, Tobian AAR, et al. Epidemiology of Hospitalized Patients with Babesiosis, United States, 2010–2016. Emerg Infect Dis. 2022;28:354–62.

4. Schreeg ME, Marr HS, Tarigo JL, Cohn LA, Bird DM, Scholl EH, et al. Mitochondrial Genome Sequences and Structures Aid in the Resolution of Piroplasmida phylogeny. Shao R, editor. PLOS ONE. 2016;11:e0165702.

5. Lack JB, Reichard MV, Van Den Bussche RA. Phylogeny and evolution of the Piroplasmida as inferred from 18S rRNA sequences. Int J Parasitol. 2012;42:353–63.

6. Garrett KB, Hernandez SM, Balsamo G, Barron H, Beasley JC, Brown JD, et al. Prevalence, distribution, and diversity of cryptic piroplasm infections in raccoons from selected areas of the United States and Canada. Int J Parasitol Parasites Wildl. 2019;9:224–33.

7. Schnittger L, Rodriguez AE, Florin-Christensen M, Morrison DA. *Babesia*: A world emerging. Infect Genet Evol. 2012;12:1788–809.

8. Yang Y, Christie J, Köster L, Du A, Yao C. Emerging Human Babesiosis with "Ground Zero" in North America. Microorganisms. 2021;9:440.

9. Scott JD, Scott CM. Human Babesiosis Caused by *Babesia duncani* Has Widespread Distribution across Canada. Healthcare. 2018;6:49.

10. Herc E, Pritt B, Huizenga T, Douce R, Hysell M, Newton D, et al. Probable Locally Acquired *Babesia divergens*–Like Infection in Woman, Michigan, USA. Emerg Infect Dis. 2018;24:1558–60.

11. Irwin PJ. Canine babesiosis. Vet Clin North Am Small Anim Pract. 2010;40:1141–56.

12. Dear JD, Owens SD, Lindsay LL, Biondo AW, Chomel BB, Marcondes M, et al. *Babesia conradae* infection in coyote hunting dogs infected with multiple blood-borne pathogens. J Vet Intern Med. 2018;32:1609–17.

13. Javeed NN, Shultz L, Barnum S, Foley JE, Hodzic E, Pascoe EL, et al. Prevalence and geographic distribution of *Babesia conradae* and detection of *Babesia vogeli* in free-ranging California coyotes (*Canis latrans*). Int J Parasitol Parasites Wildl. 2022;19:294–300.

14. Birkenheuer AJ, Neel J, Ruslander D, Levy MG, Breitschwerdt EB. Detection and molecular characterization of a novel large *Babesia* species in a dog. Vet Parasitol. 2004;124:151–60.

15. Zygner W, Gójska-Zygner O, Bartosik J, Górski P, Karabowicz J, Kotomski G, et al. Canine Babesiosis Caused by Large *Babesia* Species: Global Prevalence and Risk Factors—A Review. Anim Basel. 2023;13:2612-.

16. Barash NR, Thomas B, Birkenheuer AJ, Breitschwerdt EB, Lemler E, Qurollo BA. Prevalence of *Babesia* spp. and clinical characteristics of *Babesia vulpes* infections in North American dogs. J Vet Intern Med. 2019;33:2075–81.

17. Goethert HK, Telford SR. What is *Babesia microti*? Parasitology. 2003;127:301–9.

18. Jinnai M, Kawabuchi-Kurata T, Tsuji M, Nakajima R, Fujisawa K, Nagata S, et al. Molecular evidence for the presence of new *Babesia* species in feral raccoons (*Procyon lotor*) in Hokkaido, Japan. Vet Parasitol. 2009;162:241–7.

19. Birkenheuer AJ, Marr HS, Hladio N, Acton AE. Molecular evidence of prevalent dual piroplasma infections in North American raccoons (*Procyon lotor*). Parasitology. 2008;135:33–7.

20. Clark K, Savick K, Butler J. *Babesia microti* in Rodents and Raccoons from Northeast Florida. J Parasitol. 2012;98:1117–21.

21. Birkenheuer AJ, Horney B, Bailey M, Scott M, Sherbert B, Catto V, et al. *Babesia microti*-like infections are prevalent in North American foxes. Vet Parasitol. 2010;172:179–82.

22. Skinner D, Mitcham JR, Starkey LA, Noden BH, Fairbanks WS, Little SE. Prevalence of *Babesia* spp., *Ehrlichia* spp., and tick infestations in Oklahoma black bears (*Ursus americanus*). J Wildl Dis. 2017;53:781–7.

23. Westmoreland LSH, Stoskopf MK, Sheppard E, DePerno CS, Gould NP, Olfenbuttel C, et al. Detection and Prevalence of *Babesia* spp. in American Black Bears (*Ursus americanus*) from Eastern and Western North Carolina, USA. J Wildl Dis. 2019;55:678–81.

24. Shaw M, Kolba N, Huffman JE. Babesia spp. in *Ursus americanus* (Black Bear) in New Jersey. Northeast Nat. 2015;22:451–8.

25. Goethert HK. What *Babesia microti* Is Now. Pathogens. 2021;10:1168.

26. Holbrook AA, Frerichs WM. *Babesia mephitis* sp. N. (Protozoa: Piroplasmida), a hematozoan parasite of the striped skunk, *Mephitis mephitis*. J Parasitol. 1970;56:930–1.

27. Yabsley MJ, Davidson WR, Stallknecht DE, Varela AS, Swift PK, Devos JJ, et al. Evidence of tick-borne organisms in mule deer (*Odocoileus hemionus*) from the western United States. Vector Borne Zoonotic Dis Larchmt N. 2005;5:351–62.

28. Gubbels JM, Vos AP de, Weide M van der, Viseras J, Schouls LM, Vries E de, et al. Simultaneous Detection of Bovine *Theileria* and *Babesia* Species by Reverse Line Blot Hybridization. J Clin Microbiol. 1999; Available from: https://journals.asm.org/doi/10.1128/jcm.37.6.1782-1789.1999

29. Hall TA. BioEdit: a user-friendly biological sequence alignment editor and analysis program for Windows 95/98/NT. Nucleic Acids Symp Ser. [London]: Information Retrieval Ltd., c1979-c2000.; 1999. p. 95–8.

30. Zechmeisterová K, Javanbakht H, Kvičerová J, Široký P. Against growing synonymy: Identification pitfalls of *Hepatozoon* and *Schellackia* demonstrated on North Iranian reptiles. Eur J Protistol. 2021;79:125780.

31. Baker E, Jensen A, Miller D, Garrett KB, Cleveland CA, Brown J, et al. *Hepatozoon* spp. infection in wild canids in the eastern United States. Parasit Vectors. 2023;16:372.

32. Modarelli JJ, Westrich BJ, Milholland M, Tietjen M, Castro-Arellano I, Medina RF, et al. Prevalence of protozoan parasites in small and medium mammals in Texas, USA. Int J Parasitol Parasites Wildl. 2020;11:229–34.

33. Garrett K, Halseth A, Ruder MG, Beasley J, Shock B, Birkenheuer AJ, et al. Prevalence and genetic characterization of a *Babesia microti*-like species in the North American river otter (*Lontra canadensis*). Vet Parasitol Reg Stud Rep. 2022;29:100696.

34. Dear JD, Birkenheuer A. *Babesia* in North America: An Update. Vet Clin North Am Small Anim Pract. 2022;52:1193–209.

35. Yu S, Modarelli J, Tomeček JM, French JT, Hilton C, Esteve-Gasent MD. Prevalence of common tick-borne pathogens in white-tailed deer and coyotes in south Texas. Int J Parasitol Parasites Wildl. 2020;11:129–35.

36. Bloemer SR, Zimmerman RH. Ixodid Ticks on the Coyote and Gray Fox at Land between the Lakes, Kentucky–Tennessee, and Implications for Tick Dispersal. J Med Entomol. 1988;25:5–8.

37. Eads RB. Ectoparasites from a Series of Texas Coyotes. J Mammal. 1948;29:268–71.

38. Green EN, Porter WT, Howard AL, Yaglom H, Benford R, Busch JD, et al. Coyotes (*Canis latrans*) in Arizona, USA, exhibit immune and genetic evidence of Rickettsial infections. J Wildl Dis. 2019;56:261–9.

39. Herb H, González J, Ferreira FC, Fonseca DM. Multiple piroplasm parasites (Apicomplexa: Piroplasmida) in northeastern populations of the invasive Asian longhorned tick, *Haemaphysalis longicornis* Neumann (Ixodida: Ixodidae), in the United States. Parasitology. 2023;150:1063–9.

40. Perison PWD, Amran N-S, Adrus M, Anwarali Khan FA. Detection and molecular identification of blood parasites in rodents captured from urban areas of southern Sarawak, Malaysian Borneo. Vet Med Sci. 2022;8:2059–66.

41. Tomé B, Maia JPMC, Harris DJ. *Hepatozoon* Infection Prevalence in Four Snake Genera: Influence of Diet, Prey Parasitemia Levels, or Parasite Type? J Parasitol. 2012;98:913–7.

42. Allen KE, Yabsley MJ, Johnson EM, Reichard MV, Panciera RJ, Ewing SA, et al. Novel *Hepatozoon* in vertebrates from the southern United States. J Parasitol. 2011;97:648–53.

43. Clark KA, Robinson RM, Weishuhn LL, Galvin TJ, Horvath K. *Hepatozoon procyonis* infections in Texas. J Wildl Dis. 1973;9:182–93.

44. Elsheikha HM, Mansfield LS, Fitzgerald SD, Saeed MA. Prevalence and tissue distribution of *Besnoitia darlingi* cysts in the Virginia opossum (*Didelphis virginiana*) in Michigan. Veterinary Parasitology. 2003 Aug 14;115(4):321-7.

45. Wikander YM, Reif KE. *Cytauxzoon felis*: An Overview. Pathogens. 2023 Jan 13;12(1):133.

# Appendix

**Table 2. Prevalence of *Babesia* spp. infections in the eastern United States**

VOPO stands for Virginia opossum. Percentage is shown, and number positive and total number tested are shown in parenthesis.

| State | Bear | Bobcat | Coyote | Gray fox | Groundhog | Mink | Muskrat | Raccoon | Red Fox | Skunk | VOPO |
|---|---|---|---|---|---|---|---|---|---|---|---|
| **GA** | - | - | - | - | - | - | - | - | 33% (2/3) | - | - |
| **LA** | - | - | 0% (0/25) | 0% (0/1) | - | - | - | - | 0% (0/1) | - | - |
| **MD** | - | - | 0% (0/1) | - | - | - | - | - | 0% (0/1) | - | - |
| **NC** | - | - | 0% (0/4) | 0% (0/2) | - | - | - | - | 0% (0/1) | - | - |
| **PA** | 0% (0/28) | - | 0% (0/10) | - | 0% (0/23) | 0% (0/10) | 0% (0/159) | 33% (2/6) | 24% (20/82) | 28% (16/57) | - |
| **SC** | - | - | 0% (0/58) | - | - | - | - | - | - | - | - |
| **TN** | - | 0% (0/1) | 0% (0/74) | 100% (2/2) | - | - | - | 75% (88/117) | 50% (2/4) | 71% (5/7) | 4% (1/28) |
| **VA** | - | - | 0% (0/13) | - | - | - | - | - | 0% (0/2) | - | - |
| **Total** | **0% (0/28)** | **0% (0/1)** | **0% (0/185)** | **40% (2/5)** | **0% (0/23)** | **0% (0/10)** | **0% (0/159)** | **73% (90/123)** | **26% (24/94)** | **33% (21/64)** | **4% (1/28)** |

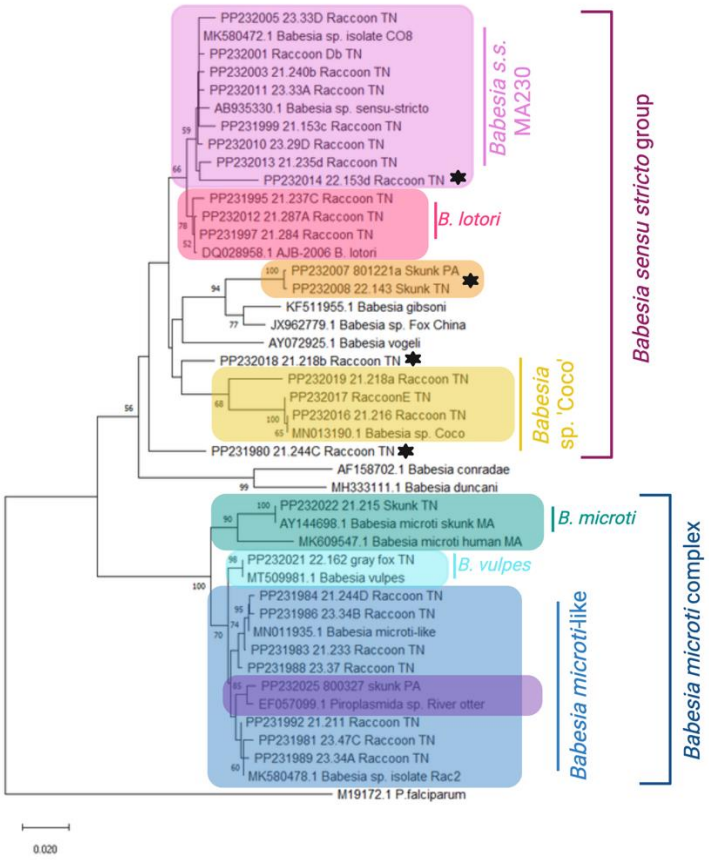


**Figure 5. Phylogeny of partial 18S Babesia sequences**

*Babesia* spp. found in wildlife in the eastern United States. *Plasmodium falciparum* was chosen as the outgroup. All unique sequences are shown, and novel sequences are marked with stars. The phylogenetic tree was generated using the Neighbor-joining algorithm and a Kimura 2-parameter model in MegaX with (v10.1.7). The percentage of replicate trees in which the associated taxa clustered together in the bootstrap test (500 replicates) are shown next to the branches. Created with BioEdit.

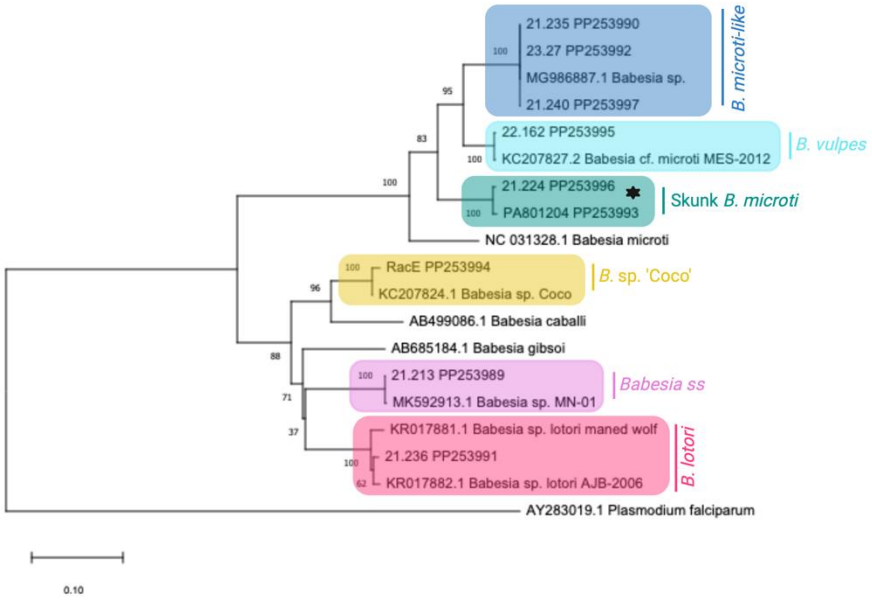


**Figure 6. Phylogeny of partial cox1 babesia sequences**

*Babesia* spp. found in wildlife in the eastern United States. *Plasmodium falciparum* was chosen as the outgroup. All unique sequences are shown, and novel sequences are marked with a star. The phylogenetic tree was generated using the Neighbor-joining algorithm and a Kimura 2-parameter model in MegaX with (v10.1.7). The percentage of replicate trees in which the associated taxa clustered together in the bootstrap test (500 replicates) are shown next to the branches. Created with BioEdit.

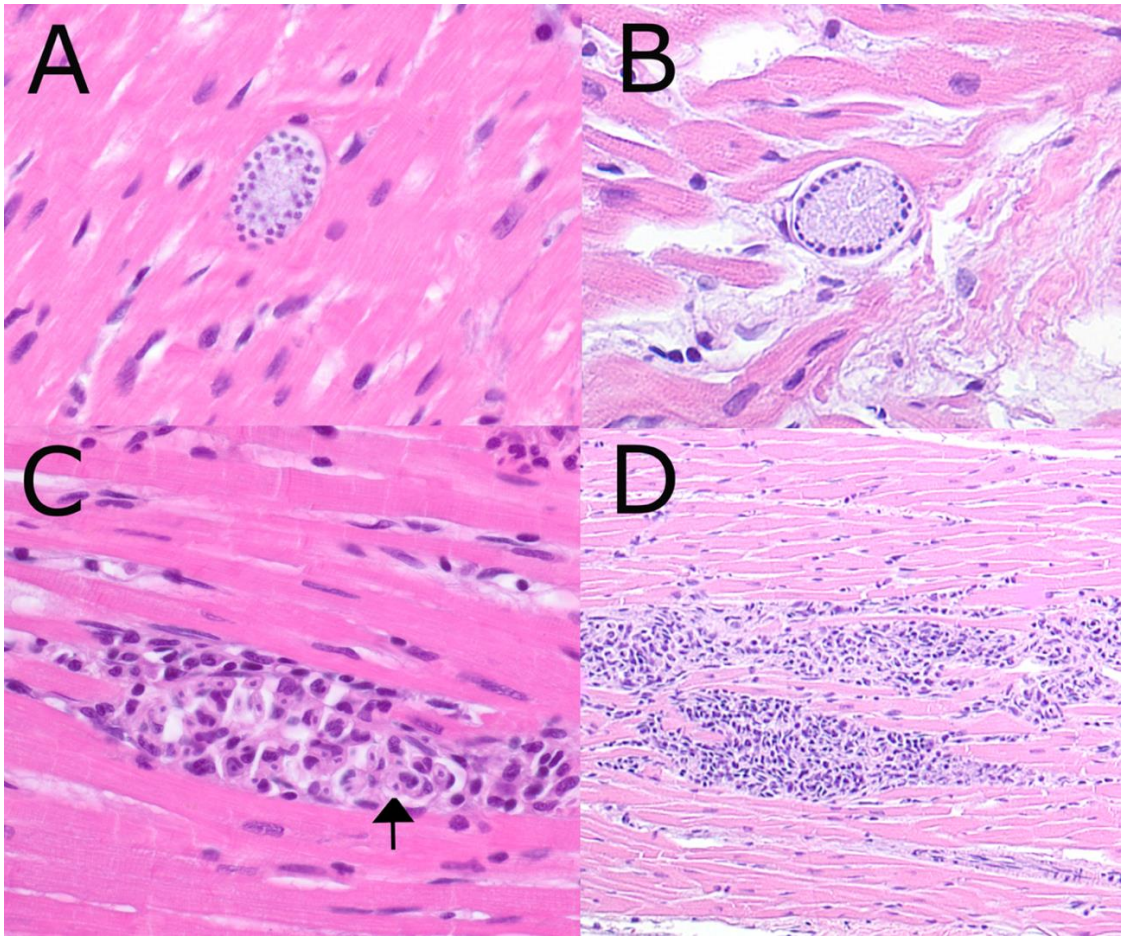


**Figure 7. *Hepatozoon procyonis* photomicrographs from raccoons**

Examples of meronts are shown in A and B. Mixed inflammation consisting primarily of lymphocytes and neutrophils with basophilic inclusion bodies of *H. procyonis* (arrow) are shown in C. A larger view of the typical moderate to severe multifocal myocarditis seen in infected raccoons is shown in D.

# CHAPTER III
# HEALTH SURVEY OF SOUTHEASTERN COYOTES

## Abstract

Coyotes serve as excellent sentinels for a variety of pathogens of human and animal concern including *Trichinella, Trypanosoma cruzi, Toxoplasma gondii, Leptospira, Echinococcus*, and a variety of tick-borne diseases. To assess the prevalence and distribution of these diseases, we conducted a health survey of coyotes from east Tennessee and South Carolina. We performed necropsies with histopathology, PCR on blood and tissue samples, serology, fecal flotations, and ectoparasite identification to assess prevalence of these pathogens. Numerous infections were found including a high seroprevalence to *Borrelia burgdorferi* in Tennessee coyotes (43% [28/65]) while seroprevalence was low in South Carolina (2% [1/52]). *Borrelia* DNA was amplified in 4.7% (4/86) of *I. scapularis* ticks from Tennessee. Tennessee coyotes also had a high prevalence of *Paragonimus* (25% [17/71]) and *Trichinella* (17% [12/71]). Coyotes from both states were infected with canine distemper virus (9% [7/76]) despite minimal respiratory or neurologic pathology. Seropositivity for *Leptospira* was 25% (23/91), and three coyotes from TN were PCR positive for *Leptospira,* including two infected with *L. santarosai.* Heartworm (*Dirofilaria immitis*) infection was present in 53% (8/15) of South Carolina coyotes and 44.6% (33/74) Tennessee coyotes. Coyotes made excellent sentinels for diseases of pets and people. Assessment of coyotes can help determine the risk and spread of many important pathogens, and regular disease surveillance can be an important component of a One Health program.


## Background

Coyotes (*Canis latrans)* have expanded their range across the eastern United States in the last few decades [1]. Though their historic range was limited to the arid deserts and plains of the mid-West, the extirpation of predators like wolves and mountain lions as well as changes to the landscape have allowed coyotes to thrive in areas previously devoid of their presence. Their generalist and adaptable nature have allowed them to colonize almost the entirety of North America in just a few short decades [2]. Unlike wolves and mountain lions, coyotes thrive in suburban and fragmented habitats. Packs have been found in areas as dense as New York City, and reported conflict with coyotes has been on the rise for several years [3].

The impact of coyotes on this new eastern habitat is not yet clear. They can carry numerous diseases of veterinary, human, and wildlife health importance, and changes in disease ecology are likely as they interact with their new habitat. A baseline health assessment of coyotes can indicate the range and prevalence of pathogens of concern. This data can be used by veterinarians and physicians to understand the risk to their patients, as well as by wildlife ecologists to interpret diagnostic investigations on population scales and to better understand the potential impacts of coyotes on eastern ecosystems.

There is some preliminary knowledge from the southeast. A survey in South Carolina found a 15% (3/20) seroprevalence of canine distemper virus and a 25% (7/28) seroprevalence for at least one serovar of *Leptospira* [4].Though no carcasses were available in that study, 35% (12/34) of adults had *Dirofilaria immitis* microfilaria present

in blood smears. No PCR testing for any pathogens was performed in that study, though one coyote was positive for parvovirus via electron microscopy of feces. A similar study in Georgia also found high rates of seropositivity to canine distemper virus (48% [14/27]) [5]. That study found a 100% seropositivity to canine parvovirus, and 32% (10/31) were real-time PCR positive for CPV, though CT values were high (29.5-38.8) and only four were sequenced. The Georgia study tested for antibodies to several more pathogens including *Trypanosoma cruzi* and *Toxoplasma gondii*, finding a low prevalence (7% [2/27]) of the former and a high prevalence (92% [22/24]) of the latter. Carcasses were available in that study, and 52% (16/31) had adult *D. immitis* present in the heart or pulmonary arteries.

These studies demonstrated that coyotes are exposed to many diseases of concern, but their sample size was limited, and serology was the primary diagnostic tool. Though serology can provide an excellent baseline, there are many infections better understood with histopathology or molecular diagnostics. This study sought to fill in the knowledge gaps on the zoonotic and domestic animal infectious diseases of eastern coyotes.

## Materials and Methods

### Sample collection

Samples were opportunistically collected from a variety of sources. A collaborator sent excess whole blood, serum, fecal, and tick samples collected from a GPS collaring study of coyotes in South Carolina (SC). In addition, any study animals that died while still collared were collected and saved frozen until necropsies could be performed. Whole carcasses from eastern Tennessee (TN) were collected opportunistically from hunters, trappers, rabies testing facilities, and wildlife resources agents.

### Autopsy

Autopsies were performed as soon as possible on fresh carcasses, though those from South Carolina and from Animal and Plant Health Inspection Service's (APHIS) rabies testing facilities were frozen until necropsies could be performed. Life stage (juvenile or adult) was determined based on tooth development and wear, body size, and uterine development in females [6]. All visible ectoparasites were collected and saved in 70% ethanol. Body, heart, and liver weights were taken during autopsy. Any parasites visualized in the lung or heart were also saved in 70% ethanol until identification could be performed. Intestinal contents were not examined because they were sent to a collaborator working on an *Echinococcus* survey. Blood or blood clots were collected from the heart as soon as possible after death. An aliquot of the blood was centrifuged at 4500 rpm for 15 minutes to isolate serum. Cerebrum, cerebellum, heart, lung, liver, and kidney were saved frozen. Samples from all major organs were collected and saved in 10% neutral buffered formalin, then trimmed and routinely processed for histology. Slides with suspected pathology were reviewed with a pathologist (authors DM and MD).

**Serology**

Many serum samples were collected post-mortem and were significantly hemolyzed. Therefore, tests that are strongly affected by hemolysis were not run. *Trypanosoma cruzi* was assessed following the protocol described in the nation-wide working dog survey [7]. In short, we screened serum (n=106) for antibodies using the commercially available Chagas Stat-Pak (ChemBio). Positive samples were then assessed with a second immunochromatographic test, the InBios Chagas DetectTM Plus Rapid Test, when enough serum was available. In addition, if serum remained, Stat-Pak positive samples were tested via IFA at Texas A&M University following their standard protocol. Samples were considered true positives if they were positive on at least two tests.

Modified agglutination tests (MAT) for *T. gondii* antibodies were performed in the University of Tennessee Microbiology Laboratory (n=105) as previously described, starting at a 1:25 dilution [8]. Remaining serum (n=91) was tested with the microscopic agglutination test for antibodies to 12 serovars of *Leptospira:* Autumnalis, Ballum, Bataviae, Bratislava, Canicola, Copenhageni, Pomona, Icterohaemorrhagiae, Grippotyphosa, Hardjo, Mankarso, and Tarrasovi, as described previously [9]. Samples were considered positive if they had a titer of at least 1:50 (2+ agglutination), and serial dilution was performed on samples with >2+ agglutination to determine higher titers. Serum or whole blood samples (n=117) were tested using 4dx SNAP tests (Idexx) that assess for antibodies to *Ehrlichia* spp., *Anaplasma* spp., *Borrelia burgdorferi,* and antigens to adult female *Dirofilaria immitis.*

**Molecular Diagnostics**

We extracted DNA from 200µl whole blood (n=130), 25mg heart (n=77), and 25mg kidney (n=75) using Qiagen DNeasy Blood and Tissue kits following manufacturer's instructions. A summary of the primers and protocols used for PCR is presented in Table 3. All PCR products were run on a 1.5% agarose gel, and samples with bands at the correct location were sequenced with Sanger sequencing using a commercial facility (Eurofins Genomics).

All kidney samples were tested via real-time PCR for *Leptospira* spp. as previously described [10]. Traditional PCR targeting both the Lipl32 gene and the rrs2 gene was performed on any sample with a CT value <40. Due to the significant hemolysis associated with many of the serum samples, canine distemper virus (CDV) serology was not attempted. Instead, RNA was extracted from all lung samples (n=76) using RNeasy kits from Qiagen following manufacturer's instructions. All lung samples were tested via reverse-transcriptase real-time PCR for canine distemper virus following the standard protocols of UTCVM's Virology laboratory as previously described [63]. Samples were run in duplicate and were considered positive if both CT values were <35.

DNA from fecal samples (n=113) was extracted using the ZymoResearch Quick-DNA MiniPrep kits (Orange, USA) following manufacturer's instructions. Fecal samples from South Carolina were preserved in 70% ethanol for several months before testing, while fecal samples from Tennessee were collected fresh. Fecal samples were tested for parvovirus with a combination of real-time PCR and traditional PCR. Initially, real-time PCR was performed following the standard protocols of UTCVM's Virology laboratory.

Forward primer (GACGACAGCACAGGAAACAA) and reverse primer (CTGGTTGTGCCATCATTTCA) were used alongside the probe (56-FAM/ACGCACCCGTCTGCCACGGGA/3BHQ_1) to amplify a region of the NS1 gene. However, results were inconclusive, likely influenced by the method used for sample preservation, with many samples producing inconsistent results on duplicate testing. Attempts to amplify rt-PCR positive cases with traditional PCR were unsuccessful, and most CT values fell between 37-40. Therefore, previously tested samples with CT values <40 and future samples (n=38), all of which were from TN, were tested with traditional PCR as previously described [11].

DNA was extracted from *Ixodes scapularis* ticks from TN (n=86) using Qiagen DNeasy kits following manufacturer's instructions (Qiagen Inc, Germantown, Maryland, USA). Ticks were bisected sagittally, and half of the tick was extracted while the other half was retained frozen. If the ticks were not engorged, up to three tick halves were combined in each DNA extraction. Engorged ticks were always extracted individually. Extracted DNA was tested for *B. burgdorferi* using real-time PCR following the standard procedures at the UTCVM Virology laboratory as previously described [64]. When the CT value was <40, ticks were individually extracted and tested via traditional PCR using nested primers targeting the 16S-23S ribosomal RNA (rRNA) intergenic spacer as previously described [12].

Paraffin extraction was performed on samples with *Trichinella* larvae on histology using the Qiagen DNeasy Blood and Tissue kits. In cases where fresh muscle, tongue, or diaphragm was available, we extracted DNA from fresh tissue as well. Multiplex PCR was attempted following previous protocols for *Trichinella* but was not successful, potentially due to the poor DNA quality of formalin-fixed tissue and the decreased sensitivity of tissue extractions rather than individual larvae extraction [13]. To confirm genus identity, we performed PCR targeting a small segment of large ribosomal subunit as previously described [13].

**Parasitology**

Fecal flotation with centrifugation was performed on all samples using Sheather's sugar solution as previously described [14]. Parasite eggs were identified to species when possible. Fecal samples with Taeniidae eggs seen on flotation were tested with primers targeting the COI gene of the genus to differentiate between *Echinococcus* and *Taenia* infection [15]. Heartworms were removed from the heart, lungs, and portal vein and saved in 70% ethanol. All worms were counted and sexed based on their size and tail morphology. Adult ticks were saved in 70% ethanol and identified to species using dichotomous keys whenever possible.

*Data analysis*

Statistical analysis was performed in RStudio. Association between presence or absence on histopathology and positive or negative results on serology was assessed with Chi-squared tests or Fisher's exact tests depending on values. T-tests using Spearman correlation were used to assess association between heartworm number and heart weight and liver weight. Normality was assessed with Shapiro-Wilkes tests, and the significance level was set to 0.05.

# Results

A summary of all results is available in Tables 4-8. Results for individual coyotes and specific titer information are available in Supplementary Table 1.

## Autopsy

A total of 86 coyote carcasses were collected and necropsied between 2019 and 2023, 71 from Tennessee and 15 from South Carolina (Figure 8). In addition, heart alone was available from three Tennessee coyotes, and whole blood (n=56), serum (n=41), and fecal (n=80) samples were collected antemortem from SC coyotes. Estimated post-mortem interval ranged from a few hours to over two days. Coyotes from SC were initially trapped in McCormick County, though several had dispersed to other areas, including as far as northern Georgia, by the time of death. Coyotes from TN were primarily from Campbell County (n=55), though some were from Knox (n=9), Blount (n=4), Wayne (n=2), and Union (n=1) counties (Figure 8). The coyotes with only heart available were from middle TN, but specific county location was not known. All but two (13/15) SC coyotes were female, while 36 Tennessee coyotes were female and 35 were male. Most coyotes appeared in good nutritional condition, with 18% of Tennessee coyotes (13/71) and 33% (5/15) of South Carolina coyotes classified as underweight (body condition score [BCS] less than 4/9). Body weight ranged from 7.6kg to 20.5kg with an average body weight of 12.7kg. Most coyotes were young adults, though 16% (14/86) were estimated between 6-12 months old.

Liver weights ranged from 1.3%-4.4% of body weight (average of 2.51%), and heart weights ranged from 0.61-1.3% of body weight (average of 0.87%). Adult heartworms were found in 41 coyotes (46%), 53% (8/15) of South Carolina coyotes and 44.6% (33/74) Tennessee coyotes. On average, coyotes with heartworms had 15 adult worms, though that number is skewed by several outliers including a coyote that had 109 adult heartworms. Male and female heartworms were found equally with no significant difference between the sexes. Unisex infections were present in six coyotes - two male-only and four female-only infections. There was no statistically significant association between heartworm burden and relative heart or liver weight.

Diet was assessed when stomach contents were identifiable. Coyotes primarily relied on mammalian food sources, with mammalian tissue found in 69% (31/45) of TN coyotes and 60% (6/10) of SC coyotes. Vegetation was also commonly consumed and was found in 38% (17/45) of TN and 10% (1/10) of SC coyote stomachs. Avian tissue was rarely identified (4% [2/45] of TN and 20% [2/10] of SC coyotes). Finally, many coyotes consumed human-associated items including stuffed animals, metal gears, plastic pieces, compost, and gravel. These human-associated items were found in 9% (4/45) of TN and 20% (2/10) of SC coyotes. The remaining coyotes had unidentifiable digesta.

## Histopathology

***Urinary system:*** Lymphoplasmacytic interstitial nephritis typical of canine chronic kidney disease affected 28% (17/60) of TN coyotes and 43% (6/14) of SC coyotes (Figure 9A). Kidneys from one SC coyote and 11 TN coyotes were too autolyzed to accurately evaluate and were not included in the assessment. One Tennessee coyote

had numerous large abscesses of neutrophils and macrophages within the cortex and medulla (Figure 9B). Two coyotes from Tennessee had a renal chronic infarction, with lymphoplasmacytic inflammation and fibrosis consuming a wedge-shaped streak in the cortex and medulla. Finally, one South Carolina coyote had severe necrosis consuming half of its left kidney, with large swaths of necrosis, suppurative inflammation, and mineralization. This coyote had evidence of sepsis throughout multiple other organs.

Bladder was analyzed in 55 coyotes. Fifteen percent (8/55) of coyotes had mild to moderate neutrophilic or eosinophilic cystitis (Figure 9C). There were no bladder stones, tumors, bacterial, or parasitic infection identified on autopsy or histology.

***Pulmonary:*** *Paragonimus kellicoti* flukes were encysted in the lungs of 24% (17/71) Tennessee coyotes and were not found in the lungs of South Carolina coyotes. Coyotes typically had less than five total cysts, though infections with dozens of cysts were present in two cases. There was one severe infection with extrapulmonary involvement with several firm masses consuming the liver parenchyma (Figure 10). Smaller masses were found in the fat surrounding the liver as well as the nearby lymph nodes. The largest liver nodule was 4cmx3cm and had two adult flukes within. Histology revealed these masses consisted almost entirely of *P. kellicoti* eggs. PCR was performed on a section of these masses as well as an adult fluke form the lung to confirm species, and sequences were identical to each other and 99.7% identical to the only *P. kellicoti* 18S sequence in GenBank (HQ900670). Moderate to severe granulomatous and eosinophilic pneumonia was present in all coyotes with *P. kellicoti* flukes. Histologic pulmonary changes typically consisted of egg masses, hemosiderin-laden macrophages throughout the lung lobes, and severe granulomatous inflammation surrounding the cysts themselves (Figure 11).

Eosinophilic alveolitis was documented in 10 coyotes, with a significant association with *D. immitis* infection (Odds ratio = 5.4, p=0.04, Figure 12B). Most cases were mild to moderate and found sporadically throughout the lung lobes. Six TN coyotes had evidence of villous endarteritis or periarteritis, all of whom were *D. immitis* positive (Figure 12C). Other parasite-associated changes included a coyote with severe granulomatous pneumonia due to an *Angiostrongylus vasorum* infection and two coyotes with dystrophic mineralization at the center of focal granulomas, putatively associated with parasite migration (Figure 12A). The identity of *A. vasorum* was confirmed with sequencing of the ITS region (accession number OQ702321), and a full case report is pending.

Aside from parasitic pathology, lung lesions were uncommon. Diffuse bacterial pneumonia was documented in one SC and one TN coyote, and embolic pneumonia was found in two septic coyotes, one from each state. One coyote has villous mesothelial proliferation (Figure 12D) potentially due to pleural effusion caused by *P. kellocoti* fluke migration. Finally, one coyote had a focal proliferation of mesenchymal and acinar cells in one lobe without a clear cause of chronic inflammation.

***Dermatologic:*** An emaciated coyote from Knox County, Tennessee, had sarcoptic mange (Figure 13C). The coyote suffered scabbing, pyoderma, and alopecia throughout most of its skin and had numerous *S. scabei* mites present on a skin scrape. Sequencing of the 16S rRNA sequence was 100% similar to other *S. scabiei* sequences in GenBank

(KY290803). On histopathology, this coyote had evidence of sepsis, with bacterial emboli and associated suppurative inflammation present in the heart, lung, and kidney. No other coyotes had evidence of mange.

Several coyotes (24% [9/38]) had evidence of allergic skin disease on histopathology characterized by eosinophilic, histiocytic, or neutrophilic inflammation in the dermis and occasionally accompanied by hyperkeratosis or neutrophilic scabs (Figure 13D). There was no association between *D. immitis* status and allergic skin disease. One coyote had severe eosinophilic vasculitis with thrombi and intradermal hemorrhage associated with a circular rash surrounding bites from two *I. scapularis* ticks (Figure 13A and B). Neither tick tested positive for *Borrelia* DNA, though other bacterial infections cannot be excluded.

***Gastrointestinal:*** Minimal gastrointestinal histopathology was assessed due to autolysis. However, pancreas (n=19) and liver (n=28) were assessed when autolysis was minimal. Seven (37%) coyotes had moderate to marked eosinophilic and proliferative inflammation of the pancreatic duct. Three of these had *Eurytrema* spp. eggs or adults within the pancreatic duct (Figure 14C). Numerous (>50) *Eurytrema* adults were found incidentally within the small intestine of one coyote during autopsy. DNA was extracted from one adult fluke and tested with universal trematode primers [16]. The 731bp consensus sequence was 98% similar to *E. pancreaticum* sequences in GenBank (KY490004). There are no *E. procyonis* sequences in GenBank, so the species identity is not clear.

Hepatitis affected 32% (9/28) of coyotes. Most cases consisted of mild focal or multifocal eosinophilic inflammation, likely related to parasite migration. As discussed above, one coyote had large granulomas consisting of *P. kellicoti* eggs present in its liver and associated lymph node. One case was not likely related to parasite migration – a coyote with a large neutrophilic abscess.

***Musculoskeletal:*** *Trichinella* larvae were found in the skeletal muscle, tongue, or diaphragm in 17% (12/71) Tennessee coyotes as shown in Figure 14B. No *Trichinella* spp. were found in South Carolina coyotes. *Trichinella* was most common in the tongue (80% of positive cases), followed by skeletal muscle (58% of positive cases), and diaphragm (50% of positive cases). Multiplex PCR on paraffin-extracted pieces of tissue was not successful. However, traditional PCR was successful in cases where fresh tissue was available (n=3). Amplified sequences were 100% identical to each other and to *T. britovi* sequences found in GenBank (KU374854). However, the short sequence length and paucity of *T. murrelli* sequences in GenBank precluded species identification. Though myositis was found in some coyotes, it was not associated with *Trichinella* larvae.

***Miscellaneous:*** One coyote had moderate lymphocytic perivascular cuffing surrounding several vessels in its cerebrum and cerebellum. No distemper-like inclusions were present, and IHC of the slides, performed at University of Georgia, were negative for CDV, EEE, and WNV. The only other histopathologic lesions in this coyote were mild myocarditis and interstitial nephritis. Several coyotes had myocarditis, typically consisting of mild to moderate lymphoplasmacytic inflammation. In the South Carolina coyotes, this was often associated with *Hepatozoon americanum* infection, which we

describe in detail elsewhere [17]. Myocarditis was less common in TN and consisted of rare multifocal lymphoplasmacytic clusters of inflammation. No causative agent was determined.

**Serology and Molecular Diagnostics**

***Leptospirosis:*** Though *Leptospira* MATs can be run with hemolyzed serum, extreme hemolysis can interfere with the results. Therefore, fourteen severely hemolyzed serum samples were excluded from analysis. Of the remaining 91 serum samples, 25% (23) had titers of 1:50 or greater. Titers were low, with only 26% (6/23) of positive titers >1:100. Serovar prevalence differed between states. Autumnalis was the most common serovar in TN (19% [10/53]), while Grippotyphosa was the most common in SC (13% [5/38]). None of the coyotes were positive for Ballum, Bataviae, Canicola, or Tarrasovi, and only one coyote from TN was positive for Hardjo. Full serovar information and titers are available in Supplementary Table 1.

Three of the 75 tested kidney samples (4%) were rtPCR positive for *Leptospira* DNA (CT values 32.9-34.5), all of which were from Tennessee. Sequencing of both the LipL32 gene and the RRS2 gene was successful in all three cases. One case was 100% identical to *L. interrogans* on both gene targets, while the other two were *L. santarosai* (100% and 98% in the LipL32 gene and 100% and 99.9% on the rrs2 gene). The coyote positive for *L. interrogans* was seropositive for Autumnalis (>1:6400), Pomona (>1:6400), Icterohaemorrhagiae (1:100), Bratislava (1:50), and Copenhageni (1:50). Both *L. santarosai*-positive coyotes were negative on the MAT test.

Neither *L. santarosai* coyote had any evidence of renal pathology, though the *L. interrogans*-positive coyote had numerous large neutrophilic abscesses throughout the kidney, with non-abscessed areas showing evidence of lymphoplasmacytic nephritis (Figure 9B). There was a statistically significant correlation (Odds ratio = 7.8; p=0.002) between *Leptospira* seropositivity and interstitial nephritis. Only 21% (9/42) of seronegative coyotes had interstitial nephritis, compared to 69% (9/13) of seropositive coyotes.

***Toxoplasma gondii:*** Most coyotes (85% [90/105]) were seropositive for *T. gondii*. Seropositivity was higher in SC (92% [36/39]) than TN (82% [54/66]), and the average titer in both states was 1:200. Just over 7% of coyotes from both states had titers >1:3200 (8/105).

***Trypanosoma cruzi:*** None of the 130 tested coyotes were PCR positive for *T. cruzi* on either blood or heart. However, 19.8% (21/106) of the coyotes were seropositive for *T. cruzi* on the Chagas Stat-Pak. Of those, 9 were also positive on the InBios ICT test, though two Stat-Pak positive cases did not have enough remaining serum to test. Only one SC coyote was positive on IFA with a titer of 1:1280. Therefore, 8.7% (9/104) of samples were positive on at least two serologic tests.

***Distemper (CDV):*** Real-time PCR for distemper virus was positive in 9.2% (7/76) of the coyotes, with 15.4% (2/13) of SC coyotes and 7.9% (5/63) of TN coyotes with CT values <35. Only two coyotes were strongly positive (CT value of 14.9 and 20.8), while the rest had values between 30-35. Both strongly positive coyotes and two of the weakly

positive coyotes had interstitial pneumonia. Five coyotes had equivocal results, with CT values consistently between 35-39. None of the equivocal coyotes had lung pathology.

***Parvovirus (CPV):*** Only one of the ethanol-preserved fecal samples from SC was positive for parvovirus on real-time PCR, with a CT value of 33. None of the ethanol-preserved fecal samples were positive on traditional PCR. Of the fresh fecal samples tested with traditional PCR, 10.5% (4/38) were PCR positive and confirmed via sequencing to be CPV-2. The small sequence length precluded more specific typing.

***Idexx 4dx SNAP tests:*** Tennessee coyotes had a higher prevalence of all tested 4dx pathogens, with 66% (43/65) seropositive for *Ehrlichia,* 43% (28/65) seropositive for *B. burgdorferi,* and 29% (19/65) seropositive for *Anaplasma.* South Carolina coyotes had no evidence of exposure to *Anaplasma,* and only one of 52 was seropositive for *B. burgdorferi.* Eleven of 52 (21%) were seropositive for *Ehrlichia.* There was no statistically significant correlation between *Borrelia, Anaplasma,* or *Ehrlichia* seropositivity and renal inflammation. The 4dx heartworm antigen results generally agreed with autopsy results. Of coyotes that had at least one adult female worm on autopsy, the SNAP test was able to identify 89% as positive and was able to identify 100% of infections that had greater than three adult female worms. False positives were present in two cases, giving an overall specificity of 97%.

*Parasitology*

***Ticks:*** Three hundred and thirteen adult ticks were collected, 110 from South Carolina and 203 from Tennessee (Table 8). Black-legged ticks (*Ixodes scapularis)* predominated in South Carolina, making up 81% of specimens collected (89/110). *Ixodes scapularis* was also common in Tennessee making up 43% of ticks (86/203). *Amblyomma americanum* was the second most common, making up 47% (94/203) of TN ticks and 7% (8/110) of SC ticks. *Amblyomma maculatum* was found on 12% (13/110) of SC coyotes and only on two TN coyotes. Finally, *Dermacentor variabilis* made up 9% (19/200) of TN samples but was not found in SC. All but one coyote from South Carolina was harvested in the wintertime, while those from Tennessee were primarily harvested in winter but some were collected in spring, which may explain the variability in tick species.

Since few SC coyotes were seropositive for *B. burgdorferi* antibodies, SC ticks were not tested. Of the TN black-legged ticks tested for *B. burgdorferi* DNA, 4.7% (4/85) had CT values <35 on rtPCR, and three were sequenced with traditional PCR. There were also six equivocal samples with CT values between 35-40. However, none of the equivocal samples could be sequenced with traditional PCR. Of the three sequences generated, one was 99.68% similar to a *B. burgdorferi* strain B31 sequence (CP019767), and two were identical to each other and 99.57% similar to a strain 80a sequence (CP124108).

***Fecal flotation:*** Fecal flotations were performed on 133 coyotes (81 from South Carolina and 52 from Tennessee). Parasite eggs were found at much higher frequencies in the fresh (TN) stool compared to ethanol-preserved (SC) with 94% (49/52) of Tennessee coyotes positive for at least one parasite on fecal float compared to only 36% (29/80) of South Carolina coyotes. Full fecal floatation results are shown in Table 7. Tennessee coyotes had the highest prevalence of *Ancylostoma* spp. (77%) followed by *Sarcocystis*

spp (54%) and *Capillaria* spp. (29%). *Eurytrema* spp. eggs were found in 7.7% (4/52) Tennessee coyotes. Taeniidae spp. were found in 10% (8/80) South Carolina coyotes and 7.7% (4/52) Tennessee coyotes. Cestode PCR was successful in seven of these samples. Six samples (four from SC and two from TN) were 92-98% similar to *T. pisiformis* sequences in GenBank, and one sample from TN was 99.2% similar to *T. hydatigena.*

## Discussion

Coyotes carried numerous pathogens of human and veterinary importance, including several considered to be emerging in the southeast. For most pathogens of concern, coyotes had a higher prevalence than what has been documented in pets or people, making them excellent sentinels for these diseases.

### Autopsy and Histopathology

***Leptospira:*** Out of the three PCR-positive cases of *Leptospira,* two were *L. santarosai,* rather than the more commonly diagnosed *L. interrogans. Leptospira santarosai* is a cause of leptospirosis in humans in Central and South America and has been found in the United States in cattle herds in Puerto Rico [18,19]. The first report of *L. santarosai* in a dog did not occur until 2016 in Brazil [20]. This dog did not show any clinical symptoms of leptospirosis, but persistently shed *L. santarosai* in the urine for several weeks. There have been a few other reports of subclinical *L. santarosai* since then, with one study finding *L. santarosai* sequences from dogs were genetically distinct from other mammals [21]. Though no clinical cases of *L. santarosai* have been reported in canids, most veterinary diagnostic laboratories in the United States do not test for *L. santarosai* with their MAT tests. Therefore, although *L. interrogans* is considered the primary species in dogs, little is known about the prevalence or potential virulence of *L. santarosai* in canids. However, the pathogen appears more common than previously believed. Due to the known zoonotic potential, continued monitoring of both domestic and wild canids important.

There was a statistically significant correlation between *L. interrogans* seropositivity and interstitial nephritis. Studies in domestic dogs have found that asymptomatic leptospirosis is associated with chronic kidney disease, and our findings suggest a similar association in coyotes [22]. The coyote PCR positive for *L. interrogans* had both interstitial nephritis as well as multifocal large renal abscesses, which is not typical for *Leptospira* infection. Whether *Leptospira* infection contributed to these lesions is unclear, and this coyote was the only one with renal abscesses.

Serovars differed between the two states, with TN having more Autumnalis and SC more Grippotyphosa. Serovar Autumnalis is considered less pathogenic to dogs and is sometimes not even included in canine MAT tests, while Grippotyphosa is often a cause of clinical illness [23]. We did not have a large enough sample size to confidently assess differences between renal pathology and individual serovars. Future studies with a larger sample size should assess the relationship between serovar, titer, and renal pathology in coyotes.

***Trichinella:*** Tennessee coyotes had a high prevalence of *Trichinella* spp. infection. We were unable to confirm species, likely since most genotyping protocols

require digestion and assessment of individual larvae, which we did not attempt for this study. *T. murrelli* is one of the most common species in wildlife in the temperate United States and has been documented in coyotes in the past [24,25]. The prevalence of 17% in TN coyotes is higher than most previous reports in coyotes, which typically range from 4-10% prevalence [24,26–28]. Only one study from Wisconsin found a higher prevalence of 26% (11/42) [25]. The last survey in TN in 1987 examined 170 coyote diaphragms and did not find any positives [29]. It is unclear from the description if they performed tissue digestion or simple squash preparations. Regardless, we report a higher prevalence than previously documented in TN, even though we did not perform tissue digestion, the gold standard for diagnosis. Though the zoonotic potential of *Trichinella* in coyotes is hopefully minimal, as they are not game animals, they can be excellent sentinels for the prevalence in an area.

**Virology**

There are no comparable molecular studies assessing CDV prevalence in coyotes. Seroprevalence is variable, ranging between 10%-56% in previous studies across the United States [30–33]. A study of raccoons and foxes found a 74% (43/58) rtPCR prevalence including in 55% (12/22) of clinically healthy animals [34]. Only 17 of the PCR positive wildlife had lung pathology, suggesting either an acute or carrier state for raccoons and foxes. Our study provides evidence that coyotes may also be capable of subclinical or post-clinical shedding.

Like CDV, relatively few molecular surveys for CPV have been performed in wildlife. Though seropositivity is often as high as 100% in coyotes, less is known about the prevalence of active infection [5,30,35,36]. Despite CPV's hardiness in the environment, it appears that long-term ethanol preservation decreased the quality of DNA. Therefore, the 1.4% (1/70) prevalence found via rtPCR in the SC coyotes is likely an underestimate of infection, and comparison between the two states should not be made. If we included equivocal results with CT values between 35-40, we would have a higher prevalence of 20% (14/70). However, traditional PCR failed to amplify DNA in any of these equivocal cases, so we elected a conservative cut off. The 10.5% (4/38) prevalence in the fresh fecal samples of TN coyotes is lower than the 32% (10/31) rtPCR positivity reported in Georgia coyotes [5]. However, CT values in the Georgia study were high (29.5-38.8), and only four (12.9%) were sequenced. The prevalence of sequence-confirmed CPV positives was similar to the prevalence we found in the fresh TN fecal samples (10.5%) and demonstrates that coyotes can act as important reservoirs for the disease.

***Trypanosoma***

No serologic tests for *T. cruzi* are validated in coyotes, and studies vary in their methodology for determining positives. We followed a conservative approach, considering a sample positive only if it was positive on two separate tests. Though 19.8% (21/106) of coyotes in our study were seropositive on the STAT-Pak alone, only 8.6% (9/104) were positive on both Stat-Pak and InBios ICT. Samples were more likely to be positive on both tests if the Stat-Pak band was strongly positive, while those with fainter

lines were often, but not exclusively, negative on the InBios ICT. IFA testing was limited in our study due to the low volume and quality of serum. However, only one SC coyote was positive on IFA, showing a poor agreement between tests.

Prevalence in SC (17.5% [7/40]) was markedly higher than prevalence in TN (3.1% (2/64), corresponding with the known increase in prevalence further South [37]. Few similar surveys exist with which to compare our findings. A survey in South Carolina tested two coyotes and 26 gray foxes with both the InBios ICT and IFA. None of the coyotes were positive, but 8% (2/26) of the foxes were positive on both tests, similar to our total prevalence [38]. The only previous coyote survey in Tennessee used the InBios ICT exclusively and found a 9.5% (2/21) prevalence, again similar to our total prevalence although the use of only one serologic test would lead to a higher reported prevalence. The working dog survey, which our methods are based on, found a higher percent seropositivity in Tennessee working dogs (11%) than we found in coyotes. This is surprising, as coyote exposure to triatomine bugs would theoretically be higher than owned dogs. This could be explained by the high incidence of *T. cruzi* infected bugs documented in dog kennels or differences in prevalence between eastern Tennessee and the rest of the state [39]. Though both the Stat-Pak and the InBios ICT can be used with hemolyzed serum or even whole blood, it is also possible that the lower quality of our post-mortem samples decreased the sensitivity of the tests. As concern for the spread of *T. cruzi* in the United States grows, wildlife surveillance will remain a vital component of assessing distribution and risk.

**Ticks and Tick-borne Diseases**

Our findings support the increasing concern for the spread of Lyme disease in the South. Several states previously considered non-endemic for Lyme have seen human cases more than double since the mid-2000s, and studies have found an increase in the distribution of black-legged ticks in eastern Tennessee [40,41]. Black-legged ticks were first reported in eastern Tennessee in 2006, where they were found in only 8 counties, and no ticks were positive for *B. burgdorferi* [42] . By 2017, they were found in 26 counties, and *B. burgdorferi*-positive ticks were found in four counties (Union, Anderson, Claiborne, and Hamilton) [40]. Though ticks from Knox and Campbell Counties were assessed in that study, none were positive for *B. burgdorferi.* We found a near 5% prevalence of positive ticks in those counties, demonstrating an expanded distribution.

Of the three generated *B. burgdorferi* sequences, two IGS genotypes were present. One sequence was strain B31, which is considered the reference strain for *B. burgdorferi* sensu-stricto [43]. The other two sequences were more similar to strain 80a, which is also known to infect humans and has been found in New York and Michigan [44]. Strain B31 is ospC type A and strain 80a is ospC type N, and both types have been associated with invasive infections in people [45]. The finding of two distinct genotypes despite such a small positive sample size suggests there may already be a high diversity of *B. burgdorferi* genotypes circulating in the southeast.

In addition, though the PCR prevalence of 5% in ticks is relatively low, the antibody prevalence in coyotes was remarkably high at 43%. This suggests that there is still substantial risk, primarily to pets who are not on prevention. The low rate of

exposure (2%) in South Carolina suggests that infected ticks have not established themselves as fully in that area. Given the rapid expansion in *B. burgdoerferi*-positive ticks in the last decade, it is likely that the distribution and prevalence will only continue to increase [41]. Therefore, continued monitoring is important.

The remaining ectoparasite results demonstrated that coyotes are important hosts not only for the black-legged tick but also for the Gulf Coast tick (*Amblyomma maculatum*), the lone star tick (*Amblyomma americanum*), and, to a lesser extent, the American dog tick (*Dermacentor variabilis*). The Gulf Coast tick has been common in South Carolina for decades, and has recently expanded its range as far north as Delaware, so its rare occurrence in Tennessee is expected [46,47]. It is important to interpret the ectoparasite results with the season of capture in mind. Almost all carcasses were collected in winter, so the high occurrence of *I. scapularis* and low occurrence of more summertime ticks is not surprising.

**Fecal Flotation**

Ethanol storage appeared to have a major impact on the sensitivity of fecal flotation in the South Carolina coyotes. Therefore, the rates reported from SC should be viewed as minimum occurrence rather than true prevalence, and the results should not be compared with the results from TN, which were obtained with fresh feces.

The high prevalence of *P. kellicoti,* both in the fecal flotations and the lungs, was unexpected. Previous analyses have found *P. kellicoti* in less than 4% of coyotes [48,49]. Even in the accepted primary definitive host, mink, prevalence is typically <20% [50]. Therefore, our finding of a 25% (13/52) prevalence in TN is unusual. This study provides only the second report of extrapulmonary *Paragonimus* in a canid. The previous report occurred in 1976 in a mixed breed dog with numerous *Paragonimus* cysts in its lungs, and egg granulomas found throughout its liver, spermatic cord, and mediastinal lymph nodes [51]. Of the autopsy-positive coyotes, 92% (12/13) had *Paragonimus* eggs on fecal flotation, demonstrating a high sensitivity of fecal flotation for infection. The fecal-negative coyote only had two cysts present in the lungs.

The presence of *Eurytrema* spp. was surprising, since many previous parasite surveys have been performed in coyotes with only one finding *Eurytrema* in a single coyote-red wolf hybrid [4,5,52–54]. Raccoons are considered the definitive host of *E. procyonis,* and *Eurytrema* has also been documented in domestic cats, foxes, and maned wolves [54–57]. It is worth noting that all but one *Eurytrema* spp. and *P. kellicoti* infection were from Campbell County. It is possible that mollusk, grasshopper, or crayfish abundance is higher in this area, creating a hotspot for these trematode infections. However further research with a greater sample size from other counties would be necessary to make that determination.

The high prevalence of *Ancylostoma, Sarcocystis,* and *Neospora*-like species is similar to what has been found in previous fecal flotation surveys in wild canids, though there is significant geographic variability [48,52]. Although *Echinococcus canadensis* has been reported in elk in Tennessee, none of the coyotes from TN or SC were positive for this zoonotic parasite [58].

### Limitations

There were several limitations of this study, primarily related to the opportunistic sample collection. Most TN samples came from one wildlife management area (WMA) in Campbell County, while all SC samples came from a single county. Therefore, though the prevalence of disease is likely comparable to neighboring counties, we cannot determine what trends may be related to the specific ecology of those regions.

The presence of marked autolysis in some coyotes (n=11) and freeze artifact in others (n=16) limited the usefulness of histology in certain cases, particularly when evaluating gastrointestinal organs. Histopathology of brain, intestine, liver, and pancreas were often unusable due to these changes, limiting our assessment of some of the diseases of interest including CPV and CDV. In addition, using only post-mortem samples limited our ability to test serum, which kept us from comparing our results to the previous southeastern coyote surveys that assessed exposure to CPV, CDV, and West Nile Virus.

Finally, a major limitation of the study was the delayed testing of samples from South Carolina. Fecal flotation was likely significantly impacted by the months-long storage times in ethanol, which has been shown to decrease fecal egg counts in experimental testing [62]. The difference in storage methods and duration makes comparison of histology and fecal results between the two states challenging. That said, many autopsy findings would not have been impacted by storage methods including heartworm, *Paragonimus,* and *Trichinella*.

## Conclusion

Coyotes are excellent sentinels for disease. Their generalist nature places them in contact with many pathogens, as well as humans and pets. This study provided a better understanding of coyote disease burden and demonstrated their usefulness at monitoring the emergence of new diseases, particularly tick-borne diseases, to an area. Coyote assessment can be a vital part in a disease surveillance program.

# References


1. Hody JW, Kays R. Mapping the expansion of coyotes (*Canis latrans*) across North and Central America. ZooKeys. 2018;81–97.

2. Bijl H, Csányi S. The reasons for the range expansion of the grey wolf, coyote and red fox. Rev Agric Rural Dev. 2022;11:46–53.

3. Henger CS, Herrera GA, Nagy CM, Weckel ME, Gormezano LJ, Wultsch C, et al. Genetic diversity and relatedness of a recently established population of eastern coyotes (*Canis latrans*) in New York City. Urban Ecosyst. 2020;23:319–30.

4. Miller DL, Schrecengost J, Merrill A, Kilgo J, Ray HS, Miller KV, et al. Hematology, Parasitology, and Serology of Free-Ranging Coyotes (*Canis latrans*) from South Carolina. J Wildl Dis. 2009;45:863–9.

5. Gates M, Gerhold RW, Wilkes RP, Gulsby WD, Maestas L, Rosypal A, et al. Parasitology, Virology, and Serology of Free-Ranging Coyotes (*Canis latrans*) from Central Georgia, USA. J Wildl Dis. 2014;50:896–901.

6. Gier HT. Coyotes in Kansas, rev. Kans Agric Exp Stn Kansaa State Univ Manhattan Kans. 1968;

7. Meyers AC, Purnell JC, Ellis MM, Auckland LD, Meinders M, Hamer SA. Nationwide exposure of US working dogs to the Chagas disease parasite, *Trypanosoma cruzi*. Am J Trop Med Hyg. 2020;102:1078.

8. Desmonts G, Remington JS. Direct agglutination test for diagnosis of Toxoplasma infection: method for increasing sensitivity and specificity. J Clin Microbiol. 1980;11:562–8.

9. Rajeev S, Bolfa P, Shiokawa K, Beierschmitt A, Palmour R. *Leptospira* Infection in African Green Monkeys in an Endemic Area: An Opportunity for Comparative Studies in a Natural Environment. Pathogens. 2020;9:474.

10. Stoddard RA, Gee JE, Wilkins PP, McCaustland K, Hoffmaster AR. Detection of pathogenic *Leptospira* spp. through TaqMan polymerase chain reaction targeting the LipL32 gene. Diagn Microbiol Infect Dis. 2009;64:247–55.

11. Schunck B, Kraft W, Truyen U. A simple touch-down polymerase chain reaction for the detection of canine parvovirus and feline panleukopenia virus in feces. J Virol Methods. 1995;55:427–33.

12. Kelly AL, Raffel SJ, Fischer RJ, Bellinghausen M, Stevenson C, Schwan TG. First isolation of the relapsing fever spirochete, *Borrelia hermsii*, from a domestic dog. Ticks Tick-Borne Dis. 2014;5:95–9.

13. Zarlenga DS, Chute MB, Martin A, Kapel CMO. A multiplex PCR for unequivocal differentiation of all encapsulated and non-encapsulated genotypes of *Trichinella*. Int J Parasitol. 1999;29:1859–67.

14. Wyrosdick H. UTCVM diagnostic procedures in veterinary parasitology: A handbook. University of Tennessee Press, Knoxville, Tennessee; 2021.

15. Gasser RB, Zhu X, McManus DP. Display of sequence variation in PCR-amplified mitochondrial DNA regions of *Echinococcus* by single-strand conformation polymorphism. Acta Trop. 1998;71:107–15.

16. Díaz EA, Donoso G, Mosquera JD, Ramírez-Villacís DX, González G, Zapata S, et al. Death by massive air sac fluke (Trematoda: *Bothriogaster variolaris*) infection in a free-ranging snail kite (*Rostrhamus sociabilis*). Int J Parasitol Parasites Wildl. 2022;19:155–60.

17. Baker E, Jensen A, Miller D, Garrett KB, Cleveland CA, Brown J, et al. *Hepatozoon* spp. infection in wild canids in the eastern United States. Parasit Vectors. 2023;16:372.

18. Hamond C, Dirsmith KL, LeCount K, Soltero FV, Rivera-Garcia S, Camp P, et al. *Leptospira borgpetersenii* serovar Hardjo and *Leptospira santarosai* serogroup Pyrogenes isolated from bovine dairy herds in Puerto Rico. Front Vet Sci. 2022.

19. Peláez Sanchez RG, Lopez JÁ, Pereira MM, Arboleda Naranjo M, Agudelo-Flórez P. Genetic diversity of *Leptospira* in northwestern Colombia: first report of *Leptospira santarosai* as a recognised leptospirosis agent. Mem Inst Oswaldo Cruz. 2016;111:737–44.

20. Miotto BA, Moreno LZ, Guilloux AGA, Sousa GO de, Loureiro AP, Moreno AM, et al. Molecular and serological characterization of the first *Leptospira santarosai* strain isolated from a dog. Acta Trop. 2016;162:1–4.

21. Miotto BA, Guilloux AGA, Tozzi BF, Moreno LZ, Hora AS da, Dias RA, et al. Prospective study of canine leptospirosis in shelter and stray dog populations: Identification of chronic carriers and different *Leptospira* species infecting dogs. PLOS ONE. 2018;13:e0200384.

22. Sant'Anna R, Vieira AS, Oliveira J, Lilenbaum W. Asymptomatic leptospiral infection is associated with canine chronic kidney disease. Comp Immunol Microbiol Infect Dis. 2019;62:64–7.

23. Ward MP, Guptill LF, Prahl A, Wu CC. Serovar-specific prevalence and risk factors for leptospirosis among dogs: 90 cases (1997–2002). J Am Vet Med Assoc. 2004;224:1958–63.

24. Reichard MV, Tiernan KE, Paras KL, Interisano M, Reiskind MH, Panciera RJ, et al. Detection of *Trichinella murrelli* in coyotes (*Canis latrans*) from Oklahoma and North Texas. Vet Parasitol. 2011;182:368–71.

25. Hill DE, Samuel MD, Nolden CA, Sundar N, Zarlenga DS, Dubey JP. *Trichinella murrelli* in scavenging mammals from south-central Wisconsin, USA. J Wildl Dis. 2008;44:629–35.

26. Pozio E, Pence DB, La Rosa G, Casulli A, Henke SE. *Trichinella* Infection in Wildlife of the Southwestern United States. J Parasitol. 2001;87:1208–10.

27. Zimmermann WJ, Hubbard ED, Schwarte LH, Biester HE. *Trichinella spiralis* in Iowa Wildlife during the Years 1953 to 1961. J Parasitol. 1962;48:429–32.

28. Seesee FM, Sterner MC, Worley DE. Helminths of the Coyote (*Canis latrans* Say) in Montana1. J Wildl Dis. 1983;19:54–5.

29. Van Den Bussche RA, Kennedy ML, Wilhelm WE. Helminth Parasites of the Coyote (*Canis latrans*) in Tennessee. J Parasitol. 1987;73:327–32.

30. Arjo WM, Gese EM, Bromley C, Kozlowski A, Williams ES. Serologic Survey for Diseases in Free-Ranging Coyotes (*Canis latrans*) from Two Ecologically Distinct Areas of Utah. J Wildl Dis. 2003;39:449–55.

31. Cypher BL, Scrivner JH, Hammer KL, O'Farrell TP. Viral antibodies in coyotes from California. J Wildl Dis. 1998;34:259–64.

32. Gese EM, Schultz RD, Rongstad OJ, Andersen DE. Prevalence of Antibodies against Canine Parvovirus and Canine Distemper Virus in Wild Coyotes in Southeastern Colorado. J Wildl Dis. 1991;27:320–3.

33. Guo W, Evermann JF, Foreyt WJ, Knowlton FF, Windberg LA. Canine distemper virus in coyotes: a serologic survey. J Am Vet Med Assoc. 1986;189:1099–100.

34. Pope JP, Miller DL, Riley MC, Anis E, Wilkes RP. Characterization of a novel Canine distemper virus causing disease in wildlife. J Vet Diagn Invest. 2016;28:506–13.

35. Grinder M, Krausman PR. Morbidity—mortality factors and survival of an urban coyote population in Arizona. J Wildl Dis. 2001;37:312–7.

36. Chitwood MC, Swingen MB, Lashley MA, Flowers JR, Palamar MB, Apperson CS, et al. Parasitology and serology of free-ranging coyotes (*Canis latrans*) in North Carolina, USA. J Wildl Dis. 2015;51:664–9.

37. Brown EL, Roellig DM, Gompper ME, Monello RJ, Wenning KM, Gabriel MW, et al. Seroprevalence of *Trypanosoma cruzi* among eleven potential reservoir species from six states across the southern United States. Vector-Borne Zoonotic Dis. 2010;10:757–63.

38. Rosypal AC, Tidwell RR, Lindsay DS. Prevalence of Antibodies to *Leishmania* infantum and *Trypanosoma cruzi* in Wild Canids From South Carolina. J Parasitol. 2007;93:955–7.

39. Busselman R, Curtis-Robles R, Meyers A, Zecca I, Auckland L, Hodo C, et al. Abundant triatomines in Texas dog kennel environments: Triatomine collections, infection with *Trypanosoma cruzi*, and blood feeding hosts. Acta Trop. 2023;107087.

40. Hickling GJ, Kelly JR, Auckland LD, Hamer SA. Increasing Prevalence of *Borrelia burgdorferi* sensu stricto–Infected Blacklegged Ticks in Tennessee Valley, Tennessee, USA. Emerg Infect Dis. 2018;24:1713–6.

41. Lantos PM, Nigrovic LE, Auwaerter PG, Fowler VG, Ruffin F, Brinkerhoff RJ, et al. Geographic Expansion of Lyme Disease in the Southeastern United States, 2000–2014. Open Forum Infect Dis. 2015;2:ofv143.

42. Rosen ME, Hamer SA, Gerhardt RR, Jones CJ, Muller LI, Scott MC, et al. *Borrelia burgdorferi* Not Detected in Widespread Ixodes scapularis (Acari: Ixodidae) Collected from White-Tailed Deer in Tennessee. J Med Entomol. 2012;49:1473–80.

43. Fraser CM, Casjens S, Huang WM, Sutton GG, Clayton R, Lathigra R, et al. Genomic sequence of a Lyme disease spirochaete, *Borrelia burgdorfer*i. Nature. 1997;390:580–6.

44. Qiu W-G, Bruno JF, McCaig WD, Xu Y, Livey I, Schriefer ME, et al. Wide Distribution of a High-Virulence *Borrelia burgdorferi* Clone in Europe and North America. Emerg Infect Dis. 2008;14:1097–104.

45. Earnhart CG, Buckles EL, Dumler JS, Marconi RT. Demonstration of OspC Type Diversity in Invasive Human Lyme Disease Isolates and Identification of Previously Uncharacterized Epitopes That Define the Specificity of the OspC Murine Antibody Response. Infect Immun. 2005;73:7869–77.

46. Alkishe A, Peterson AT. Climate change influences on the geographic distributional potential of the spotted fever vectors *Amblyomma maculatum* and *Dermacentor andersoni*. PeerJ. 2022;10:e13279.

47. Phillips VC, Zieman EA, Kim C-H, Stone CM, Tuten HC, Jiménez FA. Documentation of the expansion of the Gulf Coast tick (*Amblyomma maculatum*) and *Rickettsia parkeri*: first report in Illinois. J Parasitol. 2020;106:9–13.

48. Grigione MM, Burman P, Clavio S, Harper SJ, Manning DL, Sarno RJ. A comparative study between enteric parasites of Coyotes in a protected and suburban habitat. Urban Ecosyst. 2014;17:1–10.

49. RAMSDEN RO, PRESIDENTE PJA. *Paragonimus kellicotti* infection in wild carnivores in southwestern Ontario: prevalence and gross pathologic features. J Wildl Dis. 1975;11:136–41.

50. Dubey JP. Endemic *Paragonimus kellicotti* infections in animals and humans in USA and Canada: Review and personal perspective. Food Waterborne Parasitol. 2023;30:e00184.

51. Ah H, Chapman WL. Extrapulmonary granulomatous lesions in canine paragonimiasis. Vet Parasitol. 1976;2:251–8.

52. Gompper ME, Goodman RM, Kays RW, Ray JC, Fiorello CV, Wade SE. A Survey of the Parasites of Coyotes (*Canis latrans*) in New York based on Fecal Analysis. J Wildl Dis. 2003;39:712–7.

53. Franson JC, Jorgenson RD, Boggess EK, Greve JH. Gastrointestinal Parasitism of Iowa Coyotes in Relation to Age. J Parasitol. 1978;64:303–5.

54. Custer JW, Pence DB. Ecological Analyses of Helminth Populations of Wild Canids from the Gulf Coastal Prairies of Texas and Louisiana. J Parasitol. 1981;67:289–307.

55. Foley GL, Anderson WI, Georgi ME. *Eurytrema procyonis* in a New York fox. Cornell Vet. 1987;77:168–71.

56. Miller ER, Fowler ME. Fowler's Zoo and Wild Animal Medicine Current Therapy, Volume 7. Elsevier Health Sciences; 2011.

57. Vyhnal KK, Barr SC, Hornbuckle WE, Yeager AE, Wade SE, Frongillo MF, et al. *Eurytrema procyonis* and pancreatitis in a cat. J Feline Med Surg. 2008;10:384–7.

58. Dell B, Newman SJ, Purple K, Miller B, Ramsay E, Donnell R, et al. Retrospective investigation of *Echinococcus canadensis* emergence in translocated elk (*Cervus canadensis*) in Tennessee, USA, and examination of canid definitive hosts. Parasit Vectors. 2020;13:330.

59. Souto RP, Vargas N, Zingales B. *Trypanosoma rangeli*: Discrimination from *Trypanosoma cruzi* Based on a Variable Domain from the Large Subunit Ribosomal RNA Gene. Exp Parasitol. 1999;91:306–14.

60. Regnery RL, Spruill CL, Plikaytis BD. Genotypic identification of rickettsiae and estimation of intraspecies sequence divergence for portions of two rickettsial genes. J Bacteriol. 1991;173:1576–89.

61. Ahmed N, Devi SM, de los Á Valverde M, Vijayachari P, Machang'u RS, Ellis WA, et al. Multilocus sequence typing method for identification and genotypic classification of pathogenic *Leptospira* species. Ann Clin Microbiol Antimicrob. 2006;5:28.

62. Crawley JA, Chapman SN, Lummaa V, Lynsdale CL. Testing storage methods of faecal samples for subsequent measurement of helminth egg numbers in the domestic horse. Vet. Parasitol. 2016 May 15;221:130-3.

63. Halecker S, Bock S, Beer M, Hoffmann B. A new molecular detection system for canine distemper virus based on a double-check strategy. Viruses. 2021 Aug 18;13(8):1632.

64. Seo HJ, Noh J, Kim HC, Chong ST, Klein TA, Park CU, Choi CY, Kwon YS, Kim M, Min S, Park Y. Molecular detection and phylogenetic analysis of *Anaplasma* and *Borrelia* species in ticks collected from migratory birds at Heuksan, Hong, and Nan islands, Republic of Korea. Vector-Borne and Zoonotic Diseases. 2021 Jan 1;21(1):20-31.

# Appendix

**Table 3. PCR Protocols** Primers used for nested or traditional PCR on coyote blood, tissue, or ticks are shown. Sequences >200bp were deposited in GenBank, and their accession numbers are shown in the GenBank column.

| Organism | Gene | Sequence | Annealing temperature | PCR product | Citation | GenBank |
|---|---|---|---|---|---|---|
| *Trypanosoma cruzi* | 24s αRNA | D75: GCAGATCTTGGTTGGCGTAG<br>D76: GGTTCTCTGTTGCCCCTTTT | 59 | 262 | Souto et al. 1999 [59] | NA, all negative |
| *Rickettsia rickettsii* | OMPa | Rr190.70p: ATGGCGAATATTTCTCCAAAA;<br>Rr190.602n: AGTGCAGCATTCGCTCCCCCT | 50 | 532 | Regnery et al. 1991 [60] | NA, all negative |
| *Leptospira* | Lipl32 | LipL32F: ATCTCCGTTGCACTCTTTGC<br>LipL32R: ACCATCATCATCATCGTCCA | 55 | 474 | Ahmed et al. 2006 [61] | PP554249-PP554251 |
| *Leptospira* | rrs2 (16S rRNA) | rrs2F: CATGCAAGTCAAGCGGAGTA<br>rrs2R: AGTTGAGCCCGCAGTTTTC | 55 | 541 | Ahmed et al. 2006 [61] | PP555946-PP555948 |
| *Trichinella* | LRS rRNA ESV | NeF: TCTTGGTGGTAGTAGC<br>NeR: GCGATTGAGTTGAACGC | 55 | ~225 | Zarlenga et al. 1999 [13] | PP544891<br>PP544892 |
| Taeniidae spp. | COI | EchinoCOIF: TTTTTTGGGCATCCTGAGGTTTAT<br>EchinoCOIR:TAAAGAAAGAACATAATGAAAATG | 55 | ~450 | Gasser et al. 1999 [15] | PP555030-PP555945 |
| CPV | VP2 | M1: GAAAACGGATGGGTGGAAAT<br>M2: AGTTGCCAATCTCCTGGATT | 50 | 221 | Schunck et al. 1995 [11] | PP554252-PP554255 |
| *Borrelia burgdorferi* | 16S rRNA IGS | External - (F): GTATGTTTAGTGAGGGGGGTG; (R): GGATCATAGCTCAGGTGGTTAG Internal - (Fi): AGGGGGGTGAAGTCGTAACAAG; (Ri): GTCTGATAAACCTGAGGTCGGA | 55 (external); 60 (internal) | 1336 | Kelly et al. 2014 [12] | PP544200-PP544202 |
| Trematodes | 18S | Trem18SF: ATGGCTCATTAAATCAGCTAT,<br>Trem18SR: TGCTTTGAGCACTCAAATTTG | 60 | ~720 | Diaz et al. 2020 [16] | PP544396-PP544398 |

**Table 4**. **Histopathologic lesions found in coyotes**

Percentage positive is shown, with total number positive and total number assessed in parenthesis. Some tissues have lower sample size either due to autolysis or because certain tissues (pancreas, bladder, and skin) were not routinely sampled until later in the study.

| **Category** | **Lesion** | **TN** | **SC** | **Total** |
|---|---|---|---|---|
| Musculoskeletal | Chronic fracture | 2.8% (2/71) | 13% (2/15) | 4.6% (4/86) |
| | Myositis | 14% (10/71) | 27% (4/15) | 16% (14/86) |
| | Glossitis | 12% (6/49) | 9% (1/11) | 12% (7/60) |
| | *Trichinella* | 17% (12/71) | 0% (0/15) | 14% (12/86) |
| Cardiac | Myocarditis | 4% (3/73) | 33% (5/15) | 9% (8/88) |
| | Heartworm | 45% (33/74) | 53% (8/15) | 46% (41/89) |
| Pulmonary | *Paragonimus* | 24% (17/71) | 0% (0/15) | 20% (17/86) |
| | Eosinophilic Alveolitis | 8.5% (6/71) | 27% (4/15) | 12% (10/86) |
| | Endarteritis or periarteritis | 8.5% (6/71) | 0% (0/15) | 7.0% (6/86) |
| | Other Pneumonia | 11% (8/71) | 27% (4/15) | 14% (12/86) |
| Urogenital | Interstitial nephritis | 27% (16/60) | 43% (6/14) | 30% (22/74) |
| | Renal abscesses | 1.7% (1/60) | 0% (0/15) | 1.3% (1/75) |
| | Chronic renal infarction | 6.7% (4/60) | 6.7% (1/15) | 6.7% (5/75) |
| | Cystitis | 15% (8/53) | 0% (0/2) | 15% (8/55) |
| Skin | Allergic dermatitis | 29% (9/31) | 14% (1/7) | 26% (10/38) |
| | Vasculitis | 3.2% (1/31) | 0% (0/7) | 2.6% (1/38) |
| | Sarcoptic mange | 1.4% (1/71) | 0% (0/15) | 1.2% (1/86) |
| Misc. | Pancreatic duct hyperplasia | 44% (7/16) | 0% (0/3) | 37% (7/19) |
| | Hepatitis | 35% (8/23) | 20% (1/5) | 32% (9/28) |
| | Sepsis | 1.4% (1/71) | 6.7% (1/15) | 2.3% (2/86) |

**Table 5**. **Serology results from coyotes from TN and SC**

Total positives and total number tested are shown in parenthesis. The Chagas Stat-Pak was used as the primary screening tool for *T. cruzi* in coyotes, and only coyotes positive on the Stat-Pak were tested with the InBios ICT or IFA at Texas A&M University. Coyotes were considered positive if they were positive on 2 or more tests.

| State | *Toxoplasma gondii* | *Leptospira* | *Anaplasma* | *Ehrlichia* | *Borrelia* | Heartworm Antigen | *T. cruzi* | | | |
|---|---|---|---|---|---|---|---|---|---|---|
| | | | | | | | Stat-Pak | InBios ICT | IFA | Pos on ≥2 tests |
| TN | 82% (54/66) | 25% (13/53) | 26% (17/65) | 66% (43/65) | 43% (28/65) | 37% (24/65) | 18% (12/66) | 20% (2/10) | 0% (0/7) | 3.1% (2/64) |
| SC | 92% (36/39) | 26% (10/38) | 0% (0/52) | 21% (11/52) | 2% (1/52) | 35% (18/52) | 23% (9/40) | 78% (7/9) | 11% (1/9) | 17.5% (7/40) |
| Total | 86% (90/105) | 25% (23/91) | 15% (17/117) | 46% (54/117) | 25% (29/117) | 36% (42/117) | 20% (21/106) | 47% (9/19) | 6.2% (1/16) | 8.6% (9/104) |

**Table 6. PCR results from coyotes from TN and SC**

Protocols for PCR are available in Table 3. Coyotes were considered CPV positive if they had a replicable CT value <35 on rtPCR or if sequence was obtained with traditional PCR. All SC coyote feces were preserved in ethanol prior to testing, while TN feces was fresh. If only traditional PCR on fresh fecal samples is considered, 10.5% (4/38) were positive.

| | ***Rickettsia rickettsii*** | ***Trypanosoma cruzi*** | ***Leptospira*** | **CPV** | **CDV** | ***Borrelia*** |
|---|---|---|---|---|---|---|
| Organ tested | Whole blood | Whole blood and heart | Kidney | Feces | Lung | Ticks |
| TN | 0% (0/74) | 0% (0/74) | 4.7% (3/64) | 9.3% (4/43) | 8% (5/63) | 4.7% (4/86) |
| SC | 0% (0/56) | 0% (0/56) | 0% (0/11) | 1.4% (1/70) | 15.4% (2/13) | Not tested |
| Total | 0% (0/130) | 0% (0/130) | 4.0% (3/75) | 4.4% (5/113) | 9% (7/76) | 4.7% (4/86) |

**Table 7. Fecal flotation results from coyotes from Tennessee (TN) and South Carolina (SC)**

The percentage of coyotes positive for each parasite is shown, with the total number positive and total number tested in parenthesis. The *Neospora*-like category includes both *N. caninum* and *Hammondia* spp. since they are indistinguishable on fecal flotation. Samples from SC were stored in ethanol for 1-6 months before processing, while samples from TN were processed fresh within 24 hours of collection. Parasites in the other category included *Uncinaria, Strongyloides,* and dorsal-spine larvae.

| **Species** | **TN** | **SC** | **Total** |
|---|---|---|---|
| *Ancylostoma* | 77% (40/52) | 2.5% (2/80) | 32% (42/132) |
| *Sarcocystis* | 54% (28/52) | 14% (11/80) | 30% (39/132) |
| *Neospora*-like | 21% (11/52) | 5% (4/80) | 11% (15/132) |
| *Coccidia* | 9.6% (5/52) | 10% (8/80) | 9.8% (13/132) |
| *Capillaria* | 29% (15/52) | 3.8% (3/80) | 14% (18/132) |
| *Paragonimus* | 25% (13/52) | 2.5% (2/80) | 11% (15/132) |
| *Trichuris* | 17% (9/52) | 2.5% (2/80) | 8.3% (11/132) |
| *Taeniidae* | 7.7% (4/52) | 10% (8/80) | 9.1% (12/132) |
| *Physaloptera* | 7.7% (4/52) | 0% (0/80) | 3.0% (4/132) |
| Ascarid | 15% (8/52) | 2.5% (2/80) | 7.6% (10/132) |
| *Eurytrema* | 7.7% (4/52) | 0% (0/80) | 3.0% (4/132) |
| Other | 21% (11/52) | 0% (0/80) | 9.1% (11/132) |

**Table 8. Tick species collected from coyotes from TN and SC**

The total number of ticks collected is shown with the percentage in parenthesis.

| | Total Ticks | *Ixodes scapularis* | *Amblyomma americanum* | *Amblyomma maculatum* | *Dermacentor variabilis* |
|---|---|---|---|---|---|
| **Total** | 313 | 177 (57%) | 102 (33%) | 15 (4.8%) | 19 (6%) |
| **TN** | 203 | 88 (43%) | 94 (46%) | 2 (1%) | 19 (9.4%) |
| **SC** | 110 | 89 (81%) | 8 (7.3%) | 13 (12%) | 0 |

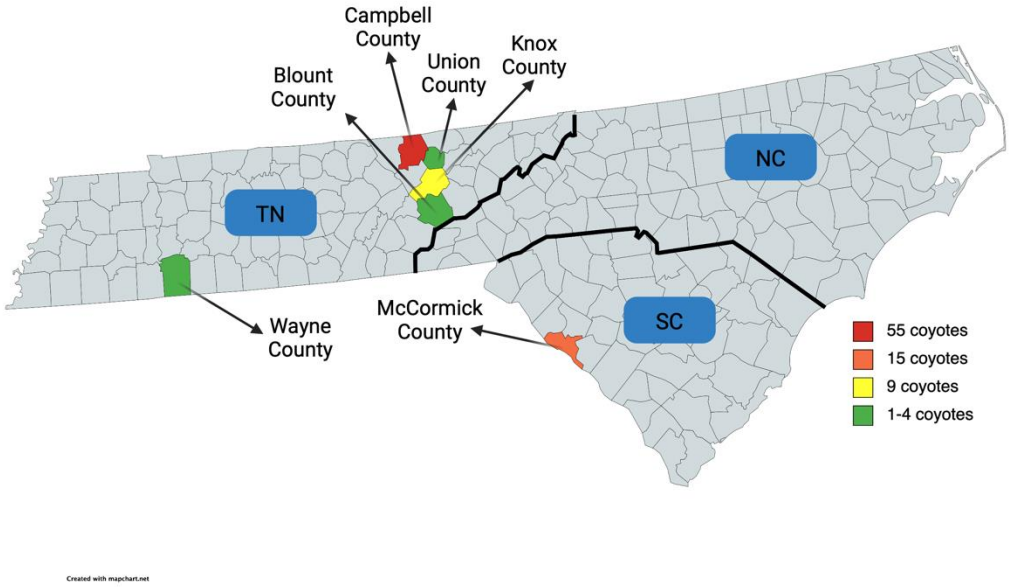


**Figure 8. Sampling locations of coyotes**

The locations of collected coyote carcasses in Tennessee (TN) and South Carolina (SC) are shown. Created with MapCharts.

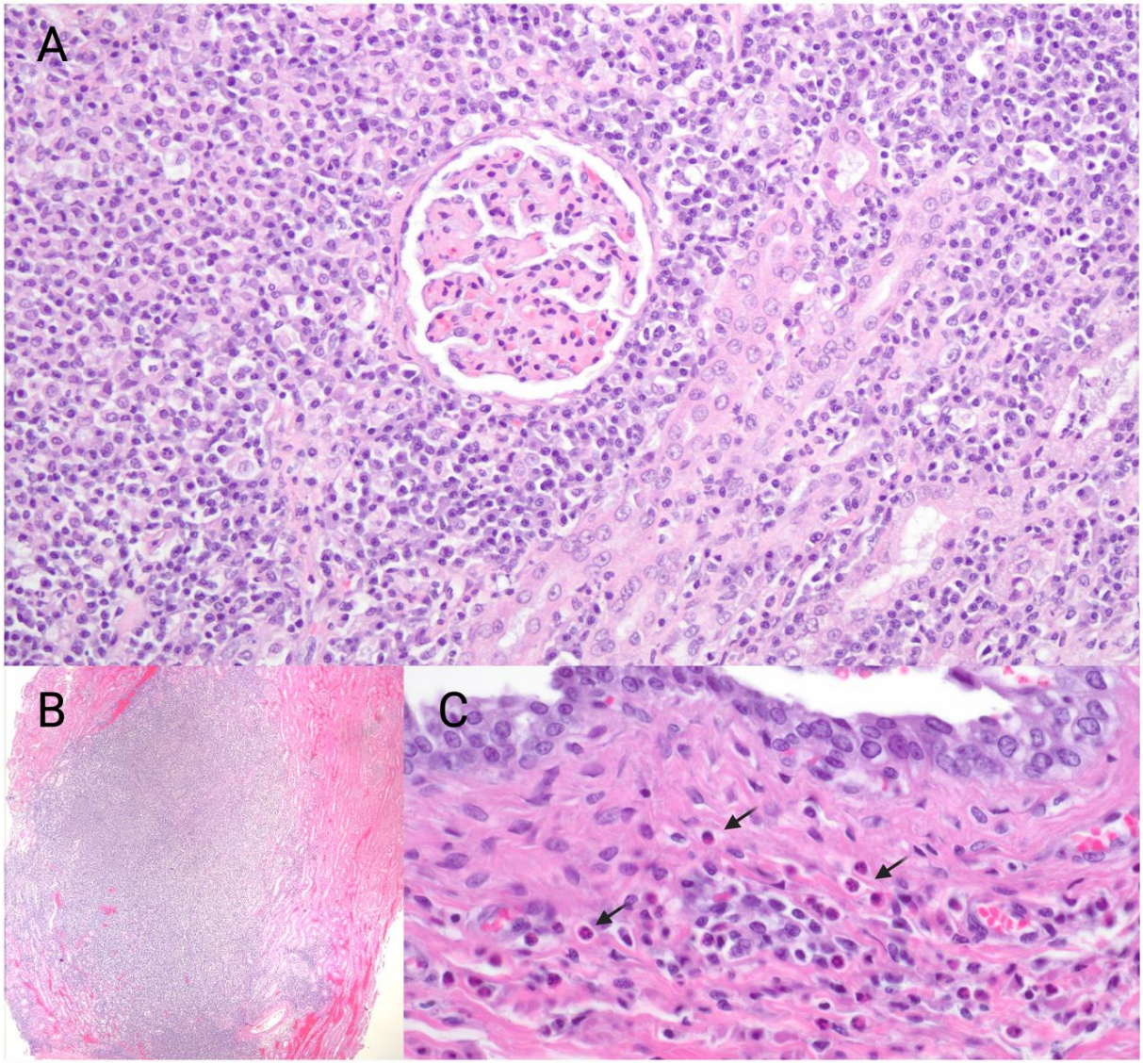


**Figure 9. Nephritis and cystitis in *Canis latrans***

A. Photomicrograph of severe, lymphoplasmacytic interstitial nephritis in *Canis latrans.* The glomeruli and renal tubules are surrounded by inflammation, primarily lymphocytes and plasma cells with fewer macrophages. B. Photomicrograph from *Canis latrans* with severe, multifocal renal abscesses. The renal cortex is consumed by neutrophilic inflammation, and remaining renal tubules are expanded by inflammation and hemorrhage. C. Mild eosinophilic cystitis in *Canis latrans.* There is mild mixed inflammation primarily consisting of eosinophils (arrows) in the lamina propria of the bladder.

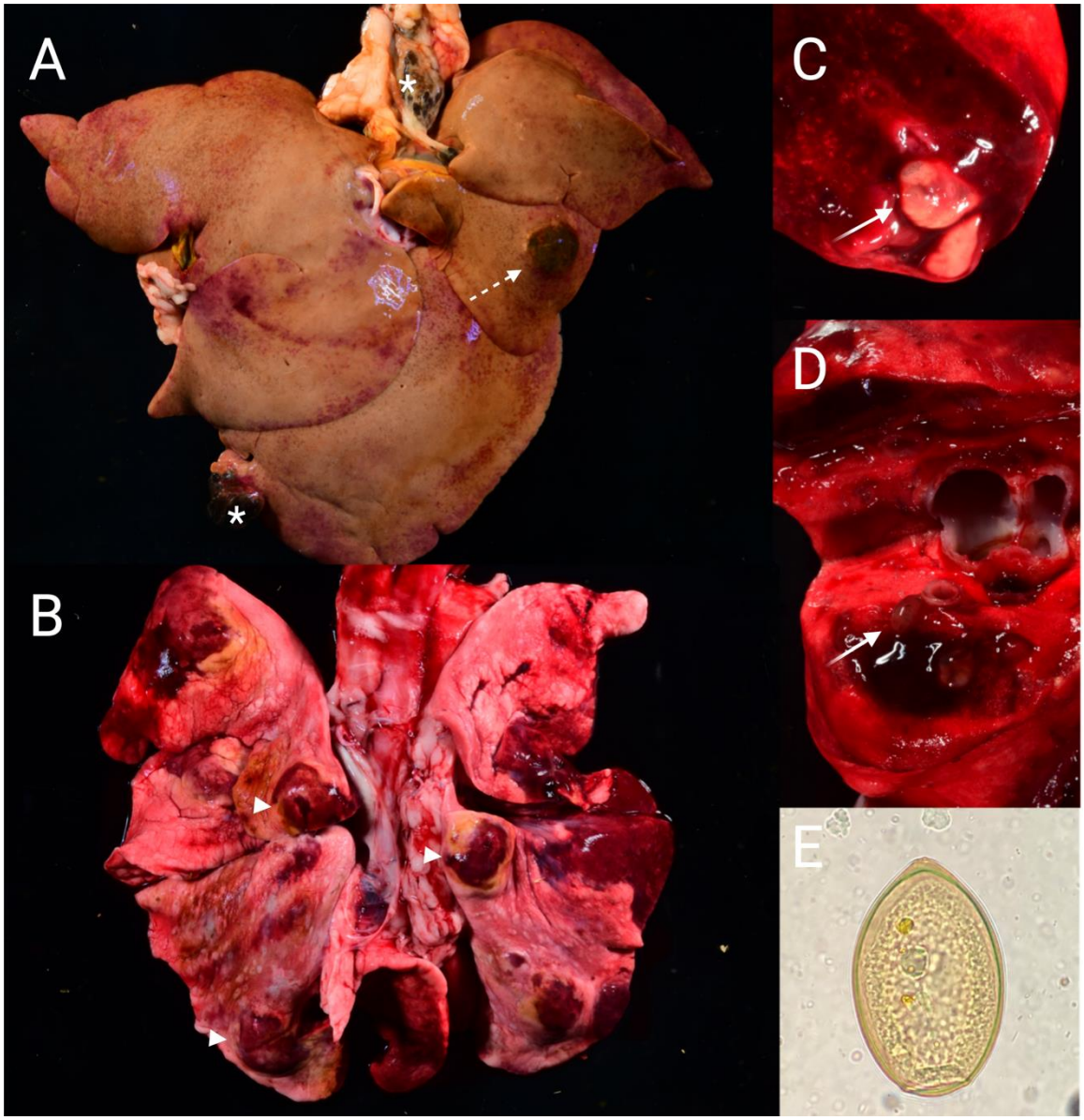


**Figure 10. Extrapulmonary *Paragonimus kellicotti* infection in *Canis latrans***

*Paragonimus kellicotti* cysts in the liver and lung of *Canis latrans*
A. Liver with a 4cmx3cm mass in the left lobe (dashed arrow) which contained parasitic hematin and two *P. kellicotti* flukes. Dark brown pigmented masses containing *P. kellicotti* eggs were also in the fat surrounding the liver and along the edge of the right medial liver lobe (asterisk). B. Lungs from the same coyote with numerous *P. kellicotti* cysts (arrow heads) in multiple lobes. Cysts were apparent grossly by their firm texture and dark red color, and contained two *P. kellicotti* adults (C,D, arrows). E. *P. kellicotti* egg from the same coyote seen on fecal flotation.

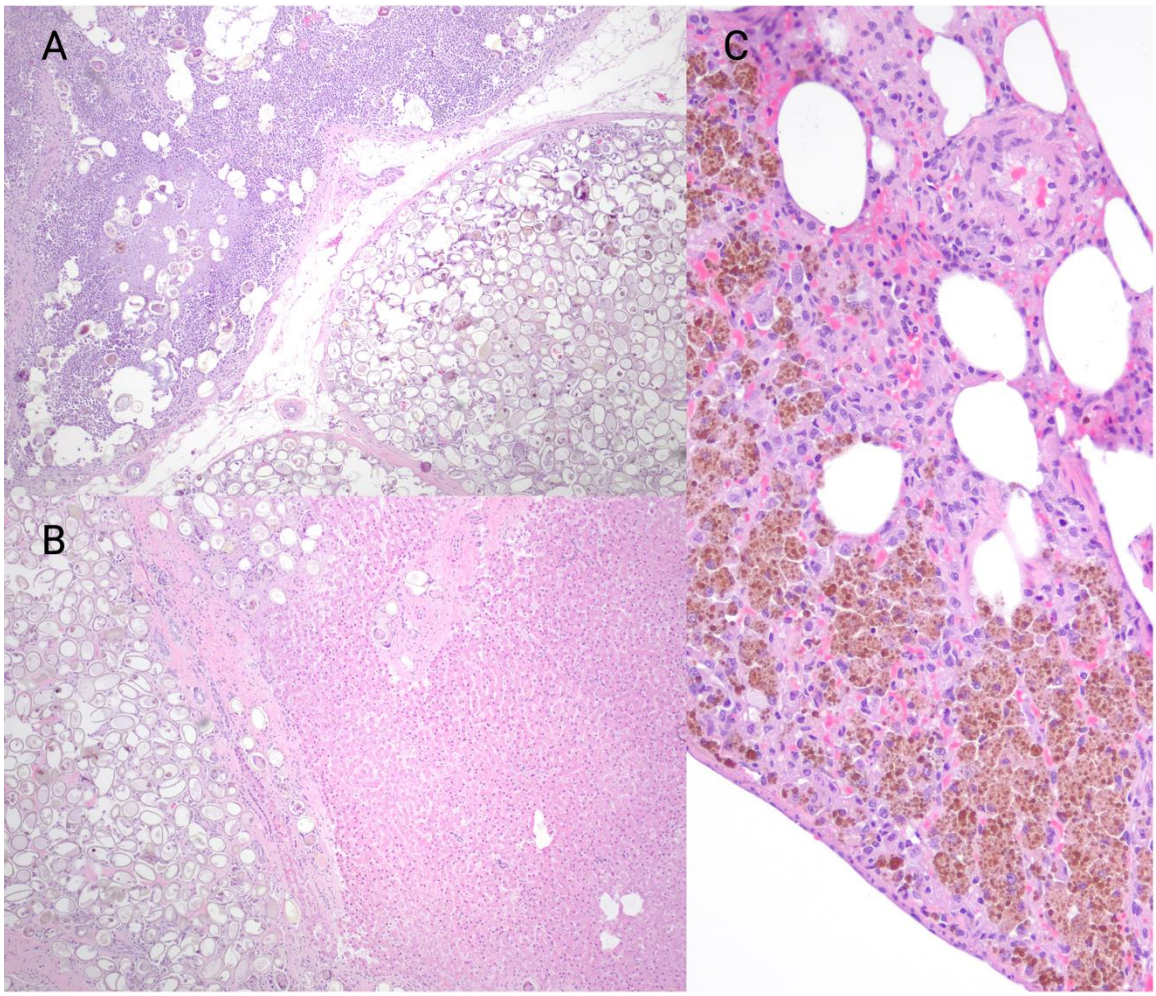


**Figure 11. *Paragonimus kellicotti* egg granuloma in liver and neighboring lymph nodes**

A. Mesenteric lymph node hyperplasia with intracortical *P. kellicotti* eggs. Adjacent lymphatic vessels are also plugged with eggs. B. Severe, focal, hepatic *P. kellicotti* egg granuloma. There are dense collections of *P. kellicotti* eggs expanding the hepatic parenchyma with moderate mixed inflammation. C. Pulmonary hemosiderosis in *Canis latrans* infected with *P. kellicotti*. Hemosiderin-laden macrophages were throughout the pulmonary interstitium of all coyotes with paragonimiasis.

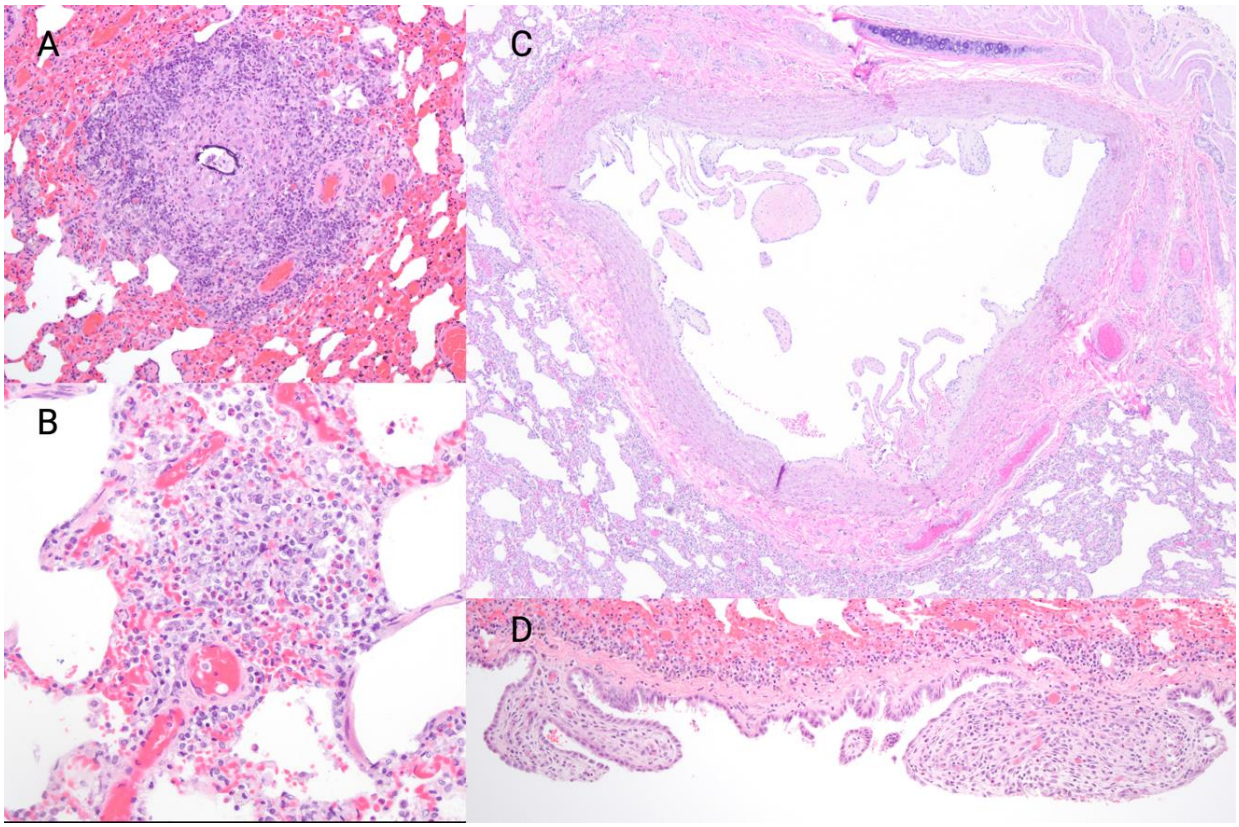


**Figure 12. Parasitic pulmonary changes in *Canis latrans***

A. Pulmonary granuloma in *Canis latrans* surrounding calcification, putatively associated with parasite migration. B. Mild eosinophilic alveolitis in *Canis latrans.* Multifocal clusters of mixed inflammation consisting primarily of eosinophils with fewer macrophages and neutrophils expand the pulmonary interstitium. C. Villous endarteritis in *C. latrans* due to *Dirofilaria immitis* infection. D. Mesothelial hyperplasia in *C. latrans* likely secondary to *Paragonimus kellicotti* infection.

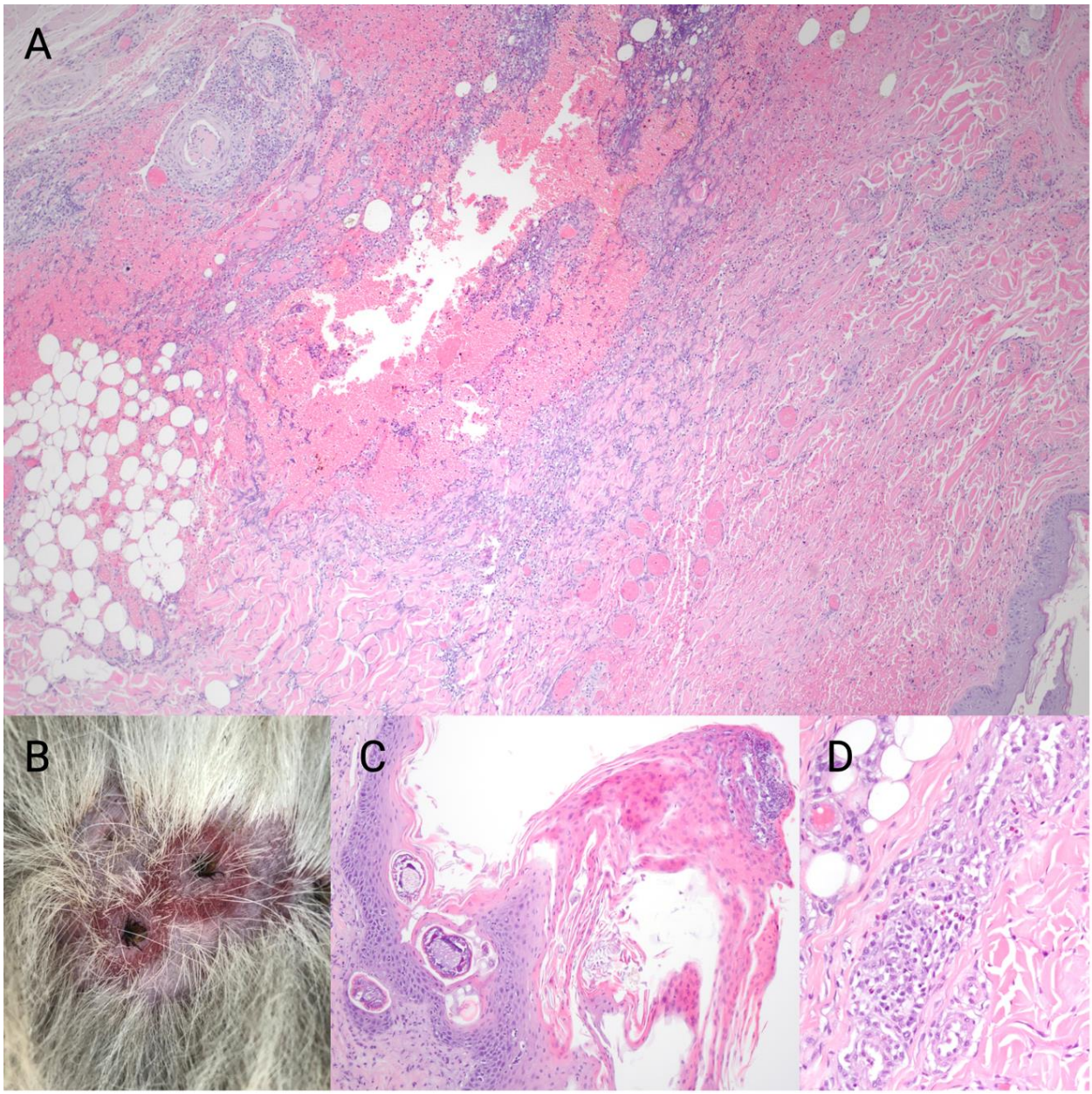


**Figure 13. Parasitic dermatitis in *Canis latrans***

A. Photomicrograph of severe, acute vasculitis associated with tick bites in *C. latrans.* Diffuse hemorrhage with mixed inflammation and rare thrombi expand the subcutis. The vasculitis is constrained to a circular area surrounding the tick bites. B. Multifocal rings of erythema surround embedded *Ixodes scapularis* ticks on *Canis latrans*. C. *Sarcoptes scabiei* dermatitis in *C. latrans*. Serocellular crusts consisting of acantholytic keratinocytes overlie the cross section of three mites. The stratum spongiosum is mildly thickened. D. Mild eosinophilic allergic dermatitis in *C. latrans.* Mild eosinophilic inflammation is present within the periadnexal and perivascular tissue.

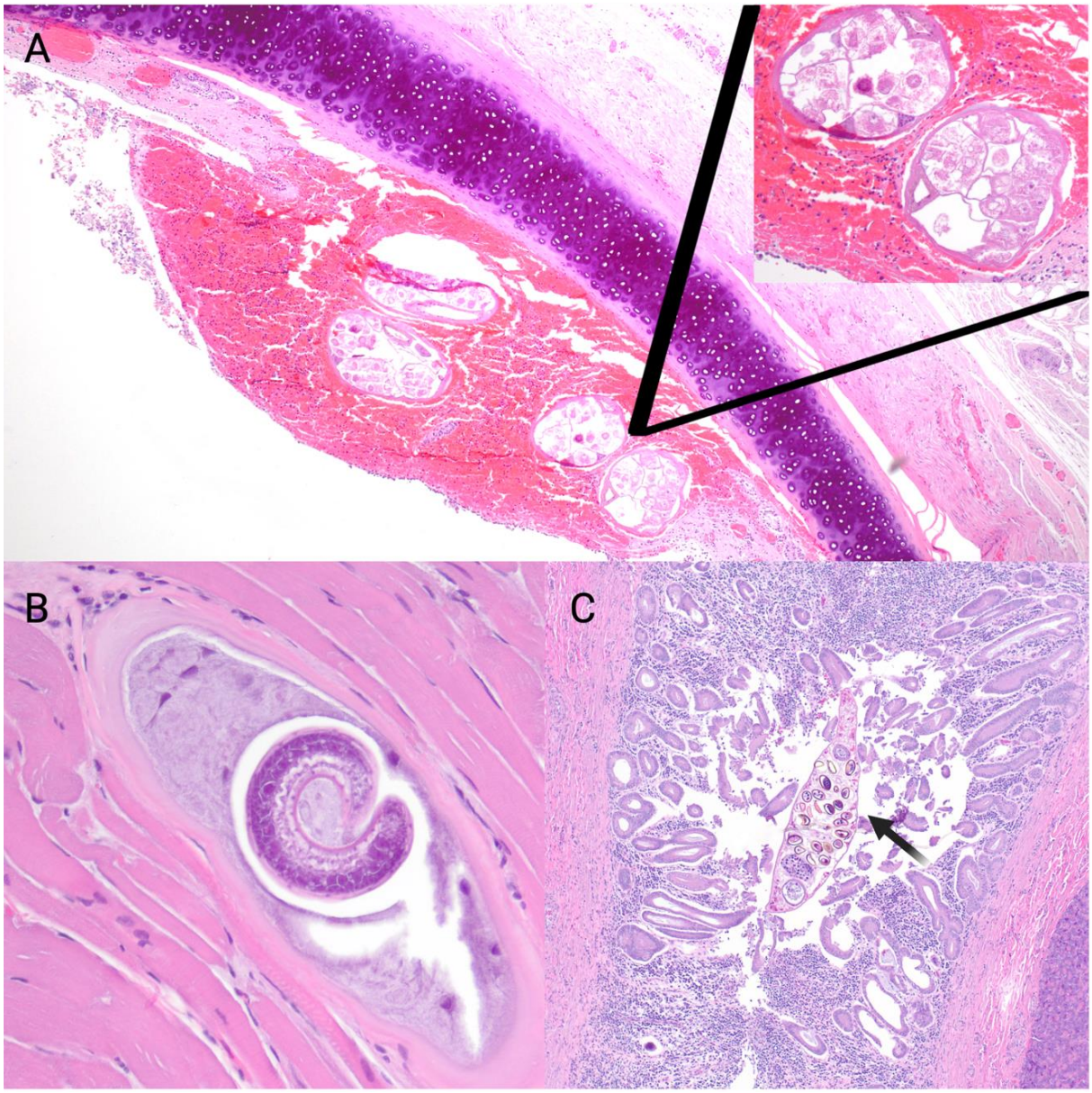


**Figure 14. Examples of parasites found in *Canis latrans***

A. Focal hemorrhagic tracheitis associated with *Oslerus osleri* in *C. latrans*. Mild mixed inflammation is present within the hemorrhagic nodule, and the tracheal epithelium is multifocally eroded. B. Intramyocytic *Trichinella* sp. larvae in *C. latrans.* There is minimal associated inflammation surrounding the nurse cell. C. Chronic proliferative pancreatic dochitis in *C. latrans* due to *Eurytrema* sp. infection. The duct is hypertrophied with significant mixed inflammation filling the lumen. An adult *Eurytrema* fluke is present within the pancreatic duct (arrow).

# CONCLUSION

## Urban wildlife make excellent sentinels for diseases of human and animal concern

In the wake of a global pandemic, the importance of wildlife disease surveillance has never been clearer. Most emerging and re-emerging diseases are zoonotic, with an estimated 70% of those originating in wildlife [1]. In addition, many economically and agriculturally important diseases like anthrax, tuberculosis, and brucellosis are known to pass between wildlife and livestock [2]. Though public interest in wildlife disease research has historically been lacking, focus on regular surveillance has increased recently after numerous diseases, from COVID-19 to Ebola, have made the jump from animals to humans in the public arena.

The importance of a "One Health" approach, or collaboratively integrating societal, environmental, and veterinary perspectives into our understanding of global health, has also taken a spotlight in recent years [3]. Though surveillance of human diseases is typically prioritized, a complete view of public health must include all factors that influence the start, spread, and impact of a disease. In addition, cooperation at the local, national, and international level is required to prepare for future outbreaks. For example, urbanization and climate change play a pivotal role, not just in the spread of known pathogens, but also the risk for the development of new diseases. As wilderness is altered for human housing and farmland, the junction between wildlife, domesticated animals, and humans becomes interwoven, causing increased exposure to previously rare or unknown pathogens [4]. Though these types of outbreaks are unavoidable, our preparedness to face them depends largely on the background of research and surveillance done before the first human infection occurs.

There are numerous methods for population surveillance. In many cases, it is simplest to sample the population of interest itself. However, when the targeted population is elusive, fragile, or endangered, many researchers choose to rely on sentinel animals. For example, in South Dakota coyotes are used as sentinels for the diseases that can infect the endangered black footed ferret [5]. Sentinel sampling has numerous benefits including increased sample size and decreased risk to the population of interest. In the case of zoonotic diseases, wildlife sentinels can indicate the relative risk for public health without requiring extensive human testing.

An ideal sentinel is easily captured or monitored, maintains a steady and healthy population, and shares some significant diseases with the population of interest [5]. In some cases, an ideal sentinel will be more susceptible to disease than the target population. Crows, for example, are susceptible to severe disease from West Nile Virus, while humans are often resistant [6]. Therefore, die-offs will be seen in crows at the very start of the season, allowing public health officials time to plan and prepare for potential human cases. In other instances, an ideal sentinel will be more resistant to the disease. White-tailed deer rarely have clinical symptoms from *Parelaphostrongylus tenuis* infections even though disease is often fatal in moose or elk [7]. Deer can therefore be used to assess the prevalence of the disease in an area to better understand the risk to other native cervids. Pest species, like coyotes, raccoons, and opossums, also make

excellent sentinels due to their abundance. In addition, they live at the cross section of urban and wild areas and interact frequently with humans, allowing for the possible spread of disease.

A complete assessment of ecosystem health must rely on numerous testing and sampling strategies. It is impossible to mitigate the risks of spillover to people or pets without understanding the disease ecology in wildlife.

# References

1. Cutler SJ, Fooks AR, van der Poel WHM. Public Health Threat of New, Reemerging, and Neglected Zoonoses in the Industrialized World. Emerg Infect Dis. 2010;16:1–7.

2. Pruvot M, Musiani M, Boyce MS, Kutz S, Orsel K. Integrating livestock management and telemetry data to assess disease transmission risk between wildlife and livestock. Prev Vet Med. 2020;174:104846.

3. Mackenzie JS, Jeggo M. The One Health Approach—Why Is It So Important? Trop Med Infect Dis. 2019;4:88.

4. Mackenzie JS, Jeggo M, Daszak P, Richt JA, editors. One Health: The Human-Animal-Environment Interfaces in Emerging Infectious Diseases: The Concept and Examples of a One Health Approach. Berlin, Heidelberg: Springer; 2013.

5. Schuler K, Claymore M, Schnitzler H, Dubovi E, Rocke T, Perry MJ, et al. Sentinel coyote pathogen survey to assess declining black-footed ferret (*Mustela nigripes*) population in South Dakota, USA. J Wildl Dis. 2020;57:264–72.

6. Eidson M, Komar N, Sorhage F, Nelson R, Talbot T, Mostashari F, et al. Crow deaths as a sentinel surveillance system for West Nile virus in the northeastern United States, 1999. Emerg Infect Dis. 2001;7:615–20.

7. Lankester MW. Understanding the impact of meningeal worm, *Parelaphostrongylus tenuis*, on moose populations. Alces J Devoted Biol Manag Moose. 2010;46:53–70.

# VITA

Eliza Baker began her wildlife career by volunteering at a wildlife rehabilitation center in her hometown of Nashville, Tennessee as soon as she received her driver's license. During her undergraduate program at American University in Washington, D.C., she began working for a wildlife rehabilitation clinic that focused on urban wildlife. She was interested in the ways the wildlife clinic worked with the local health department to monitor for West Nile Virus and lead contamination in the area. This experience compelled her to pursue veterinary school at University of Tennessee, where she began volunteering in Dr. Richard Gerhold's lab after her first year. Her initial projects focused on wild turkey health, but she quickly found a passion for pathology and urban mammals. She began researching coyote and raccoon diseases her second year of veterinary school and decided to apply pursue a PhD soon after.