To the Graduate Council:

I am submitting herewith a thesis written by Tyler Grant O'Brien entitled "Human Soft-tissue Decomposition in an Aquatic Environment and its Transformation into Adipocere". I have examined the final copy of this thesis for form and content and recommend that it be accepted in partial fulfillment of the requirements for the degree of Master of Arts, with a major in Anthropology.

William M. Bass, Major Professor

We have read this thesis

and recommend its acceptance:

Accepted for the Council:

Associate Vice Chancellor

and Dean of the Graduate School

HUMAN SOFT-TISSUE DECOMPOSITION IN AN AQUATIC ENVIRONMENT AND ITS TRANSFORMATION INTO ADIPOCERE

A Thesis Presented for the

Master of Arts Degree

The University of Tennessee, Knoxville

Tyler G. O'Brien

May 1994

Copyright 1994 by Tyler G. O'Brien

All rights reserved

ACKNOWLEDGMENTS

I have traveled the path of a graduate student for three years now and have come to only one juncture in the trail. Ahead of me lies a vast forest of knowledge and experience and I am not yet even half way there. I have much to learn and live. But for that part of my life which I have already tread upon I owe many gratuitous praises. The following have lent me support and concern for my long trip. They have cooperated with me, understood my bizarre fascination for this pursuit, and shared in my exasperation and weariness while standing at my side and forever pushing me on and encouraging me to do my best; for this I acknowledge you all.

To the most important individuals in my life, my family: I owe you this paper and one more. But for that one I will pay in more ways than just financially. Soon there will be two doctors in the house.

To my committee members, Dr. Klippel and Dr. Jantz: your support and editing has resulted in this finalized version. Thank you.

To Dr. William Bass, committee chair, major professor, advisor, mentor, teacher, and friend: I owe you more than just this stack of paper. This research is claimed as "never done before in the world, as far as we know it" (LESAT, 1994). Its uniqueness and intriguing nature will carry me throughout my life with future research papers and might even get me tenure. This will certainly become a landmark for future research at the Facility. Forever, I will honor your teachings and stories. I will always appreciate your concern for my advancement in the field of forensic anthropology by allowing me opportunities to lecture and assist you. I am eternally grateful. Thank you.

To David Ringelberg, you were supportive, patient, extremely understanding and cooperative toward my ignorance of the chemistry involved in such an undertaking as this type of work. Thank you for providing me with the materials and the methods for applying some form of statistical analysis to this project. Obviously thanks to the Center for Environmental Biotechnology for the use of their facilities.

To my friends, you know who you are: thanks for the advice and the criticisms and the ideas. Can't you find something else better to do with your time than read this. Andy, thanks for the carpentry.

Finally, and most importantly, a friend who is and will always be very important in my life: without your encouragement, support, admiration, faith, and love I might not be at this place right now. I owe you. My debt will be to read your thesis.

ABSTRACT

The problems addressed in this study are how long does it take for adipocere to form in a human body and what are the gross morphological changes that occur on and within the decomposing body. In order to determine the answers for these questions an actualistic study was constructed to test the rates of adipocere formation on human cadavers in a non-laboratory environment.

The experiment consisted of immersing three human cadavers into excavated holes in the earth for three months (or until adipocere formed). Gross morphological changes of the external tissues and body were recorded as well as the ambient and water temperatures. Fluctuations in climatological and meteorological conditions were compared to the transformation occurring in and around the cadavers. Liquid and tissue samples were extracted during the study period and analyzed for fatty acid content and microbial composition.

The analysis of recorded temperatures for both weather and water revealed that adipocere formation was most likely occurring during the warmer periods of the study. The interpretation of the fatty acid profiles showed inconclusive results but suggested the expected increase in palmitic fatty acid as the rate of oleic fatty acid decreased. The polar lipid fatty acid profile suggested corroborative evidence of *Clostridium perfringens (welchii)*, the primary bacteria responsible for adipocere formation, still present after a three month interval.

Conclusions suggest that temperature is a major variable in underwater decomposition. The "Goldilocks Phenomenon" indicates there is a certain range for temperatures to be operative in the formation of adipocere. The

optimum growth temperature for the primary bacteria involved in the formation, *Clostridium perfringens* (*welchii*), would be from about 70° to 113° F. (21° to 45° C.). The literature on this topic states that a warm, moist, virtually anaerobic environment with adequate bacterial action is suitable for adipocere formation to occur. This study concurs with these criteria. In two of the three cadavers, characteristic tissue resembling that found on adipociferous bodies was present after a time period of three months. The two cases with this phenomenon were the ones that floated the entire time of the study. The gross morphological changes that occurred in/on the cadaver in Hole 2 provided data for a progressional stage analysis to be made. The development of adipocere formed on the cadaver in the following stages: float, bloat, insect activity, hatching, mummification/maceration, fungal growth, color loss, cutis anserina, adipocere. The limited sample size (i.e., three cadavers) for this research does not allow for accurate predictions to be made on adipocere formation. However, it is possible to say that complete immersion in an aquatic environment may not be necessary for this decompositional process to occur. Also, an individual who is deceased prior to immersion will tend to float but is still susceptible to adipocere formation.

CONTENTS

I. INTRODUCTION 1

II. WHAT IS ADIPOCERE 9

III. HOW IS ADIPOCERE FORMED 13

IV. WHERE AND WHY IS IT FORMED 17

V. MATERIALS AND METHODS 27

VI. RESULTS 36

VII. DISCUSSION AND CONCLUSIONS 47

VIII. SUMMARY 71

BIBLIOGRAPHY 74

APPENDICES 80

APPENDIX A. Partial Analysis of Composites of Daily Samples of Raw and Tap Water 81

APPENDIX B. Brief Overview of Commercial Soap Manufacture 82

APPENDIX C. Suggested Readings on Topics Relating to Adipocere Development 85

VITA 87

LIST OF FIGURES

Figure 1. Post mortem actions of a human body during underwater decomposition: The Free Floating and Snagged Scenarios 2

Figure 2. Schematic for Hole 1 without polyethylene plastic 30

Figure 3. Schematic for Hole 2 without polyethylene plastic 31

Figure 4. Schematic for Hole 3 without polyethylene plastic 32

Figure 5. Schematic for tray used in retrieval of cadaver 34

Figure 6. Graph of Temperature Measurements from October 20, 1993 to January 22. 1994 displaying air and water temperatures against air temperatures from the National Oceanic and Atmospheric Administration (NOAA) 44

Figure 7. Free Fatty Acid analysis for flesh and fluid samples from Holes 1, 2, and 3. (Provided by the University of Tennessee Center for Environmental Biotechnology) 60

Figure 8. Polar Lipid Fatty Acid analysis for flesh and fluid samples from Holes 1, 2, and 3. (Provided by the University of Tennessee Center for Environmental Biotechnology) 61

LIST OF TABLES

Table 1. The Percentage Composition of Hard Clean Adipocere Wax ... 11

Table 2. Temperature Measurements for Air and Water 43

Table 3. Variables Involved in Adipocere Formation 63

Table 4. Case Reports Citing Bodies Found with Adipocere 64

I. INTRODUCTION

The crime scene is set to where the police are pulling a human body out of a lake. A fully nude, adult, male's corpse is laid on the ground and examined by the forensic anthropologist. He or she notices the skin and how it has changed in appearance and texture. It has transformed to a grayish-yellow, thick, dense, waxy substance. Because it is still fresh the tissue remains soft and damp, and has kept the body in a remarkable state of preservation. The forensic anthropologist is questioned as to when this individual died. A case similar to this one is recited and from experience with the phenomenon (i.e., underwater decomposition) the forensic anthropologist is able to respond with "a little over two years, maybe".

When the human life-functions cease (heart ceases to beat) a curious phenomenon sets its course; a sequence by which decompositional processes take over and the body begins to putrefy. This incident can occur on land, buried or underwater (there are numerous other places where decomposition may occur but these are the general locations). When the body falls into or is located in water or a damp environment the putrefaction takes a different route. For example, say the deceased was on a boat and suffered a myocardial infarction and collapsed but in so doing fell overboard into a fresh water lake. The postmortem actions of the body would occur roughly in the following stages (O'Brien, 1993) assuming there is no apparent trauma (see Figure 1):

1.) the body would float for a variable period of time depending on how long it takes for the lungs to fill with water and the air to evacuate the body's cavities; the body would then become totally immersed and sink. At such time other factors start playing a crucial role in determining time since death.

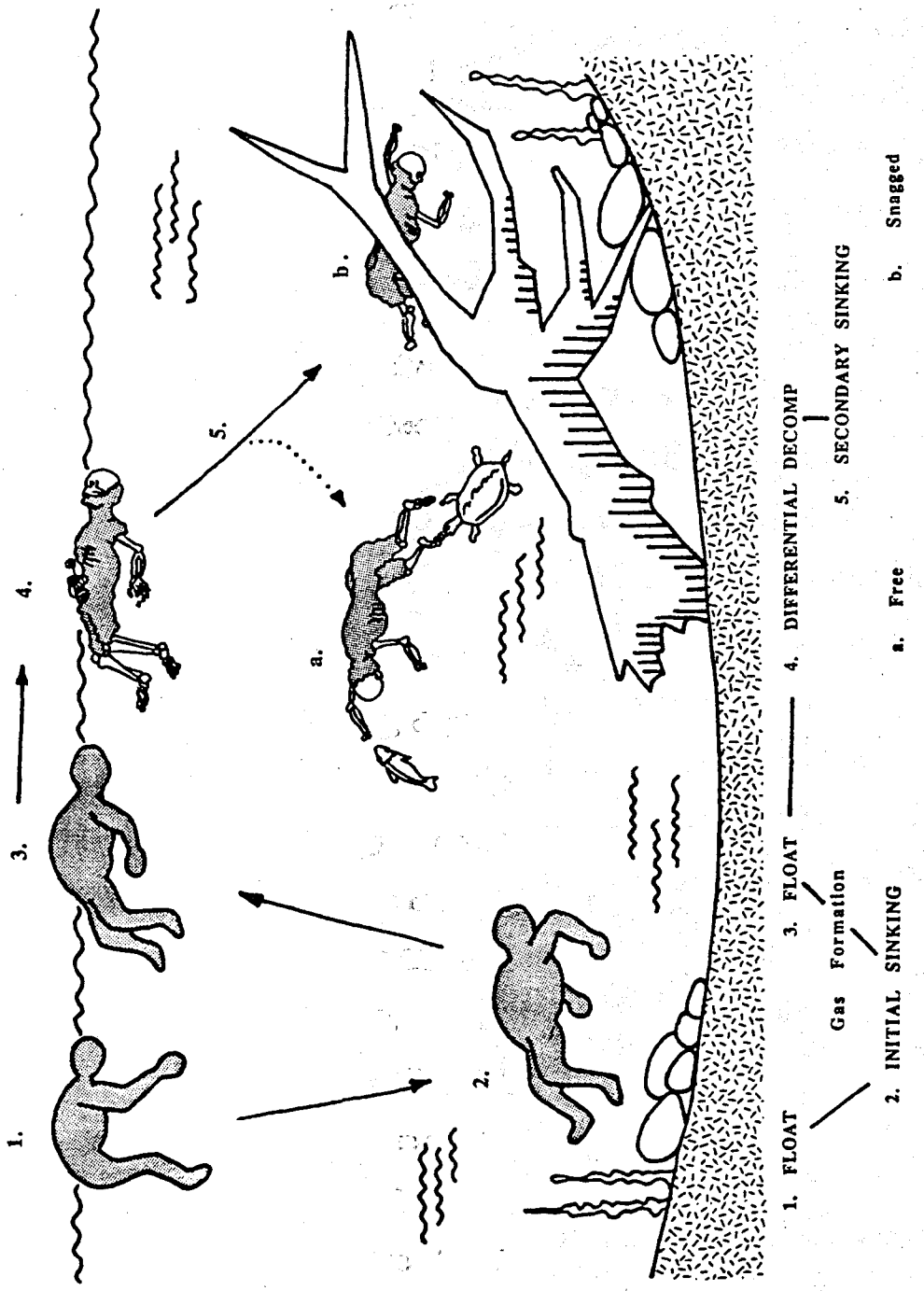

Figure 1. POST MORTEM ACTIONS OF A HUMAN BODY DURING UNDERWATER DECOMPOSITION: THE FREE FLOATING AND SNAGGING SCENARIOS (O'Brien, 1993)

Climatic conditions, predation, and bodily build (Knight, 1991) can inhibit the body from refloatation.

2.) But the next stage of decomposition in immersion deaths involves the evolution of the putrefactive bacteria. The bacteria from within the intestinal tract and the digestive system migrate throughout the body (Drasar and Hill, 1974). Their ingestion of the internal viscera of the decedent creates toxic gases which makes the body inflate and rise. The rate of this rise is dependent upon evolution of these bacteria as well as contact with underwater obstructions.

3.) Refloatation of the body can occur rapidly under the right conditions. Tomita (1975 and 1976) studied the putrefaction and refloatation of both animal and human bodies underwater. His conclusions were that as ambient temperatures decrease, days until refloatation increase. So the colder the water the longer it takes for a body to reach the surface upon refloatation. According to his chart, a body in an aquatic environment of approximately 25° C. (77° F.) can reach the surface in about 5 - 7 days. Of course this rate depends on certain conditions and variables, however, his formula accounts for those such as temperature and depth.

4.) Once the body has refloated, differential decomposition occurs. The bloated body reaches the surface and the exposed portion becomes open territory for insect ovapositioning (Smith, 1986). Once hatched the larvae will begin to consume the soft tissue. The internal gases will escape and the body will sink for a second time.

5.) Upon this secondary submersion another stage of decomposition takes place. This is the focus of this thesis. For at this point in underwater decomposition a transformation occurs within the subcutaneous adipose

tissues. A process where the microscopic nature of the cellular components of the body become changed and reformed into a new tissue that has been called adipocere.

When the forensic scientist is presented with adipocere (adipo- : fat; -cere: waxy) the knowledge of this substance is usually vague and undefined. Although adipocere has been studied and researched since 1789 no real documentation of its transformation from beginning to end in a field context has ever been researched. This study takes on the responsibility of trying to solve the problem of understanding the factors involved in adipocere formation. The project has attempted to recreate adipocere formation in an aquatic environment where climatic conditions and environmental factors are close to normal (i.e., those that may be found in a field context). When looking at such research, the questions that need to be answered are: What is adipocere? How is it formed? How long does it take for it to form? Does it change throughout time? Where and why does it occur?

The questions, that relate to this study directly, which will be addressed are how long does adipocere take to form to completion and what conditions are conducive to its formation? This study attempts to answer these questions by focusing on human cadavers in an underwater decay research facility. By creating human adipocere in a somewhat controlled environment, rate and conditions may be measured. Thus, a means by which to qualify adipocere formation may be constructed.

Adipocere is a fatty, waxy substance comprised basically of highly saturated fatty acids. In a chemical process known as saponification, conversion into soap, the fatty acids are hydrolyzed by a water soluble mineral salt thus producing glycerol and three molecules of alkali salt of the fatty acid

(Mortimer, 1983). Literally the body's tissues transform into a cake of soap. When this new tissue remains firm and consistent at room temperature scientists (Ruttan and Marshall, 1917; Mant and Furbank, 1957; Evans, 1963) then call the substance adipocere and not just hydrolyzed fats. "The formation of adipocere is a process occurring under virtually anaerobic conditions in which human fat is converted into a complex of saturated fatty acids by a great variety of bacterial species occurring in and on the decomposing body" (Den Dooren De Jong, 1961: 361).

Previous studies that have focused on adipocere concentrated their efforts in analyzing what constitutes adipocere. Many papers have analyzed its chemical constituents and its microscopic properties (Ruttan and Marshall, 1917; Saito, 1966; Takatori, et. al., 1986 and 1987; Takatori and Yamaoka, 1977a, 1977b; Gotouda, et.al., 1988), and many projects have recreated it in the laboratory (Den Doren De Jong, 1961; Mellen, et. al., 1993); none to date have had the facility to do any such research on transformation of the subcutaneous tissue layer in human subjects from the early onset of saponification to the complete formation of adipocere. Most studies have been actualistic in nature and have recreated adipocere formation in non-human subjects (Payne and King, 1972; Tomita, 1984).

This study utilizes an area specifically designed to test human decomposition. An area designed for experimental studies has been constructed in Knoxville, Tennessee. Thus, all results are specific to that region and climate, however, the basic formula for transformation remains the same and variables present in different environments can be adjusted to suit the location of where an adipociferous body may be found.

This actualistic study used human cadavers immersed in an aquatic environment in order to simulate underwater decomposition. In this project the conditions essential for its formation are recreated (Mant and Furbank, 1957): presence of skin and human fatty tissue in an excess of moisture, warm, anaerobic environment with the presence of putrefactive bacteria (contra Glaister, 1950) which are conducive to adipocere formation. The site is located at the Anthropological Research Facility which is outside, open and partially wooded. The micro-organisms needed for the transformation are intrinsic to the cadavers.

The purpose of this research stems from the basic necessity for more comprehensible literature on the transformation of human soft tissue into adipocere and to answer the above-proposed questions. The current literature presents numerous articles and books written on the subject (Simonsen, 1977; Tomita, 1984; Cotton, et. al., 1987; Dix, 1987; Takatori, et. al., 1987; Mellen, et. al., 1993). None of them offer an adequate system at which to observe the qualification of the case material they have examined. This study allows for comparable measures to be taken in order to assess a more accurate portrayal of changes that occur during the post-mortem interval. The usefulness of the results from this research presents the Forensic scientist with verifiable results and thus can be interpreted when dealing with cases involving aquatic decay of human tissues.

In the process of underwater decomposition, many authors have researched the mechanisms involved in the patterns and rates of decay (Payne and King, 1972; Haglund, 1993; Tomita, 1975 and 1976). As there is a specific process by which all organisms decompose there is also a general course. Payne and King (1972) established the most effective means by which to

observe and measure the phases of decay in animal decomposition. Their system is outlined in six stages: submerged fresh, early floating, floating decay, bloated deterioration, floating remains, and sunken remains. The process was observed through experiments on fetal pig carcasses submerged in tanks of water. Measurements of water and air temperature were recorded as well as weight of the carcass measured at hourly intervals. The stages of decay were dependent on such factors as weather, age of the pig, mode of death, exposure, the observer, and even the species used.

Stage one, submerged fresh, is characterized by initially floating then sinking. As the body lay submerged the putrefactive bacterial actions cause gas to form and the internal cavities expand and bloat. Thus the creature floats to the surface. In warmer days during the summer bloating does not occur until about 1 to 2 days after submersion, however, in colder winter periods floatation might not occur until 2 to 3 weeks after deposition.

Stage two, early floating, is evident by the distended abdomen of the carcass exposed above the water surface. This exposure of soft-tissue leads to immediate insect ovapositioning. Blow flies and bottle flies (*Calliphora spp.*) find the body and deposit their eggs. In this stage, obvious odor is well pronounced.

Stage three, floating decay, begins with the hatching of the larvae. If any natural openings of the body (i.e., the nostrils, anus, mouth) are exposed maggots will enter through these portals. However, the intense feeding of the small insects creates many openings in the skin. The surface area of the exposed carcass diminishes as maggot activity increases.

Stage four, bloated deterioration, displays maggots and the predatory beetles being forced into the water due to the lack of exposed tissue. Maggots,

however, are able to continue feeding below the water line because they have spiracles (posterior ends) projecting above the water surface enabling them to breathe.

Stage five, floating remains, can last from 4 to 14 days depending on how long insect activity takes to devour the carcass. The floating body no longer has built-up gas trapped in any cavities, thus it begins to sink. When the carcass completely submerges stage five is finished.

Stage six, sunken remains, has decomposition of the soft tissue remaining being completed by bacteria and fungi. Maceration of the tissue occurs with only bones and tissue scattered across the bottom. As the tissues liquefy and putrefy they disintegrate and disarticulate from the skeletal remains allowing the bones to sink to the floor. The surface of the water is littered with the capsules of dead maggots and carrion fragments which are preyed upon by mosquito larvae and small flies. The process is now complete with all six stages terminated and the remains of the creature submerged in the water.

II. WHAT IS ADIPOCERE

In order to understand the nature of adipocere one must first comprehend basic histology and the cellular aspects of decomposition. The human skin is comprised of two main layers: the epidermis and the dermis. The epidermis is the surface layer of epithelial cells packed close together while the dermis is a deeper layer of dense, irregular connective tissue. In different areas around the body, fat is deposited in the loose connective tissue, forming adipose tissue. The area from the dermal layer to the adipose depots comprises the subcutaneous tissue. Adipose is essentially fat cells dispersed in loose connective tissue where within each cell's membrane a fat globule flattens the nucleus of the cell against the wall and the cytoplasm forms a thin ring surrounding the globule of fat (Spence and Mason, 1987).

Hierarchically fats are lipids; a subset of a lipid is a triglyceride; triglycerides are made up of glycerol and three fatty acids; fatty acids are an alkyl chain composed of carbon and hydrogen atoms. Most of the lipids in a cell are in the form of glyceryl esters and fatty acids. Those fatty acids most associated with adipocere formation are the following: Palmitic acid (Hexadecanoic acid; 16 carbon saturated fatty acid), Stearic acid (Octadecanoic acid; 18 carbon saturated fatty acid), Oleic acid (Octadecenoic acid; 18 carbon unsaturated fatty acid with a double bond between the ninth and tenth carbons). In general, human cells contain at least twice as many unsaturated fatty acids as saturated fatty acids (Montgomery, et al., 1977).

The cell contains a membrane constructed of glycerol, fatty acids, phospholipids and proteins. The cells are composed of a lipid bilayer acting as a cell membrane. The bilayer consists of fatty acids oriented in opposite

directions. One end is hydrophilic which directs itself toward the water while the other end is hydrophobic which points inward away from the water. This membrane maintains equilibrium within the cell through osmosis. If the cell is placed in a hypotonic solution then the cell wall will maintain osmotic equilibrium by taking in water and subsequently swelling. However, if the solution is hypertonic then the cell will shrink due to excessive water loss (McElroy, 1964).

The composition of adipocere as a chemical compound has been sought since 1789 when Fourcroy was the first to analyze the substance. The name was originated when he was commissioned to research the decomposition of interred bodies (Den Dooren De Jong, 1961). Fourcroy carried out investigations during the later half of the 18th century when bodies were being exhumed from the "Cimetiere des Innocents" in Paris. He described his findings on adipocere as: a homogenous, gray-white, friable substance without odor. The bodies discovered were not completely decomposed but had transformed into a fatty, waxy tissue; hence the term *adipocere* (French. *adipocire* < Latin.: *adeps*, fat + *cera*, wax). It was observed to occur most prevalently in the fatty regions of the body such as the cheeks or breasts. Also noted was the desiccation of the internal viscera. The different states of the compound were soft and wet in the fresh condition while it became dry and brittle in the aged stage. Applying quantitative tests on adipocere he concluded that the composition was an animal soap converted from the combination of fat with ammonia.

It was not until 1917 (Ruttan and Marshall) that a more comprehensive chemical analysis of this material was finally defined. Ruttan and Marshall obtained a sample of pig adipocere to analyze. Their substance was a hard,

white wax which appeared rather homogenous with fine strands of connective tissue being easily detected. In a preliminary qualitative analysis their results yielded the following components: ordinary saturated solid fatty acids, lime soap, insoluble fatty acids and connective tissue. Through quantitative studies they were able to isolate the ingredients (fatty acids, etc.) of the adipocere sample by ether extraction (see Table 1.)

Table 1: THE PERCENTAGE COMPOSITION OF HARD CLEAN ADIPOCERE WAX (Ruttan and Marshall, 1917: 326)

CONSTITUENT	%	CONSTITUENT	%
Palmitic acid	67.52	Unsaponified matter	0.87
Stearic acid	3.3	Calcium soaps	4.41
Oleic acid	5.24	Protein	0.665
Hydroxystearic acids	15.8	Ash	0.578
Stearin and palmitin	1.21	Humus and undetermined	0.247
Olein	0.16		

"It [adipocere] is composed almost entirely of the insoluble fatty acids left after the slow hydrolysis of the fats in wet ground. The protein matter has entirely disappeared and the glycerol, soaps, etc., resulting from the hydrolysis have been carried away in aqueous solution. The insoluble hydroxystearic acids which are so characteristic of adipocere are probably derived from a portion of the oleic acid in the original fat by hydration" (Ruttan and Marshall, 1917: 327).

Several Japanese chemists have completed further research on the chemical composition of adipocere. Saito (1966) states it consists mainly of

saturated fatty acids with a large amount of hydroxy fatty acids. Gotouda and colleagues (1988), have shown that 10-hydroxy and 10-oxo fatty acids are present in human adipocere but absent in the original adipose tissue, which led them to conclude that it was converted through bacterial enzymatic activity. By gas chromatography- mass spectrometry, Takatori and Yamaoka (1977a) identified the primary and secondary components as 10-hydroxyoctadecanoic [hydroxystearic] and 10-hydroxyhexadecanoic [hydroxypalmitic]. In a supplement to their 1977 research, Takatori and Yamaoka (1977b) offered more types of fatty acids found in human adipocere: 10-oxohexadecanoic acid and 10-oxo-octadecanoic acid.

III. HOW IS ADIPOCERE FORMED

Adipocere is "a postmortem chemical alteration of normal adipose tissue rendering it firm, grayish-white and of a wax-like consistency" (Cotton, et al., 1987:1128). "The formation of adipocere is a process occurring under virtually anaerobic conditions in which human fat is converted into a complex of saturated fatty acids by a great variety of bacterial species occurring in and on the decomposing body" (Den Dooren De Jong, 1961:361).

Two bodies that were discovered in a submerged automobile were positively identified, thus leading to a postmortem interval of five years (Cotton, et al., 1987). This discovery produced a sequencing of events leading up to the formation of adipocere. Their stages are as follows: 1) degradation of triglycerides of neutral fat is initiated by lipases; 2) postmortem putrefaction is initiated by growth of intestinal bacteria; 3) bacterial enzymes normally convert neutral fat into fatty acids; 4) other bacterial enzymes convert these fatty acids into hydroxy fatty acids (e.g., 10-hydroxystearic acid, where oleic acid is the source fatty acid and the bacterial species responsible for this conversion is *Clostridia perfringens* (*welchii*); 5) the hydroxy fatty acids have high melting points which allow for better stability to the adipocere; 6) some fatty acids are polymerized into dimers and oligomers; 7) the low pH (4.5-5.5) produced by the fatty acids stops bacterial growth and becomes a self-sterilizing process, arresting putrefaction and contributing to stability.

The phenomenon of adipocere formation is a chemical process known as saponification, or a conversion into soap (see Appendix B.). A soap is formed from a fatty acid and an alkali metal by the action of either a caustic alkali or a neutral oil or of a free fatty acid or carbonate (Davidsohn, et al,

1953). The fatty acids are hydrolyzed by a water soluble mineral salt thus yielding glycerol and three molecules of alkali salt of the fatty acid. "Adipocere, a variant of putrefaction, is brought about by the hydrolysis and hydrogenation of subcutaneous and other body fats" (Garland and Janaway, 1989: 23; see also Janssen, 1984; Polson, et. al., 1985). Fats may be degraded by two types of chemical reactions: hydrolysis and oxidation. The neutral fat (i.e., glycerol, lipids) is hydrolyzed to an extent by the body's own intrinsic lipases into the fatty acids such as oleic, palmitic and stearic acids. However, hydrolysis happens on a larger scale through the lipolytic enzymes produced by bacteria, specifically those of the *Clostridia* species (Garland and Janaway, 1989).

During internal decomposition, after autolysis of cellular structure has occurred the intestinal flora migrate through the vascular system as well as through the tissue system of the body. They are a brigade of aerobic bacteria ready to consume all elements blocking their attack. The neutral fat as well as muscle tissue is attacked by the bacteria. The micro-organisms secrete toxins which contain proteases and phopholipases which destroy the cell membrane. These digestive enzymes breach the integrity of the cell thus releasing its contents into the internal fluid environment of the body. Slowly the aerobic bacteria consume all the oxygen that has been released from this chemical activity. At this point the micro-organisms either sporulate into hibernation or die from lack of oxygen. When the anoxic environment has become suitable the anaerobic bacteria take their place and swarm across the body from the internal systems such as the gut and intestinal tract (Drasar and Hill, 1974). The anaerobic micro-organisms follow a similar path by destroying remaining cells through secretion of intrinsic lipases.

One particular genus of bacteria responsible for the internal decomposition is *Clostridium* with the major species being *perfringens* [*welchii*] (Mant and Furbank, 1957; Collee, et al, 1961; Corry, 1978). These putrefactive bacteria are degradative anaerobes and exist in the intestine and deep in the tissue where there is no oxygen. The presence of flagella allow them to be motile and travel throughout the system with ease. During times of unsuitable conditions the bacteria initiates a survival mechanism in which it sporulates and more or less hibernates until the ambiental conditions are habitable. The sporulation stage of the bacteria entails creating a thicker cell wall (personal communication, Dr. Dwayne Savage, Microbiology Department, University of Tennessee, Knoxville, 1993).

The neutral fat that is released contains the triglycerides composed of fatty acids and glycerol. The bacterial enzymes secreted from the *Clostridium perfringens* (*welchii*) attack the protein and convert the free fatty acids to hydroxy fatty acids. This conversion process is known as hydrolysis which is dependent on the presence of water. The fatty acids present before hydrolysis were essentially unsaturated oleic acids which are in a semi-liquid state within the vascular system as well as a partial solid state throughout the fat depots of the body. But now that they are free fatty acids separated from the glycerol backbone they are transformed into other shorter length carbon-chains. The glycerol is like candy for the bacteria and is rapidly consumed. However, as the amount of originally present oleic acid (Cramer and Brown, 1943) disappears [or is converted] the amount of palmitic acid increases (Den Dooren De Jong, 1961; Evans, 1963; Takatori and Yamaoka, 1977a and 1977b). The water for the hydrolyzation of the free fatty acids is derived primarily from the bodily tissues (Mant and Furbank, 1957). But as is the focus of this paper

another obvious source of water is from the external environment. As water from the bodily tissues is extracted and utilized the viscera take on a greatly shrunken state. In the same proportions the epidermis sloughs away and the dermal tissues become desiccated (Evans, 1963).

Bacteria continue to ingest the neutral fat and convert it into free fatty acids and eventually into saturated fatty acids by the action of hydrogenation (or the addition of hydrogen atoms). The remaining saturated components such as palmitic acid evolve into a hardened state thus creating a stabilized tissue (Wigner, 1940). At the same time, the anaerobic bacteria have consumed tissues rich in ammonia-producing contents and as a result have created an alkaline environment which is uninhabitable for an anaerobe. Thus, many of the micro-organisms die or sporulate. When the saturated fatty acids have hardened to a state of consistency similar to lard or "butter" (Den Dooren De Jong, 1961:361) and the bacteria have destroyed themselves the formation of adipocere is complete. This stage brings the process of putrefaction to a close (Den Dooren De Jong, 1961).

If the body still remains in an aquatic environment then the adipocere retains the sogginess and never gets a chance to actually become firm. If the body is recovered or floats to the surface or shore (O'Brien, 1993) then it gains a chance to dry. The tissues become desiccated and the adipociferous body takes on a yellowish-gray hue. A body which has undergone adipocere transformation may appear larger than ante mortem size due to the dermal tissues being converted to hardened, dense material. Adipocere has been described by various people as friable, caseous, homogenous, cheesy, crusty and feeling like wet leather. In this condition the body may be preserved for an indefinite period of time (Evans, 1962).

IV. WHERE AND WHY IS IT FORMED

Adipocere relies on a moist or damp environment to form. It may be as simple as a small creek bed or as grandiose as an ocean. Either way the saponification process will not commence without the essential criteria. As both Mant and Furbank (1957) and Evans (1963) will agree the basic necessities for the formation of adipocere to begin are: a moist or aquatic environment (complete or partial immersion), warm temperatures, intrinsic bacterial enzymatic action, and adipose tissue.

The process of adipocere formation has been described in the previous chapters as well as its morphological structure and chemical nature. In this chapter the environments which are conducive to its development are observed. To expose the reader to the variance in conducive environments case studies are presented in which the author was involved in some manner; whether through consultation or direct involvement.

Six case studies are noted with observations on the gross structure of what is believed to be adipocere:

CASE STUDIES:

CASE 1. A facility for defleshing animal remains at a Veterinary- Medical school is used when processing human remains that enter the Forensic Center at the University of Tennessee. A human cadaver was placed in early June into a boiling vat to simmer and was slowly defleshed. Over a period of a few days the soft-tissue disarticulated from the bone. Once the process was completed, however, the bones were accidentally left in the apparatus. The water level still covered the remains. They remained in this condition for

over two months. When opened in August, a curious sight appeared: the bones were covered with patchy areas of a white caseous material that was waxy to the touch. It could be scraped off with a fingernail because of its softness. Other areas of the bones not covered with this material were clean and dry. The bones appeared to be covered with adipocere. However, the question remains: was this actually adipocere?

This material might have been the transformation of the fatty tissue from within the medullary cavity (marrow) into adipocere or it might have simply been the loose liquefied fat floating in the water. As the level of the liquid lowered, the hydrolyzed fat and bodily fluids floating on the water surface possibly could have adhered to the bone surface and dried as the water level passed; thus leaving a waxy residue appearing white and caseous looking like adipocere. Can this substance still be classified as adipocere?

CASE 2. In April of 1992, an unclothed human body was discovered on the shore of Lake Ontario, near Oswego, New York. The remains were partially complete and the victim was in an advanced state of decomposition with partial skeletonization of limbs and skull (O'Brien, 1993). The thorax and abdomen were encased in a grayish-yellow soft-tissue that had a waxy texture. The tissue in the chest area and ventral portions of the legs had desiccated and demonstrated a crumbling caseous consistency. The crusty layer on the superior portion of the body as well as the damp, soggy waxy tissue on the posterior area of the body appeared to have the characteristics of adipocere. Again: is this adipocere? How can we tell from this body the rate of change to determine time since death?

CASE 3. A headless body was discovered at the base of a rocky bluff in eastern Tennessee in the late summer of 1993 (personal communication, Craig Lahren, University of Tennessee, Chatanooga, 1993). The body was clothed and in an advanced state of decay. A noose hanging from a tree atop the bluff was discovered which led to subsequent discovery of the cranium. Through positive identification of the decedent time since death was determined to be in the early summer. Thus the body had laid at the base of the bluff for possibly a little over two months.

Beneath the layer of clothing the soft-tissue in the thorax and abdomen regions had transformed into a moist, thick, dense, cheesy substance which facilitated the extraction of the hard-tissue. However, the tissue surrounding the appendages was mummified.

The remains were taken to a defleshing facility for processing. With water and detergent the bones were cleaned. But, when the skeletal material was lifted from the apparatus the spinal column, sacrum, shoulder girdles and ribs had completely disintegrated. Proper maintenance of processing and measurement of detergent were watched and no differences in technique from previous defleshings were noted. The observation was marked that where the adipocere had covered the skeleton those bones were the ones to disintegrate.

The question: was this really adipocere? and why did only the bones covered with this tissue disappear?

CASE 4. The body of an unknown white female was found in a river near Nashville, Tennessee and brought to the Medical Examiner for examination. She was discovered in good state of preservation with extensive formation of a waxy, caseous tissue in all regions of the body. The material was dry and

crumbling externally, but had more of a greasy consistency on the internal surfaces of the abdominal cavity. The broad areas of exposed flesh had a texture which could be termed as goose-pimply (cutis anserina). The hair follicles had apparently swelled and created a small upraised bump. This is typical in adipociferous bodies especially in parts of the body that are exposed. No clothing was evident with the body. The distal appendages had disarticulated. From the distal ends of the radius and ulna, all hand bones from the right side were absent. The right foot was missing as well. The body had been autopsied.

Question: is this tissue what most scientists classify as adipocere?

CASE 5. A study in which an attempt to simulate conditions for formation of adipocere tissue in an outdoor context was conducted by the author. Rabbits were used for their size and inexpensiveness as well as their convenience in a pilot study. Death was inflicted by electrocution to 15 rabbits.

In a secluded open area of a field, a fenced-in facility was created. Six rabbits were buried in moist, organic rich soil contained within a five gallon plastic bucket. Of those, three were covered with a plastic lid designed for sealing the bucket. The remaining three were exposed. The soil used for burial was highly organic and rich in minerals and trace elements due to the source: a horse pasture.

Eight more rabbits were submerged in water contained within similar five gallon buckets. Of these, four were covered and three were exposed. One of the covered buckets contained two rabbits. As a control one rabbit was placed on the ground for observations of uncontrolled decomposition.

Weekly observations of air and water temperatures and pH were recorded. But for all intents and purposes gross morphological changes were the primary observations recorded.

In the initial stages of immersion the rabbits did not sink. The buried rabbits were excavated during two week intervals. After a period of two months no adipocere had formed on any animal. Insect activity was a constant throughout the study and added to the differential decomposition of the floating remains. The water became a thick mass of organic liquids, decompositional fluids, deceased insect larvae and floating pieces of soft tissue. The chunks of flesh that remained after a period of two months were red, soft, liquefied lumps of tissue. When the excavated or underwater rabbit cadavers were dissected the internal muscle tissue still remained red in nature.

Adipocere must be solid at room temperature in order to be classified as such; these samples were in a rapid state of decay within the liquefaction stage. Adipocere had not formed in any of the rabbit bodies that had floated in water or under damp soil for the period of two months. In comparison to human decomposition this study has no relevance. Its purpose was as a pilot study to orient the author in variability of temperature and environmental conditions for use in a research project on human samples. However, certain elements presented options for use in a future study such as complete submersion and not to limit insect activity.

Even though the bodies were in an aqueous environment adipocere still did not form, why? At what point is adipocere actually said to occur and form?

CASE 6. A vehicle deposited at the Anthropological Research Facility was used for a study where rates of decomposition of cadavers in automobiles were

measured (personal communication, William Grant, University of Tennessee, Knoxville, 1994). A cadaver was removed from the trunk of a four door sedan which had been decomposing for a period of over two years. The superior portion of the supine-positioned body had desiccated completely. Hundreds of insect pupae littered the remains. A few live insects still remained burrowed beneath the flesh. Upon dissection of the body, the leathery skin from the top of the body was removed and the soft tissue from below the cadaver was exposed. The result of gravity had apparently pulled all the bodily fluids to the inferior section of the body and saturated the tissue. This created a gross morphological change in the tissue on the back and shoulder region of the cadaver. The transformed tissue had gained a consistency of a cheesy, damp, greasy material.

Question: if this material were allowed to sit at room temperature for an extended period of time would it harden to the point of where it could be classified as adipocere? Does the soggy consistency of fresh adipocere disappear as the water within the sample evaporates?

VARIABLES

One can see how difficult it is to correctly classify what *is* adipocere. It occurs in a variety of locations for a variety of reasons. But to answer the above-proposed questions one must analyze what variables could be present and which of them must be controlled if used in an experiment.

The previous case analyses leave many questions unanswered. Thus the potential for research is considered. The variables, in the study presented in this thesis, are quite limited due to time constraints and financial burdens. However, the ones that are measured may be used in a better understanding of

adipocere change. There are countless other variables present in the transformation of adipocere. Research stemming from these may take the forensic scientist years to complete, although, the profits will benefit the discipline greatly. Below is a brief outline of some of the variables that could be examined in further detail:

Staying within the narrow range of environments in which adipocere may form, the aquatic setting offers such conditions as temperature of the water (whether a colder environment is any different than a warmer one). The depth to which a body may sink, whether or not the body is affected by relative pressure from the external surroundings the deeper it is submerged. A body found in a stagnant pond or pool versus one discovered in a stream where water is constantly moving over the corpse may affect the rate of chemical changes within and on the body. A watery location like a swimming pool in which chlorine is prevalent may offer some different rate of change due to an increase or decrease in the pH of the pool water. Finally, a body which has been floating out at sea (i.e., salt water) for an extended period of time and eventually moves in towards shore to be discovered versus one that has been laying in a bathtub (i.e., fresh water) for the same time interval may be dramatically different in total transformation.

The variable of ambient conditions like the air provides more measurements to be aware of such as the temperature of the air or relative humidity. The body found at the base of a bluff (see Case Study 3.) was hanging in an external environment totally exposed to weather conditions. The cadaver was discovered totally encased in adipocere. Perhaps in this instance relative humidity identified from a local meteorological report might have been useful in establishing a post mortem interval. Evans (1963) also

noticed that bodies buried on days when there was fog or haze were more likely to develop adipocere than those buried on days of pleasant weather.

The actions of putrefactive bacteria as well as extrinsic bacteria on a decaying corpse speed up the rate of decay. However, many species are controlled by ambient temperatures and available food supply. Although, the bacterial flora of the human intestinal system find quite enough nutritive elements to feed upon in the submerged human body. This variable provides the bacteriologist/ forensic anthropologist with a means by which to study underwater decay and examine the bacteria that attack the cadaver; whether or not they originate from within the body cavity or externally.

Location may be the prime variable in adipocere formation. Because if a body is in too dry a location then it will mummify, however, if the conditions are too wet or the temperature is too hot then the body might simply liquefy. Although, location also means inside an apartment in a bathtub or out in a field in direct sunlight, in the woods covered by damp foliage or buried in a shallow grave along some roadside. All these positions allow for some decompositional process to occur. Adipocere may form in all or none, it is all contingent on the other variables mentioned.

Individual A is out boating on a lake and suffers a myocardial infarction and collapses into the water. Individual B is being forced down into his basement by an assailant, struck over the back of the head with a blunt instrument, and subsequently buried in the moist dirt beneath the freezer. Both individuals ended up in wet environments and both have the potential to develop extensive adipocere formation. However, no research has examined the effects of blunt trauma and subsequent loss of blood in comparison to the rate of adipocere. Could the loss of blood be a hindrance in the rate of change?

If Individual A had died and collapsed onto the deck of the boat instead of falling directly into the water first, then perhaps regular decompositional processes might have occurred. But say he then slips into the water after putrefaction has initiated, will adipocere begin to form?

While a body slowly rises to the surface (post-initial sinking) or lingers around beneath the water level (post-secondary sinking) there will inevitably be predatory action upon the body. Whether it be insect, animal or fish the process will occur and parts of the tissue will be extracted and dispersed across the floor of the aquatic environment. Some body parts and tissue will be consumed while others will disarticulate and sink to unknown depths or float away. Predatory action along with disarticulation through the action of water-currents may be the primary sources for body part loss on the adipociferous corpse.

Bodies disposed of in lakes, ponds or rivers are bound to be discovered. They float to the surface or are dislodged through current activity and predatory action. Either way they are usually not intended to be discovered. Some perpetrators prefer to wrap up their victims in rope, plastic and blankets then weight them down with heavy objects such as concrete blocks and battery cables or a barbecue grill, and a tire wheel (Dix, 1987). Whatever the conditions of disposal, the body will be forced to remain in the watery grave for an extended period of time more than what the normal time lapse might be. In this scenario adipocere would gain a stronger foothold in formation before refloatation.

A body which is protected from the elements through the use of clothing may or may not be affective in the rate of adipocere formation,

however, the literature suggests that clothing tends to promote adipocerization in human bodies (Mant and Furbank 1957; Evans 1963).

Then there is the personal nature of the decedent. The variables of age, sex or race may present themselves in different contexts yet always entail some analysis. Theoretically speaking a fetus or small child would most likely form adipocere quicker than an adolescent because of the presence of "baby-fat". Also, a female should have the potential to form more adipocere in her body than a male simply for the mere fact that she has more adipose depots than her male counterpart. In regards to ethnic identity and its relation to adipocere formation, this has yet to be studied.

The variables have been shown to be quite extensive for adipocere development. If its formation is to be complete then all must be tested. For scientific endeavors, future research may pursue these. But for the project completed in this thesis the variables were not so scientifically tested but rather more of observational recordings of gross morphological changes in adipocere development in a human cadaver in an aquatic environment. In the chapter outlining the results obtained from this study, one shall understand more the significance and findings of this research.

V. MATERIALS AND METHODS

Human subjects were used in this research. Samples of non-human fatty tissue could have been used because of its unique similarity to human adipose tissue (Payne and King, 1972), however, access to human cadavers facilitated the actualism of the results. Due to the nature of adipocere formation, full cadavers were essential for reproduction of underwater decompositional events.

Three adult human cadavers were used in this project. All bodies had been stored in a morgue cooler for a period of about three months. The first body was an adult white male who weighed approximately 188 pounds and stood 70 inches. Following a twenty foot fall he was brought to the hospital where he was pronounced dead upon arrival. The decedent had apparently died from multiple blunt traumatic injuries sustained from the fall, thus, he was not autopsied. He had extensive open trauma to the head region where he probably landed. Mold and mildew had accumulated around the neck and trauma-affected area of the head. Multiple peri-mortem bruises were located in various sites on the body.

The second body was an adult white male who weighed approximately 173 pounds and stood 68 inches. The decedent died from a self-inflicted gunshot wound to the head. Open trauma was present in the left lateral and posterior cranial region. No other trauma or pathology was noted in the cadaver; the decedent had not been autopsied. Upon arrival to the site, the body was partially bloated .

The third body was an adult, black male who weighed approximately 220 pounds and stood 69 inches. The body had no trauma or pathology and had not

been autopsied. Cause or manner of death was not indicated on the records received by the University of Tennessee (UT) Forensic Anthropology Center.

The cadavers were acquired from the State Medical Examiner Office in Nashville, Tennessee. The subjects had either donated their bodies to the UT Department of Anthropology for research concerning scientific endeavors or been unclaimed. Bodies that remain unidentified or not claimed by next of kin remain in the morgue for a limited time period. If not recovered by the time the limit has expired then they are donated to the UT Forensic Anthropology Center. The cadavers are utilized in ongoing research at a specific site (described below) for such endeavors. All pertinent data, such as: age, gender, ethnic identity, stature and weight were observed and recorded by the Medical Examiner staff.

Studies were conducted at the Anthropological Research Facility. It is located in a partially wooded area in Knoxville, Tennessee. The Facility is enclosed by a chain-link wire fence topped with razor wire for security purposes. Also, within six feet of the chain-link fence is a wooden privacy fence for added security. The specific area chosen for this study was a level portion of ground near a water source. The source of the water is a pipeline that enters the Facility underground and exits through an above-ground faucet. The water originates from the Knoxville Water Treatment Plant (see Appendix A for water quality analysis).

Three holes measuring approximately 8' x 4' x 4' were excavated using a back hoe. The holes are separated by approximately two or more feet. The three holes are labeled Hole 1, 2 and 3. Hole 1 and Hole 2 are in use as the experimental scenario while Hole 3 is utilized as the control of the study. Holes 1 and 2 are lined with polyethylene clear plastic.

Hole 1 was excavated shallow for the mere reason that the quantity of large rocks and boulders present below the Facility's topsoil prevented further depth being achieved. Its measurements are as follows: Length = 7' 10"; Width = 4' 4"; Height (to ground level) = 3'. For this hole the addition of vertical support is necessary to achieve a 4' deep hole. Concrete blocks with wooden planks are constructed together to form a frame over which the plastic is hung. This vertical wall around the hole measures 1' 6" above ground level making the entire depth of the hole 4' 6" (see Figure 2.).

Hole 2 was excavated shallow in places because of penetrating bedrock and exposed boulders too large to move. If they had been excavated their removal might have destroyed the integrity of the hole. Its measurements are as follows: Length = 8' 6"; Width = 4'; Height (to ground level) = 3' 6". Again vertical support is maintained by wooden planks and concrete blocks totaling a vertical height of 10"; thus the entire depth of the hole measures 4' 4" (see Figure 3.).

Hole 3 was used as a control for this study in order to see what effect the absence of plastic would have on decomposition. The consistency of the soil's context is primarily clay. In a preliminary test of the hole's water holding capacity, water was placed into the hole for a period of a week. After the test period the water level remained constant. The clay's ability to retain water presented itself as an adequate environment to test the formation of adipocere in a context without plastic. The measurements of Hole 3 are as follows: Length = 9'; Width (at floor) = 3', Width (at ground level) = 5'; Height = 4' (see Figure 4.).

A doubled sheet of clear, polyethylene plastic measuring 6 millimeters thick (single sheet thickness = 3 mm.) lined the internal contours of Hole 1 and

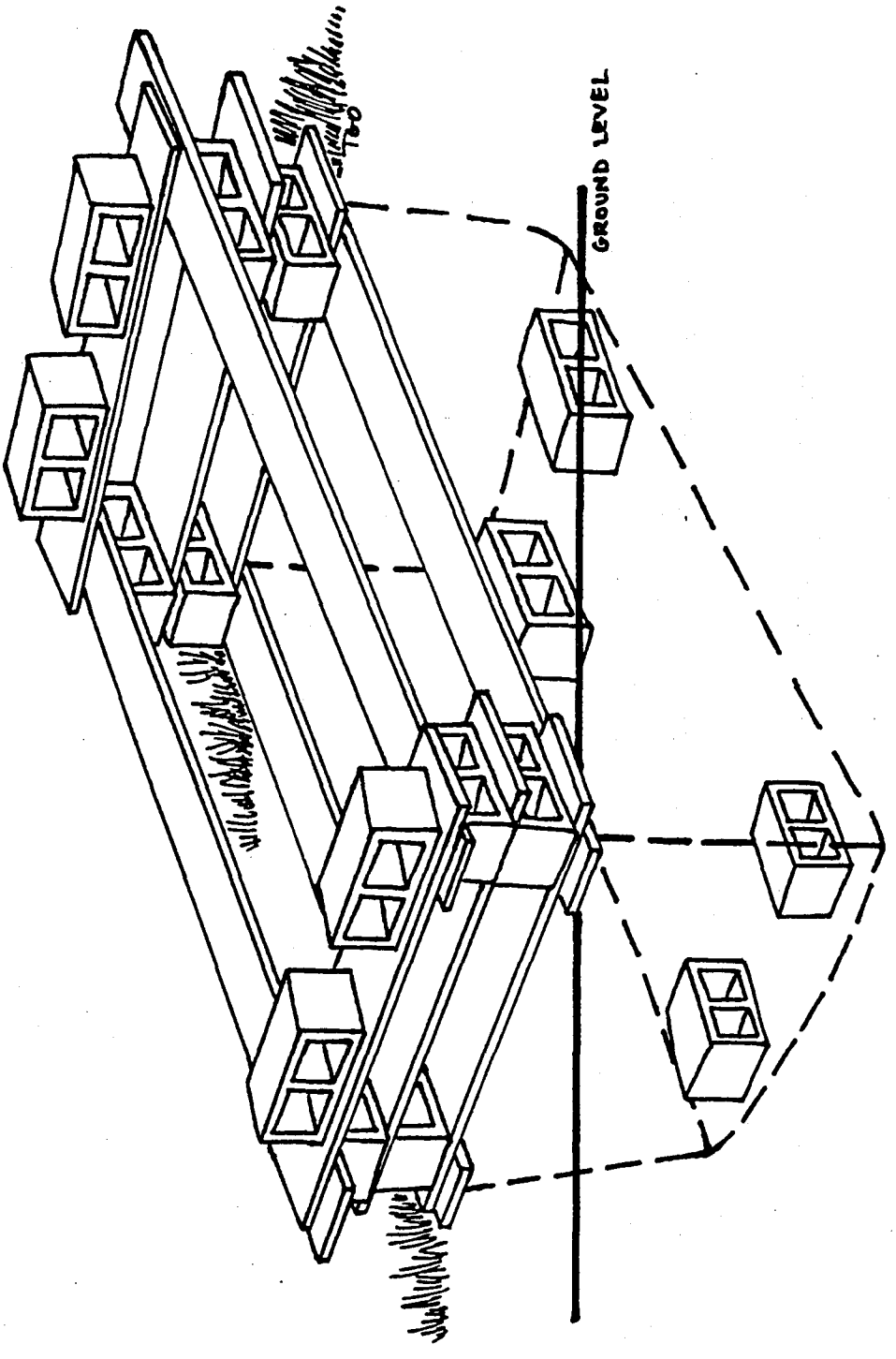

Figure 2. Schematic for Hole 1 without polyethylene plastic (drawing not to scale)

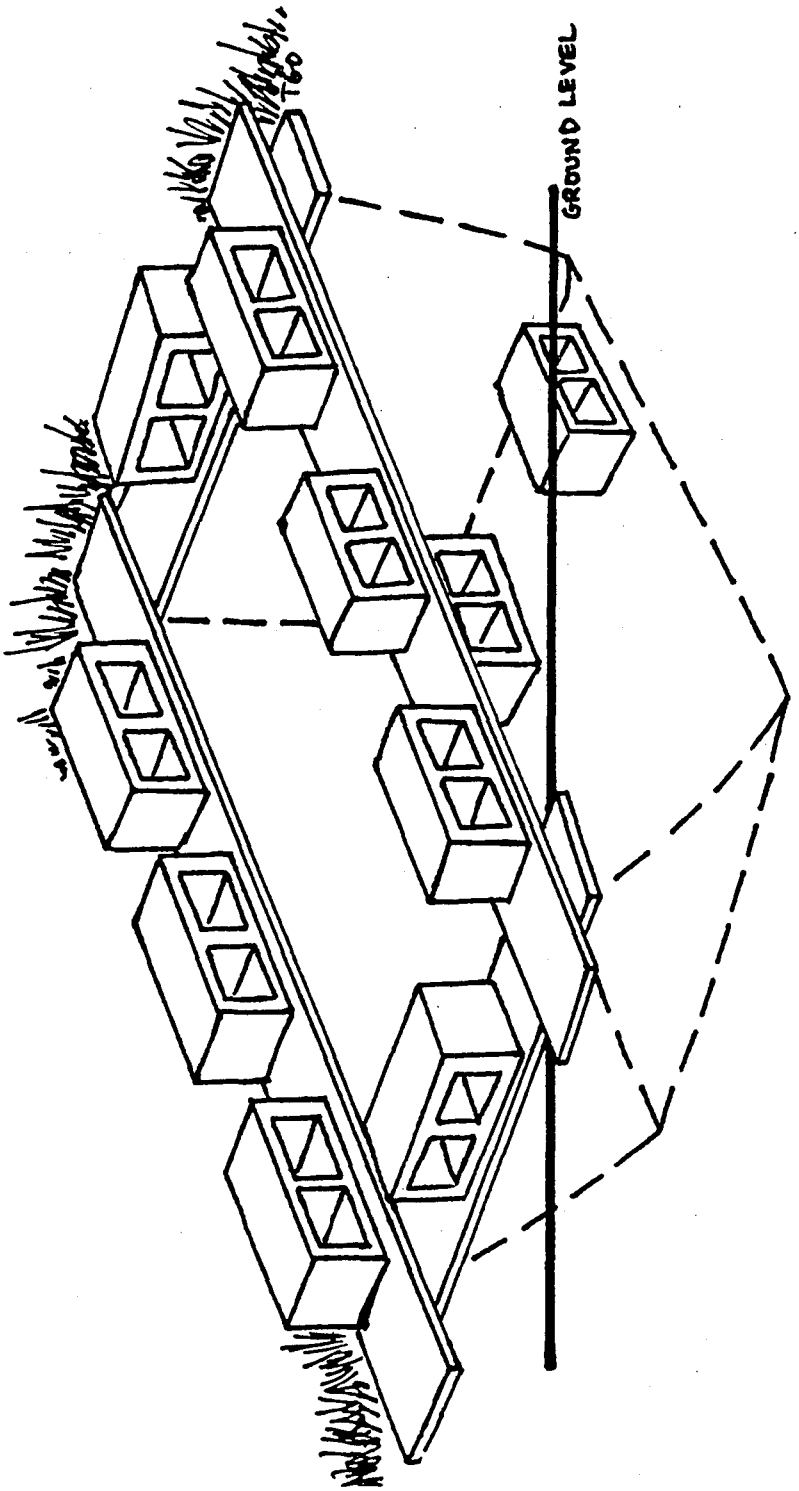

Figure 3. Schematic for Hole 2 without polyethylene plastic (drawing not to scale)

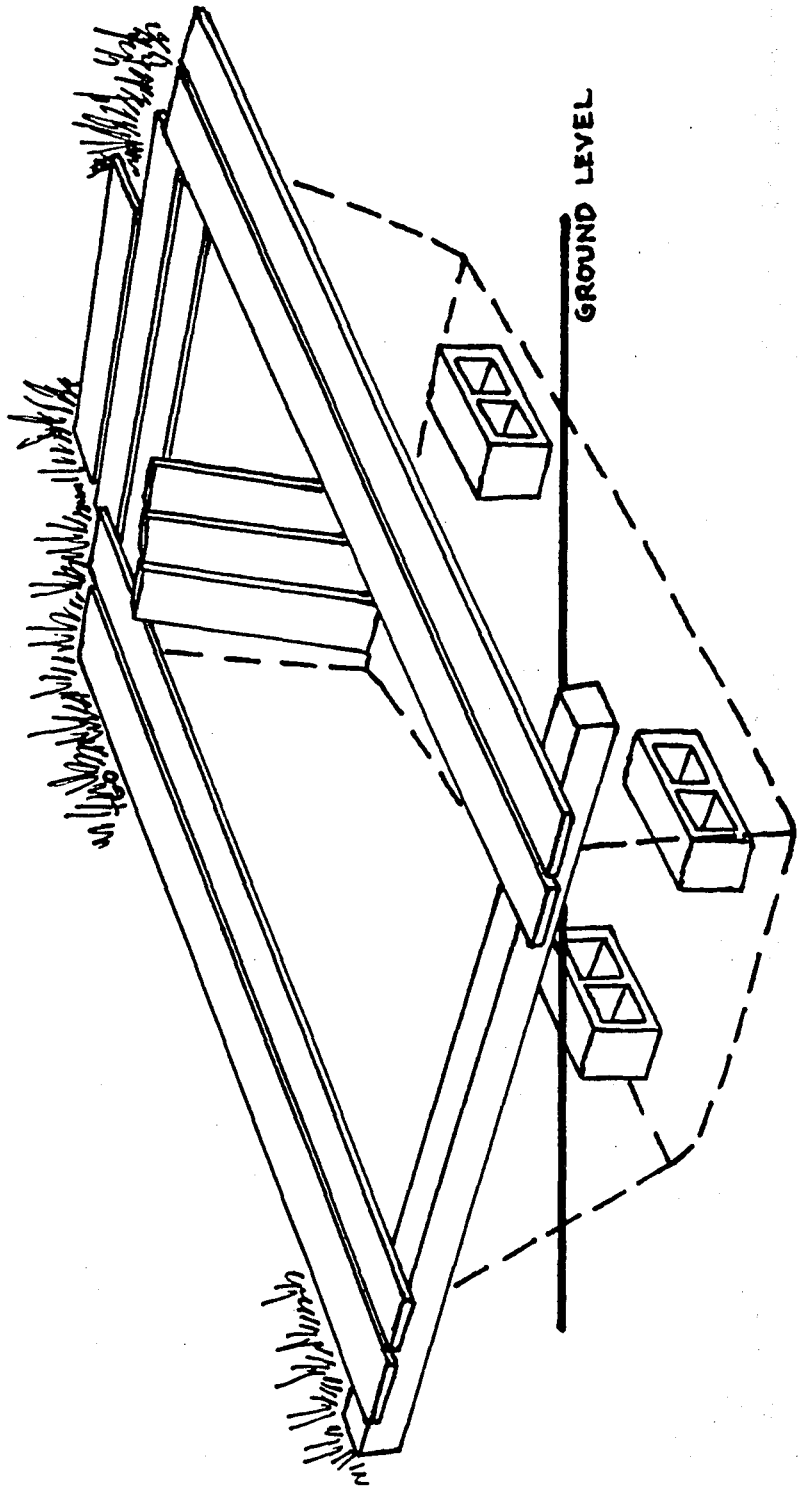

Figure 4. Schematic for Hole 3 without polyethylene plastic (drawing not to scale)

2 making them impervious to the escape of water. The plastic is weighted down around the edge of the hole with the excavated dirt as well as wooden planks and concrete blocks. Inside each hole on top of the plastic are four 20-pound concrete blocks for support of the body trays. In some instances, corners of some holes have exposed rocks which lend extra support (Holes 2 and 3). But all three holes have at least two blocks in each. The concrete blocks that are used measure: Length = 16"; Width = 8"; Height = 8".

Support trays for the cadavers are made from wood and wire fencing (see Figure 5). Three trays were constructed. The following description is for all three. The tray frame is constructed of non-treated pine wall studs (2" x 4") and held together by 16-penny nails. All cutting was done by an electric radial hand saw. Two boards measuring 5' 11 3/4" form the length of the tray while two boards measuring 3' cap the ends. The wire fencing used is 36" utility wire fencing and it was attached to the tray frame by 2" roofing nails. A length of fence measuring 78" is nailed to the tray frame and secured by corner braces made from the wall studs. The wire fence is nailed down the length of the frame with the roofing nails. Extra bracing is made possible by adding two cross beam wall studs measuring 36" placed 22" from either end. When the tray is placed correctly it is supported by the corner braces and the cross beams which act as "legs". The final measurements of each tray are as follows: Length = 6'; Width = 3' 4"; Maximum Height = 6". In order for easier access, to observe and document changes, lengths of rope are attached at each corner and draped outside of the hole for facilitating retrieval.

Preparation of the cadavers entailed stripping them of all clothing and jewelry prior to placement. This preparatory method was completed at the Medical Examiner's Office. Upon arrival at the Facility the body bags

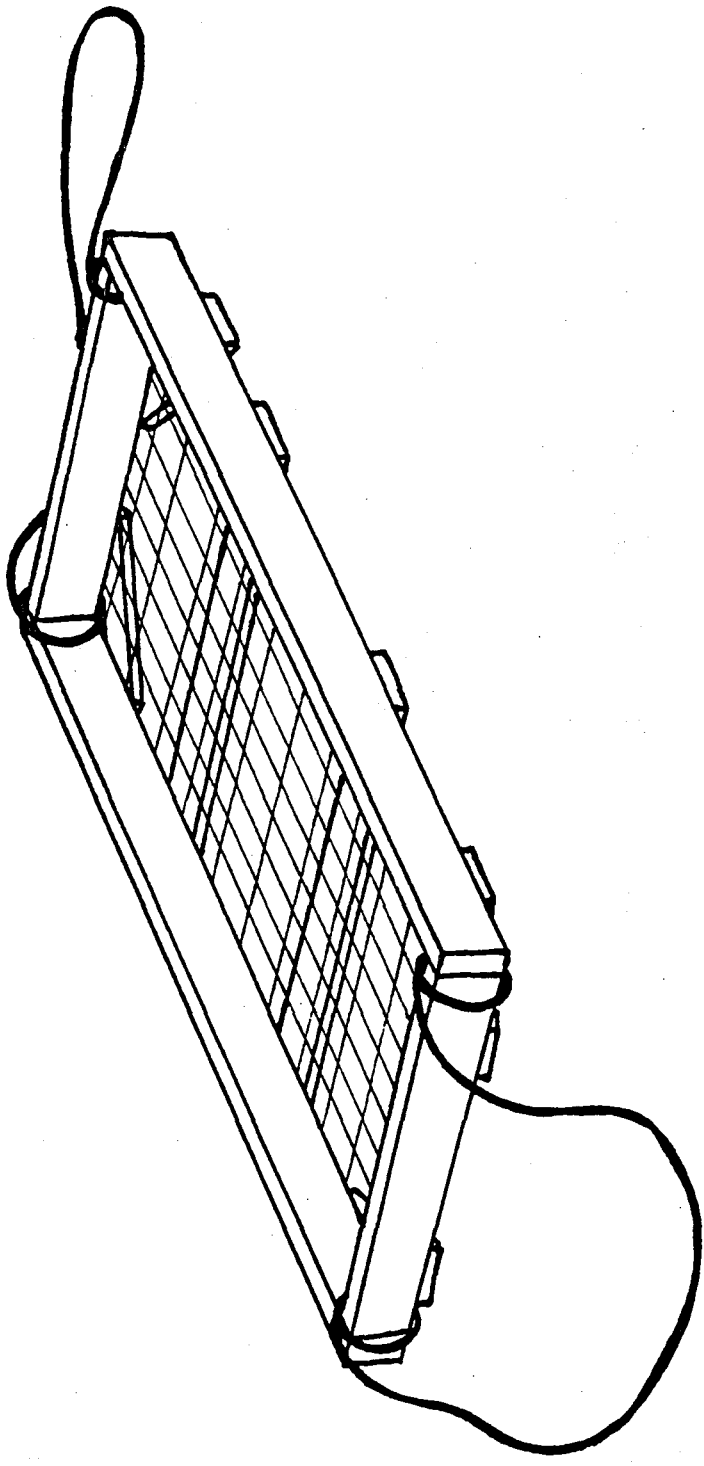

Figure 5. Schematic for tray used in retrieval of cadaver (drawing not to scale)

containing the cadavers were opened one at a time. Each cadaver was placed on each tray in a supine position with the arms to the side and legs were slightly spread apart. The trays were then lifted and lowered into their respective holes. A common garden hose was attached to the faucet and used to fill each hole prior to immersion. Total submersion of the cadavers entailed filling the water level to four feet from the floor of the hole. Water depth for Hole 1 came to a point approximately six inches above ground level; Hole 2 came up to ground level; Hole 3 had a water level reaching about seven inches below ground level.

Initial observations of the cadavers for external trauma or pathology were conducted prior to submersion. Upon lowering the cadavers photographs were taken with an Asahi Pentax K1000 camera with a SMC Pentax-A 1:2 50 mm. lens and Kodak Ektachrome Elite 200 35 mm. Daylight film for color slides. Climatic conditions were observed and documented (i.e. temperature, cloud cover, etc.). Water temperature was measured for each hole with a Universal Enterprises T220 Fahrenheit Food Thermometer.

In the initial stages of decomposition observations were made three times a week in order to record drop in water level as well as take measurements of water temperature and note decay rate. Added examination included photographing the cadavers in the water and partially exposed. In order to examine the body without aquatic distortion the tray was lifted out of the water from the head end, using the ropes tied to the corners of the tray, and supported by an assistant. With this procedure the cadaver could be exposed from the mid-abdominal region and up. Photographs were taken to record gross morphological changes. Temperature was recorded to mark environmental changes.

VI. RESULTS

After submersion of the cadavers in the holes, the three bodies acted rather differently. The cadavers will be named by the hole they occupy (e.g., cadaver one is in hole 1 thus it will be named Hole 1).

PRE-IMMERSION:

Hole 1 had external trauma from the lateral to frontal aspect of the head. The body was not autopsied. The skin was bruised and started to slip. The soles and the palms were extremely wrinkled. The neck and upper torso were moldy and pock-marked.

Hole 2 had external trauma to the posterior aspect of the head. The body was not autopsied. The abdomen was slightly bloated with skin slippage present on the hands and feet. The soles and palms were extremely wrinkled. The body had already progressed into the early stages of putrefaction with minimal bloating.

Hole 3 was in a good physical state with no apparent trauma. The body was not autopsied. The palms and soles were extremely wrinkled with minimal peeling of the outer layers of tissue. The body had already progressed into the early stages of putrefaction with minimal bloating.

PERI-IMMERSION:

Hole 1 became totally submerged within thirty minutes after immersion.

Hole 2 remained floating after immersion. The cadaver floated on the surface of the water with exposure of the anterior portions of the thighs, anterior portions of the upper arm, abdomen, thorax, anterior portion of the

neck, and the head from about the level of the posterior aspect of the jaw and ear.

Hole 3 remained floating after immersion, yet slightly lower than Hole 2. The only exposed portions of the body were the face, anterior portions of the shoulders, upper arms and thighs, and the "belly" portion of the abdomen.

POST-IMMERSION:

FIRST WEEK Hole 1 was unremarkable and unchanged. Hole 2 and Hole 3 had not submerged. All holes had an accumulation of organic material due to the dropping foliage.

SECOND WEEK Hole 1 had a softening of the flesh and the water was visibly turbid. When raised to surface level a penetrating and pungent odor of decay was quite apparent.

Hole 2 was floating and had noticeable effects of putrefaction. The lateral aspects of the body had become exposed due to both bloating and a small loss of water from the hole. The belly had distended and the scrotum and penis were quite swollen. The body showed more discoloration than was evident during initial immersion. Red and dark purple hues were evident. Insect activity (i.e., flies) was evident in the oral and nasal cavities. The soles and palms became much more wrinkled and started to peel. When the mouth was opened to observe dentition a red, viscous liquid seeped out.

Hole 3 was covered with a thin layer of sediment that had accumulated from the particulates in the water during immersion. Between the dried, cracked areas of the sediment on the abdomen green hues could be noted on the skin. A red liquid also seeped out of the oral cavity upon inspection of the dentition. The hands and feet were still wrinkled.

THIRD WEEK Hole 1 had not floated; upon raising to the surface, the emittance of a strong, decaying odor was noted; a smell similar to putrid fecal matter.

Hole 2 remained floating and putrefaction had continued. The discolored areas of redness on the arms and neck intensified. The areas resembled bruising and were apparent on the upper thighs.

Hole 3 had puddles of a thin, oily film covering the water around the body. The water was thicker and more dense. Also along the exposed contours of the body was a whitish, milky, oily film. When the floating oily puddles were disrupted they remained clinging to other particles in the mass. Odor was present in all holes.

FOURTH WEEK Hole 1 remained submerged. It has a slightly opaque film collecting among the leaves littering the surface of the water.

Hole 2 remained floating. The discoloration on the exposed tissue surface had transformed into patchy, moldy clusters of brown fungal growth. The hands and feet remained wrinkled and peeling. Insect activity (ovapositioning) was noted around the genital region. Beetles were present crawling over the exposed torso.

Hole 3 remained floating. Tissue decay was remarkable. Slight insect activity was noted but with no visible ovapositioning. The water increased in cloudiness to the point of almost total opacity. A thicker film built up on the surface and was viscous to the touch (like the film that forms on the surface of hot gravy when allowed to sit). Leaf foliage littered the surface.

FIFTH WEEK Hole 1 was still submerged. A remarkable change in the surface water occurred. A thin, opaque film formed on the surface. It was a green, slimy algal growth that had both living and dead insects trapped in it.

In Hole 2, the skin from the underside of the body on the back started to slough off in large segments, however, without disarticulation. The skin around the water level, above and below, became wrinkled and thickened. The color of the body closer to the water level turned from the original body tone to a pale yellow color. A loss of color was noted; although the most exterior portions of the skin (i.e., upper chest, lower abdomen, and upper thighs) became a darker red and brown. The tissue above the water level became crusty and hardened or mummified. An incredible maggot infestation was observed around the upper neck and facial regions. The maggots appeared lethargic but continued to feed. Bubbles of flesh were observed with writhing masses of maggots beneath the skin. The beetles were absent. The decomposing fluid along with the sloughing tissue particles collected to form a scum along the top of the water.

Hole 3 was bloated considerably and floated high in the water. The abdomen was quite distended. There was a slight discoloration of the body with patches of lighter colors; a noted loss of color. There were few to no insects observed on the body. A slimy mat of algal matter appearing oily and thick, covered the water surface.

SIXTH WEEK Hole 1 was unremarkable and still remained submerged but the water had a dense consistency with much particulate matter.

Hole 2 was floating. The previously darkened regions of the body above the water became lighter in color. The brown fungal growth had changed in

color to a paler hue. The zone of tissue approximately two to three inches above and below the water level ("water-level zone") became wrinkled and warped. The skin was yellowish-white with a 'goose-pimply' texture (cutis anserina) on the surface. This texture was also noted on the exposed shoulder and upper thigh regions. The internal aspect of the oral cavity was decaying because of the intense insect infestation. The mouth and lips, with numerous maggots present, had flared open dramatically. Other facial regions which were exposed or under water remained unaffected.

Hole 3 had made no remarkable change in general but appeared distinctly lighter in skin color. A small area on the right arm near the elbow displayed evidence of the 'goose-pimply' flesh texture (cutis anserina).

SEVENTH WEEK Upon raising the body to the surface, Hole 1 was green and slime-ridden. The body was still corpulent. It was not bloated nor decomposing drastically. The tissue was soft, wet and soggy. The anterior portion of the body was plastered in a green, algal mat. The algal growth covered the walls of the plastic lining the hole. The pungent odor of decay was still present.

Hole 2 was drying and the body was floating. The color had become more yellow on the lateral portions of the body. The skin appeared to be more wrinkled and rippled in the zone above and below the water. The tissue of the hands and feet were still wrinkled and peeling. The chest and lower abdomen dried and displayed pockets of brown and orange mold and mildew. The mouth remained flared although many of the maggots seemed to be migrating away from the body. Maggots were observed in the water.

Hole 3 had no remarkable change.

Precipitation in the form of rain had fallen for the past two weeks intermittently, but strong at times (to the point of torrential downpour). The effects of the rain on the holes was varied. The rain disturbed the algal growth and washed away some of the moldy encrustations.

EIGHTH WEEK Hole 1 remained submerged. There is an opacity to the water and no remarkable changes to the corpulency of the body itself.

Hole 2 was still floating. The penis and scrotum were deflated. The abdomen was no longer distended but rather deflated. The exposed tissue was mummifying. The extremities became light colored with hues of yellow and whitish-gray. Gross changes which occurred were within the "water-level zone". The tissue appeared warped and crumpled around the abdominal regions, waist, and shoulders. Remaining maggots still worked in the oral cavity even though it was below water level.

Hole 3 continued to mummify without remarkable desiccation. The body was discolored and patchy with hues of light brown and tan as well as hints of beige. A thin film remained on the surface of the water.

NINTH WEEK Hole 1 had no remarkable changes and remained submerged. Hole 2 still had some maggot activity and no apparent changes or decay of the tissue.

Hole 3 had no remarkable changes. Holes 2 and 3 remained floating.

TENTH WEEK Hole 1 had no remarkable changes and remained submerged. Hole 2 remained unchanged in general form or structure. However, a new colored bright orange, moldy growth had appeared on the chest cavity of the body.

Hole 3 remained floating and deflated.

ELEVENTH WEEK Hole 1 had no remarkable changes and remained submerged. Hole 2 remained unchanged in general form or structure. The body had lowered slightly in the water yet remained floating. The orange mold-mildew spread across the chest cavity and down the upper shoulders and upper thighs.

Hole 3 remained floating and deflated.

TWELFTH WEEK Hole 1 had no remarkable changes and remained submerged. Within the "water-level zone", Hole 2 remained wrinkled and warped with an outer border of 'goose-pimply' flesh (cutis anserina). The cadaver remained covered with the orange mold-mildew growth and patched in brown, decomposed, mummified flesh encrusting the area on the top of the cadaver.

Hole 3 remained floating and deflated. Certain areas of the arms and upper thighs appeared wrinkled and slightly 'goose-pimply' (cutis anserina).

Even after a period of three months Hole 1 refused to rise to the surface. In the final stages of observation, the body appeared soggy and covered in algal matter while the other two holes displayed a yellowish-white caseous material encasing the body. The resulting tissue that had formed on Hole 2 and 3 exhibited the characteristics typical in adipociferous bodies found in natural aquatic contexts. At the end of a three month observational period the bodies of two of the three, human, male cadavers had decomposed to the state where tissue similar to adipocere had occurred.

The countless number of variables that could have been observed and measured were too extensive for a project with both time constraints and financial burdens. Thus, observations and measurements were limited to recording water and air temperature. Each was recorded in Fahrenheit every

other day for the first month and a half. When the changes in biomorphology slowed, observations were taken two to three times a week. The initial day of observation and immersion was on October 20, 1993. The final day of observation was January 22, 1994, a period of approximately three months. All measurements were recorded and synthesized into TABLE 2. and graphed in Figure 6.

Table 2. TEMPERATURE MEASUREMENTS FOR AIR AND WATER

DATE	WATER TEMP HOLE (F.°)	AIR TEMP HOLE (F.°)	AIR TEMP NOAA (F.°)
10/ 20	64	70	72
10/ 22	59	59	54
10/ 24	58	64	55
10/ 27	58	60	57
10/ 29	57	51	44
11/ 01	48	40	40
11/ 04	50	52	52
11/ 09	43	24	38
11/ 12	51	58	47
11/ 13	55	75	60
11/ 15	55	75	66
11/ 17	58	65	62
11/ 22	49	47	44
11/ 28	46	47	40
12/ 01	44	46	42
12/ 04	49	50	52
12/ 08	43	45	47
12/ 13	40	41	38
12/ 21	40	39	34
01/ 08	37	33	26
01/ 13	40	42	42
01/ 22	32	35	25

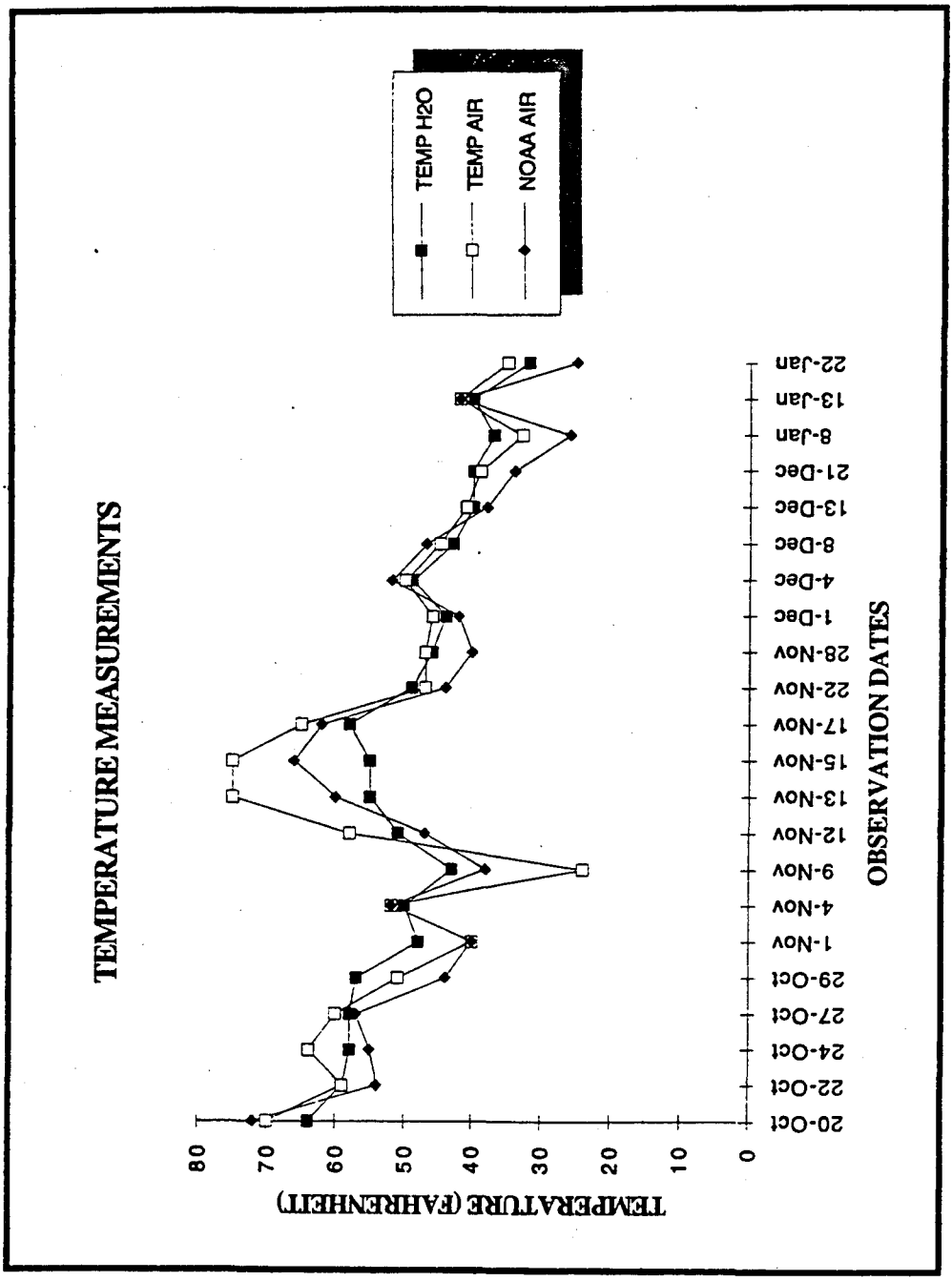

Figure 6. Graph of Temperature Measurements from October 20, 1993 to January 22, 1994 displaying air and water temperatures against air temperatures from the National Atmospheric and Space Administration (NOAA)

On three occasions throughout the experiment liquid samples were extracted from the cadavers for analysis. Extraction entailed using a Bector-Davidson 10 cc. syringe accompanying a Bector-Davidson 18G 1/2 Precision Glide Needle. The three time intervals at which samples were taken were: five weeks (11/28), nine weeks (12/24), and twelve weeks (01/13) after initial immersion. These samples, including both liquid and soft-tissue, were analyzed by the University of Tennessee Center for Environmental Biotechnology. Free fatty acid content and polar lipid fatty acid profiles were produced. The two procedures were conducted in order to determine the amount of free fatty acid conversion from oleic to palmitic acid, and the bacterial population associated with each cadaver. (Ruttan and Marshall, 1917; Cotton, et. al., 1987; Gotouda, et. al., 1988)

METHODOLOGY

Each sample was subjected to a Bligh and Dyer (B&D) extraction. This involves the use of organic solvents in order to recover extractable lipid components from the samples. A B&D extraction consists of chloroform and methanol (1:2, v:v) which was modified to include a phosphate buffer. After the initial extraction, phases were split by the addition of chloroform and water (1:1, v:v). The residue was put through an acid hydrolysis releasing hydroxy fatty acids. The extractable lipids were placed on a silicic acid column and subsequently separated into three classes: by elution with chloroform, neutral lipids were recovered; elution with acetone, the glycolipids were recovered; and with the elution of methanol, the polar lipids were recovered.

The neutral lipids contain such items as steroids, hydrocarbons, diglycerides, triglycerides and free fatty acids. By utilizing thin layer

chromatography the free fatty acids were isolated and analyzed. The polar lipids were further separated and quantified by gas chromatography after the formation of methyl esters in a mild alkali methanolic solution.

VII. DISCUSSION AND CONCLUSIONS

A period of three months has passed since initial immersion. The progressional stages of gross morphological and microbial/ bacterial development are apparent. To begin this chapter, a review of the original questions intended to be answered shall be presented.

The first question was What is adipocere? A chapter was devoted to the explanation that adipocere is a chemically altered state of human adipose soft tissue. The matter is saponified into a thick, waxy, caseous material resembling soap.

The second question posed was How is it formed? The process, as just mentioned, is called saponification where the fatty acids of the adipose cells are hydrolyzed. An adipociferous body is transformed with the direct involvement of water or moisture. Where and why it is formed was answered by explaining the variability and numerous factors and conditions that could or should be present during adipocere formation. The case studies presented a list of the different forms it may take and that it assumes many states but still is classified as adipocere. The point of this project was to lend more credence to what adipocere actually is and offer an easy system for recognizing the typical characteristics found in adipociferous bodies. The explanations taken from the literature offer case studies and research to compare against, however, with this study one can see a direct progression of adipocere transformation documented through gross morphological change. The chemistry of the process has been briefly analyzed and conclusions have been drawn from the chemical analysis of the samples extracted. These will be discussed later.

In looking at the progression of decay in the three cadavers, remarkable situations occurred in all three bodies. A synopsis shall be presented synthesizing all transformations:

HOLE 1 The body in this hole did not perform as expected. Upon immersion it submerged, but remained in this underwater state for the extent of the project. At different time intervals throughout the study it was raised to the surface for observational purposes. The abdomen had not bloated nor had it progressed through expected decompositional stages (Knight, 1991). By the last date of observation (January 22) no remarkable changes had occurred relating any transformation of soft tissue to a nature or state resembling typical adipocere formation. The body's tissues were slowly macerating. A progression was noted of algal growth. Each successive raising displayed a thicker mat of green algae that had collected/ grown on the decomposing body.

HOLE 2 The body in this hole made the most remarkable changes of any of the three cadavers. The body remained floating for the extent of the project, an unexpected variable. In this position, the body was subjected to differential decomposition. A progression of normal decompositional processes occurred. The initial stages of bloating, with subsequent insect ovapositioning was followed by maggot activity, tissue decay and sloughing of epidermis. Since a major portion of the cadaver was exposed above the "water-level zone", this area allowed ample breeding grounds for fungal growth. Observations recorded a progression of different colored growths upon the superior surface of the chest and abdomen. The most notable was the bright orange growth which spotted the cadaver's shoulders and chest. This fungus most likely falls within the taxonomic nomenclature of *Fusarium spp.* (Larone,

1987; Barnett and Hunter, 1987; Bulmer, 1991). This genus is wide and diverse. It typically forms a cotton-like culture with a tinge of yellow. It is commonly considered more as a contaminant; occasionally involved in skin and nail infections and systemic infections in severely debilitated hosts (Larone, 1987:147). It has a rapid rate of growth becoming mature in four days, although, on the cadaver it was noted after ten weeks. In microscopic analysis it displayed the typical multiseptated, canoe-shaped sporulated stage. Thus, indicating that conditions had become unsuitable. This situation, of sporulated microbial organisms, suggests highly that the conditions for growth had become inhospitable on the decomposing body and perhaps within as well. At the tenth week the temperatures for the ambient air had been slowly decreasing. The colder temperatures (below 50° F.) would have been a condition improper for survival, thus, they went into hibernation and did not erupt to their full potential until the air temperatures reached a suitable maximum (over 50° F.).

Apart from fungal growth, the most notable of all transformations that occurred with the body was the change in gross morphology of the soft tissues in and around the "water-level zone". This area runs from approximately three to four inches above and below the water surface around the body when it is in the floating stage. Within this zone the first signs of characteristic tissue resembling that found on adipociferous bodies were noted. In the earlier stages (sixth week), cutis anserina was observed speckling the body in areas around the shoulders and upper arms as well as the lateral aspects of the thoracic cavity to the upper thighs (hence the "water-level zone"). The goose-pimply nature of the external tissues offered the earliest distinction of adipocere. The tissues, after the emergence of this texture, became thicker

and more dense. The layers of the skin became rippled and transversely billowed. It appeared as if adipocere were forming.

There was a noted color (melanin) loss. The body had normal pinkish to reddish-brown hues in the initial stages of immersion but three weeks later the color had disappeared and only dull yellow and white remained. This state of color loss and billowy nature of the thickening tissue in the "water-level zone" was enough evidence to make the general conclusion that what was forming was characteristic tissue resembling that found on adipociferous bodies. The tissues above the "water-level zone" were mummifying. They had become hardened and dry. The tissues below the "water-level zone" appeared to be sloughing and macerating. The tissue was soggy and loose. No gross tissue loss nor any exposure of bone was noted. After the study period of three months the body remained floating and corpulent.

HOLE 3 The body in this hole reacted contrary to expected processes of underwater decay. The body floated for the entire study period of three months. The only noticeable differences in position of the body were during the bloating stage where the body floated higher in the water due to internal gas evolution. As the gases escaped, the body lowered to the initial position at which it was deposited (floating low in the water with only the face, shoulders, distended abdomen, and upper thighs exposed).

The progressions noted on this body were similar to Hole 2 in that the body remained floating for the entire period yet differed in the fact that there was never any maggot activity noted. In the fourth week, insect activity was observed but without any ovapositioning. Normal decompositional processes were noted as not progressing at a normal rate. Characteristic discoloration of the skin was observed as well as bloating. Tissue loss due to sloughage was

noted. During the same time period that cutis anserina was observed on Hole 2, it was also noticed in smaller proportions on the body in Hole 3. On areas around the "water-level zone", the goose-pimply texture was evident. To confirm the tissue was transforming into adipocere at that point is difficult, however, it did have the characteristic origins.

No fungal growth was noted on the body. The only other notable progression was the loss of color. Mann and colleagues (1990) state that color loss is typical in blacks during decomposition. The observations of severe loss of melanin in this cadaver agrees with their 1990 study. During initial immersion, the external tissue color of the body put in Hole 3 was very dark brown. Early observations noted that the body had already begun to putrefy. Patches of outer layers of epidermis had slipped to reveal a distinct whiter color beneath the darker melanin-rich outer layers of skin. During the decay stages in the water the body exhibited further loss of color, but not due to tissue loss. Earliest gross color loss was first noticed during the fifth week of submersion. The melanocytes (melanin-containing cells) appeared bleached.

By the end of the observational period, the only conclusions made in relation to adipocere formation for this body is that: there is a strong possibility that the tissue on the body has transformed into characteristic tissue resembling that found on adipociferous bodies. It has a typical "water-level zone" with color loss most noted in this area. The exposed tissues were mummified while the underside tissues appeared to slough and separate (macerate). The billowy texture or cutis anserina is not noted to such an extent as Hole 2. After the three month study period, the body remained floating and corpulent.

The reason that all three holes remained so corpulent was probably due to the diverse temperature fluctuations (see Figure 6). The air temperatures in this study ranged from a high of 75° F.(24° C.) to a low of 24° F. (-4° C.). During the peak temperatures the insect activity was most prolific; lending toward further decay and decomposition. But the lowest temperatures hindered decay considerably. The surface of the water was frozen in the thirteenth week. The range of temperatures varied widely for this study. Temperature was the major variable to be considered and is the major factor in adipocere development. This study was lucky in regards to the fact that it did have such fluctuation in climatic conditions. Second to the variable of warm temperature for adipocere formation is bacterial evolution within the body. In colder temperatures the bacteria slow down their activity but still perform (i.e., release enzymes). In warmer temperatures, bacteria progress at such a fast rate that it is difficult for a body to stay corpulent for an extended period of time because decay is so rapid.

Since adipocere formation is so contingent on appropriate temperatures this variable was used as the primary qualifiable measurement. Adipocere will form within a certain range of temperatures, this has been discussed in earlier literature (Payne and King, 1972; Tomita, 1975; Corry, 1978; Cotton, et.al., 1987). Payne and King's (1972) study shows, at the peak of decomposition, the water temperatures reached close to 81° F. (27° C.). Tomita (1975) notes that *Clostridium perfringens* (*welchii*) will not grow in laboratory temperatures of 70° F. (21° C.) or below. Corry (1978) explains the optimum growth temperature for *Clostridium perfringens* (*welchii*) is about 113° F. (45° C.). Cotton and coworkers (1987), cite a case report where adipocere was found on bodies where water temperature exceeded 70° F. (21°

C.). Bryan and colleagues (1962), state that bacteria function between temperatures ranging from 32° F. (0° C.) to 194° F. (90° C.). Also they explain the thermophilic species have a minimum temperature of 77° to 113 F. (25° to 45° C.), an optimum temperature of 122° to 131° F. (50° to 55° C.), and a maximum temperature of 140° to 185° F. (60° to 85° C.); where *Clostridium perfringens* (*welchii*) has an optimum temperature of 95° to 99° F. (35° to 37° C.). According to the above cases, a combined range of the temperatures for the optimum growth temperature of *Clostridium perfringens* (*welchii*) would be from about 70° to 113° F. (21° to 45° C.). Essentially when the ambient temperatures reach a maximum or a minimum, adipocere will not form due to a depression in the rate of bacterial action and enzymatic release. The temperature range must be "just right". This reaction will be titled the "Goldilocks Phenomenon".

As mentioned earlier, complete decomposition of the remains are contingent upon numerous variables and conditions of the environment. If water temperature is too cold or warm then the process will not be so simple as to just freeze or liquefy. The "Goldilocks Phenomenon" incorporates the following premises:

If the water temperature is too warm or heated then the tissues will liquefy easily and tend to macerate. The cellular structures of the soft-tissue autolyze, the subcutaneous adipose depots melt and the leaking fluid adds to the liquefaction of all tissue All the soft-tissue will decompose rapidly and nothing will remain except the disarticulated hard-tissue (i.e., the bones). If these processes were to occur on land, in a hot, arid environment decomposition would lead to mummification. The epidermis would become severely desiccated along with the internal organs. If the temperature of the

water is too cold, perhaps even freezing, then the processes of regular decomposition will slow down for all decompositional activity until temperatures warm. All bodily fluid will freeze and crystallization will commence (see Zugibe and Costello, 1993). If the body was on a barren, arctic wasteland; with the temperatures so cold, the body would essentially freeze-dry and decomposition would most likely not occur. Although when the body is brought into warmer temperatures putrefactive activity will be greatly increased (Spitz and Fisher, 1980:23).

Temperature was a major factor in this study as it would be in any research or case study in adipocere development. The significance of this variable is that all three cadavers were subjected to a similar environment and similar temperatures. However, in the end only two of the three formed what could be classified as characteristic tissue resembling that found on adipociferous bodies. The body that was contained in the underwater condition for the extent did not saponify while the others, which were partially exposed, did saponify. Adipocere formation started in the fifth week and by the twelfth week had progressed to a typical state of adipocere.

A variable that was added to this project that as yet has not been mentioned was the addition of polyethylene plastic to Holes 1 and 2. This impenetrable barrier was to prevent extensive water loss. It did not function as such, because water had to be periodically added to all three holes from water loss. Water was added by means of a garden hose and natural means (precipitation). The addition of new water to each hole does not constitute a significant change in the post-immersion water chemistry. Simple precipitation can cause more severe chemical alterations than city water in such a confined environment as the holes. The only remarkable change that

was noted during any water addition was that it disrupted the bacterial or microbial growth on and in the water. During the third and fourth week it was noted that an opaque film covered the water in all three holes. It appeared viscous and thick with algal and/or bacterial growth. But, upon observing the holes in a rainstorm the film disappeared. Disruption and overturn dispelled the opacity. In conclusion, the plastic did not play a significant part as a variable in this study. It might be argued that the addition of plastic to the holes does not constitute a true field (non-laboratory) experiment. But as just mentioned the plastic offered no important role in the formation or non-formation of adipocere. In fact, in the two holes that had the plastic, one body (Hole 1) did not form characteristic tissue resembling that found on adipociferous bodies while the other (Hole 2) did. It may be concluded from these problems that Hole 3 (without plastic) did not offer valid criteria to be included as a control. Rather, it succeeds in producing a scenario more in line with actualistic events in a field context.

The initial thoughts in doing this research were that all three bodies will act as if they were recently deceased and follow a textbook design of decomposition and subsequent activities. For example, if all went according to plan a freshly deceased body that dies in the water should float for a few moments before sinking. Once it submerges the decompositional processes begin to function (see Figure 1 in Chapter I.). As mentioned earlier there are certain stages that would be expected of a drowning death. After the body sinks, it begins to bloat due to bacterial action and autolysis of cellular structure. The gas formation within the body cavity causes a slow ascent to the surface. Once exposed to the air, the body undergoes differential decomposition where the superior portion of the body maintains a hospitable

location for ovapositioning; while the inferior portion suffers the effects of underwater decay through: internal mechanisms (bacteria) as well as external factors such as predatory action. The larvae hatch and burrow into the cadaver to devour the soft tissue. The integrity of the epidermal shell is breached and the gases that have been accumulating within now escape. The deflated, partially decomposed body now submerges for the second time. Upon this secondary sinking is when the author believes adipocere formation is at peak progression. The time interval for this stage can range anywhere from five to seven days (Tomita, 1976) depending on environmental conditions and state of the body at time of death.

If the body, upon the secondary sinking, becomes lodged in some underwater obstruction, then eventual rising to the surface will be definitely hindered. This impediment may also occur on the initial sinking. However, if one deals solely with the post-secondary sinking scenario then two hypotheses emerge (O'Brien, 1993): free floating versus snagged.

In the free floating scenario (see Figure 1, Stage 5a. in Chapter I.), the body is subjected to tidal action as well as current action beneath the surface of the water (Dilen, 1984). Temperature fluctuations under water bring warmer currents to the surface while colder water flows to the bottom. In isothermal water, during the spring or fall overturn, wind forces surface water to be overturned and replaced by lower level water (Hough, 1958). Depending on wind velocity, speed, and size of the aquatic environment this overturn may raise a free floating body to the surface in approximately less than a week. Although in a smaller more confined area, like a pond or stream, this scenario might only take a couple of days. Stagnant water in a small pond most likely does not have enough movement to jostle a body.

However, in all water environments the body will definitely be attacked by underwater creatures. Both microscopic and macroscopic will invade the body's tissues and disarticulate it to the point where decomposition will be hastened. Predatory action from fish and aquatic mammals will destroy tissue as well as carry away pieces, thus leading to further disarticulation. A free floating human body, beneath the surface of the water, will tend to float with the dorsal surface supine to the surface of the water (Spitz and Fisher, 1980). In this position the body is free and the arms and legs may be out-stretched. At the joints (i.e., wrists and ankles) the tissue will become weakened from the subsequent responsive action of those appendages due to water movement (Haglund, 1993). The tissue will begin to wear and slowly slough to the point of separation. At this time the hands and feet may be easily loosened by predators or simply fall to the water bottom.

In the snagging scenario (see Figure 1, Stage 5b. in Chapter I.), the body may become trapped in, on or under an obstruction. For example, a submerged car or sunken boat may obviously prevent return to the surface. In a stream or river, pond or lake, tree limbs and trash may grab a body. This situation may occur on the initial or secondary sinking. If the body is thrown off a bridge by an assailant, into a swift moving river, it may float downriver for some time before becoming snagged on the shore or an underwater obstruction (Dilen, 1984). In any event, the body is impeded from rising to the surface. The natural buoyancy after the initial sinking and subsequent bloating may be confined to the watery depths by heavy objects attached to the body (Dix, 1987). The body's watery grave may be maintained by the stratification of the winter or summer period (Hough, 1958) where lighter water circulates above the denser water (see Hypothesis Two in: O'Brien, 1993).

Once trapped below the surface, whether it be free floating or snagged, the body will continue to decompose. Putrefaction will ensue. The bacteria will emerge from their intestinal and vascular lodging to penetrate the body's cellular network and destroy it. The subsequent release of the internal cell's mass will cause a chemical reaction to take place between the bacteria, the watery environment, and the cellular contents. The result is adipocere. Over an undefined period of time it accumulates within the body to become an encasing tomb for the bacteria. Adipocere has reached its completion when all the bacteria are dead or there is no more soft tissue to hydrolyze. The body will remain in this state of preservation for an indefinite interval. Even when brought to the surface, albeit through discovery or refloatation, the adipocere will remain consistent. If allowed to dry, the transformed tissue will become a saponified, caseous mass of crumbling, chalky "soap".

This outline of adipocere formation is theoretically ideal under the right conditions and location. But this was not the case for the research project posed in this thesis. This project had holes excavated in the soil just four feet below the ground level. Two of the holes had plastic lining the contours while one did not. The water within them was stagnant and confined. The cadavers were not freshly deceased. They had been in a morgue cooler for over a month or more. A recently dead body may do something completely different and thus the decompositional events may progress at a new rate. Adipocere is known to occur in relatively warmer temperatures. This project was initiated in mid-October and ended in February (the colder time of the year). The conditions were not ideal.

Even with all these influential factors acting against the agents of adipocere transformation, the bodies were still able to persist and convert to

adipocere. Two of the three cadavers immersed had characteristic tissue resembling that found on adipociferous bodies. The adipociferous structures found on the bodies in this study resembled those found on other cases studied and those discussed in the literature. There were some limitations to its formation: mainly the post-mortem interval in relation to immersion.

Hole 1 throughout the extent of the project persisted in remaining submerged the entire lapse of study. Hole 2 and Hole 3 maintained a position floating on the water surface for the entire time. Unexpectedly, though, the bodies that were not completely submerged were the ones noted to have characteristic tissue resembling that found on adipociferous bodies.

The chemistry of this research involves much more than simple gross morphological observations. It entails a biochemical analysis of external tissues and internal liquids. By extracting these samples from the bodies an interpretation of the results was performed. (see Figures 7 and 8; H1= Hole 1, H1A= Hole 1 sample A; H2= Hole 2; H3A= Hole 3 sample A; H3B= Hole 3 sample B).

The flesh sample was the only sample to show free fatty acids distinct from those observed in the procedural blank. This was probably due to the limited amount of material extracted from the bodies. Increasing the sample size an order of magnitude in picomolar concentrations would improve the quality of this examination.

The presence of monoenoic fatty acids (oleic and vaccenic) in both the flesh and fluid samples indicates synthesis through anaerobic desaturation, a fatty acid biosynthetic pathway which does not require the presence of oxygen and is predominantly a gram negative bacterial pathway. Analysis of the polar lipid fatty acid profiles indicated the likely presence of a form of *Clostridium perfringens* (*welchii*). The proportions of 18:1w7c and 18:1w9c

Lipid Analyses

Free Fatty Acids (FFA)

mol% FAME	Fluid H1(12/24)	Fluid H1A(1/13)	Scum/Liq. H2(11/28)	Scum/Sol. H2(11/28)	Flesh H3A(1/13)	Fluid H3B(1/13)	Blank
12:0	–	–	9.71	–	–	–	–
15:0	3.13	–	–	–	–	–	–
16:0	67.84	54.03	62.32	67.40	14.47	58.98	46.29
17:0	3.30	4.37	–	–	1.62	–	4.36
18:0	25.72	23.95	27.97	32.60	11.53	41.02	35.26
20:0	–	–	–	–	0.47	–	–
22:0	–	–	–	–	2.79	–	–
23:0	–	–	–	–	1.63	–	–
24:0	–	–	–	–	30.90	–	–
25:0	–	–	–	–	7.87	–	–
26:0	–	–	–	–	22.06	–	–
27:0	–	–	–	–	0.86	–	–
28:0	–	–	–	–	2.99	–	–
Total	100.00	82.35	100.00	100.00	97.17	100.00	85.91
18:1w9c	–	14.22	–	–	2.58	–	7.39
18:1w7c	–	3.43	–	–	0.25	–	6.70
Total	–	17.65	–	–	2.83	–	14.09
Total pmol	20.32	25.25	56.02	11.39	90.72	18.69	23.75
mgdw		22			78	15	15
pmol/mgdw		1.15			1.16	1.29	1.58
16:0/18:1w9c		3.80			5.60		6.26

Figure 7. Free Fatty Acid Analysis for flesh and fluid samples from Holes 1, 2, and 3. (Provided by University of Tennessee Center for Environmental Biotechnology)

Lipid Analyses

Polar Lipid Fatty Acids (PLFA)

mol% FAME	Fluid H1(12/24)	Fluid H1A	Sous/Sed. H2(11/29)	Flesh H3A	Fluid H3B	Blank
12:0	–	–	–	0.08	–	–
13:0	–	–	–	0.07	–	–
14:0	–	–	1.22	2.01	–	–
15:0	–	–	0.94	1.07	–	–
16:0	51.22	29.19	16.77	13.72	44.71	–
17:0	–	–	0.16	0.29	–	–
18:0	13.78	24.31	0.23	1.33	6.56	–
20:0	–	–	–	0.13	–	–
22:0	–	–	–	0.21	–	–
23:0	–	–	–	0.16	–	–
24:0	–	–	–	0.45	–	–
25:0	–	–	–	0.08	–	–
26:0	–	–	–	0.16	–	–
28:0	–	–	–	0.03	–	–
Total	64.99	53.50	18.72	19.78	51.27	–
i13:0	–	–	0.02	0.12	–	–
a13:0	–	–	–	0.04	–	–
i14:0	–	–	0.27	0.12	–	–
i15:0	–	–	4.97	2.81	–	–
a15:0	–	–	2.39	1.86	–	–
i16:0	–	–	0.20	–	–	–
i17:0	–	–	0.19	0.14	–	–
Total	–	–	8.05	5.09	–	–
14:1w7c	–	–	–	0.15	–	–
14:1w5c	–	–	–	0.13	–	–
15:1a	–	–	0.08	1.05	–	–
15:1b	–	–	–	0.07	–	–
16:1w9c	1.98	–	–	–	–	–
16:1w7c	10.08	3.38	55.16	33.21	–	–
16:1w7t	–	–	–	1.13	–	–
16:1w5c	–	–	1.50	2.94	–	–
17:1w8c/a17	–	–	0.23	2.61	–	–
17:1w6c	–	–	0.32	2.00	–	–
cy17:0	8.16	–	1.38	0.32	7.24	–
18:1w7c	–	2.84	8.31	5.73	–	–
18:1w7t	–	0.42	0.07	0.46	–	–
18:1w5c	–	–	0.02	0.09	–	–
19:1	–	–	–	0.05	–	–
cy19:0	–	–	0.07	–	–	–
20:1	–	–	–	0.06	–	–
Total	20.21	6.44	66.12	50.03	7.24	–
br15:1	–	–	0.06	0.34	–	–
br16:1	–	–	0.09	0.14	–	–
i17:1	–	–	0.62	0.86	–	–
a17:1	–	–	0.13	0.26	–	–
br19:1	–	–	0.29	0.30	–	–
Total	–	–	1.19	1.89	–	–
10me14:0	–	–	0.17	–	–	–
2OH16:0	–	–	–	0.06	–	–
18:1w9c	12.04	37.44	2.46	15.16	41.46	–
16:2	–	–	0.13	0.50	–	–
16:3	–	–	–	1.08	–	–
17:2	–	–	–	0.09	–	–
18:3w6	–	–	0.04	0.11	–	–
18:4w3	–	–	0.06	–	–	–
18:2w6	2.75	2.63	0.81	5.13	–	–
18:3w3	–	–	0.14	1.19	–	–
20:4w6	–	–	0.03	0.10	–	–
20:5w3	–	–	0.09	–	–	–
Total	14.80	40.06	3.76	23.35	41.46	–
Total pmol	6833	32583	558945	473128	2884	–
mgdw		22		78	15	15
pmol/mgdw		1495		6085	192	
18:0/18:1w9c	4.25	0.78	6.81	0.91	1.06	

Figure 8. Polar Lipid Fatty Acid Analysis for flesh and fluid samples from Holes 1, 2, and 3. (Provided by University of Tennessee Center for Environmental Biotechnology)

indicates the possibility of the presence of this gram negative bacteria. *Clostridium perfringens* (*welchii*) is a gram negative bacteria which contains similar fatty acids to those discovered in the human samples. Fatty acid methyl esters (FAME) are designated by the number of carbons (e.g., 16: or 18:). A "w" indicates the position of a double bond (i.e., 18:1w9c = one double bond nine carbons from the methyl end of the molecule). The flesh sample revealed the highest presence of any remarkable findings including fatty acids indicative of the tissue as well as of microorganisms. The presence of terminally branched saturates are likely from obligate anaerobes (second grouping of rows) but may also be the result of gram positive microbial synthesis.

As for the rate of transformation of oleic acid to palmitic acid (see ratio labeled 16:0/18:1w9c in Figure 7.), that which would be expected in adipocere conversion (Cotton, et. al., 1987), the free fatty acid profile revealed an increase in the two samples taken from Hole 1, thus indicating a slight change in concentration. Although the original ratio noted that nothing was evident (ratio= undetermined) to begin with and then suddenly evolved to an increased state (ratio= 3.80%) is not enough evidence to base any conclusions. However, it does show there was some change in the oleic/ palmitic fatty acid ratio. The free fatty acid profile shows that this sample size was not sufficient for such a test. The free fatty acid profile represented the actions of microbial populations on the flesh over time. The polar lipid fatty acid profile estimated the presence of viable microbes living in, on, and around the decomposing body.

To answer the questions of how long does it take for adipocere to form and what conditions are conducive to its formation one must look at all the variables and the literature. In Table 3, the extent of different variables

present that need to be factored in when determining a post-mortem interval can be quite immense. In order to conduct such an estimation, the forensic scientist must first realize the scope of the incident and then attempt to rationalize the consequences surrounding the death. Once this stage has been concluded, the scientist may move on toward interpreting the data associated (i.e., climatological reports for the scene prior to the day of discovery; possible next of kin; possible cause of death); all of which may be so interconnected that to discern any distinction would challenge the knowledge of the scientist. Thus, an accurate method of understanding the variables contingent upon development of tissue decay in an underwater setting is necessary (see Table 3.).

Table 3. VARIABLES INVOLVED IN ADIPOCERE FORMATION

PRIMARY	SECONDARY
WATER:	Temperature; Depth; Movement (stagnant/ running); Chemistry (pH); Salt or fresh water
AIR:	Temperature; Relative humidity
BACTERIA:	Intrinsic or extrinsic
LOCATION:	Buried or non-buried; Inside or outside; Direct or indirect sunlight; Open or wooded
PREDATORY ACTION:	Insects; Mammals; Fish (crustaceans); Birds; Bacteria
TRAUMA:	Loss of blood; Poison; Prior to or after immersion
OTHER:	Weighted or not; Clothed or nude; Weight of decedent; Race of decedent; Sex of decedent; (Age of decedent?)

Table 4. shows only some of the extensive data available to the forensic scientist for comparable means. It shows the wide variability in time since death and state of the adipocere. Adipocere can reach completion in as little time as three weeks (Simonsen, 1977) but progress slowly until completion over a period of perhaps five or more years (Cotton,et.al., 1987; Evans, 1962 respectively). The studies display a good number of cases involving direct contact with water. Although the one study (Mellen, et. al., 1993) showed adipocere formation in an aquatic environment with human tissue, it was conducted inside a laboratory setting. The results were conclusive that adipocere formed within three months. Applying the variables in Table 3. with the case reports in Table 4. one can judge that the factors (i.e., variables) in adipocere development are so interrelated that one must consider them all before making any hypothetical deductions.

Table 4. CASE REPORTS CITING BODIES FOUND WITH ADIPOCERE

AUTHOR (YEAR)	ENVIRONMENT	TIME PERIOD	CONDITION
Cotton, et.al. (1987)	water	5 years	complete
Mant and Furbank(1957)	water	1 year	complete
Dix (1987)	water	10 months	complete
Dix (1987)	water	6 months	moderate
Takatori and Yamaoka (1977a)	water	4.5 months	complete
Dix (1987)	water	4 months	slight
Mellen, et.al. (1993)	water (lab)	2.5 months	complete
Dix (1987)	water	3 weeks	minimal
Simonsen (1977)	water	3 weeks	complete
Evans (1962)	buried	100- 140 years	complete
Rodriguez and Bass (1985)	buried	1 year	complete
Rodriguez and Bass (1985)	buried	6 months	moderate
Rodriguez and Bass (1985)	buried	3 months	minimal
Rodriguez and Bass (1985)	buried	2.5 months	slight

In order to assess the rate of formation of adipocere a progressional stage analysis has been devised from this study to determine whether or not adipocere is developing. Certain stages of development are and were present during the course of decomposition. Allowing for the variability in temperature, environment and condition of the body, the following progression of adipocere formation has been taken into consideration: (the following list is formed from the saponification of the tissues resembling adipocere on the cadaver in Hole 2; in other words this method for analysis is in regards to a body that is floating within a confined area of stagnant water for a definite period of time):

STAGE 1. FLOAT: The body will tend to float. Amount of adipose tissue present in the body and post mortem interval can be strong factors contributing to the submersion of the body.

STAGE 2. BLOAT: Once putrefaction has commenced the face and torso will distend and bloat. The internal gases can be strong inhibitors in total submersion.

STAGE 3. INSECT ACTIVITY: Flies will discover the body immediately upon deposition and floatation. Ovapositioning and activity will progress in areas on the body where warmth, moisture, and protection from the elements are present.

STAGE 4. HATCHING: The insect larvae will hatch and migrate across the body. Most will be present in the groin and facial regions of the body. Those areas deep in the water will not be attacked. However, places immediately below water level may be subject to intrusion of maggot feeding. The maggots will feed underwater with the distal ends of their capsules (the spiracle end) projecting above the water line.

STAGE 5. MUMMIFICATION/ MACERATION: The exposed areas of soft tissue will be subjected to the conditions of the surrounding environment. The most superior portions will tend to dry and become mummified. The areas surrounded by water will be penetrated by the liquid and become loose and separated. Maceration will occur with a sloughing of the soft tissue. (The underside of the body is also subjected to predatory action.)

STAGE 6. FUNGAL GROWTH: The exposed areas of soft tissue are prime targets for fungal or bacterial growth. The rich, organic soft tissue of the debilitated host is unable to defend against microbial attack. The micro-organisms will flourish on the organic matter of the epidermis. (This effect is highly seasonal and may be used in determining post mortem interval.)

STAGE 7. COLOR LOSS: The decomposing body exposed to the elements and the effects of putrefaction will undergo a rapid color loss. Along with the sloughing of the epidermal tissues, melanin content will decrease. The color of the body will bleach drastically over time. The range of colors through which the body may progress is: pink to dark brown (original tone), ivory to light brown, yellowish-white to beige. The color change is most likely correlated with drying of the epidermis.

STAGE 8. CUTIS ANSERINA: A distinct area around the body will form. This is the "water-level zone". Here will occur the most transformation. Within an area approximately three to four inches above and below the water surface, the soft tissue will warp and contort. A billowing will occur with subsequent rippling of the tissue. A build-up of released waxes and oils from the tissues will form a thin film or residue across the surface of the water. The epidermis of the body becomes bubbled with tiny upraised portions of skin. Around each

hair follicle a bump will form. The appearance is "goose-pimply flesh". The name for this phenomenon is cutis anserina.

STAGE 9. ADIPOCERE: The congealed soft tissue will become dense and thick. The subcutaneous adipose depots have saponified (solidified). The texture of the skin is wrinkled and greasy. The decay of the soft tissue has reached a point of stability.

Within these stages of progression is generally how the tissue transformed into characteristic adipocere in the the cadaver which displayed the most abundant adipocere-like qualities present in this study (i.e., the cadaver in Hole 2). A time interval for each stage is not presented due to the fact that only the one cadaver (Hole 2) was utilized in developing the progressional scenario. The chronological relationship with the progression can be limited to a twelve week period. The differences between the Hole 2 scenario and the free-floating/ snagging scenarios, presented earlier, is that the Hole 2 progression states a process occurring in a floating state; while the body in the free-floating/ snagging scenarios is confined to a subsurface level in the water. Both scenarios present a body with differential decomposition, but the difference is in the Hole 2 scenario the body has never submerged nor followed the ideal decay progression as in the free-floating/ snagging scenarios.

In this study, characteristic tissue resembling that found on adipociferous bodies has formed in three months to an assumed state of completion. If allowed to stay in the watery environment for further research, one might find that decay would not continue. Adipocere is a finalized state of decomposition where no more decay will take place. Mant and Furbank (1957) and Evans (1963) state once adipocere forms,

decomposition has reached completion. Mainly because once the tissues have saponified they remain in an unalterable state. Thus, a body can remain in this condition for an extended period of time (see Bass, 1984). This phenomenon of adipocere formation can perplex the forensic scientist when developing an appropriate post-mortem interval. Since adipocere is so homogenous and well structured it does not decay over time. However, its friable and caseous consistency will, however, aid in its fragmentation (i.e., assuming that it has dried). At first when it is pulled out of the aquatic environment, adipocere will tend to be soggy and doughy. Older adipocere is known to be dry and brittle, crumble and split apart if allowed to dry. It tends to lose the yellowish tone and become more grayish-white (Evans, 1963) to brown.

To refer back to the crime scene in the introductory chapter, the forensic scientist was reluctant to place a time since death interval on the body that was pulled up from the lake. If the body was completely encased in adipocere then most likely he or she could say five to six months to be on the safe side. But with the forensic application of this study the result of estimating a finer age range for time since death may become more acute. The human bodies tested for adipocere formation in an aquatic environment converted to the waxy tissue in only three months. This information may be added to the forensic literature as well as be used as a comparative measure for indicating adipocere development in a human body that has been submerged or immersed for an extended period of time. The anthropological implications for this research should add more credence to the conversion of human adipose tissue in watery locations and its subsequent transformation into adipocere as well as aid law enforcement officials in eastern Tennessee, if not

all of the southeastern United States, in identifying correctly and understanding the processes behind adipocere development.

Another fact that was stated by Mant (1987) was the densifying properties of adipocere in its developmental stages. As the tissue grows (conversion of the liquid, unsaturated fatty acids into more solid, saturated fatty acids) it becomes more dense and thick. A forensic anthropological significance for this transformation is: if an individual is shot or stabbed in the abdomen or portion of the body where no evidence remains on the hard tissues (i.e., bones) the result would obviously be a gaping entry wound. But if the decedent was then deposited or fell into an aquatic environment and adipocere developed, then the resulting hypertrophy or hyperplasia (Montgomery, et.al., 1977) of the soft tissues might obliterate the external wound. Only through radiography might a gunshot wound be detected by discovering lead wipe. A knife wound may never be found. Mant's (1987) recollection indicated that after a twelve month burial in moist soil the partial conversion into adipocere nearly obscured the entrance hole of the bullet. The path of the bullet was only traced through the holes in the clothing. Hence, the forensic scientist should be well trained in the art of interpreting an adipociferous body.

Future research in this field encompasses a wide range of diversity. As pointed out earlier, the extensive amount of variables can lead to a lifetime of study. This author plans to continue the work in adipocere development so that the discipline of forensic anthropology may have a better means of estimating post-mortem interval through the conversion of the body's fats. The cadavers that are currently in experimentation will continue to be analyzed and observations on further development or decay of the bodies will

be noted. What could be expected is that the tissue in a gross aspect will not decay but rather remain consistent and stable.

In conclusion, it is now quite evident how variable adipocere is in its development. This study has offered another insight and angle at viewing adipocere formation in an aquatic environment. As the research continues on these cadavers, more studies will be produced. For the time being, adipocere has its own style for aiding in the decomposition of human remains. The forensic scientist is forced to consider all possible variables and factors in its development. Hopefully this research provided those who encounter this phenomenon with a better understanding of human soft-tissue decomposition and its transformation into adipocere formation.

VIII. SUMMARY

The problems addressed in this study are how long does it take for adipocere to form in a human body and what are the gross morphological changes that occur on and within the decomposing body. In order to determine the answers for these questions an actualistic study was constructed to test the rates of adipocere formation on human cadavers in a non-laboratory environment. The opportunity of utilizing a Research Facility designed specifically to test decomposition of human remains presented itself as a highly rewarding event. The majority of previous adipocere studies has offered conclusions based on tests conducted on non-human remains, or human samples in an aquatic environment. None have any results analyzing the decompositional rates of full human cadavers completely immersed in water. This study has presented a unique look into the actualistic decay of human soft tissue in water and the subsequent conversion into adipocere.

The experiment consisted of immersing three human cadavers into excavated holes in the earth for three months (or until adipocere formed). Gross morphological changes of the external tissues and body were recorded as well as the ambient and water temperatures. Fluctuations in climatological and meteorological conditions were compared to the transformation occurring in and around the cadavers. Weather events provided a variety of situations in which to observe the decay rates (e.g., rain, snow). Liquid and tissue samples were extracted during the study period and analyzed for fatty acid and microbial composition.

In the initial stages of immersion the cadaver in Hole 1 submerged while the cadavers in Holes 2 and 3 remained floating. This phenomenon was

contrary to what was expected. Normal processes of decay state that a body should sink within a few hours after death. This did not occur. Conclusions were that the post mortem interval spent in the morgue cooler might have played a significant role in determining post-mortem effects on the cadavers. After a period of about five to six weeks the first signs of characteristic adipocere were noted. The soft tissues continued to saponify both internally and externally. Once a period of three months had passed final observations were recorded. The cadaver in Hole 1 was still completely submerged in the water while the cadavers floated in Holes 2 and 3. Upon raising to the surface, the cadaver in Hole 1 exhibited a thick, green-algal mat covering the entire supine surface of the body. Evidence of tissue sloughage was present but no signs of adipocere formation were evident. On the cadavers in the latter holes the external soft tissues above the "water-level zone" had mummified yet retained an adipocere-like quality and appearance. The tissue that was in the "water-level" zone had turned in to a rippled, decayed, friable, caseous material resembling adipocere. The tissue on the underside of the two cadavers had sloughed away revealing a soggy, saponified, waxy material.

The analysis of recorded temperatures for both weather and water revealed that adipocere formation was most likely occurring during the warmer periods of the study. The interpretation of the fatty acid profiles showed inconclusive results but suggested the expected increase in palmitic fatty acid as the rate of oleic fatty acid decreased. The polar lipid fatty acid profile suggested corroborative evidence for the presence of *Clostridium perfringens (welchii)*, the primary bacteria responsible for adipocere formation, still present after a three month interval.

Conclusions suggest temperature is a major variable in underwater decomposition. The "Goldilocks Phenomenon" presented here indicates that there is a certain range for temperatures to be operative in the formation of adipocere. The ambient or water temperatures can not be too hot or too cold but "just right". The range is dependent on the evolution of the bacteria. The optimum growth temperature for Clostridium *perfringens* (*welchii*) would be from about 70° to 113° F. (21° to 45° C.). The literature on this topic states that a warm, moist, virtually anaerobic environment with adequate bacterial action is suitable for adipocere formation to occur. This study concurs with these criteria.

The gross morphological changes that occurred in the cadaver in Hole 2 provided data for a progressional stage analysis to be made. The development of adipocere formed on the cadaver in the following stages: Stage 1. Float; Stage 2. Bloat; Stage 3. Insect activity; Stage 4. Hatching; Stage 5. Mummification/ Maceration; Stage 6. Fungal growth; Stage 7. Color loss; Stage 8. Cutis anserina; Stage 9. Adipocere.

The limited sample size (i.e., three cadavers) for this research does not allow for accurate predictions to be made on adipocere formation. However, it is possible to say that complete immersion in an aquatic environment is not necessary for this decompositional process to occur. Also, an individual who is deceased prior to immersion will tend to float but is still susceptible to adipocere formation.

BIBLIOGRAPHY

BIBLIOGRAPHY

Barnett HL and Hunter BB (1987) Illustrated Genera of Imperfect Fungi. MacMillan Publishing Company, New York, New York.

Bass, WM (1984) *Time Interval Since Death, A Difficult Decision.* In: Rathbun TA and Buikstra JE (eds): Human Identification: Case Studies in Forensic Anthropology. Charles C. Thomas Publishing Company, Springfield, Illinois. pp. 136-147.

Bryan AH, Bryan CA, and Bryan CG (1962) Bacteriology: Principles and Practice. Barnes and Noble Books, New York, New York.

Bulmer, GS (1991) Medical Mycology. The Upjohn Company, Kalamazoo, Michigan.

Collee JG, Knowlden JA, and Hobbs BC (1961) *Studies on the Growth, Sporulation and Carriage of* Clostridium Welchii *with Special Reference to Food Poisoning Strains.* Journal of Applied Bacteriology. 24:326-339.

Corry JEL (1978) *Possible Sources of Ethanol Ante- and Post-mortem: its Relationship to the Biochemistry and Microbiology of Decomposition.* Journal of Applied Bacteriology. 44:1-56.

Cotton GE, Aufderheide AC, and Goldschmidt VG (1987) *Preservation of Human Tissue Immersed for Five Years in Fresh Water of Known T emperature.* Journal of Forensic Sciences. 32:1125-1130.

Cramer DL, and Brown JB (1943) *The Component Fatty Acids of Human Depot Fat.* Journal of Biological Chemistry. 151:427-438.

Davidsohn J, Better EJ, and Davidsohn A (1953) Soap Manufacture. Volume 1. Interscience Publishers, Inc., New York, New York.

Den Dooren De Jong LE (1961) *On the Formation of Adipocere from Fats.* Antonie Van Leeuwenhoek. 27:337-362.

Dilen DR (1984) *The Motion of Floating and Submerged Objects in the Chattahoochee River, Atlanta, GA.* Journal of Forensic Sciences. 29:1027-1037.

Dix JD (1987) *Missouri's Lakes and the Disposal of Homicide Victims.* Journal of Forensic Sciences. 32:806-809.

Drasar BS and Hill MJ (1974) Human Intestinal Flora. Academic Press Inc., New York, New York.

Evans WE (1962) *Adipocere Formation in a Relatively Dry Environment.* Medicine, Science, and Law. 3:145-153.

Evans WE (1963) The Chemistry of Death. Charles C. Thomas, Springfield, Illinois.

Garland AN and Janaway RC (1989) *The Taphonomy of Inhumation Burials.* In: Roberts CA, Lee F and Bintliff J, (Eds), Burial Archaeology Current Research, Methods and Developments. BAR British Series 211. pp. 15-36

Glaister J (1950) Medical Jurisprudence and Toxicology, 9th edition. E&S Livingstone, Ltd., Edinburgh, England. pp. 30.

Gotouda H, Takatori T, Terazawa K, Nagao M, and Tarao H (1988) *The Mechanism of Experimental Adipocere Formation: Hydration and Dehydrogenation in Microbial Synthesis of Hydroxy and Oxo Fatty Acids.* Forensic Science International. 37:249-257.

Haglund WD (1993) *Disappearance of Soft Tissue and the Disarticulation of Human Remains from Aqueous Environments.* Journal of Forensic Sciences. 38:806-815.

Hough JL (1958) Geology of the Great Lakes. University of Illinois Press, Urbana, Illinois.

Janssen W (1984) Forensic Histopathology. Springer Verlag Press, Berlin, Germany.

Knight B (1991) Forensic Pathology. Oxford University Press, New York, New York.

Larone DH (1987) Medically Important Fungi: A Guide to Identification. Elsevier Publishing Company, New York, New York.

Mann RW, Bass WM, and Meadows L (1990) *Time Since Death and Decomposition of the Human Body: Variables and Observations in Case and Experimental Field Studies.* Journal of Forensic Sciences. 35:103-111.

Mant AK (1987) *Knowledge Acquired from Post-War Exhumations.* In: A Boddington, AN Garland, and RC Janaway (eds): Death, Decay and Reconstruction. Approaches to Archaeological and Forensic Science. Manchester University Press, Manchester, England.

Mant AK, and Furbank R (1957) *Adipocere - A Review.* Journal of Forensic Medicine. 4:18-35.

McElroy WD (1964) Cell Physiology and Biochemistry. Prentice-Hall Inc., Englewood Cliffs, New Jersey.

Mellen PFM, Lowry MA, and Micozzi MS (1993) *Experimental Observations on Adipocere Formation.* Journal of Forensic Sciences. 38:91-93.

Montgomery R, Dryer RL, Conway TW, and Spector AA (1977) Biochemistry: A Case-Oriented Approach. The C.V. Mosby Company, St. Louis, Missouri. pp. 363-417.

Mortimer CE (1983) Chemistry. 5th edition. Wadsworth Publishing Company, Belmont, California.

O'Brien TG (1993) Waxing Grave about Adipocere. Paper presented at the annual meeting of the American Academy of Forensic Sciences; Boston, Massachusetts.

Payne JA and King EW (1972) *Insect Succession and Decomposition of Pig Carcasses in Water.* Journal of Georgia Entomological Society. 7:153-162.

Polson CJ, Gee DJ, and Knight B (1985) The Essentials of Forensic Medicine. 4th edition. Pergamon Press, Oxford, England.

Rodriguez WC, and Bass WM (1985) *Decomposition of Buried Bodies and Methods That May Aid in Their Location.* Journal of Forensic Sciences. 30:836-852.

Ruttan RF, and Marshall MJ (1917) *The Composition of Adipocere.* Journal of Biological Chemistry. 29:319-327.

Saito K (1966) *The Occurrence of 10- Hydroxystearic Acid in Adipocere.* The Journal of Biochemistry. 59:487-494.

Simonsen J (1977) *Early Formation of Adipocere in Temperate Climate.* Medicine, Science, and Law. 17:53-55.

Smith KGV (1986) A Manual of Forensic Entomology. New York: Comstock Publishing Associates, pp. 25-27.

Spence AP and Mason EB (1987) Human Anatomy and Physiology. 3rd Edition. The Benjamin/ Cummings Publishing Company, New York, New York.

Spitz WU and Fisher RS (1980) Medicolegal Investigation of Death. 2nd Edition. Charles C. Thomas, Springfield, Illinois.

Takatori T, Ishiguro N, Tarao H, and Matsumiya H (1986) *Microbial Production of Hydroxy and Oxo Fatty Acids by Several Microorganisms as a Model of Adipocere Formation.* Forensic Science International. 32:5-11.

Takatori T, Gotouda H, Terazawa K, Mizukami K, and Nagao M (1987) *The Mechanism of Experimental Adipocere Formation: Substrate Specificity on Microbial Production of Hydroxy and Oxo Fatty Acids.* Forensic Science International. 35:277-281.

Takatori T, and Yamaoka A (1977a) *The Mechanism of Adipocere Formation 1. Identification and Chemical Properties of Hydroxy Fatty Acids in Adipocere.* Forensic Science. 9:63-73.

Takatori T, and Yamaoka A (1977b) *The Mechanism of Adipocere Formation 2. Separation and Identification of Oxo Fatty Acids in Adipocere.* Forensic Science. 10:117-125.

Tomita K (1975) *On Putrefactions and Floatations of Dead Bodies Under Water.* Hiroshima Journal of Medical Sciences. 24:117-152.

Tomita K (1976) *On Putrefactions and Floatations of Dead Bodies Under Water (supplement).* Hiroshima Journal of Medical Sciences. 25:155-174.

Tomita K (1984) *On the Production of Hydroxy fatty Acids and Fatty Acid Oligomers in the Course of Adipocere Formation.* Japan Journal of Legal Medicine. 38:257-272.

Wigner JH (1940) Soap Manufacture. Chemical Publishing Company, Inc., New York, New York.

Zugibe FT and Costello JT (1993) *The Iceman Murder: One of a Series of Contract Murders.* Journal of Forensic Sciences. 38:1404-1408.

APPENDICES

APPENDIX A.

PARTIAL ANALYSIS OF COMPOSITES OF DAILY SAMPLES OF RAW AND TAP WATER

MBW WATER PLANT - KNOXVILLE, TENNESSEE. (ppm = parts per million)

MEASUREMENTS FOR THE MONTH OF OCTOBER, 1994	
pH	7.82
TEMPERATURE (C°.)	22
DISSOLVED SOLIDS (ppm)	160
SUSPENDED SOLIDS (ppm)	0
TOTAL SOLIDS (ppm)	160
ALKALINITY as CaCO3 (ppm)	71
HARDNESS as CaCO3 (ppm)	88
CHLORIDE	15.6
CHLORINE (minimum)	0.9
SULFATE (ppm)	27
COLOR (Apparent)	0
DISSOLVED OXYGEN (ppm)	9.1

APPENDIX B.

BRIEF OVERVIEW OF COMMERCIAL SOAP MANUFACTURE

Early soap came from animal fats and ashes. In a chemical sense, soap is "any compound formed by the reaction of a water-insoluble fatty acid with a metallic radical or with an organic base" (Davidsohn, et. al., 1953:11). The salts of fatty acids with ammonia are used as technical soaps (shaving creams, etc.). Saponification is an exothermic reaction. Only fatty acids can be saponified with ammonia, not neutral fats and oils. Fats and oils belong to a class of esters, basically acids and alcohols. The higher the quantity of double bonds in the fatty acids makes the soap more liquid. Soaps can become rancid by oxidation. Fats high in oleic acid become rancid after the absorption of less oxygen than fats in which the ratio of the acids is reversed. Absorption of oxygen is accelerated by heat and light. (Davidsohn, et. al., 1953)

Fatty acids above twelve carbons become less water soluble. The hardness of a soap depends on its amount of saturated fatty acids. Softness of soaps comes from oils yielding a large amount of unsaturated acids. Hydrogenation saturates the double bonds of the unsaturated constituents. Soap can be produced by placing a sample of animal fat and caustic soda in a beaker. This is placed into a container filled with boiling water. Steam is injected into the sample. If the fat/ soda ratio becomes too thick more alkali (soda) should be added. Brine may be a valid substitute for the soda. The lye form the sample will separate. The contents after heating will be a soap hydrate and water. The sample of saponified fat (fat with salt and water mixture) floating in the lye can be extracted as a soap hydrate and the lye is

then filtered. What will flow through the filter will be the salt, water and glycerine. The soap (free fatty acids) will remain. If there is any neutral fat remaining in the sample of soap it will become rancid. (Wigner, 1940)

APPENDIX C.

SUGGESTED READING ON TOPICS RELATING TO ADIPOCERE DEVELOPMENT

Bal TS, Hewitt RW, Hiscutt AA, and Johnson B (1989) *Analysis of Bone Marrow and Decomposed Body Tissue for the Presence of Paracetamol and Dextropropoxyphene.* Journal of the Forensic Science Society. 29:219-223.

Barber P (1988) Vampires, Burial and Death. Vail-Ballou Press, Binghamton, New York.

Clausen CJ, Cohen AD, Emiliani C, Holman JA, and Stipp JJ (1979) *Little Salt Spring, Florida: A Unique Underwater Site.* Science. 203:609-614.

Cochrane CC, and Harwood HJ (1961) *Phase Properties of Mixtures of 9- and 10- Oxo-octadecanoic Acids and of 9- and 10-Hydroxyoctadecanoic Acids.* Journal of Organic Chemistry. 26:1278-1282.

Conlogue G, Schlenk m, Cerrone F, and Ogden J (1989) *Dr. Leidy's Soap Lady: Imaging the Past.* Radiologic Technology. 60:411-415.

Garrett G, Green MA, and Murray LA (1988) *Technical Method - Rapid Softening of Adipociferous Bodies.* Medicine, Science, and Law. 28:98-99.

Henderson J (1987) *Factors Determining the State of Preservation of Human Remains.* In: Boddington A, Garland AN, and Janaway RC, (Eds), Death, Decay and Reconstruction, Approaches to Archaeology and Forensic Science. Manchester University Press, Manchester, England. pp. 43-54.

Ingram M, and Dainty RH (1971) *Changes Caused by Microbes in Spoilage of Meats.* Journal of Applied Microbiology. 34:21-39.

Jones RN (1988) *A Yellow-Stained Human Femur From Tell esh-Shuqafiya, Egypt: Evidence of Ancient Trauma.* American Journal of Physical Anthropology. 77:77-83.

Mant AK (1960) Forensic Medicine. Lloyd-Luke (Medical Books) Ltd. London, England.

Mant AK (1967) *Recent Work on Post-Mortem Changes and Timing Death.* In: K Simpson (ed): Modern Trends in Forensic Medicine. Apple Century Crofts, New York, New York. pp. 147-162.

Mant AK (1969) *Autopsy Diagnosis of Accidental Hypothermia.* Journal of Forensic Medicine. 16:126-129.

Micozzi MS (1986) *Experimental Study of Postmortem Change Under Field Conditions: Effects of Freezing, Thawing, and Mechanical Injury.* Journal of Forensic Sciences. 31:953-961.

Pachar JV, Cameron JM, and Path FC (1992) *Scanning Electron Microscopy: Application in the Identification of Diatoms in Cases of Drowning.* Journal of Forensic Sciences. 37:860-866.

Putnam RJ (1978) *Flow of Energy and Organic Matter from a Carcass During Decomposition.* Oikos. 31:58-68.

Rathbun TA, and Rathbun BC (1984) *Human Remains Recovered from a Shark's Stomach in South Carolina.* Journal of Forensic Sciences. 29:269-276.

Rose GW, and Hockett RN (1971) *The Microbiologic Evaluation and Enumeration of Postmortem Specimens form Human Remains.* Health Laboratory Sciences. 8:75-78.

Schroepher GJ, and Bloch K (1965) *The Stereospecific Conversion of Stearic Acid to Oleic Acid.* The Journal of Biological Chemistry. 240:54-63.

Stoffel W, Chu F, and Ahrens EH (1959) *Analysis of Long-Chain Fatty Acids by Gas-Liquid Chromatography.* Analytical Chemistry. 31:307-308.

Tkocz I, Bytzer P, and Bierring F (1979) *Preserved Brains in Medieval Skulls.* American Journal of Physical Anthropology. 51:197-202.

Wallen LL, Benedict RG, and Jackson RW (1962) *The Microbiological Production of 10-Hydroxystearic Acid from Oleic Acid.* Archives of Biochemistry and Biophysics. 99:249-253.

Vass AA, Bass WM, Wolt JD, Foss JE, and Ammons JT (1992) *Time Since Death Determinations of Human Cadavers Using Soil Solution.* Journal of Forensic Sciences. 37:1236-1253.

Zimmerman MR (1979) *Paleopathologic Diagnosis Based on Experimental Mummification.* American Journal of Physical Anthropology. 51:235-254.

VITA

Tyler G. O'Brien was born in Ogdensburg, New York in 1969. He graduated from Potsdam High School in 1987 with concentrations in science and art. From there he enrolled at the State University of New York in Plattsburgh. He graduated from Plattsburgh in 1991, with the degree of Bachelor of Arts in Anthropology with a double minor in Archaeology and Spanish. During the fall semester of his last year at Plattsburgh, he attended the Universidad de Chile in Santiago, Chile, South America as an exchange student. Later that same year he attended the graduate program at the University of Tennessee in Knoxville. In May of 1994, he received the degree of Master of Arts in Anthropology. His concentrations in this field were in physical anthropology with research interests in forensic anthropology.