Transmission and ecology of *Toxoplasma gondii* in various wild bird species

A Dissertation Presented for the
Doctor of Philosophy
Degree
The University of Tennessee, Knoxville

Sawsan Ibrahim Ammar

December 2019

DEDICATION

To the soul of my beloved mom

ACKNOWLEDGEMENTS

I would like to express my great gratitude to my supervisor Dr. Richard Gerhold for his supervision, guidance and kind encouragement as I completed this work. Without his support, I could not accomplish any of this. I would also like to express many thanks to all my committee members Drs. John Schaefer, Chunlei Su and Marcy Souza for their guidance, support and encouragement throughout the whole Ph.D. journey. Sincere gratitude goes to Dr. Chunlei Su, who hosted me in his lab as one of his lab members, for his continuous assistance, patience and support throughout each stage of this work. I also express my gratitude to my co-supervisor Dr. John Schaefer for always opening his doors for my questions. I would like to also thank Dr. Marcy Souza for her cheerful attitude towards and support of me as a person and as a researcher. I was lucky to be surrounded by this wonderful group of *Toxoplasma* experts.

Moreover, I want to thank my dear friend Dr. Kate Purple for her endless support inside and outside the lab. She was always there when I needed her. I would also like to thank all the past and present molecular and diagnostic parasitology lab members for their continuous help the whole time I was there. Dr. Stephen Kania, Kim Rutherford and Misty Bailey, thank you for your help and kindness throughout this journey. Thanks for helping me to acclimatize and adjust when I first came to the USA.

I want to thank all my coauthors and the persons behind the scenes who helped with collecting the bird samples that I tested for my dissertation. I also wish to express my gratitude to Cary Springer, my statistical consultant, for helping me to understand my data and represent my work in the best way possible. I would like to thank the Egyptian Ministry of Higher Education and the Egyptian cultural and Educational Bureau for the scholarship and financial support they provided.

This acknowledgement cannot be complete without thanking my family. My husband Ahmed, thank you for all the sacrifices that you made since the first day we met. I could not accomplish anything without your support, your patience and your love. My mom and my dad, you were always the model for me, and I hope that one day I will be as awesome as you both are. My sisters, I appreciate all your support during times of home sickness, the loss of our mom and Ph. D. stress. I love you all!

ABSTRACT

Toxoplasma gondii is an important zoonotic protozoan parasite that infects all warm-blooded animals including humans and birds. Wild birds are intermediate hosts of the parasite and important prey item of the Felidae family, which are the only animals that act as definitive hosts for the parasite and capable of producing *T. gondii* oocysts. We investigated *T. gondii* prevalence in various wild bird species to better understand the parasite's epidemiology and ecology. We tested 28 wild bird species for *T. gondii* infection using modified agglutination testing (MAT), polymerase chain reaction (PCR), mice bioassay or a combination of these tests. We detected a *T. gondii* prevalence of 27.4% (308/1124) in various wild bird species using different methods. We had a prevalence of 78.3% (18/23) in Charadriiformes, 48.4% (178/368) in Anseriformes, 20.5% (78/381) in Galliformes, 44.8% in Falconiformes (13/29), 75% in Strigiformes (15/20) and 3.8% in Ciconiiformes (4/106) using MAT. We examined the brains of 197 Columbiformes by molecular methods and only two birds (1%) were *T. gondii* sequence positive. We successfully isolated viable *T. gondii* tachyzoites from one red-shouldered hawk (*Buteo lineatus)* and genotyped it using PCR-RFLP of ten genetic markers (TgHawkFL1, ToxoDB PCR-RFLP genotype #28). We also experimentally infected twenty-five four-week old female domestic turkeys (*Meleagris gallapavo*) intraperitoneally with *T. gondii* tachyzoites of two different stains and doses (10^5 and 10^8 tachyzoites/ml PBS) to investigate the seroconversion, feed conversion rate (FCR), weight gain pattern and parasite tissue tropism in relation to the parasite dose and virulence. We recorded an increase in FCR and a decrease in bird weight gain and survival rate with increase of *T. gondii* dose and virulence. The group infected with 10^8 tachyzoites/ml PBS of the virulent *T. gondii* strain seroconverted earlier than the other groups and had a significantly higher antibody titers as tested by MAT. Gross and histological findings are also discussed. We documented the presence of *T. gondii* infection in

various wild birds which represents an important host for the maintenance of *T. gondii* life cycle, and we investigated the progress of the infection in experimentally infected turkeys which support our understanding of the parasite's life cycle and pathogenesis.

TABLE OF CONTENTS

CHAPTER I Introduction…….1

1. Background and significance……...2
2. History……..2
3. *Toxoplasma gondii,* the causative agent……...3
4. Significance of studying *T. gondii* in avian species……..4
5. Mode of transmission……...5
6. *Toxoplasma gondii* in birds……..5
7. Diagnosis of *T. gondii* infection in birds……..8
8. Aims and conclusion……..12

CHAPTER II *Toxoplasma gondii* prevalence in carnivorous wild birds in the eastern United States……..14

1. Abstract……..15
2. Introduction……16
3. Materials and methods……17
4. Results……18
5. Discussion……..20
6. Appendix II.....……..25

CHAPTER III *Toxoplasma gondii* prevalence in waterfowl and gulls from eight states in United States……..28

1. Abstract……..29
2. Introduction……30
3. Materials and methods……31
4. Results……33
5. Discussion……..35
6. Appendix III……..44

CHAPTER IV *Toxoplasma gondii* prevalence in hunter-killed Mourning doves (*Zenaida macroura*) and Rock pigeons (*Columba livia*) from East Tennessee…….51

1. Abstract……..……52
2. Introduction …….……..52
3. Materials and methods……53
4. Results……...……53
5. Discussion…….……55

CHAPTER V Serological survey of *Toxoplasma gondii* in wild turkeys (*Meleagris gallapavo*) form southcentral Tennessee……..57

1. Abstract……..58
2. Introduction……59
3. Materials and methods……60

4. Results……61
5. Discussion……..62
6. Appendix V……...66

CHAPTER VI *Toxoplasma gondii* strain and dose effects on feed conversion rate, body weight, serum antibodies response and systemic distribution in intraperitoneally infected domestic turkey poults……68

1. Abstract……..69
2. Introduction……70
3. Materials and methods……71
4. Results……77
5. Discussion……..93
6. Appendix VI……101

CHAPTER VII Conclusion……..109

List of references……113

Vita……...136

LIST OF TABLES

Table II-1. Demographic data and counts of various carnivorous bird species tested for *Toxoplasma gondii* using modified agglutination test……...25

Table II-2. *Toxoplasma gondii* antibody titers and seroprevalence in wild bird species as tested by modified agglutination test……...26

Table III-1. *Toxoplasma gondii* PCR and MAT results of bird samples collected from Tennessee and Pennsylvania……...44

Table III-2. Data of bird samples collected from Arkansas, Georgia, Minnesota, Louisiana, New Jersey, Pennsylvania, Tennessee and Texas for *Toxoplasma gondii* testing……45

Table III-3. *Toxoplasma gondii* seroprevalence and modified agglutination test titers of wild bird species collected from Tennessee and Pennsylvania……47

Table III-4. *Toxoplasma gondii* seroprevalence and modified agglutination test titers of bird samples collected from Arkansas, Georgia, Minnesota, Louisiana, New Jersey and Texas…….48

Table III-5. Age and sex data for samples collected for *Toxoplasma gondii* testing……49

Table III-6. Seroprevalence of *T. gondii* in wild birds from eight different states from 2009 to 2019 using modified agglutination test……..50

Table V-1. Wild turkey serum samples tested for *Toxoplasma gondii* in southcentral Tennessee……...66

Table V-2. *Toxoplasma gondii* modified agglutination test antibody titers in wild turkeys…….67

Table VI-1. Experimental infection of domestic turkeys with two strains and doses of *Toxoplasma gondii*……...101

Table VI-2. Feed conversion rate (FCR) of the various *Toxoplasma gondii*-infected treatment and control groups of domestic turkeys……...102

Table VI-3. Count and percent of *Toxoplasma gondii* DNA positive tissues determined by qPCR in the various domestic turkey treatment groups……..……...103

Table VI-4. Frequency and percentage of qPCR positive tissues from *Toxoplasma gondii* infected domestic turkeys……..……..104

Table VI-5. Medians, maximum, and minimum of *Toxoplasma gondii* tachyzoites concentrations per mg of heart and brain tissues from experimentally infected domestic turkeys…….105

Table S-VI-1. Means and standard deviations of the weight (kg) for various treatment groups of domestic turkeys infected with *Toxoplasma gondii* or saline (controls)……..106

Table S-VI-2. Concentration of *Toxoplasma gondii* tachyzoites in 1mg tissue in various bird tissues.……...……...107

LIST OF FIGURES

Figure I-1. Life cycle and modes of transmission of *Toxoplasma* gondii ……..……6

Figure IV-1: Area of sample collection in East Tennessee……..……..54

Figure VI-1. The experiment timeline and points of blood and weight data collection and euthanasia of domestic turkeys infected with *Toxoplasma gondii*……..…….……..…...72

Figure VI-2. Floor pens where *Toxoplasma gondii*-infected domestic turkeys were raised from day 22 post infection until completion of experiment……..…….....74

Figure VI-3. Survival rates of domestic turkeys in various treatment groups following infection with two doses and two strains of *Toxoplasma gondii*…..…...……78

Figure VI-4. Difference in domestic turkey mean weights of all treatment groups in the first three timepoints 0dpi, 7dpi, 14dpi…….……80

Figure VI-5. A graph showing the difference in mean weight of domestic turkeys between groups GBb5, GTk5, GTk8 and control over the whole experiment time……..……..82

Figure VI-6. Difference between *Toxoplasma gondii* mean antibody titers tested by MAT between all domestic turkey groups at 0dpi and 7dpi……..……83

Figure VI-7. Difference between mean *Toxoplasma gondii* antibody titers of domestic turkey treatment groups GBb5, GTk5, GTk8, and control groups at all timepoints as tested by modified agglutination test……..……84

Figure VI-8. Percentage of *Toxoplasma gondii* DNA positive tissues from each treatment group……87

Figure VI-9. Establishment of a standard curve to quantify *T. gondii* tachyzoites in tissues of infected turkeys……..88

Figure VI-10. Gross lesions of domestic turkey 1221 in group GTK8 infected with *Toxoplasma gondii* ……...……90

Figure VI-11. Histological findings in turkeys experimentally infected with *Toxoplasma gondii* tachyzoites ...…… ……91

LIST OF ATTACHMENTS

Table VI-6. *Toxoplasma gondii* antibody titers of turkeys infected with different strains and doses of *T. gondii* as tested by modified agglutination test at different blood collection point during the experiment……Table VI-6.xlxs

CHAPTER I

Introduction.

1. Background and significance:

Toxoplasmosis is a zoonotic disease that effects a wide host range including humans and birds (Dubey, 2010b). The infection is caused by the apicomplexan parasite *Toxoplasma gondii* (Tenter et al., 2000) and it is estimated that one third of the human population has been infected with the parasite (Montoya and Liesenfeld, 2004) with a prevalence ranging from 4% in Korea to 92% in Brazil (Dubey, 2010b). The disease is usually asymptomatic in immunocompetent individuals (Dubey, 1996). The most common clinical signs are flu like symptoms, lymphadenopathy (Montoya and Liesenfeld, 2004) and ocular disease (Commodaro et al., 2009). However, toxoplasmosis can be a serious disease in immunocompromised individuals and pregnant women (Dubey, 2010b). Immunocompromised individuals including HIV infected patients can have severe meningoencephalitis (Happe et al., 2002) that can lead to death. Children born to pregnant women that contracted the infection for the first time during their pregnancy may present with congenital abnormalities including hydrocephalus, microcephaly, intracranial calcifications and chorioretinitis (Montoya and Liesenfeld, 2004). Abortions and stillbirths are also common in the first trimester in humans (Tammam et al., 2013) and animals (Edwards and Dubey, 2013) after contracting the infection.

2. History:

Toxoplasma gondii was accidently discovered in 1908 in the tissues of a Tunisian rodent, *Ctenodactylus gundi*, by Nicolle and Manceaux (1908). In 1909, Nicolle and Manceaux named the parasite, *Toxoplasma gondii* based on the morphology (from Greek: toxo=arc or bow, plasma=life) and the host *Ctenodactylus gundi* from which the parasite was first isolated (Ajioka and Morrissette, 2009; Nicolle and Manceaux, 1909). A similar microorganism was also described

around the same time in Brazil by Splendore in a laboratory rabbit (Splendore, 1908). In 1970, cats were identified as the definitive host of the parasite and the life cycle was described (Dubey et al., 1970; Frenkel et al., 1970). Recently, it was discovered that feline intestines are deficient in delta-6-desaturase, an enzyme required for linoleic acid metabolism and that unique property makes them the only mammal suitable for *T. gondii* sexual replication. Simulation of these circumstances in mice allowed for production of infective oocysts in mice feces (Martorelli Di Genova et al., 2019).

3. *Toxoplasma gondii,* the causative agent:

Toxoplasma gondii is a coccidian parasite that belongs to phylum Apicomplexa (Frenkel et al., 1970). The parasite is related to *Plasmodium*, *Isospora* and *Eimeria* species which are important protozoan diseases in humans and animals (Dobrowolski and Sibley, 1996; Dubey et al., 1970). *Toxoplasma gondii* was classified as a National Institute of Allergy and Infectious Diseases (NIAID) Category B priority agent after multiple waterborne outbreaks (Kim and Weiss, 2008). The parasite exists in mainly three infectious forms, oocysts containing sporozoites, tachyzoites and tissue cyst containing bradyzoites (Dubey, 2010b).

Oocysts are produced by members of the family Felidae which are the definitive host of the parasite (Dubey et al., 1970). The mechanism behind cats being the sole host that can harbor the sexual stages of the parasite is not completely understood but it is thought that the deficiency of Intestinal delta-6-desaturase activity in cats in comparison to other mammals plays the main role in this host determination (Martorelli Di Genova et al., 2019). Cats can shed millions of oocysts after 7-24 days of ingesting oocyst or tissue cyst and these produced oocysts are not infective until they sporulate in the environment (Dubey et al., 1970). Oocysts are environmentally resistant and keep

their infectivity for years in fresh water (Dumetre and Darde, 2003), seawater (Lindsay and Dubey, 2009) and soil (Ruiz et al., 1973). Oocysts contain sporozoites that convert to tachyzoites by endodyogeny about 12 hours after initial oocyst ingestion (Speer & Dubey, 1998). *Toxoplasma gondii* tachyzoites are the most fragile and less infective stage of the parasite (Dubey et al.,1998). Tachyzoites takes a crescent shape and measures about 2um X 6um (Dubey, 1996). They multiply by endodyogeny several times and protect themselves in a parasitophorous vacuole before they convert to bradyzoites (Dubey, 2004). Bradyzoites contained in tissue cyst, can persist for the entire life of the host and they exist in any nucleated cells in their hosts (Dubey, 1997). When immune status of the host is altered, tissue cysts can rupture releasing their content of bradyzoites that can convert into tachyzoites and causes acute symptoms (Dubey, 2010b; Dubey et al., 1998).

4. Significance of studying *T. gondii* in avian species:

Birds are intermediate hosts of *T. gondii* and play a role in maintaining the parasite's life cycle (Dubey, 2002). Felids, which are the only source of the oocysts in the environment, prey on birds and mammals, therefore studying *T. gondii* in birds is critical to understanding the parasite's lifecycle and transmission dynamics (Godoi et al., 2010). Detection of *T. gondii* oocysts in the environment is challenging even in areas of high contamination (Dumetre and Darde, 2003; Lass et al., 2009). Detection of *T. gondii* prevalence in ground feeding birds is used as an indirect way to determine the environmental contamination with the parasite (Dubey, 2010a). In addition to that, *T. gondii* infected game birds are a potential source of infection for humans if not handled and cooked properly (Kijlstra and Jongert, 2009).

5. Mode of transmission:

Toxoplasma gondii can be transmitted in various ways (Figure I-1) (Worth et al., 2013; Tenter et al., 2000). In birds, the mode of infection depends on the bird's feeding habits (Mancianti et al., 2013). Ground feeding birds are primarily infected through ingestion of sporulated oocyst in the environment and, less commonly, through the ingestion of small rodents or birds containing *T. gondii* tissue cysts (Dubey, 2002; Dubey et al., 1993a). Carnivorous birds including raptors primarily are infected with *T. gondii* through the ingestion of tissue cysts in their prey's tissues but also can be infected with oocysts through the ingestion of contaminated water (Dubey, 2008). Aquatic birds are thought to acquire the infection through the ingestion of contaminated water or filter feeders like small fish and mollusks (Conrad et al., 2005; Miller et al., 2002a). Although the transplacental migration of tachyzoites from mother to fetus in mammals is a common and important mechanism of transmission (Guha et al., 2017), there is little data on the transmission of the parasite through avian eggs and it is unknown if humans can get infected through the ingestion of raw eggs (Dubey, 2010a).

6. *Toxoplasma gondii* in birds:

Susceptibility of birds to *T. gondii* varies by species (Work et al., 2000). Although subclinical toxoplasmosis infections are common in many avian species, it can be clinically severe in some species including pigeons and canaries (Dubey, 2002). Fatal clinical toxoplasmosis was reported previously in various bird species, including the Hawaiian 'Alala (*Corvus hawaiiensis*) (Work et al., 2000), wild turkeys (*Meleagris gallapavo*) (Quist et al., 1995; Howerth and Rodenroth, 1985), Valley quail (*Callipepla californica*) (Casagrande et al., 2015), kereru (*Hemiphaga novaeseelandiae*), North Island brown kiwi (*Apteryx mantelli*), North Island kaka

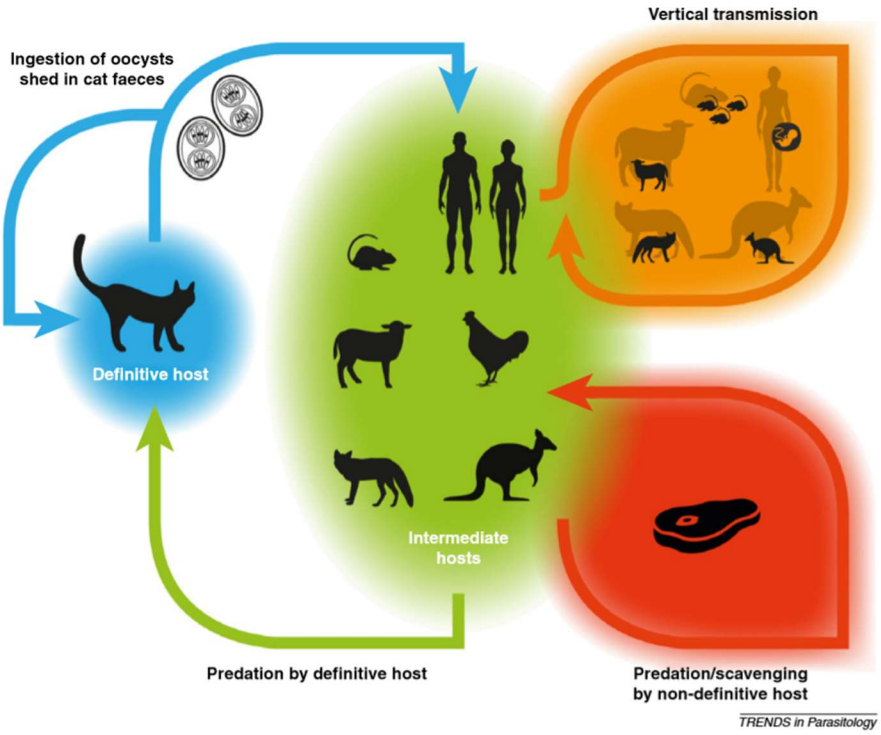

Figure I-1. Life cycle and modes of transmission of *Toxoplasma gondii* (Worth et al., 2013)

(*Nestor meridionalis*), (Howe et al., 2014), Vinaceous Amazon Parrot (*Amazona vinacea*) (Ferreira et al., 2012), red lory (*Eos bornea*) (Howerth et al., 1991), red-bellied woodpecker (*Melanerpes carolinus*) (Gerhold and Yabsley, 2007), Great Spotted Woodpecker (*Dendrocopos major*) (Jokelainen and Vikoren, 2014) and bald eagle (*Haliaeetus leucocephalus*) (Szabo et al., 2004).

Subclinical *T. gondii* infections in birds can be detected by several diagnostic methodologies. Several studies were performed on birds to detect *T. gondii* seroprevalence (Darwich et al., 2012). Dubey compiled all the data published on wild bird species affected, sampling location, diagnostic test used, numbers tested, and the prevalence reported (Dubey, 2002). He also reviewed and compiled the publications on chicken toxoplasmosis in another review publication (Dubey, 2010a). In brief, *T. gondii* can infect numerous birds and reports on the prevalence vary by bird species, geographical location, test used, cat and bird population densities in the area, the frequency of predation cycle and *T. gondii* dose and strain (Gilot-Fermont et al., 2012; Dubey, 2002).

Birds are used as laboratory animals to conduct *T. gondii* experimental infections because they are easy to handle and results of these experiments can be applied to other animals (Maksimov et al., 2018). Experimental infections in birds can be performed by oral inoculation of sporulated oocysts previously excreted by cats (Godoi et al., 2010; Dubey et al., 1993a), through ingestion of tissue cysts (Vitaliano et al., 2010) or through injection of tachyzoites intravenously (Hotop et al., 2014), intraperitoneally (Wang et al., 2014b) or intramuscularly (Zoller et al., 2013). Experimental infections are useful tools in determining *T. gondii* pathogenesis and infectivity. They can be controlled to investigate tissue tropism (Zoller et al., 2013) and the humoral and innate immune response (Hotop et al., 2014; Dubey et al., 1997) to

different *T. gondii* strains and doses. They are also valuable in testing different treatments (Rodriguez and Szajnman, 2012) and in validating diagnostic tests (Dubey et al., 1993a).

7. Diagnosis of *T. gondii* infection in birds:

Because *T. gondii* infection is commonly a subclinical disease in birds and clinical signs are not specific, when clinical, diagnosis cannot be confirmed unless a laboratory test is used (Dubey, 2002). Diagnosis can be performed various ways including serological, histological, molecular, biological or immunochemical methods (Dubey, 2008).

Modified agglutination test (MAT) is the most widely used serological test for detection of *T. gondii* IgY in bird sera. The test is easy, economic and rapid (Dubey, 2010b). The test uses whole formalin fixed *T. gondii* tachyzoites as an antigen and 2-mercaptoethanol for destruction of the non-specific IgM, thus the test is suitable only for detecting non-acute infections. Serum samples are tested with MAT after two-fold dilution with phosphate buffered saline (PBS) (Dubey, 2010b). Dilutions traditionally started at 1:25 dilutions, but recently *T. gondii* was isolated from birds positive at a 1:5 dilution (Cong et al., 2013; Dubey et al., 2006). MAT was validated in chickens (Dubey et al., 2016) and has been proven useful in many other bird species (Godoi et al., 2010; Dubey, 2002; Dubey et al., 1993a). Sensitivity of MAT in chickens was 76% which was lower than ELISA and IFAT in the same study, however, the MAT has the advantage of not requiring a specific conjugate as in ELISA and IFAT (Casartelli-Alves et al., 2014).

Sabin–Feldman dye test (DT) is highly sensitive when used with human sera (Udonsom et al., 2010), however, this is not the case with birds (Dubey, 2010b). *Toxoplasma gondii* was isolated from DT negative chicken and sparrows (Dubey et al., 1993b; Ruiz and Frenkel, 1980). Dye test is a complement mediated test which may account for the insensitivity in birds compared

to mammals (Frenkel, 1981). Live tachyzoites are used in DT which represents a major disadvantage due to the biohazard concern and the test needs to be done by highly experienced personnel (Dubey, 2010b).

Indirect hemagglutination test (IHAT) is insensitive for detection of *T. gondii* in birds (Dubey et al., 1993b). Casartelli-Alves et al. (2014) dettermined a sensitivity of 61% and specificity 80% of IHAT when used in chickens. Although Dubey et al. fed chickens *T. gondii* oocysts and isolated the parasite from their tissues by mice bioassay, they could not detect antibodies by IHAT (Dubey et al., 1993b).

Indirect fluorescent antibody test (IFAT) is more commonly used in humans than birds or mammals because it requires a species-specific conjugate (Dubey, 2010b). The test has a sensitivity of 80% and a specificity of 52% when used in chickens (Casartelli-Alves et al., 2014). *T. gondii* was isolated from two chickens that tested negative by IFAT (Brandao et al., 2006). However, Godoi et al. (2010), suggested that IFAT can be used as a reliable method for detection of anti-*T. gondii* antibodies in gallinaceous birds and its results agrees with MAT.

Enzyme-Linked Immunosorbent Assay (ELISA) is an attractive test to use in chickens to test for *T. gondii* antibodies especially with large numbers of samples (Schares et al., 2018; Casartelli-Alves et al., 2014). The ELISA had a sensitivity of 87.5% and a specificity of 86.2% in chickens (Schares et al., 2018). There are different types of ELISA that can test IgM or IgG in various mammals and birds (Dubey, 2010b).

Serological tests are useful in detection of exposure to the infection and does not relate to the clinical disease or to the viability and infectiousness of the parasite causing the infection (Dubey, 2008). **Histopathology, immunohistochemistry and mouse bioassay** are considered the

gold standard tests for detection of *T. gondii* infections. They are highly specific but less sensitive than serological tests (Casartelli-Alves et al., 2014; Dubey, 2008). One of the most valuable diagnostic methods is passage and isolation of *T. gondii* from a sensitive, *Toxoplasma* negative mammal (interferon gamma knocked out mouse or golden hamster) and the demonstration of antibodies or developmental stages of the parasite *T. gondii* (Schares et al., 2018). Successful isolation is dependent on the number of mice inoculated, amount of tissue used and parasite concentration in tissue samples (da Silva and Langoni, 2001).

Molecular detection of toxoplasmosis usually depends on detection of specific DNA sequences from highly conserved regions such as the B1 gene which is repeated 35 times in the genome, 529 bp repetitive element with about 200-300 copies in the genome, ITS-1 (internal transcribed spacer) that is found in 110 copies and 18S rDNA gene sequences (Ivović et al., 2012).

Targeting the B1 gene for the detection of *T. gondii* was developed by Burg et al. (1989). The function of the B1 gene is unknown but it is used in diagnosis and epidemiological studies because of its specificity and sensitivity (Ivović et al., 2012; Burg et al., 1989). The B1 gene has a high sensitivity and can be detected directly from a crude cell lysate. It was detected from purified DNA samples containing as few as 10 parasites in the presence of 100,000 human leukocytes. The B1 gene is also highly specific and could not be detected for a variety of other organisms (Burg et al., 1989). These characteristics give this gene a very important role in *T. gondii* detection and genotyping.

The 529 bp repetitive element was first identified by Homan and showed a 10 to 100 times higher sensitivity compared to the B1 gene (Reischl et al., 2003; Homan et al., 2000). Because of

this high sensitivity, the 529bp repetitive fragment is the most preferred marker for *Toxoplasma* detection and diagnosis (Edvinsson et al., 2006).

Genotyping is very important in studies of the population biology of *T. gondii* and in epidemiological studies as it greatly helps in the detection and identification of an infection source. There may be a strong correlation between genotypes and the clinical disease pattern, so recent research has focused on using molecular biological tools in *T. gondii* infection for diagnosis, epidemiology and strain typing (Switaj et al., 2005).

Multilocus restriction fragment length polymorphism (PCR-RFLP) genotyping is considered the method of choice in epidemiological research because of its simplicity and low cost (Ivović et al., 2012; Su et al., 2006). Studies of *T. gondii* population structure and genotyping was previously performed using a single marker, mostly SAG2, and sometimes combined with GRA6. However, genotyping with one or two markers is not useful in determination of non-clonal strains. Multiple markers are preferred although sometimes insufficient amounts of extracted parasite DNA may make this method impractical. To have the best results, genotyping should be performed using a set of PCR-RFLP genetic markers including SAG1, SAG2, alt.SAG2, SAG3, BTUB, GRA6, c22-8, c29-2, L258, PK1, CS3 and Apico (Shwab et al., 2014; Ivović et al., 2012 and Dubey et al., 2007). PCR-RFLP allowed for the detection of different *Toxoplasma* genotypes. Genotype #1 (Type II clonal), #2 (Type III), #3 (Type II variant) and #10 (Type I) are identified globally. Genotypes #2 and #3 dominate in Africa, genotypes #9 (Chinese 1) and #10 are prevalent in Asia and genotypes #1, #2 and #3 are prevalent in Europe. Genotypes 1, 2, 3 and 12 are the dominant genotypes in North America and there is not a dominant genotype in Central and South America. (Shwab et al., 2014).

8. Aims and conclusion:

Toxoplasma gondii infection is widespread in humans (Tenter et al., 2000). Although typically asymptomatic, it can represent a life-threatening disease in some cases, particularly immunosuppressed people (Montoya and Liesenfeld, 2004). The risk of infection can be minimized in humans by basic hygienic measures and proper meat handling and preparation. Toxoplasma diversity was lowest near human settlements (Jiang et al., 2018); however, expansion to human- uninhabited forests increases the contact between humans, domestic and wild animals which has implications on the diversity and virulence of the parasite (Shwab et al., 2018). Investigating T. gondii prevalence in wildlife is crucial to understanding the parasite's life cycle, transmission dynamics, and public health risk (Gerhold et al., 2017). Many wildlife species are harvested for human consumption and research confirmed the presence of T. gondii in these game animals (Gerhold et al., 2017; Hollings et al., 2013). Birds represent a major sector of wild game animals and they are also important T. gondii intermediate hosts (Dubey, 2002). In our study, we aim to investigate the prevalence of T. gondii infection in wild birds in Tennessee and surrounding states by modified agglutination test (MAT) and molecular techniques to understand the epidemiology and ecology of T. gondii in wildlife. We tested 28 wild bird species and detected a T. gondii prevalence of 27.4% (308/1124) using different methods. Mice bioassay and genotyping of the parasite was attempted when possible to add to the growing data set on the parasite diversity in wild animals. We successfully isolated viable T. gondii tachyzoites from one red-shouldered hawk (Buteo lineatus) and genotyped it using PCR-RFLP of ten genetic markers (TgHawkFL1, ToxoDB PCR-RFLP genotype #28). An experimental infection using T. gondii tachyzoites was performed to investigate the seroconversion, feed conversion rate, weight gain and T. gondii tissue tropism in domestic turkeys (Meleagris gallapavo) in relation to the parasite dose and virulence.

We recorded an increase in FCR and a decrease in bird weight gain and survival rate with increase of T. gondii dose and virulence. Gross and histological lesions corresponded to the dose and strain of T. gondii used. Future research on the mechanisms of infection of various species of wild birds, although they differ in habitat and feeding habits, will elucidate the unique mechanisms of success of the parasite in the wild and may help in the development of control strategies in humans. Education of the public about zoonotic diseases such as toxoplasmosis, and the ability to prevent them by basic hygienic measures is crucial to moving toxoplasmosis from being a neglected parasitic disease to a well understood disease by the public.

CHAPTER II

Toxoplasma gondii **prevalence in carnivorous wild birds in the eastern United States.**

Sawsan Ammar[1,6], Liberty Wood[1], Chunlei Su[2], Maria Spriggs[3], Justin Brown[4], Kyle Van Why[5], Richard Gerhold[1]

[1]Department of Biomedical and Diagnostic Sciences, College of Veterinary Medicine, University of Tennessee, Knoxville TN. [2] Microbiology Department, University of Tennessee, Knoxville, TN. [3] Busch Gardens, Tampa, Florida. 5Pennsylvania Game Commission, Harrisburg, PA. [5]USDA APHIS Wildlife Services, Harrisburg, PA. [6]Department of Clinical Pathology, Faculty of Veterinary Medicine, Sadat City University, Sadat City, Menofia, Egypt.

1. Abstract:

Toxoplasma gondii is an important zoonotic protozoan parasite that infects all warm-blooded animals including mammals and birds. Raptors can be intermediate hosts for *T. gondii* and represent an excellent indicator of environmental contamination of the parasite given their predatory and scavenging behavior. We investigated the seroprevalence of *T. gondii* in ten raptor species from Florida, Pennsylvania and Tennessee followed by parasite bioassay on select seropositive samples. From a total of 155 raptors, we detected *T. gondii* antibodies using modified agglutination test (cutoff 1:25) in 32 (20.6%) birds. There was a *T. gondii* seroprevalence of 44.8% in Falconiformes (13/29), 75% in Strigiformes (15/20) and 3.8% in Ciconiiformes (4/106). All the vulture samples (Ciconiiformes) were collected from Pennsylvania while the rest of the raptors were from Tennessee and Florida. There was no significant difference between TN and FL in the seroprevalence of *T. gondii* in the tested raptors. There was also no statistically significant difference between males and females or adults and subadults in exposure to the infection. Mice bioassay attempts using fresh brain and/or heart

tissue was performed on four seropositive birds. We successfully isolated viable *T. gondii* tachyzoites from one red-shouldered hawk (*Buteo lineatus*) and genotyped the isolate using PCR-RFLP of ten genetic markers. The isolated strain was designated as TgHawkFL1, which is ToxoDB PCR-RFLP genotype #28. Further research is needed to investigate the prevalence of *T. gondii* in raptors in the U.S. to obtain a better understanding of life cycle, wildlife population impacts, and transmission dynamics of the parasite.

2. Introduction:

Toxoplasma gondii is a protozoan parasite capable of infecting all mammals and birds (Dubey, 2010). The parasite is distributed worldwide and can cause severe clinical disease in immunocompromised individuals and unborn fetuses (Tenter, Heckeroth, & Weiss, 2000). *Toxoplasma gondii* oocysts, which are produced by the feline definitive host, are widely distributed in the environment including water bodies (Adamska, 2018; Aramini et al., 1999) and soil (Wang et al., 2014; Frenkel, Ruiz, & Chinchilla, 1975). Investigating the level of environmental contamination with *T. gondii* oocysts is crucial to understand the parasite life cycle and transmission.

An indirect technique of determining *T. gondii* distribution in the environment is through detecting the parasite prevalence in intermediate hosts. Rodents and birds play an important role as intermediate hosts in *T. gondii* life cycle because they are the main source of infection for several feline definitive hosts (Love et al., 2016; Gilot-Fromont et al., 2012). These small vertebrates also serve as a food source for carnivorous birds. For example, one kestrel pair can consume about 520 small vertebrates in a breeding season (Geng et al., 2009). We hypothesized that raptors would be an excellent indicator of environmental contamination of *T. gondii* given their predatory and scavenging behavior (Love et al., 2016). To this end, we aimed to estimate

the seroprevalence of *T. gondii* in various raptor species and attempted to isolate the parasite from select seropositive birds to elucidate the epidemiology, ecology and diversity of *T. gondii* in wildlife.

3. Materials and methods:

During 2016-2018, a total of 155 raptor carcasses or tissue samples representing ten different avian species (Table II-1) were collected from the University of Tennessee College of Veterinary Medicine exotics clinic, Knoxville, Tennessee, or shipped from Busch Gardens Rehabilitation Center in Tampa, Florida, or collected in Pennsylvania. Data were collected on birds' clinical history, age, sex, and county of origin.

Except for the two vulture species which we received serum and heart tissue only, raptor carcasses were grossly examined for any lesions. Heart blood and heart and brain tissues were collected and stored at 4° C until the modified agglutination test (MAT) result were obtained. The MAT was performed on all raptor serum samples as previously described (Desmonts & Remington, 1980). Sera were two-fold diluted starting at 1:25 followed by addition of formalin fixed whole tachyzoites. The plate was incubated overnight at 37C. Titers equal or higher than 1:25 were considered positive.

Mice bioassays was performed on four seropositive samples including two Eastern screech owls (*Megascops asio*) with antibody titers of 1:100 and two Red-shouldered hawks (*Buteo lineatus*) with antibody titers of 1:400 and ≥3200. Brain and heart tissues were pooled and processed for mice bioassay as previously described (Dubey, 1998). Two mice were used per each bird bioassay trial. Dexamethasone (15ul/ml) was administrated in drinking water to suppress the immune system and facilitate the parasite isolation in mice. Mice were euthanized

when they displayed clinical signs of *T. gondii* infection or at three weeks post infection. Peritoneal lavage of clinically ill mice was collected and seeded on cell culture. Propagated tachyzoites on cell culture, from mice peritoneal fluid, were purified and genotyped by multiplex multilocus nested PCR-RFLP using 10 different genetic markers (Su et al., 2010). Mice that manifested no clinical signs at 21 days post infection were bled and tested via MAT to determine if they were sero- positive or negative for *T. gondii* antibodies.

Statistics were performed using SPSS version 25 statistical package. The chi squared test was performed to detect if a difference in exposure to the parasite between order, age and sex categories was evident. The chi squared test was also performed to determine the *T. gondii* seroprevalence difference between Strigiformes and Falconiformes and an odds ratio was calculated. Because only vulture samples were collected from Pennsylvania, we only examined *T. gondii* exposure via chi-squared test between Tennessee and Florida. All tables are located in appendix II.

4. Results:

From a total 155 birds, 32 (20.6%) *T. gondii* seropositive birds were obtained using MAT. Strigiformes had significantly (p= .04) higher seroprevalence of 75% (15/20) followed by Falconiformes with 44.8% (13/29) *T. gondii* seroprevalence. Ciconiiformes had significantly lower *T. gondii* seroprevalence of 3.8% (4/106). Odds ratio was calculated for Strigiformes and Falconiformes and the results showed that Strigiformes are 3.7 times more likely to be seropositive than Falconiformes (OR=3.69). Barred owls *(Strix varia)* had the highest *T. gondii* seroprevalence of 77.8% (7/9) while Turkey vultures (*Cathartes aura,* N=2), Ospreys (*Pandion haliaetus*, N=2) and a sharp-shinned hawk (*Accipiter striatus,* N=1) had 0% seroprevalence. (Table II-2). Barred owls *(Strix varia)*, Eastern screech owls and red-shouldered hawk had

significantly higher *T. gondii* seroprevalence than other species while Black vultures (*Coragyps atratus)* had a significantly lower *T. gondii* seroprevalence (p<.001). There was no significant difference between males (18/89) and females (13/65) with both having a *T. gondii* seroprevalence of 20% (p=1.0). We had only 32 birds with known age data. After running chi squared test, there was no significant difference between adults (14/21, 66.7%) and subadults (6/11, 54.5%) in exposure to *T. gondii* infection (p=0.7).

Samples were collected from three different states (Table II-1). All the vultures were collected from Pennsylvania and they had a seroprevalence of 3.8% (4/106). The four birds that were *T. gondii* seropositive were all black vultures. There was a *T. gondii* seroprevalence of 53.3% (8/15) in Tennessee raptors and 57% (20/35) in Florida raptors and there was no statistical difference in *T. gondii* seroprevalence between raptors originating from the two states (p=1.0).

Mice bioassay was performed on four positive samples including two Eastern screech owls (*Megascops asio*) and two Red-shouldered hawks (*Buteo lineatus*). *Toxoplasma gondii* was isolated from one Red-shouldered hawk sample with an antibody titer >3200. Genotyping revealed ToxoDB PCR-RFLP genotype #28 genotype. This bird was euthanized April 4th, 2017, necropsied on April 25th and a mouse bioassay performed on the first of May. The mice were asymptomatic two weeks post infection. On May 27th, one mouse displayed clinical signs. The mouse was euthanized, and the peritoneal lavage was seeded on cell culture to maintain the *T. gondii* strain. In a second red shouldered hawk sample (MAT =1:400), mice bioassay trials were terminated on the second day post injection due to severe reaction in the mice. Although two screech owls tested positive by MAT (1:100), mice bioassays were unsuccessful for both birds.

5. Discussion:

The present study documented a prevalence of 20.6% in various species of raptors using MAT (cutoff 1:25). Strigiformes (Owls) had a significantly higher seroprevalence of 75% (15/20) followed by Falconiformes (Hawks and Ospreys) with a 44.8% (13/29) *T. gondii* seroprevalence, while Ciconiiformes (Vultures) had the lowest *T. gondii* seroprevalence of 3.8% (4/106).

Raptors serve as an intermediate host in the *T. gondii* complex life cycle (Atkinson et al., 2008). They are primarily infected via ingestion of small rodents and birds that harbor tissue cysts (Lindsay et al., 1993). This is similar to the mode of infection for felines which are the only host producing the resistant oocyst in the environment (Dubey et al., 1992). For this reason, birds of prey are considered an excellent indicator of environmental contamination with the parasite and represents an excellent technique to examine *T. gondii* epidemiology and sylvatic transmission (Dubey et al., 2010).

Raptors are considered resistant to toxoplasmosis (Dubey et al., 1992; Lindsay et al., 1991) and only one clinical case was reported in a bald eagle and confirmed by immunohistochemistry (Szabo et al., 2004). That may not be surprising given these birds are carnivorous and scavengers and frequently ingest infected prey and carrion which requires unique defense mechanisms. This is supported by the results obtained from testing vultures in the present and previous studies (Lindsay et al., 1993). Vultures have a strongly acidic stomach environment and a unique intestinal microbiota that protect them from common pathogens and bacterial toxins present in degraded carcasses (Roggenbuck et al., 2014; Waite and Taylor, 2015). Their intestines are dominated by *Clostridia* and *Fusobacteria* and have a lower bacterial diversity than their facial skin (Roggenbuck et al., 2014). This suggests that most of the bacteria

and pathogens ingested with their decayed food do not survive their intestinal environment (Waite and Taylor, 2015).

Since toxoplasmosis is a food borne disease (Mead et al., 1999), feeding habits play an important role in controlling the level of exposure to the parasite in various bird species. Although ingestion of the tissue cyst is the most common mode of infection in carnivorous birds, they also can be infected through direct ingestion of the oocysts (Dubey, 2002; Lindsay et al., 1993) present in contaminated water (Adamska, 2018), soil (Wang et al., 2014; Frenkel et al., 1975) or insects (Frenkel et al., 1975; Wallace, 1973). Two ospreys (*Pandion haliaetus)*, which feed mainly on fish (Poole, 2019; Häkkinen, 1978), tested negative for *T. gondii* antibodies in the present study. These results are in agreement with Lindsay et al., (1993) who were not able to isolate the parasite by mice bioassay from 4 ospreys and Love et al., (2016) who tested one osprey by MAT and it was negative. Owls and hawks have more diverse feeding habits than ospreys and had a higher *T. gondii* seroprevalence in the present study and previous reports (Love et al., 2016). Owl gizzards examined on necropsy in the present study often contained balls of fur and some of them had bones suggestive of small rodents. One seropositive red-shouldered hawk stomach was full of undigested insect pieces and insects have been proven to mechanically transport *T. gondii* (Wallace, 1973).

None of the birds sampled in the present study had clinical signs suggestive of toxoplasmosis. However, the fact that these birds were admitted to a rehabilitation clinic may reflect the presence of subclinical disease due to *T. gondii* in raptors that may predispose them to trauma; however, further research is needed to determine if this is true. Most of the bird carcasses examined had various fractures and one was hit by a car (MAT titer was 1:25).

Although *T. gondii* infection in raptors has been reported from all over the world (Gazzonis et al., 2018; Gennari et al., 2017; Aubert et al., 2008; Dubey, 2002), few studies have been performed in the United States and most of them consisted of opportunistic samples (Gerhold et al., 2017; Love et al., 2016; Yu et al., 2013; Dubey et al., 2010; Lindsay et al., 1993). Studies with larger sample sizes and representative samples of birds from various locations, health condition, and feeding habits are required to better understand the disease epidemiology and ecology.

Nevertheless, prevalence of toxoplasmosis in birds is likely underestimated (Lindsay et al., 1991) and that is due to the absence of an effective, sensitive and specific serological test in birds (Frenkel, 1981). We used MAT with cutoff of 1:25 to detect *T. gondii* antibodies in serum of sampled raptors. Direct agglutination test using formalin fixed tachyzoites was proven useful in Red-tailed Hawks at 1:20 as a cutoff point (Lindsay et al., 1991). MAT has been validated for use in chickens (Dubey et al., 2016) and is thought to be a specific and sensitive test for detecting *T. gondii* antibodies in birds (Dubey, 2002).

Mice bioassay, cell culture and immunohistochemistry are considered the gold standard tests for diagnosis of infections with *T. gondii* in mammals and birds (Liu et al., 2015; Atkinson et al., 2008). However, limitation on the amount of tissues used for mice inoculation make it difficult to confirm the negative result of a bioassay (Lindsay et al., 1993). Using heart and brain tissues aid in increasing the success of the mice bioassay because studies showed these tissues are most frequently infected by the parasite (Sarkari et al., 2014; Dubey et al., 1993). Also, samples from mammals or birds with higher MAT titers have greater success when used in mice bioassay trials (Gerhold et al, 2017). We were not able to isolate the parasite from the two eastern screech owls and both had MAT titers of 1:100. We were able to isolate the parasite from

a red-shouldered hawk by mouse inoculation of heart and brain tissues of the seropositive bird (MAT titer >3200). Even though the bird was euthanized four weeks before inoculating the mice, we tried the mouse bioassay on this bird because it had a higher MAT titer compared to other birds tested. The bird was refrigerated in a sealed bag and shipped after euthanasia. The heart and brain were kept at 4C in a sealed ziplock following necropsy on the 25th of April and the mouse inoculation was performed a week later. It is possible that the bird tissues were overwhelmed with tissue cysts and a few cysts survived in these tissues for the four week period at 4C. Refrigerating the whole unopened carcass may have increased the parasite persistence in tissue but this needs to be researched further.

Mice inoculated for bioassay with *T. gondii* infected tissues should be kept for 6-8 weeks prior to termination (Hill and Dubey, 2002). The mouse utilized for the bioassay of the seropositive red-shouldered hawk displayed clinical signs four weeks after the initial infection. We do not know if this is due to the duration of bird tissues processing before the inoculation or factors related to the mouse immunity or *T. gondii* strain. Further testing is needed to determine how these biotic and abiotic factors may be associated with parasite persistence and infectivity.

The isolated strain from the red-shouldered hawk was designated as TgHawkFL1, and it is ToxoDB PCR-RFLP genotype #28. ToxoDB#28 was previously isolated form cat brain in Mexico (Rico-Torres et al., 2015). *Toxoplasma gondii* type I (ToxoDB#10) was previously isolated from a red-shouldered-hawk in Alabama (Yu et al., 2013). An additional eight isolates were obtained from red-shouldered-hawks from Alabama; however, no genotyping data are available for these isolates (Lindsay et al., 1993).

In conclusion, infection with *T. gondii* is common in various raptor species depending on their preferred diet and we isolated one *T. gondii* strain (ToxoDB#28) from a red-shouldered

hawk from Florida. More research is needed to determine the overall prevalence and diversity of *T. gondii* in raptors and elucidate the potential wildlife population impacts to these avian species. It is also important to educate the public about the risks of predation and scavenging of pet and free-roaming cats on wildlife and alert them to zoonotic diseases that have the potential to be transmitted. Furthermore it is important that we educate the public on the substantial negative impact that cats have on native birds and mammals and to advocate for owners to keep pet cats indoors (Nuwer, 2013).

7. Appendex II:

Table II-1. Demographic data and counts of various Carnivorous bird species tested for *Toxoplasma gondii* using Modified agglutination test.

Order	Host	Total number tested	Birds from Pennsylvania	Birds from Tennessee	Birds from Florida	M/F(Unknown)	Adult/subadult (Unknown)
Falconiformes	**Osprey** *Pandion haliaetus*	**2**	**0**	**1**	**1**	**2/0**	**1/1**
	Cooper's Hawk *Accipiter cooperii*	**5**	**0**	**3**	**2**	**2/3**	**1/2 (2)**
	Red-shouldered Hawk *Buteo lineatus*	**18**	**0**	**3**	**15**	**13/5**	**7/5 (6)**
	Red-tailed Hawk *Buteo jamaicensis*	**3**	**0**	**2**	**1**	**2/1**	**0/1 (2)**
	Sharp-shinned Hawk *Accipiter striatus*	**1**	**0**	**0**	**1**	**1/0**	**1/0**
Strigiformes	**Barred Owl** *Strix varia*	**9**	**0**	**3**	**6**	**1/8**	**6/1 (2)**
	Great Horned Owl *Bubo virginianus*	**3**	**0**	**1**	**2**	**3/0**	**3/0**
	Eastern Screech-Owl *Megascops asio*	**8**	**0**	**1**	**7**	**5/2 (1)**	**2/1 (5)**
Ciconiiformes	**Black Vulture** *Coragyps atratus*	**104**	**104**	**0**	**0**	**58/46**	**0/0 (104)**
	Turkey Vulture *Cathartes aura*	**2**	**2**	**0**	**0**	**2/0**	**0/0 (2)**
Total		**155**	**106**	**14**	**35**	**89/65 (1)**	**21/11 (123)**

*Classification of the bird species into orders is adapted from (Alsop, 2006)

*M/F is male to female counts

Table II-2. *Toxoplasma gondii* antibody titers and seroprevalence in wild bird species as tested by modified agglutination test

Order	**Host**	***N***	**MAT titers**									**Seroprevalence (%)**
			<1:25	**1:25**	**1:50**	**1:100**	**1:200**	**1:400**	**1:800**	**1:1600**	**>1:3200**	
Falconiformes	**Osprey** *Pandion haliaetus*	**2**	2	0	0	0	0	0	0	0	0	**0**
	Cooper's Hawk *Accipiter cooperii*	**5**	3	0	2	0	0	0	0	0	0	**40**
	Red-shouldered Hawk *Buteo lineatus*	**18**	8	2	4	1	0	2	0	0	1	**55.6**
	Red-tailed Hawk *Buteo jamaicensis*	**3**	2	0	0	1	0	0	0	0	0	**33.3**
	Sharp-shinned Hawk *Accipiter striatus*	**1**	1	0	0	0	0	0	0	0	0	**0**
Strigiformes	**Barred Owl** *Strix varia*	**9**	2	2	4	1	0	0	0	0	0	**77.8**
	Great Horned Owl *Bubo virginianus*	**3**	1	0	2	0	0	0	0	0	0	**66.7**
	Eastern Screech-Owl *Megascops asio*	**8**	2	2	2	2	0	0	0	0	0	**75**

Table II-2. (continued)

Order	**Host**	***N***	**MAT titers**									**Seroprevalence (%)**
			<1:25	**1:25**	**1:50**	**1:100**	**1:200**	**1:400**	**1:800**	**1:1600**	**>1:3200**	
Ciconiiformes	**Black Vulture** *Coragyps atratus*	**104**	100	2	2	0	0	0	0	0	0	**3.8**
	Turkey Vulture *Cathartes aura*	**2**	2	0	0	0	0	0	0	0	0	**0**

*Classification of the bird species into orders is adapted from (Alsop, 2006).

CHAPTER III

Toxoplasma gondii **prevalence in waterfowl and gulls from eight states in United States.**

Sawsan Ammar[1,7], Tania Dawant[1], Janetta Kelly[2], Graham Hickling[2], Justin Brown[3], Kyle Van Why[4], Dave Stallknecht[5], Rebecca Poulson[5], Chunlei Su[6], and Richard Gerhold[1].

[1]Department of Biomedical and Diagnostic Sciences, College of Veterinary Medicine, University of Tennessee, Knoxville, TN. [2] Department of Forestry, Wildlife, and Fisheries, University of Tennessee, Knoxville, TN. [3]Pennsylvania Game Commission, Harrisburg, PA. [4]USDA APHIS Wildlife Services, Harrisburg, PA. [5]Southeastern Cooperative Wildlife Disease Study, College of Veterinary Medicine, The University of Georgia, Athens, GA. [6] Department of Microbiology, University of Tennessee, Knoxville, TN. [7]Department of Clinical Pathology, Faculty of Veterinary Medicine, Sadat City University, Sadat City, Menofia, Egypt.

1. Abstract:

Toxoplasmosis is a zoonotic disease caused by the protozoan parasite *Toxoplasma gondii* which infects mammals and birds. We tested a total of 391 serum samples from 14 wild bird species collected from 2009 to 2019 from eight different states for *T. gondii* antibodies using the modified agglutination test (MAT) and found a seroprevalence of 50.1% (196/391). In addition, PCR was performed on heart tissues from 72 gull and waterfowl samples from Pennsylvania and Tennessee and a prevalence of 13.9% (10/72) was documented. Tennessee, Pennsylvania and Arkansas had significantly higher *T. gondii* seroprevalences of 69.2% (27/39), 78.3% (18/23), and 80% (16/20) respectively while Texas had a significantly lower seroprevalence of 28.9% (24/83). Ring-billed gulls (78.3%, 18/23) and hooded merganser (100%, 9/9) had a significantly higher *T. gondii* seroprevalence while the blue winged teal had a significantly lower prevalence (25.6%, 23/90) than the rest of the species tested. Seroprevalence was not significantly different between adults (50.8%, 124/244) and juveniles (48%, 61/127), while females (60%, 87/145) had

a higher *T. gondii* seroprevalence than males (45.1%, 96/213). Further research is needed to elucidate the transmission dynamics of *T. gondii* in waterfowl, gulls and other aquatic animals and determine the zoonotic risk.

2. Introduction:

Toxoplasma gondii is a protozoan parasite and is the second most common food borne illness causing human mortalities in the United States (Scallan et al., 2011; Tenter et al., 2000). The parasite is successful in infecting all warm-blooded animals including mammals and birds; however, *T. gondii* can only sexually replicate in the intestinal tract of felids which excrete the oocysts in their feces (Dubey, 2010b).

Wild birds have proven to be an effective tool at dispersing various pathogens between different geographical areas (Cabezon et al., 2016; Jourdain, et al, 2007; Fischer et al, 1997). Migratory geese have been recently suspected in the transmission of the zoonotic parasite *T. gondii* to arctic foxes and polar bears in feline free environments (Sandstrom et al., 2013). Understanding the role of wild birds in the transmission of *T. gondii* is of interest to better understand the parasite epidemiology and zoonotic risk (Mancianti et al., 2013).

Gulls are opportunistic feeders which are commonly seen scavenging on sewage or in landfills (Cabezon et al., 2016). Waterfowl are potentially exposed to *T. gondii* via several sources including runoff from rain events carrying the oocysts into aquatic ecosystems as previously seen with various aquatic mammals (Johnson et al., 2009; Conrad et al., 2005). These avian species are important intermediate hosts for *T. gondii* as they can be predated or scavenged leading to *T. gondii* transmission (Miao et al., 2014). Studying the feeding habits, migratory

behavior as well as their *T. gondii* prevalence in various avian species will elucidate the transmission dynamics of the parasite.

Birds can be infected with sporulated oocysts by foraging or ingesting contaminated water or feed, or by ingestion of the tissue cysts (Cabezon et al., 2016). Numerous waterfowl species are migratory, making it difficult to detect the source of the infection and can lead to an increased geographical distribution of the parasite. Given numerous waterfowl species are game birds, *T. gondii* infection of these avian hosts represents a substantial public health risk. Ring-billed gulls are short to medium distance migrants and are opportunistic feeders allowing evaluation of environmental contamination of the parasite (The Cornell lab of ornithology, https://www.birds.cornell.edu/home/). The aim of this research was to investigate the prevalence of *T. gondii* in wild birds to better understand the transmission dynamics, the geographical distribution of the parasite as well as the public health risk.

3. Materials and methods:

Sample acquisition and area of collection:

A total of 72 heart tissue samples were collected from various wild hunter-harvested or nuisance-killed wild bird species from Tennessee and Pennsylvania (Table III-1). Of these, 62 birds had a corresponding serum sample. Serum samples were obtained from 391 different wild birds, comprised of 14 different species from eight different states in US from 2009 to 2019 (Table III-2). Ring-billed gull samples were collected from Erie County, Pennsylvania, USA as part of nuisance animal reduction program. The waterfowl samples from Tennessee were hunter-harvested from the Lick Creek Bottoms wildlife management area, Greene County, Tennessee, USA. Waterfowl samples collected from Arkansas, Louisiana, Minnesota, New Jersey and Texas

were all captured as part of previous studies by researchers at the Southeastern Cooperative Wildlife Disease Study (SCWDS), College of Veterinary Medicine, University of Georgia. Canada geese (*Branta canadensis*) captured in Georgia were caught by being baited into walk-in traps. All birds, except for the hunter-killed and gull samples, were live captures that were released on site.

Testing sera for *T. gondii* antibodies:

The modified agglutination test (MAT) was used to test for the presence of *T. gondii* antibodies in serum samples (Dubey and Desmonts, 1987). Briefly, sera were two-fold diluted and then mixed with *T. gondii* antigen (RH strain fixed in formalin with a concentration of $2X10^8$ tachyzoites/ml). Evans blue dye was added for better visualization and 2-alpha-mercaptoethanol was added for destruction of nonspecific antibodies. Dilutions started at 1:5 to 1:640 for all the serum samples tested except waterfowl samples from Tennessee and gull samples from Pennsylvania which were tested first at 1:25 to 1:3200. Samples showing a reaction at or above 1:5 or 1:25 respectively were considered positive. Ring-billed gull (*Larus delawarensis*) serum samples that were negative at 1:25 were retested using two-fold dilutions starting at 1:5 to 1:20 to confirm their negativity at lower dilutions. That was not possible with the Tennessee waterfowl due to poor condition of serum samples.

Polymerase chain reaction (PCR):

DNA was extracted from 72 heart tissues using Qiagen DNeasy Blood and Tissue Kit, according to the manufacturer protocol (Qiagen, Valencia, CA). A negative control, using nuclease free water was included to ensure no contamination during the extraction process. PCR targeting the B1 gene of *Toxoplasma gondii* was performed on extracted DNA. Primers used

were as follows: 5'-GGAACTGCATC CGTTCATGAG and 5'-TCTTTAAAGCGTTCGTGGTC (Burg et al, 1989). A positive and negative PCR control was included. The PCR product was visualized using 1.5% agarose gel electrophoresis with ethidium bromide. PCR positive products were purified using QIAquick PCR Purification Kit and sequenced at the sequencing laboratory at the University of Tennessee (Knoxville, Tennessee, USA). Sequencher 5.1 software was used for aligning the complementary reverse and forward sequences. A BLAST search in Genbank was done using the aligned sequences.

Statistics:

Logistic regression was used to compare prevalence by year and state. Then a Chi squared test was used to determine the difference between males and females, adults and juveniles, species and states. SPSS version 25 statistical package (IBM SPSS statistics 25) was used for all the statistical analysis and $p < .05$ was considered statistically significant. All tables are located in appendix III.

4. Results:

Serology and PCR results of Tennessee and Pennsylvania samples:

A total of 72 heart tissue samples were tested by PCR and 10 samples (13.9%) were positive for *T. gondii* DNA. A total of 62 serum samples from nine wild bird species were tested using MAT and 45 (72.6%) were positive with titers equal to or higher than 1:25 (Table III-1). *Toxoplasma gondii* antibodies were detected in 78.3% (18/23) of ring-billed gull (*Larus delawarensis)* serum samples from Pennsylvania, while Tennessee waterfowl had a total seroprevalence of 69.2% (n=27/39). Seroprevalence varied between different bird species with

hooded merganser (*Lophodytes cucullatus*) having the highest prevalence (100%, 9/9) and lesser scaup (*Aythya affinis*) having a prevalence of zero (0/1).

Toxoplasma gondii end-point dilutions of the birds by species are shown in Table III-3. The majority (84.4%, 38/45) of the positive serum samples had a titer that ranged from 1:50 to 1:400 with 1:200 having the highest frequency (24.4%, 11/45). Seven (15.6%) samples had titers less than 50 or higher than 400. All the negative gull sera that were two-fold diluted starting at 1:5 showed no reaction at the lowest dilution and were interpreted as negative.

Only one gull sample tested positive by both MAT and PCR. The MAT titer for this gull was 1:200. Eight waterfowl samples tested positive by both tests and their titers were one with 1:25, two with 1:50, one with 1:100, three with 1:200 and one with 1:400. One waterfowl sample tested positive by PCR but did not have a corresponding serum sample.

Serology results of samples from Arkansas, New Jersey, Minnesota, Georgia, Louisiana, and Texas:

A total of 329 serum samples from 10 different wild waterfowl species were collected from six different states (Table III-2). Modified agglutination test showed a total seroprevalence of 45.9% (151/329) from the six states in the US. *Toxoplasma gondii* seroprevalence was 80% (16/20) in Arkansas, 53.8% (7/13) in New Jersey, 51.9% (80/154) in Minnesota, 41.7% (10/24) in Georgia, 40% (14/35) in Louisiana, and 28.9% (24/83) in Texas.

Of the 329 serum samples tested, blue winged teal (*Spatula discors*) had a lower prevalence of 25.6% (23/90, $p < .001$). American wigeon (*Mareca americana*) and domestic

duck (*Cairina moschata)* had a seroprevalence of 100% but only one bird was collected from each species. Titers from bird species collected from these six states are shown in Table III-4.

Seroprevalence by state, species, age and sex:

Data collected from the eight states were combined to compare seroprevalence by state, species, age and sex. We had a total *T. gondii* seroprevalence of 50.1% (196/391) in wild birds collected form eight different states in the US. Logistic regression was performed to compare the prevalence by state and year. There was a significant difference among states (p=.003) but not among years (p=.185) (Table III-6). Arkansas, Pennsylvania and Tennessee all had a significantly higher prevalence (>50%) while; Texas had a significantly lower prevalence of 28.9% (24/83) than the rest of the states using a chi squared test.

Blue winged teal (*Spatula discors*) had a significantly lower prevalence than the other species of 25.6 % (23/90) while the hooded merganser (*Lophodytes cucullatus*) had a significantly higher prevalence of 100% (9/9) and the Ring-billed gulls (*Larus delawarensis)* had a significantly higher prevalence of 78.3% (18/23) with p <.001. Species that had counts less than nine were excluded from this analysis. A chi squared test comparing the adult (50.8%, 124/244) versus juvenile (48%, 61/127) was not significant p = .662 while females (60%, 87/145) had significantly higher prevalence than males (45.1%, 96/213) (p=.007) (Table III-5).

5. Discussion:

Pennsylvania Ring-billed gull (*Larus delawarensis)* and Tennessee waterfowl serum (N=62) and tissue samples (N=72) were collected and tested first. Due to the unexpectedly high seroprevalence (72.6%) we decided to test banked waterfowl sera samples from other states

(N=329). We documented a total *T. gondii* seroprevalence of 50.1% in wild birds from eight different states in the US. We showed unexpected significantly high seroprevalence in wild birds collected from Tennessee (69.2%, 27/39), Pennsylvania (78.3%, 18/23) and Arkansas (80%, 16/20) and a significantly lower prevalence in Texas (28.9, 24/83) compared to New Jersey, Minnesota, Georgia, Louisiana.

Our results are higher than previously reported prevalence from Florida in ring-billed gulls (*Larus delawarensis*) which was 15.4% (2/13),laughing gulls (*Larus atricilla*) which was 6% (2/33), and wood duck (*Aix sponsa*) which was 37.5% (1/16) using indirect hemagglutination test (Burridge et al., 1979). It is also higher than the seroprevalence of *T. gondii* in Canada geese (*Branta canadensis)* captured and tested in Maryland, which was 7.1% (12/169) (Verma et al., 2016).

Reports from other geographic areas as well as other gull and waterfowl species showed a low to a non-detectable prevalence. For example, *T. gondii* was isolated from tissues of 16.4 % (10/61) of naturally infected black-headed gulls (*Larus ridibundus*) in the Czech Republic (Dubey, 2002) and a seroprevalence of 19.9% (131/659) in black-headed gulls from China was reported using the MAT method with a cut-off titer of 1:5 (Miao et al., 2014). The seroprevalence in yellow-legged chicks (*Larus michahellis*) and Audouin's gull chicks (*Larus audouinii*) were 22.8% (109/479) and 2.2% (1/46), respectively (Cabezon et al., 2016) using MAT with a cut-off point of 1:25 in the Iberian Peninsula. Negative results were observed in 27 glaucous gulls from Svalbard Island in the high Arctic (Prestrud et al., 2007).

In waterfowl, the parasite was isolated by mouse bioassay with tissues from 12% (22/184) of Mallard (*Anas platyrhynchos*), 28% (7/25) Tufted duck (*Aythya fuligula*) and 12.5%

(1/8) of Pochard (*Aythya ferina*) which were naturally infected from the Czech Republic (Uterak et al., 1992). Previous experimental infections in waterfowl using an avirulent *T. gondii* isolate yielded no clinical disease (Bartova et al., 2004) and there is no record of clinical toxoplasmosis in any wild ducks (Dubey, 2002). However, clinical toxoplasmosis from captive geese has been previously reported (Work et al., 2002; Dubey et al., 2001). Further experimental research with various genotypes including virulent and avirulent isolates, as determined by mouse infection, is needed in various avian species including waterfowl. In addition, tropism studies are important to determine the potential zoonotic potential from hunter-harvested birds.

There is very little data available about *T. gondii* infection in gulls and waterfowl, and studies are usually performed on a small number of samples. In addition, care is needed when interpreting the prevalence data between different studies especially in birds. Differences in the prevalence between studies may be attributed to factors such as the use of different tests to detect prevalence, geographic and ecologic factors, cat populations in the sampled areas, sample size as well as the different bird species tested (Cabezon et al., 2016; Miao et al., 2014). It is important to note that not all the tests used for *Toxoplasma* detection are valid in birds and isolation of the parasite from sparrows that were Sabin-Feldman dye test negative has been documented (Dubey, 2002; Ruiz & Frenkel, 1980)

In the present study we detected *T. gondii* prevalence using two different methods, MAT and PCR targeting the 35- copy B1 gene. We had a total seroprevalence of 72.6% (45/62) using MAT compared to 14.5% (9/62) using the PCR on tissue samples from the same birds (n=62). Ten samples were tested only by PCR and did not have a corresponding serum sample. One of these tested positive by PCR. Although some studies suggest that PCR has a high sensitivity (Dubey, 2010b; Contini et al., 2005; Jauregui et al., 2001), our results suggest that it is not

suitable for prevalence studies. The low prevalence detected by PCR compared to MAT may be attributed to the small tissue sample size (25mg) processed and the lack of data about *T. gondii* tissue tropism in birds. We tested hearts from these birds because it can be accessed without destruction to the desired carcass sections. Hearts may not be the most favorable tissue for *T. gondii* as indicated by Mancianti et al. (2013) who were able to detect the parasite in the brain tissue but not in the hearts of different duck species. The 529bp repetitive marker is more sensitive than the 35-copy B1 gene that was targeted in this study, which may be a factor in the low prevalence detected by PCR (Dubey, 2010b; Homan et al., 2000). In a previous study, we targeted the 529bp repetitive marker in brains of doves in a previous study and we encountered nonspecific binding with bird DNA, so targeting B1 gene is preferable in our bird studies (Ammar et al., accepted). MAT test is widely used for the detection of antibodies against *T. gondii* in mammals and birds. It has been validated in chickens (Dubey et al., 2016) and is proven useful in other bird species such as turkeys (Dubey et al., 1993a). The test is simple, specific, low cost and does not require any species-specific antibodies so can be used for a wide range of mammals and birds (Dubey, 2010b; Dubey et al., 1997; Dubey et al., 1996). Samples that are PCR-negative should be tested by serological methods including MAT or ELISA (Hill et al., 2006; Dubey et al., 1997) before reporting them as negative.

Birds can be infected, as other intermediate hosts (IH), commonly through ingestion of sporulated oocysts in contaminated food or water or tissue cyst from other IH (Dubey, 2010b). Cats, the definitive host, shed *T. gondii* oocysts in their feces and after sporulation, they are infective to the IH. Cats fed one infected mouse with *T. gondii* can shed about 500 million oocysts in their feces (Dubey and Frenkel, 1972). *Toxoplasma gondii* sylvatic lifecycle is very efficient and plays a major role in maintaining the parasite (Dubey and Jones, 2008). A

seroprevalence of *T. gondii* in bobcats, which is the most common wild felid in the USA, was 83% in Pennsylvania, (Mucker et al., 2006) and the parasite was isolated from two bobcats in another study from the same state (Dubey et al., 2015). Six out of eight bobcats from Arkansas tested positive for *T. gondii* using an agglutination test (Heidt et al., 1988). Having a high *T. gondii* seroprevalence of 78.3% in gull samples collected from Pennsylvania and 80% in waterfowl samples from Arkansas suggests that there is an active and effective sylvatic life cycle in these states. However further research aimed at genotyping isolates from waterfowl and other avian species in conjunction with oocysts from sympatric wild and domestic felids is needed to elucidate the transmission dynamics.

Waterfowl samples collected from east Tennessee had a high seroprevalence and previous research has shown that raccoons (*Procyon lotor)*, coyotes *(Canis latrans),* feral hogs (Sus scrofa) and white-tailed deer (Odocoileus virginanus) from the southeastern USA had high *Toxoplasma* infection rates (Gerhold et al., 2017). In this study, wild animals from Tennessee had a seroprevalence of 37.5% (116/309) and a prevalence of 5.6% was reported in 18 birds, none of which were waterfowl.

The western part of the US is thought to have a lower *T. gondii* prevalence than the eastern side (Dubey et al., 2010; Vollaire et al., 2005). Our results showed a significantly lower *T. gondii* prevalence of 28.9% (24/83) in waterfowl samples collected from Texas. The variability in *T. gondii* prevalence among states may be related to the difference in climate conditions which affect *T. gondii* oocyst survival and infectivity in the environment greatly (Dubey et al., 2010; Vollaire et al., 2005; Dubey, 1998b). It also may be affected by the population density in an area and the availability and diversity of intermediate or transport hosts in this specific area (Vollaire et al., 2005).

Bird samples were collected from areas that have fresh water sources which may indicate a major contamination of bodies of water in Tennessee, Pennsylvania and Arkansas with *T. gondii* oocysts. This agrees with Cabezon et al. (2016) who reported freshwater bodies as a source of *T. gondii* infection in gulls. Gull samples were collected from Erie county which is in the northern part of Pennsylvania on the southeast shore of Lake Erie. It is an area of abundant rainfall and characterized by a large water system represented by streams, swamps and lakes (Tomikel et al., 1967). We also collected waterfowl samples from Greene County, Tennessee which is in the eastern part of the state. Greene County is drained by the Nolichucky River and the state has a large network of streams and rivers.

Under favorable conditions, oocysts can remain infective up to a year in the environment (Lindsay and Dubey, 2009; Yilmaz and Hopkins, 1972), giving the chance for animals to become infected. In addition, rain events may wash oocysts over a wide area to be distributed into various aquatic environments including rivers, ponds, lakes and marine environments (Dubey and Jones, 2008; Miller et al., 2002a). Several lakes may be used as human water reservoirs which can be an additional source for human infeciton. Further investigation of waterfowl and various aquatic ecoystems is needed to understand the transmission dynamics and determine potential human risk by ingestion of contaminated water from reservoirs or from undercooked game meat.

Toxoplasma gondii infection has historically been known as a land derived infection, but recent mortalities in endangered sea otters (*Enhydra lutris nereis*) raised the question about the mechanism of infection in the aquatic environments (Conrad et al., 2005; Miller et al., 2002a; Miller et al., 2002b; Tenter et al., 2000). The most prevalent theory explaining the mode of infection in marine mammals is the ability of filter feeders to concentrate the parasite in their

gills or biofilms leading to infection of marine mammals with a high dose of the parasite when feeding (Cabezon et al., 2016; Miller et al., 2002a). The filter feeders theory was not restricted to bivalves but was further extended to filter feeding fish species. A study done by Massie et al. (2010) found that migratory filter feeder fish were able to filter *T. gondii* oocysts from seawater, and these oocysts persisted in the gastrointestinal tract of the fish for up to 8 hours and remained infectious. Mazzillo et al. (2013) demonstrated that *T. gondii* oocysts can attach to the sticky biofilms on kelp which eases their intake by different snails. In addition, *T. gondii* infection of gulls has been linked to close proximity to human settlement, sewage (Miller et al., 2002a) and fresh water as food sources (Cabezon et al., 2016).

We detected a significantly higher prevalence in hooded mergansers and Ring-billed gulls which were collected from Tennessee and Pennsylvania respectively. This high prevalence may be attributed to the area of collection since Tennessee and Pennsylvania samples in general were significantly higher than other states. Alternatively, the feeding behavior of these avian species may have led to the increased infection prevalence. Gulls and waterfowl are opportunistic feeders and often live close to bodies of water and can feed on dumpster, sewage, human food, aquatic grasses, fish and crustaceans as well as on land grasses and insects. Mergansers eat fish and aquatic creatures as their main food especially during breeding season. Hooded merganser feed on more diverse food sources than other mergansers (The Cornell lab of ornithology, https://www.birds.cornell.edu/home/). Given that their feeding habits are consistent with exposure to *Toxoplasma*, these bird species are good candidates to study the environmental contamination with the parasite (Cabezon et al., 2016).

On the other hand, Blue-winged teal (*Anas discors*) have a significantly lower *T. gondii* prevalence than other wild bird species. That is consistent with previous studies (Dubey et al.,

2010) which showed negative *T. gondii* prevalence (N=2). It is important to note that most of the blue winged teal samples (77 out of 90) were collected from Texas that had a significantly lower *T. gondii* seroprevalence than other states in this study and may be attributed to the location rather than the bird species. A bigger study including single bird species would explain the variability in *T. gondii* prevalence among species and allow for better understanding of the parasite transmission and factors affecting species preference.

Although males and females have the same feeding habits, females are responsible for building the nest and taking care of the offspring. While using their beaks to grab grasses and make a depression in the ground to build a nest, females may be exposed to *T. gondii* oocysts in the soil which may explain the higher prevalence in females than male birds (The Cornell lab of ornithology, https://www.birds.cornell.edu/home/).

In conclusion, studying the *T. gondii* prevalence in wild birds is very important to understanding the distribution of the disease in the environment. Our results suggest that *T. gondii* is highly prevalent in gulls and waterfowl indicating high environmental contamination in Tennessee, Pennsylvania and Arkansas. Waterfowl are an excellent candidate to study *T. gondii* prevalence given their variable feeding habits, proximity to human environments and being a game animal. Our study included samples from different waterfowl and most of them are migratory birds that travel for variable distances and may play a role in dispersing the parasite geographically. Studying the range covered by these birds and their infection patterns is critical to understand the disease ecology. Some of these birds are hunter killed game birds which also represents a public health risk. Results indicate that serology is more sensitive than PCR for detecting *T. gondii* infection in these bird species. However, there is still a need in the future for a standard diagnostic test that can be effectively and specifically used in wild birds for *T. gondii*

detection. Isolating and characterizing the parasite genotypes was not possible in the present study, but it would be useful in the future to elucidate the ecoepidemiology of the parasite and its transmission dynamics.

6. Appendix III:

Table III-1. *Toxoplasma gondii* PCR and MAT results of bird samples collected from Tennessee and Pennsylvania

Species tested		Positive MAT/Total (%)	Positive PCR/Total (%)
Ring-billed gull (*Larus delawarensis)* (Pennsylvania total samples)		**18/23 (78.3%)**	**1/23(4.3%)**
Waterfowl species (Tennessee total samples)		**27/39(69.2%)**	**9/49 (18.4%)**
	Mallard (*Anas platyrhynchos*)	11/19(57.9%)	1/22 (4.5%)
	Hooded merganser (*Lophodytes cucullatus*)	9/9(100%)	4/10 (40%)
	Green winged teal (*Anas crecca*)	1/2 (50%)	2/7 (28.6%)
	Northern pintail (*Anas acuta*)	2/3 (66.7%)	2/3(66.7%)
	Lesser scaup (*Aythya affinis*)	0/1 (0%)	0/2(0%)
	Northern shoveler (*Spatula clypeata*)	1/2 (50%)	0/2(0%)
	Gadwall (*Mareca Strepera)*	1/1 (100%)	0/1(0%)
	Common merganser (*Mergus merganser*)	2/2 (100%)	0/2(0%)
Total		**45/62 (72.6%)**	**10/72(13.9%)**

Table III-2. Data of bird samples collected from Arkansas, Georgia, Minnesota, Louisiana, New Jersey, Pennsylvania, Tennessee and Texas for *T. gondii* testing

State	Species	M/F(unknown)	Age (adult/juvenile (unknown))	Positive MAT/Total (%)
Arkansas				
	Mallard (*Anas platyrhynchos*)	14/6	20/0	16/20 (80.0%)
Georgia				
	Canada goose (*Branta canadensis*)	7/7(10)	11/3(10)	10/24 (41.7%)
Louisiana				
	Mallard (*Anas platyrhynchos*)	12/0	12/0	6/12 (50.0%)
	Green winged teal (*Anas crecca*)	0/8	8/0	6/8 (75.0%)
	Blue winged teal (*Spatula discors*)	1/9	10/0	0/10 (0.0%)
	Snow goose (*Anser caerulescens*)	4/1	5/0	2/5 (40.0%)
Minnesota				
	Mallard (*Anas platyrhynchos*)	63/74(2)	27/110(2)	70/139 (50.4%)
	Green winged teal (*Anas crecca*)	0/0(1)	0/1	1/1 (100.0%)
	Blue winged teal (*Spatula discors*)	2/1	1/2	3/3 (100.0%)
	Northern pintail (*Anas acuta*)	1/1	1/1	1/2 (50.0%)
	Gadwall (*Mareca Strepera*)	2/1	1/2	2/3 (66.7%)
	Wood duck (*Aix sponsa*)	3/0	3/0	2/3 (66.7%)
	Canada Goose (*Branta canadensis*)	0/0(2)	0/2	0/2 (0.0%)
	American wigeon (*Mareca americana*)	1/0	1/0	1/1 (100.0%)
New Jersey				
	Mallard (*Anas platyrhynchos*)	2/3(7)	4/1(7)	6/12 (50.0%)
	Domestic duck (*Cairina moschata*)	0/0(1)	0/0(1)	1/1 (100.0%)
Pennsylvania				
	Ring-billed gull (*Larus delawarensis*)	11/7(5)	18/5	18/23 (78.3%)

Table III-2. (Continued)

State	Species	M/F(unknown)	Age (adult/juvenile (unknown))	Positive MAT/Total (%)
Tennessee				
	Mallard (*Anas platyrhynchos*)	13/7(2)	22/0	11/19 (57.9%)
	Green winged teal (*Anas crecca*)	1/1(5)	7/0	1/2 (50.0%)
	Northern pintail (*Anas acuta*)	3/0	3/0	2/3 (66.7%)
	Lesser scaup (*Aythya affinis*)	0/0(2)	2/0	0/1 (0.0%)
	Gadwall (*Mareca Strepera*)	0/1	1/0	1/1 (100.0%)
	Hooded merganser (*Lophodytes cucullatus*)	2/8	10/0	9/9 (100.0%)
	Common merganser (*Mergus merganser*)	1/1	2/0	2/2 (100.0%)
	Northern shoveler (*Spatula clypeata*)	1/0 (1)	2/0	1/2 (50.0%)
Texas				
	Green winged teal (*Anas crecca*)	1/5	6/0	4/6 (66.7%)
	Blue winged teal (*Spatula discors*)	60/17	77/0	20/77 (26.0%)
Total		**205/158 (38)**	**254/127 (20)**	**196/391 (50.1%)**

Table III-3. *Toxoplasma gondii* seroprevalence and modified agglutination test titers of wild bird species collected from Tennessee and Pennsylvania

Host	**No. of Samples**	**MAT titers**									**Seroprevalence (%)**
		<1:25	**1:25**	**1:50**	**1:100**	**1:200**	**1:400**	**1:800**	**1:1600**	**>1:3200**	
Ring-billed gull	23	5	1	3	3	5	3	1	1	1	18/23 (78.3%)
Hooded merganser	9	0	0	3	0	3	3	0	0	0	9/9 (100%)
Mallard	19	8	1	2	3	1	3	1	0	0	11/19 (57.9%)
Green winged teal	2	1	0	0	0	1	0	0	0	0	1/2 (50%)
Pintail	3	1	1	1	0	0	0	0	0	0	2/3 (66.7%)
Lesser scaup	1	1	0	0	0	0	0	0	0	0	0/1 (0%)
Gadwell	1	0	0	1	0	0	0	0	0	0	1/1(100%)
Common merganser	2	0	0	0	1	0	1	0	0	0	2/2 (100%)
Northern shoveler	2	1	0	0	0	1	0	0	0	0	1/2 (50%)
Total	**62**	**17**	**3**	**10**	**7**	**11**	**10**	**2**	**1**	**1**	**45/62 (72.6%)**

Table III-4. *Toxoplasma gondii* seroprevalence and modified agglutination test titers of bird samples collected from Arkansas, Georgia, Minnesota, Louisiana, New Jersey and Texas

Host	**No. of Samples**	**MAT titers**								**Seroprevalence (%)**
		<1:5	**1:5**	**1:10**	**1:20**	**1:40**	**1:80**	**1:160**	**>1:320**	
Green winged teal	15	4	3	3	4	0	1	0	0	11/15 (73.3%)
American widgeon	1	0	0	0	0	0	1	0	0	1/1 (100%)
Blue winged teal	90	67	4	5	4	6	4	0	0	23/90 (25.6%)
Canada goose	26	16	0	1	2	3	3	1	0	10/26 (38.5%)
Domestic duck	1	0	0	1	0	0	0	0	0	1/1 (100%)
Gadwall	3	1	0	2	0	0	0	0	0	2/3 (66.7%)
Mallard	183	85	37	34	13	11	1	2	0	98/183 (53.6%)
Northern pintail	2	1	0	0	0	1	0	0	0	1/2 (50%)
Snow goose	5	3	1	0	1	0	0	0	0	2/5 (40%)
Wood duck	3	1	0	1	1	0	0	0	0	2/3 (66.7%)
Total	329	178	45	47	25	21	10	3	0	151/329 (45.9%)

Table III-5. Age and sex data for samples collected for *Toxoplasma gondii* testing

		Seroprevalence (%)
Age		
	Adult	124/244 (50.8%)
	Juvenile	61/127 (48%)
	Unknown	11/20 (55%)
Sex		
	Male	96/213 (45.1%)
	Female	87/ 145(60%)
	Unknown	13/33 (39.4%)

Table III-6. Seroprevalence of *Toxoplasma gondii* in wild birds from eight different states from 2009 to 2019 using modified agglutination test.

	2009	2010	2011	2012	2013	2014	2015	2016	2017	2018	2019	Total
Arkansas	0	0	0	0	0	0	0	0	0	0	16/20 (80.0%)	**16/20 (80.0%)**
Georgia	0	0	0	0	0	0	4/14 (28.6%)	0	6/10 (60.0%)	0	0	**10/24 (41.7%)**
Louisiana	0	0	0	0	0	0	0	2/5 (40.0%)		12/20 (60.0%)	0/10 (0.0%)	**14/35 (40%)**
Minnesota	8/21 (38.1%)	17/24 (70.8%)	14/30 (46.7%)	9/15 (60.0%)	7/15 (46.7%)	7/14 (50.0%)	0	7/15 (46.7%)	9/10 (90.0%	2/10 (20.0%)	0	**80/154 (51.9%)**
New Jersey	4/8 (50.0%)	3/5 (60.0%)	0	0	0	0	0	0	0	0	0	**7/13 (53.8%)**
Pennsylvania	0	0	0	0	0	0	0	0	0	18/23 (78.3%)	0	**18/23 (78.3%)**
Tennessee	0	0	0	0	0	0	0	0	0	27/39 (69.2%)	0	**27/39 (69.2%)**
Texas	0	0	0	4/15 (26.7%)	7/15 (46.7%)	3/16 (18.8%)	8/16 (50.0%)	1/10 (10.0%)	1/11 (9.1%)	0	0	**24/83 (28.9%)**
Total	**12/29 (41.4%)**	**20/29 (69%)**	**14/30 (46.7%)**	**13/30 (43.3%)**	**14/30 (46.7%)**	**10/30 (33.3%)**	**12/30 (40.0%)**	**10/30 (33.3%)**	**16/31 (51.6%)**	**59/92 (64.1%)**	**16/30 (53.3%)**	**196/391 (50.1%)**

CHAPTER IV

Toxoplasma gondii **prevalence in hunter-killed Mourning doves (*Zenaida macroura*) and Rock pigeons (*Columba livia*) from East Tennessee.**

A version of this chapter has been previously published by Sawsan Ammar, Kate Purple and Richard Gerhold. Formatting changes have been made to the original publication.

Ammar, S., Purple, K. & Gerhold, R. (accepted). *Toxoplasma gondii* prevalence in hunter-killed Mourning doves (*Zenaida macroura*) and Rock pigeons (*Columba livia*) from East Tennessee. J. Wildl. Dis.

1. **Abstract:**

We molecularly examined brains from 186 hunter-killed Mourning doves (*Zenaida macroura*) and 11 Rock pigeons (*Columba livia*) from eastern Tennessee for *T. gondii*. A total of 2 doves (1%) were PCR and sequence positive, whereas all pigeons were PCR negative.

2. **Introduction:**

Toxoplasma gondii is a zoonotic protozoan parasite that has a heteroxenous life cycle. The parasite can infect a wide host range and different cell types in their intermediate and final hosts (Tenter et al., 2000). Intermediate hosts include all warm-blooded animals while felids are the only known definitive hosts (Tenter et al., 2000; Dubey, 2002). Diagnosis of *T. gondii* in birds is challenging, as no test is completely validated (Godoi et al., 2010). Birds can be infected with *T. gondii* through ingesting oocysts from the ground or in contaminated water. Carnivorous birds can also be infected through ingesting tissue cysts from infected small mammals and birds. Infections in birds may vary from subclinical to fatal and there are several reports of *T. gondii*-associated mortality in various bird species (Dubey, 2002; Dubey, 2008).

The order Columbiformes contains several hunted game species; however, little is known about the zoonotic potential or population impacts of *T. gondii* in these birds. Mourning doves are the most hunted game bird species in the United States, and pigeons are highly adaptable to various environments and considered pests (Godoi et al., 2010). The presence of *T. gondii* in

columbiformes is a concern for public health and disease ecology because these birds are legally harvested for human consumption, which represents a zoonotic threat if undercooked meat is consumed.

3. Materials and methods:

We collected heads from 186 hunter-killed Mourning doves (*Zenaida macroura*) and 11 hunter-killed Rock pigeons (*Columba livia*) during the 2016 hunting season in Knox County in East Tennessee (Figure IV-1). The whole brain was extracted from the skull of each bird, divided into two halves and placed in two separate tubes at -20 C. DNA was extracted from only one half of the brain using Qiagen DNeasy Blood and Tissue Kit, according to the manufacturer's instruction (Qiagen, Valencia, CA). PCR was performed on the extracted DNA targeting the 529 bp repetitive element. Primers were as follows TOX4 (5'CGCTGCAGGGAGGAAGACGAAAGTTG 3') and TOX5 (5'CGCTGCAGACACAGTGCATCTGGATT 3') (Homan et al. 2000). Negative controls, consisting of nuclease free water, were used for DNA extraction and PCR. The PCR products were analyzed on 1.5% agarose gel and sequenced for confirmation of *T. gondii* DNA.

4. Results:

In this study, we found a 1% (2/186) prevalence of *T. gondii* in brain tissue from hunter-killed Mourning doves, which was confirmed by bidirectional sequencing followed by BLAST analysis in GenBank. Both sequences from the two positive mourning doves had identical sequence and 100% match to the type III strain VEG (*accession* number LN714508.1) in GenBank. No positive samples were found in pigeons.

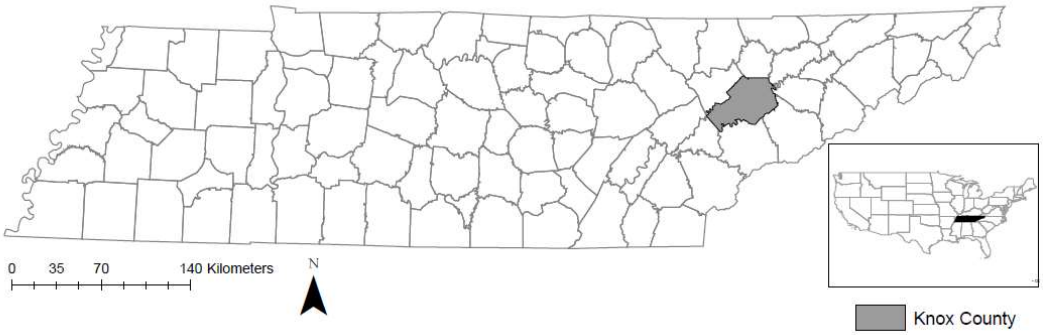

Figure IV-1. Area of sample collection in East Tennessee.

5. Discussion:

Toxoplasma gondii primarily infects the nervous system, especially the brain, eyes, and skeletal and cardiac muscles (Dubey, 1988; Tenter et al., 2000). Pigeons may suffer from neuritis and encephalitis due to toxoplasmosis infection (Dubey, 2002; Dubey, 2008). In one report, ten native Australian pigeons were reported with fatal toxoplasmosis and two pigeons, in the same area, showed multifocal meningoencephalitis with *T. gondii* tissue cysts in the brain of one of the birds (Hartley and Dubey, 1991). Because *T. gondii* infections can occur in organs other than the brain, examining only the brain tissue from the doves and pigeons may have some limitations; however, other tissue or biological samples from the birds in this study were not available.

Toxoplasma gondii has been reported in numerous bird species all over the world. However, there are few studies about the prevalence of *T. gondii* in Columbiformes in the US (Dubey, 2002; Dubey, 2008). Susceptibility to toxoplasmosis differs among different species of Columbiformes (Dubey, 2002; Rigoulet et al., 2014). A prevalence of 6% was found in pigeons from Memphis, Tennessee (Godoi et al., 2010). A similar prevalence level (5.9%) was found in pigeons from New Jersey (Kirkpatrik et al., 1990).

Doves tend to have a higher *T. gondii* prevalence than pigeons, consistent with our results of a higher prevalence found in Mourning doves compared to pigeons. A seroprevalence of 22.3% was detected in free-ranging Eared doves (*Zenaida auriculata*) from Brazil and five different *T. gondii* genotypes were isolated (Barros et al., 2014). In a separate study, four Bar-shouldered doves *(Geopelia humeralis)* were found dead due to toxoplasmosis at the Clères zoo in France (Rigoulet et al., 2014).

Although we found a low prevalence of *T. gondii* in Mourning doves, tissue cysts from undercooked meat are infectious and represent a potential risk factor to humans (Tenter et al.,

2000). Further education of the public about *T. gondii* transmission from wild game, as well as proper game meat preparation and cooking, is recommended to minimize transmission of this and other zoonotic pathogens.

CHAPTER V

Serological survey of *Toxoplasma gondii* in wild turkeys (*Meleagris gallapavo*) from southcentral Tennessee.

Sawsan Ammar,[1,5], Vinnie Johnson[2], Lindsey Phillips[2], Roger Applegate[3], Chunlei Su[4], Richard Gerhold[1]

[1] Department of Biomedical and Diagnostic Sciences, College of Veterinary Medicine, University of Tennessee, Knoxville, TN 37996. [2] Department of Forestry, Wildlife and Fisheries at the University of Tennessee, Knoxville, TN 37996. [3] Tennessee Wildlife Resources Agency, Nashville, TN. [4] Department of Microbiology, University of Tennessee, Knoxville, TN.[5] Clinical Pathology Department, College of Veterinary Medicine, Sadat City University, Sadat City, Menofia, Egypt

1. Abstract:

Wild turkeys (*Meleagris gallapavo*) are one of the most important gamebirds in the United States and their meat is consumed following harvest. However, wild turkey, as other warm-blooded mammals and birds, acts as an intermediate host of the zoonotic parasite *Toxoplasma gondii*. In this study we investigated the prevalence of *T. gondii* in wild turkeys from various counties in southcentral Tennessee to understand the transmission of this parasite and the potential public health risks of consuming improperly handled or prepared turkey. Sera from 381 wild turkeys were collected from 2014-2015 and 2017-2018. Birds were either hunter killed or captured by rocket nets during a collaborative project between Tennessee Wildlife Resources Agency and the University of Tennessee to investigate potential causes of turkey population decline in Tennessee. Samples were collected from seven counties including Giles, Lawrence, Lincoln, Wayne as experimental counties given these counties had a perceived wild turkey population decline, whereas Bedford, Lewis and Maury served as control counties that had stable turkey populations. A total prevalence of 20.5% (78/381) was observed using

modified agglutination test with no significant difference between different counties, experimental and control counties, sex of birds, or the year of sample collection. Adult turkeys had significantly higher *T. gondii* seroprevalence than juveniles. Our results suggest that prevalence of *T. gondii* in wild turkeys is stable over the period examined. It also suggests that *T. gondii* is likely not associated with turkey population decline in the experimental counties as there was no significant difference in the parasite prevalence between experimental and control counties over years.

2. Introduction:

Wild turkeys (*Meleagris gallapavo*) are known to be natural hosts for the zoonotic protozoan parasite *Toxoplasma gondii* (Dubey, 2002). Infection is usually subclinical and only two cases of fatal clinical toxoplasmosis in wild turkeys have been published (Quist et al., 1995; Howerth & Rodenroth, 1985). Although *T. gondii* prevalence in turkeys ranged from low to moderate in previous reports (Sarkari et al., 2014; Bartova et al., 2009; Quist et al., 1995; Lindsay et al., 1994), the parasite represents a potential health risk if turkey meat is improperly prepared. Similar to other birds and mammals, wild turkeys can serve as an intermediate host for *T. gondii* and can harbor the parasite in their tissues for years (Dubey, 2002). They primarily obtain the infection through ingestion of oocysts in contaminated water or environment while foraging (Tenter et al., 2000). Studies on the parasite prevalence and genotype diversity in wild birds are needed to better understand the parasite sylvatic life cycle, transmission dynamics, and to estimate the potential health risk for humans. We investigated the *T. gondii* seroprevalence in wild turkeys collected from seven different counties in Tennessee during four years through 2014 to 2018 and compared the prevalence among different counties and years to investigate potential role of *T. gondii* in the recent wild turkey decline in Tennessee.

3. Materials and methods:

A total of 381 serum samples from various counties in Tennessee, USA were collected (Table V-1) during 2014, 2015, 2017 and 2018. Samples collected during 2014 and 2015 were from hunter killed wild turkeys at hunter check stations.The 2017 and 2018 samples were collected as a part of a collaborative project between the Department of Forestry, Wildlife and Fisheries and College of Veterinary Medicine at the University of Tennessee and the Tennessee Wildlife Resources Agency to investigate the perceived wild turkey population decline in the contiguous counties of Giles, Lawrence, Lincoln and Wayne. Samples from three neighboring counties that did not report any decline in turkey populations were used as control counties for comparison. These three counties were Bedford, Lewis and Maury.

Modified agglutination test (MAT) was used to detect the presence of antibodies against *T. gondii* in turkey sera. Formalin fixed whole tachyzoites prepared in Dr. Chunlei Su's lab at the Microbiology Department, University of Tennessee were used as antigen, and sera were mixed with it in consecutive two-fold dilutions starting at 1:25. Titers lower than 25 were considered negative. Statistical analysis was performed using SPSS version 25 statistical package (IBM SPSS statistics 25). Logistic regression was run to test the difference in rate of positives to see if the prevalence differs by county or year. P value < .05 was considered statistically significant.

Sex and age comparisons were computed using Chi square test on samples collected in 2017 and 2018 only because samples collected in 2014 and 2015 were all hunter killed birds which means they are all adult males. All tables are in Appendix V.

4. Results:

A total *T. gondii* seroprevalence of 20.5% (78/381) in wild turkey samples collected from Tennessee during the years 2014, 2015, 2017 and 2018 was documented. The majority of MAT positive birds had antibody titers that ranged from 50 to 200 with 100 having the highest frequency (Table V-2). Fifty nine of 78 (75.6%) of positive birds had titers of 200 or less while 24.4% (19/78) of positive birds have titers of 400 or more (Table V-2).

Wayne county had the highest *T. gondii* prevalence of 33.3% (13/39), and the five and two wild turkey samples collected from Lincoln and Lewis counties respectively were negative (Table V-1). *Toxoplasma gondii* prevalence was stable throughout the years tested without any significant difference, with 2015 recording the highest prevalence of 22.3% (25/112) and 2014 showing the lowest prevalence of 18.8% (6/32) (Table V-1). No significant relationship was found between *T. gondii* infection and year or county (p=0.93) indicating that neither year nor county is associated with prevalence.

All samples collected in 2014 and 2015 were male hunter-killed male turkeys, so the Chi squared test to calculate the difference in the prevalence between males versus females and adults versus juveniles was calculated for the 228 birds collected in 2017 and 2018. Twelve of 81 male birds (14.8%) and 34 of 147 female birds (23.1%) were seropositive. No significant difference in *T. gondii* infection was found between males and females (Chi square=2.242, df=1, p=0.134). The same method was used to compare the *T. gondii* prevalence between adults and juvenile birds for all four years. Forty one of 157 adult birds (26.1%) and 5 of 71 juvenile birds (7%) were seropositive. Adults had a significantly higher *T. gondii* prevalence than juveniles (Chi square=11.043, df=1, p=0.001).

5. Discussion:

Wild turkey populations have remained stable in eastern Tennessee since the reintroduction efforts in the nineties (History of the Wild Turkey in America, n.d.), but there has been a concern about a recent perceived decline in several southcentral counties that was reported by hunters and the public (Tennessee Wildlife Resources Agency website). A cooperative project was initiated between Tennessee Wildlife Resources Agency and the University of Tennessee to investigate the potential reasons for this perceived decline. As part of the project, we investigated *T. gondii* seroprevalence in wild turkey serum samples collected from counties that reported turkey populations decline (Giles, Lawrence, Lincoln and Wayne) and compared them to control counties (Bedford, Lewis and Maury) with stable wild turkey populations using modified agglutination test (MAT). Hunter killed bird samples collected before the initiation of the project were also included (2014 and 2015). The aim of the study was to investigate the role of toxoplasmosis in wild turkey declines and to better understand the parasite's epidemiology.

A total *T. gondii* seroprevalence of 20.5% (78/381) was documented with no significant difference between years (2014, 2015, 2017 and 2018) or counties sampled. This indicates a stable *T. gondii* seroprevalence over the study years and counties. Our results suggest that *T. gondii* has little population impact because there was no statistical difference in seroprevalence between control and experimental counties; however, further research is needed to confirm this. Other than two wild turkeys reported to be *T. gondii* positive and clinically affected (Quist et al., 1995; Howerth & Rodenroth, 1985), *T. gondii* infection is considered to be subclinical wild turkeys (Dubey, 2010b). Turkeys are considered resistant to *T. gondii* infection as indicated experimentally and antibody titers are related to the infectious dose used (Maksimov et al., 2018;

Bangoura et al., 2013; Dubey et al., 1993a); however, it is known that *T. gondii* has a wide spectrum of virulence. Further research is needed to determine if virulent isolates would lead to clinical disease in turkeys. Although turkeys develop an adequate humoral immune response to experimental *T. gondii* infections (Dubey et al., 1993a), they tend to have lower titers compared to naturally infected birds (Quist et al., 1995; Lindsay et al., 1994). We showed that 75.6% (59/78) of positive samples tested had antibody titers of 200 or less (cutoff point 25) using MAT. That may be due to having a chronic infection or to exposure of a low dose of oocysts in the environment compared to experimental setting. Adults have a higher *T. gondii* seroprevalence than juveniles and this is not surprising given adults having a longer duration of exposure to the oocysts in the environment compared to juveniles.

Turkeys are important game birds for human consumption, and they are an intermediate host of *T. gondii* and can be a source of infection to other hosts including humans and cats (Dubey, 2002). Toxoplasmosis is a food borne zoonosis transmitted by ingestion of oocysts or tissue cysts (Dubey & Jones, 2008; Tenter et al., 2000). Felids are the only known definitive host of the parasite and the only one capable of producing oocysts in the environment (Dubey, 2010b). Wild turkeys are thought to be primarily infected with *T. gondii* via oocyst ingestion (Lindsay et al., 1994) and they can be used as an effective sentinel for investigating the environmental contamination with *T. gondii* oocysts (El-Massry et al., 2000). Wild and domestic felids may also prey on infected wild birds and this assures the success of the *T. gondii* sylvatic lifecycle (Sarkari et al., 2014; Dubey, 2002).

MAT is a specific test to detect *T. gondii* antibodies and is extensively used in veterinary research for mammals and birds (Dubey, 2010b). It has been used in turkeys and has proven useful (Casartelli-Alves et al., 2014; Dubey et al., 1993a). The test does not require species

specific conjugate as do many ELISA tests and is suitable for prevalence studies (Sarkari et al., 2014). However, detecting the cutoff point for the test is sometimes challenging and *T. gondii* was isolated from a wild turkey that was negative at 1:25 by MAT (Lindsay et al., 1994).

T. gondii seroprevalence varies greatly between different studies perhaps due to the use of different diagnostic methods and cutoff points,. For example, a zero seroprevalence was detected in Florida wild turkeys using indirect hemagglutination test (Burridge et al., 1979) and domestic turkeys from Czech Republic using IFAT (Bartova et al., 2009). A higher seroprevalence of 59.5% was found in domestic turkeys from Egypt (El-Massry et al., 2000) and 71% in hunter killed wild turkeys from Alabama using MAT (Lindsay et al., 1994). Other factors such as geographical area of sampling and sample size may also contribute to the differences seen between different studies.

Toxoplasmosis in humans is acquired through the ingestion of tissue cysts or oocysts (Dubey & Jones, 2008; Tenter et al., 2000). In the present study, we detected *T. gondii* antibodies in serum of hunter-killed turkeys from Tennessee. Although proper cooking of the meat should kill the *T. gondii* bradyzoites (Lindsay et al., 1994), it has been shown that hunters sometimes consume raw or rare meat (Wilkins et al., 2003). So, the detection of *T. gondii* seropositive birds in these hunter-harvested wild turkeys may represent a public health concern. Efforts to educate the public about proper handling to minimize food borne pathogens from wild mammals and birds is warranted.

In conclusion, exposure to *T. gondii* has been documented in wild turkey populations in Tennessee. The disease is considered subclinical in turkeys and thus may represent a public health risk if healthy-looking birds were consumed following improper handling and preparation techniques. Further comprehensive investigations are needed to understand the parasite

transmission and population dynamics in wildlife and to educate the public and hunters on the potential zoonotic risk of improper handling or preparation.

6. Appendix V:

Table V-1. Wild turkey serum samples tested for *Toxoplasma gondii* in southcentral Tennessee.

Year	2014	2015	2017	2018	Total Pos/Total
County	Pos/Total (% pos)	Pos/Total (% pos)	Pos/Total (% pos)	Pos/Total (% pos)	(% pos)
Experimental counties total:	**6/26 (23.1%)**	**16/71 (20.8%)**	**20/102 (19.6%)**	**7/24 (29.2%)**	**49/223(22%)**
Giles	6/21 (28.6%)	10/50 (20%)	7/37 (18.9%)	7/22 (31.8%)	30/130 (23.1%)
Lawrence	0/3 (0%)	1/6 (16.7%)	5/40 (12.5%)	0/0 (0%)	6/49 (12.2%)
Lincoln	0/2 (0%)	0/3 (0%)	0/0 (0%)	0/0 (0%)	0/5 (0%)
Wayne	0/0 (0%)	5/12 (41.7%)	8/25 (32%)	0/2 (0%)	13/39 (33.3%)
Control counties total:	**0/6 (0%)**	**9/41 (22%)**	**13/63 (20.6%)**	**7/42 (16.7%)**	**29/152 (19.1%)**
Bedford	0/5 (0%)	1/7(14.3%)	8/31 (25.8%)	3/22 (13.6)	12/65 (18.5%)
Lewis	0/1 (0%)	0/1 (0%)	0/0 (0%)	0/0 (0%)	0/2 (0%)
Maury	0/0 (0%)	8/33 (24.2%)	5/32(15.6%)	4/20 (20%)	17/85 (20%)
Total:	**6/32 (18.8%)**	**25/112 (22.3%)**	**33/165(20%)**	**14/65 (21.2%)**	**78/375* (20.8%)**

* Six samples are missing the county data.

Table V-2. *Toxoplasma gondii* modified agglutination test antibody titers in wild turkeys

Antibody titer	**Frequency (%)**
<25	303 (79.5%)
25	11 (2.9%)
50	15(3.9%)
100	17(4.5%)
200	16(4.2%)
400	7 (1.8%)
800	6 (1.6%)
1600	3 (0.8%)
3200	3 (0.8%)
Total	**381**

CHAPTER VI

Toxoplasma gondii **strain and dose effects on feed conversion rate, body weight, serum antibodies response and systemic distribution in intraperitoneally infected domestic turkey poults.**

Sawsan Ammar[1,3], Nathan Hoggard[1], Chunlei Su[2], Richard Gerhold[1]

[1]Department of Biomedical and Diagnostic Sciences, College of Veterinary Medicine, University of Tennessee, Knoxville, TN. [2] Department of Microbiology, University of Tennessee, Knoxville, TN. [3]Department of Clinical Pathology, Faculty of Veterinary Medicine, Sadat City University, Sadat City, Menofia, Egypt.

1. Abstract:

This study aimed to investigate the seroconversion, feed conversion rate, weight gain and parasite tissue tropism as a function of parasite dose and virulence. Twenty-five four-week old female domestic turkeys (*Meleagris gallapavo*) were intraperitoneally infected with *Toxoplasma gondii* tachyzoites of two different strains and doses (10^5 and 10^8 tachyzoites/ml) compromising four treatment groups. A fifth control group of ten birds was intraperitoneally injected with sterile phosphate buffered saline only. All birds remained subclinical except for three birds in the two high dose groups (10^8 tachyzoites/ml). Survival rate was 88% (22/25). A 92% seroconversion rate was detected in *T. gondii* infected birds using the modified agglutination test. Antibody titers as well as weight gain were related to the dose and strain of *T. gondii* used. Feed conversion rate was higher in the high dose groups compared to low dose and control groups while weight gain was significantly lower at 14 days post infection in the group infected with 10^8 of virulent *T. gondii* strain. Gross lesions were detected in the pancreas and lung of only one bird and histopathological findings varied depending on strain and dose. The organs most frequently contained *T. gondii* DNA as detected by qPCR were brain and heart, followed by bursa of Fabricius and lung.

2. Introduction:

Toxoplasmosis, caused by the protozoan parasite *Toxoplasma gondii*, is an important food borne zoonosis (Tenter et al., 2000). It is considered the second most frequent food borne illnesses-associated cause of death in The United States (Scallan et al., 2011) and an estimated one third of the human population has been exposed to *T. gondii* (Tenter et al., 2000). The parasite can be transmitted through the ingestion of contaminated food or water containing the sporulated oocysts (Dubey, 2010b) or through the ingestion of tissue cysts in infected meat (Kijlstra and Jongert, 2009). Consumption of undercooked or cured meat was historically considered to be the main risk factors for pregnant women to contract *T. gondii* infection (Cook et al., 2000); however, recent research has shown that most humans are infected via the ingestion of oocysts (Hill et al., 2011). *Toxoplasma gondii* infection in early pregnancy can lead to abortions, stillbirths, hydrocephaly and congenital anomalies (Guha et al., 2017; Desmonts and Couvreur, 1974). Toxoplasmosis in immunocompetent individuals can be asymptomatic or can occur as an ocular disease while in immunocompromised individuals it can lead to fatal encephalitis (Montoya and Liesenfeld, 2004).

Turkeys (*Meleagris gallapavo*) are an important food source for humans (Zoller et al., 2013). Oocyst ingestion is considered the main source of *T. gondii* infection for turkeys due to their ground feeding habits (Dubey, 2008) and raising domestic turkeys outdoors or on bedding makes them more susceptible to acquiring *T. gondii* infection. Less commonly, turkeys can be infected through ingestion of tissue cyst from infected small rodents and other mammals (Maksimov et al., 2018; Zoller et al., 2013). Recently, turkey meat has been introduced as raw sausages or dry cured turkey ham; however, the effects of these food items on the human consumers has not been studied (Zoller et al., 2013).

Although only one species is known in the genus *Toxoplasma* (Dubey, 1996), *T. gondii* has several distinct genotypes (Shwab et al., 2018). These genotypes differ in their virulence with type I genotype being highly virulent and type II and III causing chronic infections (Pena et al., 2008). A higher infectious dose is required of the lower virulent strains to achieve the virulent effect of Type I strains (Shwab et al., 2018). The present study aims to investigate the effect of dose and strain of *T. gondii* tachyzoites on clinical signs, weight gain, feed conversion rate, seroconversion and tissue tropism in domestic turkeys.

3. Materials and methods:

Birds and experimental design:

Thirty-five female turkeys (*Meleagris gallapavo*) were reared from hatching at the Johnson Animal Research and Teaching Unit (JARTU), University of Tennessee, USA. The birds were kept in wire bottom cages until 48 days old (22 days post infection (dpi)) and then moved to floor pens to allow for their increased body size. The floor pens contained wood shavings and were cleaned at least twice a week. Birds had commercially available poultry food and water *ad libitum*. Wing bands with a unique identification number were placed on each bird (Table VI-1). Birds were intraperitoneally infected with *T. gondii* tachyzoites at 27 days old (0dpi) and were checked twice daily for health condition and food and water availability. The study design was approved by University of Tennessee Institutional Animal Care and Use Committee # 2614_61518.

Serum samples were collected every week starting on the day of the infection until 42dpi and then every other week until 70dpi and at 95dpi. Birds were euthanized either at day 31dpi or at the end of the experiment (95 dpi) (Figure VI-1). Weight was recorded individually for all

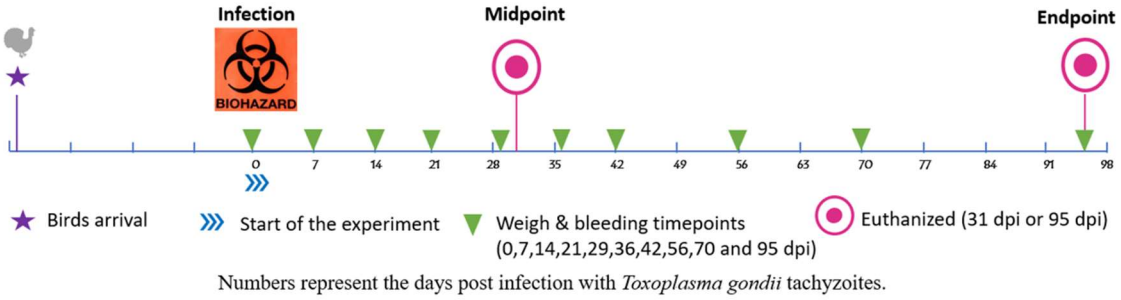

Figure VI-1. The experiment timeline and points of blood and weight data collection and euthanasia of domestic turkeys infected with *Toxoplasma gondii*

birds at time of blood collection (0,7,14,21,29,36,42,56,70 and 95 dpi). The amount of food added to each group of birds daily and the amount of feed remaining at 21 dpi were recorded to calculate the feed conversion ratio (FCR) (kg of feed/kg of body weight). Birds were moved to floor pens at 22dpi to allow for adequate space for their larger body size (FigureVI-2).

Toxoplasma gondii strains and doses used for inoculation:

Two *T. gondii* strains were used including an avirulent TgTkTn5 strain (ToxoDB genotype #5), which was isolated from a wild turkey in Tennessee (USA) and tested for virulence by mice bioassay and a highly virulent TgBbUS1 (ToxoDB genotype #147), which was isolated from a black bear in Alaska (USA). The strains were provided, propagated, and maintained on human foreskin fibroblasts (HFF) (ATCC® SCRC-1041™) in Dr. Chunlei Su's laboratory, Microbiology Department, University of Tennessee, Knoxville.

Cell culture propagated tachyzoites were collected, washed twice with phosphate buffered saline (PBS), and resuspended in sterile PBS. They were counted using Neubauer chamber hemocytometer and inverted light microscopy. Gentamicin was added to the counted tachyzoites (10ug/ml) and carried on ice to the animal research facility. Birds were injected intraperitoneally with 1 ml of PBS containing the various doses and strains of *T. gondii* (Table VI-1). Ten birds were injected with 1ml sterile PBS intraperitoneal as a control uninfected group.

Blood samples:

Jugular venipuncture was performed on 0, 7, 14, 21, 29, 36, 42, 56, 70 and 95 dpi. The 0dpi time point sera were collected immediately before infecting birds to ensure that birds were not infected with *T. gondii* prior to experimental inoculation of tachyzoites. Sera were separated

Figure VI-2. Floor pens where *Toxoplasma gondii*-infected domestic turkeys were raised from day 22 post infection until completion of experiment

from blood samples by centrifugation and were kept in -20 C degrees until tested via modified agglutination test (MAT) as described previously with minor modifications (Desmonts and Remington, 1980). Sera were two-fold diluted in PBS starting at a dilution of 1:5 to 1:5,120 prior to addition of *T. gondii* antigen. The plate containing the sera/antigen mixture was incubated at 37C overnight followed by a two hours incubation at 4C to aid in visualizing the antigen/antibody reaction. Sera collected from the same bird at different time points were run on the same MAT plate at the end of the experiment to decrease the variation due to testing conditions.

Tissue samples:

Birds were euthanized either at 31dpi (n=17) or at the end of the experiment (95dpi, n=15). Birds that showed clinical signs and poor body condition during the experiment were euthanized immediately. Telazol® 100 mg\ml (Zoetis, US) was injected at a dose of 26 mg\kg followed by cervical dislocation. Birds were necropsied and examined for gross lesions. Tissues from 15 different organs were collected from each bird; seven organ sections consisting of liver, lung, brain, pancreas, bursa, breast muscle, and heart were frozen at -20C as well as preserved in 10% buffered formalin. The remaining organ sections of spleen, kidney, eye, thigh muscle, proventriculus, gizzard, small intestine and sciatic nerve were formalin preserved only. Formalin preserved tissues were trimmed, embedded in paraffin, sectioned and stained with hematoxylin and eosin (H &E) for examination by light microscopy.

DNeasy tissue extraction kit (Qiagen, Germantown, MD) was utilized to extract DNA from approximately 350 mg of each frozen tissue sample. Extracted DNA was eluted in 50ul AE buffer and stored at -20C for quantitative polymerase chain reaction analysis (qPCR). The qPCR

was performed according to Lin et al. (2000) to amplify B1 gene of *T. gondii* using primers 5'-TCCCCTCTGCTGGCGAAAAGT-3' and 5'-AGCGTTCGTGGTCAACTATCGATTG-3'and the probe 5'-/56- FAM/TCTGTGCAA/ZEN/CTTTGGTGTATTCGCAG/3IABKFQ/-3'. The reaction mixture contained 1.0 ul of the primer and probe mix (Integrated DNA Technologies, USA), 10.0ul TaqMan master mix (applied biosystems), 0.4ul Rox reference dye and 6.6 ul nuclease free water. Finally, 2ul of DNA template was added for a final volume of 20ul for each reaction. The qPCR was performed on StepOne Real-Time PCR system, Applied Biosystems thermocycler. Initial activation of the DNA polymerase at 95C for 10 minutes was followed by 40 cycles of 95C for 15 seconds and 60C for 1 minute. The cycle threshold value (CT) was determined for each sample. The qPCR was performed on five of the ten control birds and the remaining birds were used for standard curve generation.

Quantitative PCR standard curve generation:

Brain and heart tissues of uninfected control birds were cut into pieces weighing approximately 50 mg and frozen in 1.5 ml centrifuge tube. Cell culture harvested tachyzoites of *T. gondii* RH strain were washed with PBS and counted using Neubauer chamber hemocytometer and inverted light microscopy. Tissues were spiked with different concentrations of tachyzoites with 1:10 dilutions to achieve concentrations of $1x10^6$, $1x10^5$, $1x10^4$, $1x10^3$, 100, 10, and 0 tachyzoites per mg of tissue and 0.5ul of PBS. The DNA of the spiked tissues was extracted using the aforementioned protocol. Quantitative PCR was performed, CT values were recorded, and a standard curve was generated using Excel Microsoft office using the log of the concentration values. All the CT values obtained by the qPCR were converted to concentration of tachyzoites per 1 mg of tissues (Conc) using the formula, Conc= EXP (25.7- (0.693*(CT))

where EXP is the reverse of the log. This was repeated in triplicate and the mean of the three trials was used for final calculations.

Statistics:

Statistics were performed using SPSS version 25 statistical package (IBM SPSS statistics 25). Survival rates were calculated using Kaplan-Meier analysis and displayed as cumulative survival. Repeated measures mixed model analysis of variance was used to compare weights and titers among groups. A Kruskal-Wallis was used to compare concentrations of the heart and brain by group. Chi squared test was used to compare categorical data. All tables are in appendix VI.

4. Results:

Clinical signs and bird survival:

All birds in the treatment groups remained subclinical except for three birds, two birds in GBb8 (Bird ID numbers are 1206 and 1208), and one bird in GTk8 (Bird ID number is 1221) (Figure VI-3). Bird number 1206 in GBb8 group died 7 days post infection (dpi) due to bleeding complications. The bird bled profusely after jugular venipuncture. Compression of the venipuncture site was unable to abate bleeding and the bird died in less than one minute. At 14dpi, bird 1208 in the same group displayed poor body condition, was lethargic, depressed, anorexic, and having respiratory distress. The bird was euthanized using the previously discussed protocol. In addition, on 14 dpi, bird 1221 in GTk8 group displayed acute signs of lethargy, dullness, and depression, with ruffled feathers. The bird died within an hour of displaying clinical signs. All birds in the control and low dose groups did not display clinical disease

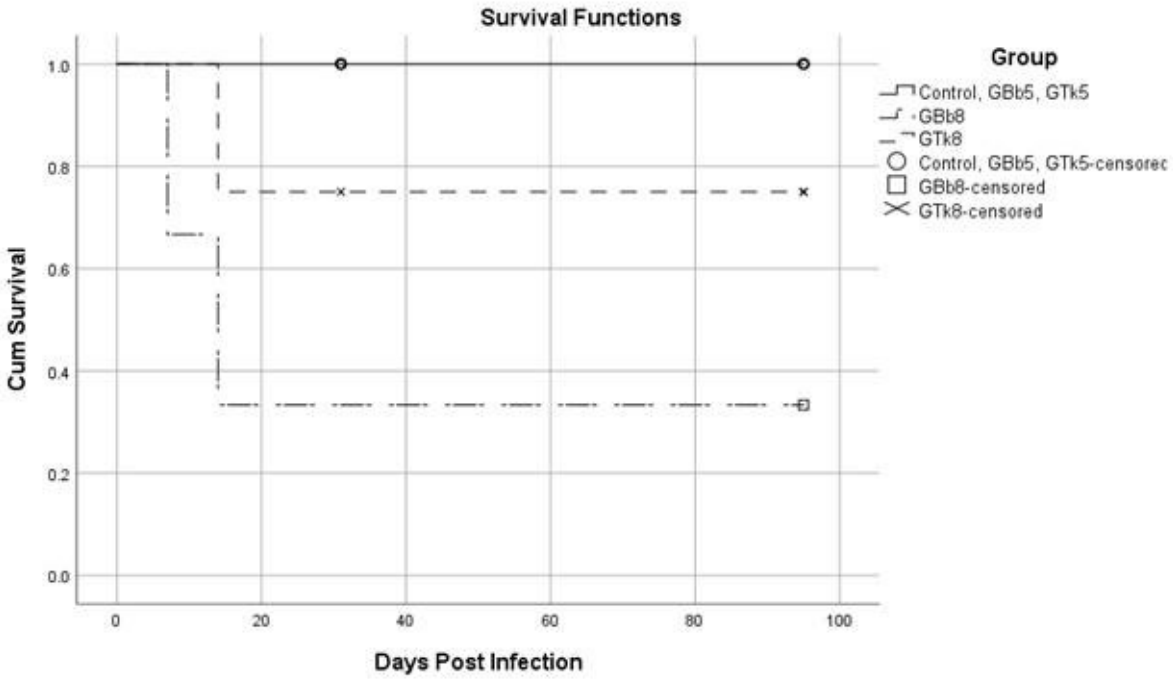

Figure VI-3. Survival rates of domestic turkeys in various treatment groups following infection with two doses and two strains of *Toxoplasma gondii.* GBb8 is infected with 10^8 virulent *T. gondii* strain, GBb5 is infected with 10^5 virulent *T. gondii* strain, GTk5 is infected with 10^5 less virulent *T. gondii* strain, GTk8 is infected with 10^8 less virulent *T. gondii* strain, and control group is injected with sterile PBS. Censored refers either death or euthanasia.

throughout the entire experiment. Birds in the control group remained seronegative throughout the entire experimental period.

Feed conversion rate (FCR):

Feed conversion rate (FCR) was calculated for the first three weeks post infection (21dpi). Low dose groups (10^5) had similar FCR of 2.2 regardless of the strain. Low dose FCRs were slightly higher than the control group but lower than the two high dose groups (10^8). Group GTk8 had a higher FCR of 2.7 and GBb8 had the highest FCR of 7.4. The control group had a FCR of 1.9, considered the normal FCR of poultry (Emmerson, 1997). (Table VI-2).

Body weight:

The group mean weights were not significantly different among the 5 treatment groups at the beginning of the experiment (0dpi). Due to the low survival rate of GBb8, only the weights at the first 3 time points (0dpi, 7dpi and 14dpi) were analyzed to include all groups followed by analysis on all the time points after exclusion of GBb8 (Table S-VI-1). Comparing the mean weights of all groups at 0dpi, 7dpi and 14dpi showed a significant interaction between dpi and weight gain ($F(8,57.01) = 8.556$, $p<0.001$) indicating weight changed differently for at least one group during the first 14 days. We further compared the groups at 0dpi, 7dpi and 14dpi to detect the exact time point where this significant change occurred. Groups did not differ at 0dpi ($p=0.535$) or 7dpi ($p=0.140$) but they did significantly differ ($p=0.002$) at 14dpi. Pairwise comparisons were made with a Bonferroni adjustment to compare groups at 14dpi. GBb8 significantly differed from all groups ($p<.05$). No other group differences were found indicating that GBb8 had significantly lower weight than the other groups at 14dpi ($F(4,28) = 5.778$, $p=0.002$) (Figure VI-4). When group GBb8 was excluded, to avoid having one bird in this

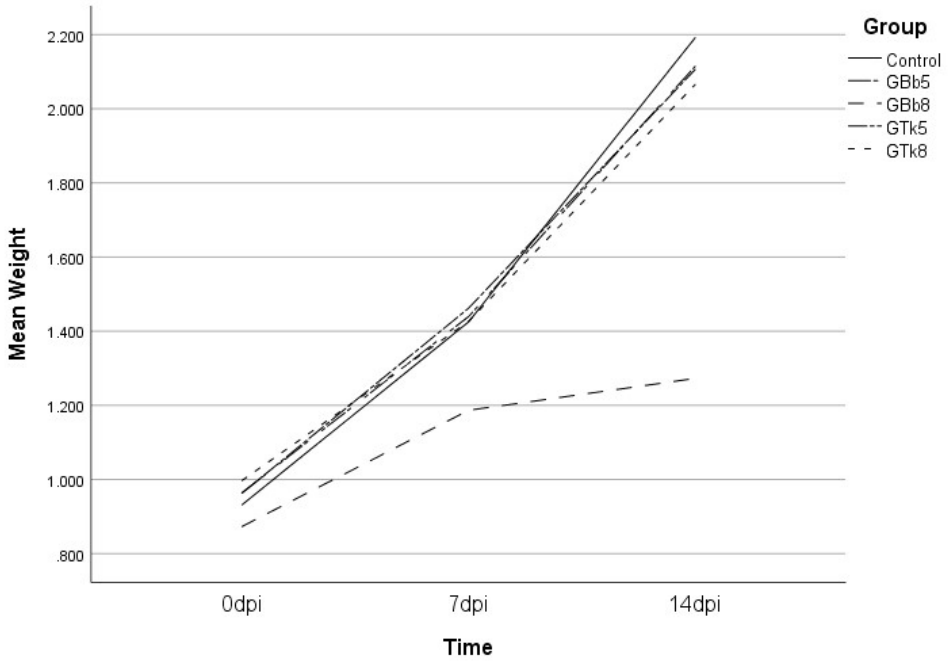

Figure VI-4. Difference in domestic turkey mean weights of all treatment groups in the first three timepoints 0dpi, 7dpi, 14dpi. GBb8 is infected with 10^8 virulent *T. gondii* strain, GBb5 is infected with 10^5 virulent *T. gondii* strain, GTk5 is infected with 10^5 less virulent *T. gondii* strain, GTk8 is infected with 10^8 less virulent *T. gondii* strain, and control group is injected with sterile PBS.

group at 21dpi, there was no significant effect of treatment groups (p=.902) or time post infection on weight gain (p=.268). Time alone was significant (p<.001) indicating weight changed over time the same for all groups including control (Figure VI-5).

Modified agglutination test (MAT) titers:

All birds were MAT negative at < 1:5 before the infection. All the birds seroconverted after being infected with *T. gondii* except for two birds (23/25, seroconversion rate is 92%), one in group GTk5 and one was in group GBb5. The control group remained *T. gondii* seronegative by MAT throughout the whole experiment. Antibody titer means of all groups were compared only at 0dpi and 7dpi due to mortality in group GBb8 following 7dpi. Antibody titers were compared for all the groups at all the time points following exclusion of GBb8. When comparing all groups at 0dpi and 7dpi, there was a significant time by group interaction ($F(4,30) = 13.998$, $p<.001$). Subsequently, we compared the groups at 7dpi due to all the groups being negative at 0dpi. GBb8 significantly differed from all other groups (p<.001) at 7dpi (Figure VI-6). No differences were found between the other groups once GBb8 was excluded.

Comparing MAT results for all time points for GBb5, GTk5, GTk8 and control groups, significant time by group interaction ($F(27,142.65) = 2.024$, $p=.004$) was found (Figure VI-7). For each group, all the time points were compared to the 0dpi timepoint to detect when the titers significantly differed from zero to indicate seroconversion. Antibody titers differed significantly at 29dpi and 36dpi for groups GBb5 (p=.006 and p=.042 respectively) and GTk5 (p=.002 and p=.002 respectively). For GTk8, 21dpi (p=.016), 29dpi (p<.001) and 36dpi (p=.006) timepoints differed significantly from 0dpi timepoint.

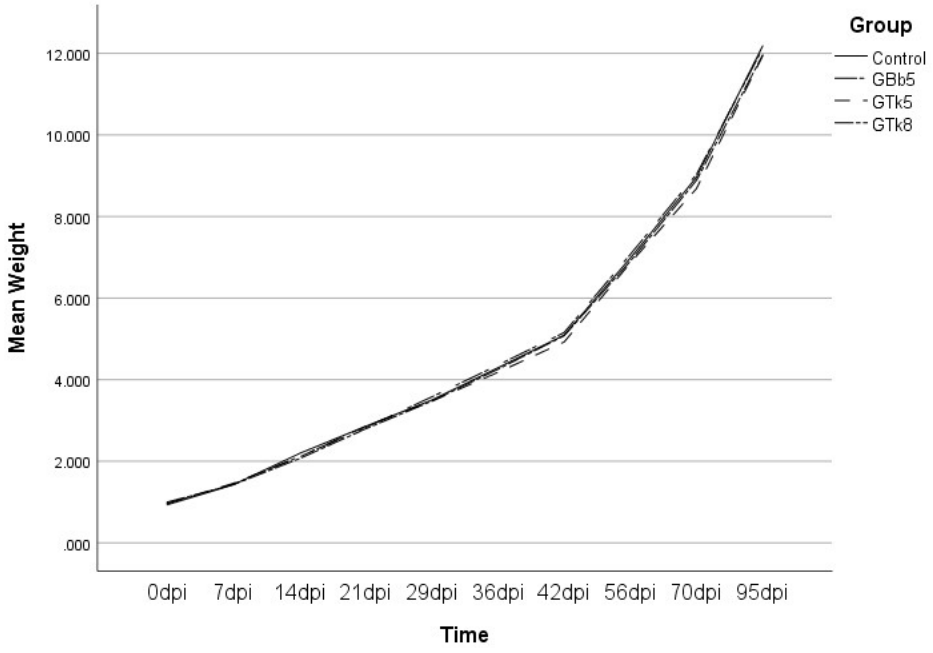

Figure VI-5. A graph showing the difference in mean weight of domestic turkeys between groups GBb5, GTk5, GTk8 and control over the whole experiment time. GBb5 is infected with 10^5 virulent *T. gondii* strain, GTk5 is infected with 10^5 less virulent *T. gondii* strain, GTk8 is infected with 10^8 less virulent *T. gondii* strain, and control group is injected with sterile PBS.

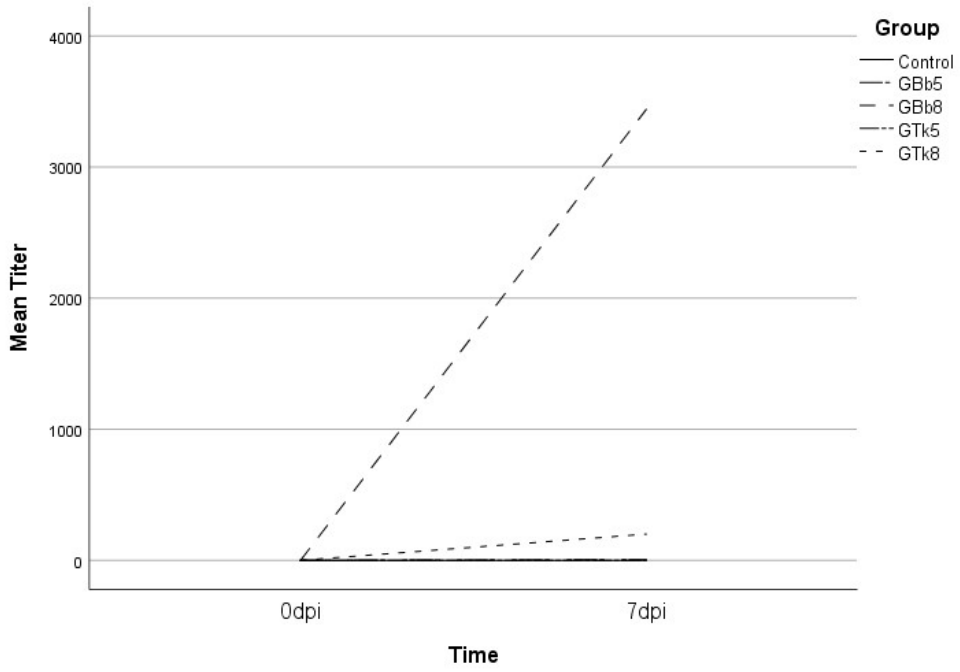

Figure VI-6. Difference between *Toxoplasma gondii* mean antibody titers tested by modified agglutination test between all domestic turkey groups at 0dpi and 7dpi. GBb8 is infected with 10^8 virulent *T. gondii* strain, GBb5 is infected with 10^5 virulent *T. gondii* strain, GTk5 is infected with 10^5 less virulent *T. gondii* strain, GTk8 is infected with 10^8 less virulent *T. gondii* strain, and control group is injected with sterile PBS.

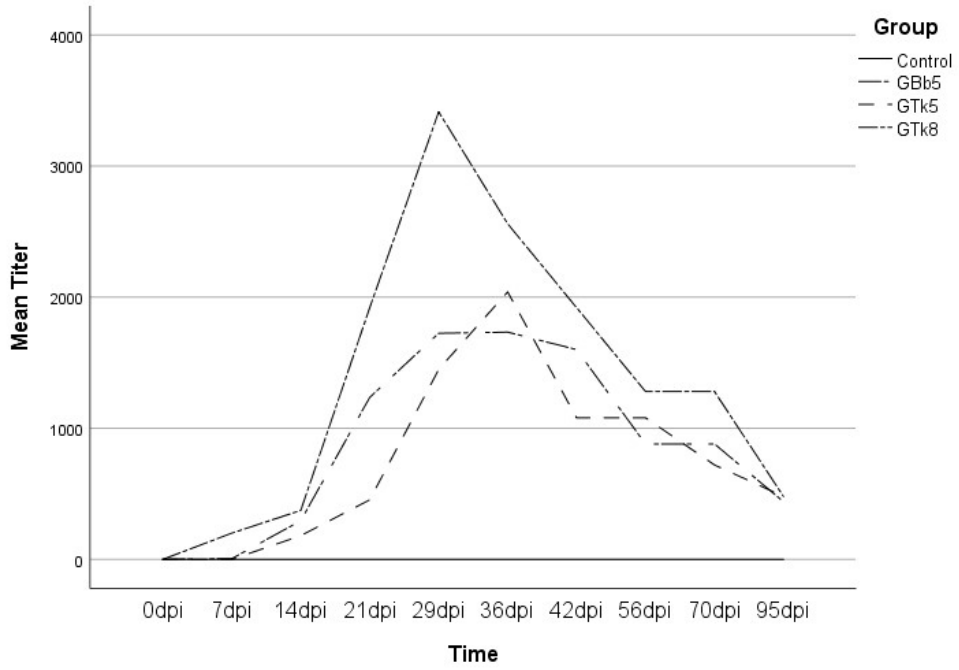

Figure VI-7. Difference between mean *Toxoplasma gondii* antibody titers of domestic turkey treatment groups GBb5, GTk5, GTk8, and control groups at all timepoints as tested by modified agglutination test. GBb5 is infected with 10^5 virulent *T. gondii* strain, GTk5 is infected with 10^5 less virulent *T. gondii* strain, GTk8 is infected with 10^8 less virulent *T. gondii* strain, and control group is injected with sterile PBS.

Repeated measures mixed model analysis was run separately for timepoints 29dpi and 36dpi to compare antibody levels between groups. No difference was found at 29dpi (p= .221) or 36dpi (p=.870) timepoints. In conclusion, the mean antibody titers at 29 and 36dpi were significantly higher compared to 0dpi for all groups while the higher dose (GTk8) of the infection was also significantly higher a week earlier (21dpi).

Quantitative polymerase chain reaction (qPCR) results:

We tested seven tissues from 30 different birds (25 infected birds and five controls) for the presence of *T. gondii* DNA by qPCR. We detected *T. gondii* DNA in 48 various tissue samples out of 209 total tissues tested (23%). Bursa of Fabricius tissue samples were accidently omitted from one bird. All tissues from the control group tested negative by qPCR (Table VI-3). Twenty out of 25 (80%) *T. gondii*-infected birds had at least one *T. gondii* DNA positive tissue. Of the five *T. gondii* infected birds that had all qPCR-negative tissues, three birds were from GBb5 and two from GTK5. *Toxoplasma gondii* DNA was detected in five out of seven organ tissues of bird number 1206 that died 7dpi in GBb8 and it was detected in all seven tissues tested in the two birds that died 14dpi in GBb8 and GTk8. The total percentage of *T. gondii* DNA positive tissues for the three birds having acute death was 90.5% (19/21)

When comparing *T. gondii*-infected birds at the two points of euthanasia (31 and 95dpi), we detected *T. gondii* DNA in 10 out of 77 tissues (13%) of the 31dpi birds, while we detected *T. gondii* DNA in 19 out of 76 tissues (25%) of the 95dpi euthanized birds. Using chi squared test, bursa of Fabricius, heart, liver, pancreas and breast muscle were more frequently positive in the acutely infected birds (Birds that died 7dpi or 14dpi). Brain was most frequently positive in late

euthanized birds (95 dpi) and lung was not significantly different at any time of death or euthanasia (Table S-VI-2).

Generally, brain tissue (72%) was the most frequently infected tissue in *T. gondii* infected birds followed by the heart (40%), bursa of Fabricius (20.8%) and lung (20%) (Table VI-4). The high dose groups (GTk8 and GBb8) had the higher percentage of tissues infected (60.7% and 61.9% respectively) while GBb5 had the lowest percentage of 9.5% (Table VI-3). When comparing groups using chi squared test, brain was significantly more frequently positive in all groups compared to control group (p=.009). Liver (p= 0.006), bursa of Fabricius (p=.018) and pancreas (p=.005) were significantly more positive in GBb8 compared to the other groups. Heart (p=.001), breast muscle (p=.029) and pancreas (p=.005) were more frequently positive in GTk8 compared to other groups. Frequency of infection of lung tissue was not significantly different between groups (p=.162) (Figure VI-8).

Concentrations of *T. gondii* tachyzoites in 1mg of tissues was estimated depending on the standard curve generated (Figure VI-9). The sensitivity of the qPCR used was 10 tachyzoites/mg tissue. The highest concentration of *T. gondii* was detected in the lung tissues of bird #1208 and #1221 in groups GBb8 and GTk8, respectively (Table S-VI-2). The two birds had respiratory distress before euthanasia or death. The concentrations, based on standard curve, were 607,302.9 and 604,447.8 tachyzoites per mg of tissue respectively. Kruskal-Wallis analysis was performed on heart and brain tissues due to having few qPCR positive samples from other organs. The concentration of the *T. gondii* was not significantly different in heart tissues of various groups (p= .052). However, GBb8 had a higher concentration (337.35 tachyzoites/mg tissue) than the other groups but was likely not significant due to small sample size. The median for *T. gondii* DNA concentration in brain tissue was significantly different between groups (p= .014). A post

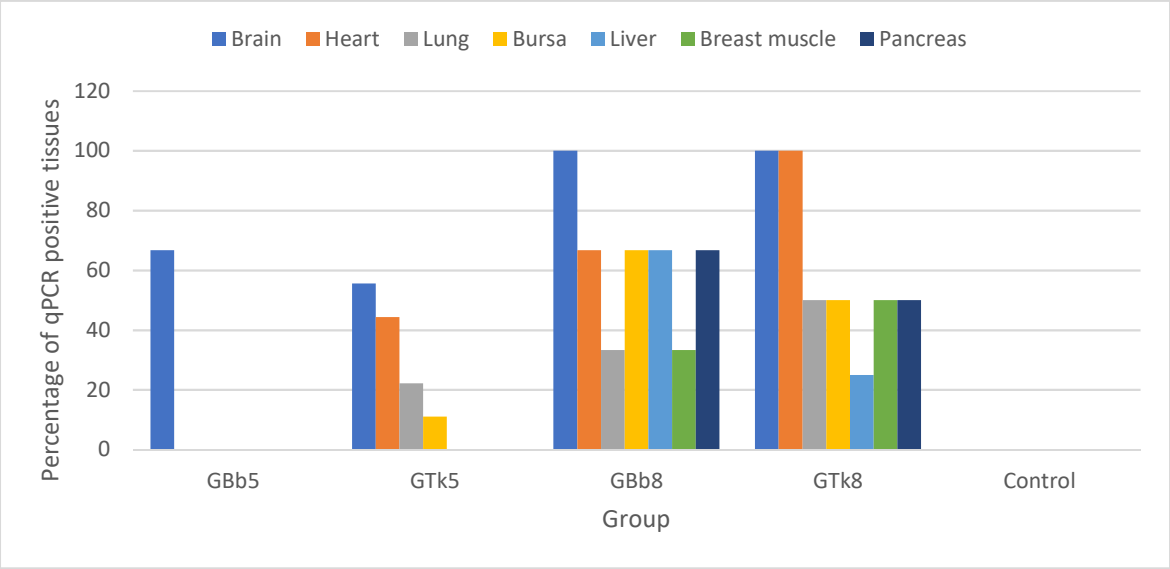

Figure VI-8. Percentage of *Toxoplasma gondii* DNA positive tissues from each treatment group. GBb8 is infected with 10^8 virulent *T. gondii* strain, GBb5 is infected with 10^5 virulent *T. gondii* strain, GTk5 is infected with 10^5 less virulent *T. gondii* strain, GTk8 is infected with 10^8 less virulent *T. gondii* strain, and control group is injected with sterile PBS.

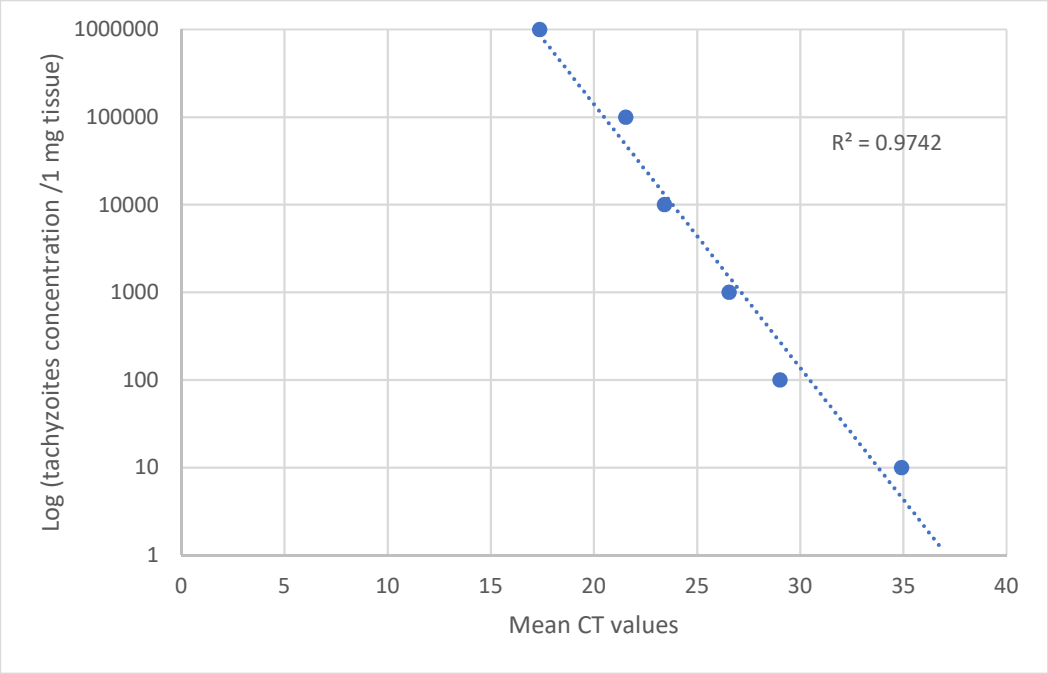

Figure VI-9. Establishment of a standard curve to quantify *T. gondii* tachyzoites in tissues of infected turkeys. Heart and brain tissues form control non-infected birds were spiked with tachyzoites concentrations ranging from 10 to 10^6 tachyzoites /1 mg tissue. CT values are plotted against log (tachyzoites concentration/1 mg tissue). Curve represents the mean of data of three independent experiments.

hoc test was not performed due to the small group sizes but GTk8 had a higher median value (265.13 tachyzoites/ 1mg tissue) compared to other groups (Table VI-5).

Tissue Lesions:

All tissues were examined thoroughly for any gross lesions at necropsy and then H&E stained slides were examined by Nathan Hoggard, a second-year pathology resident at the Biomedical and Diagnostic Sciences Department, University of Tennessee, Knoxville. Only bird #1221 from group GTk8 had gross lesions consisting of multifocal necrotic lung lesions and multifocal, pale-tan, 2-3 mm diameter areas of necrosis surrounded by a thin, dark-red rim of inflammation in the pancreas (Figure VI-10). Corresponding to these gross lesions, histologically the pulmonary parenchyma was randomly expanded by multifocal, poorly-demarcated, up to 2 mm diameter nodules composed of coagulative and lytic necrosis mixed with sheets of lymphocytes, plasma cells, fewer macrophages (Figure VI-11 a), and frequent 20 x 15 micrometer protozoa cysts having a thin wall surrounding numerous, 1-2 micrometer bradyzoites. Inflammatory cells and protozoal cysts occasionally bordered small-caliber vessels with segmental to diffuse, transmural fibrinoid vascular necrosis. The pancreas was randomly replaced by few, circumscribed, circular areas of central coagulative and lytic necrosis that were surrounded by up to 5 layers of primarily lymphocytes, few macrophages, and infrequent plasma cells, which extended radially into the adjacent viable exocrine acini (Figure VI-11 b). Few similar protozoal cysts within the neuropil and intracellular in the neurons were seen in the brain tissues of the same bird. Vessels throughout the gray and white matter were surrounded by cuffs of lymphocytes, plasma cells, and few macrophages. The intervening neuropil had increased glial cells (gliosis) that frequently formed discrete aggregates (glial nodules). Few cardiomyocytes were segmentally necrotic and bordered by lymphocytes and macrophages and

Figure VI-10. Gross lesions of domestic turkey 1221 in group GTK8 infected with 10^8 tachyzoites of less virulent *Toxoplasma gondii* strain. The lung had scattered white foci and a shiny surface (left). The pancreas had similar lesions surrounded by a dark red rim of inflammation (right).

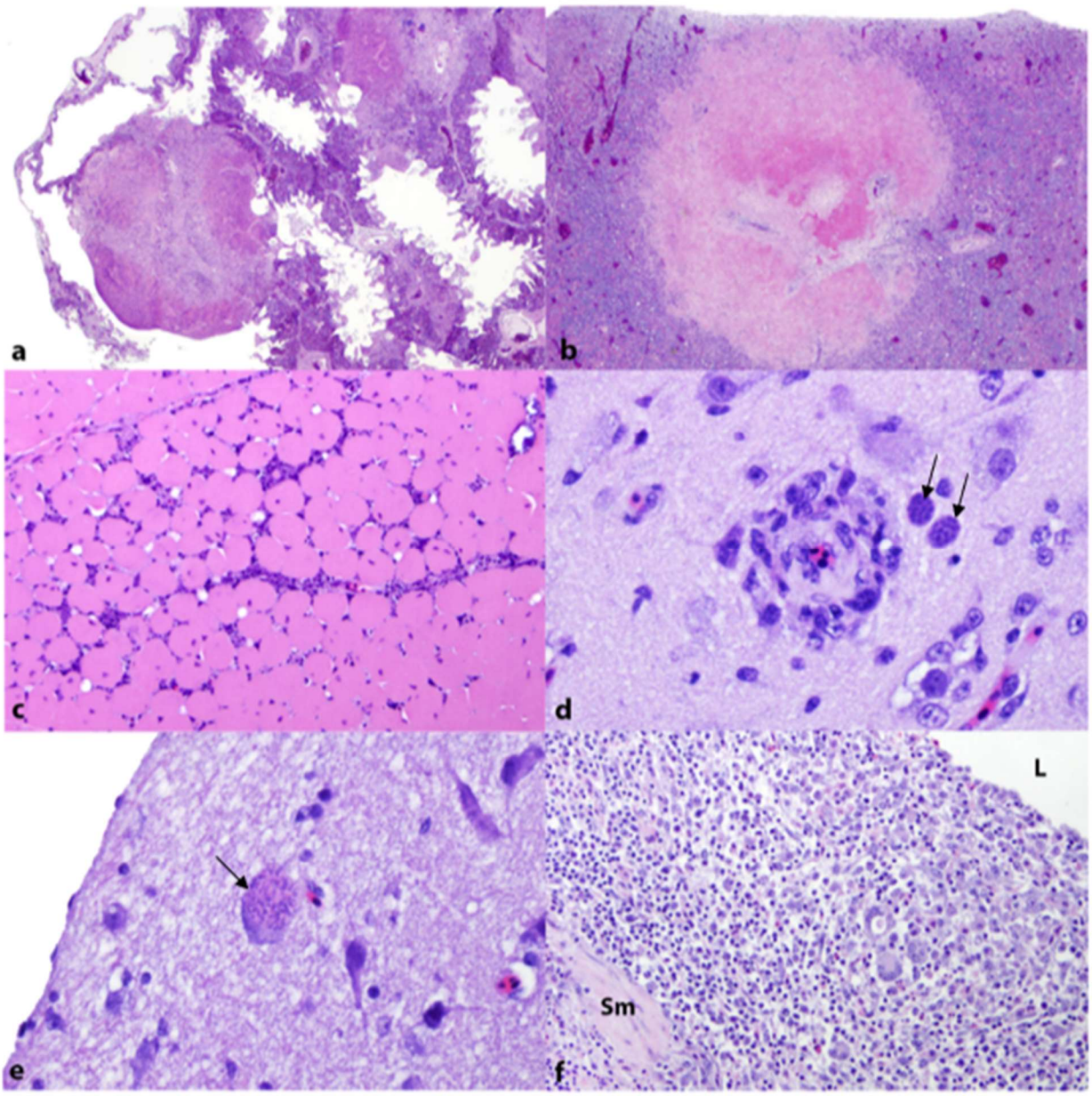

Figure VI-11. Histological findings in turkeys experimentally infected with *Toxoplasma gondii* tachyzoites. a- Lung tissue is randomly expanded by poorly demarcated, up to 2 mm diameter nodules composed of coagulative and lytic necrosis mixed with lymphocytes, plasma cells, fewer macrophages (bird #1221, GTk8, euthanized 14dpi, 2X). b- Pancreas tissue replaced by circumscribed circular nodules of coagulative and lytic necrosis similar to that seen in lung (bird#1221, GTk8, euthanized 14dpi, 2X). c- Skeletal muscle showing aggregation of lymphocytes within the endomysium (bird#1221, GTk8, euthanized 14dpi, 20X). d- Brain (cerebrum) showing two protozoal tissue cysts (Black arrows) (bird#1206, GBb8, died 7dpi, 40X). e- Brain (cerebrum) with a protozoal tissue cyst compressing a subpial neuron (black arrow) (bird#1225, GBb5, euthanized 95dpi, 40X). f- Lung showing granulomatous inflammation affecting a parabronchus (bird#1225, GBb5, euthanized 95dpi, 20X). Sm: smooth muscle; L: lumen.

similar lesions were seen in skeletal muscle (Figure VI-11 c). The spleen had a decreased density of white pulp, including periarteriolar lymphoid sheaths and associated lymphoid follicles. However, arterioles were occasionally surrounded by few layers of plasma cells. Red pulp was expanded by sheets of macrophages, hematopoietic precursor cells, and scattered, but frequent, plasma cells. Bursa of Fabricius follicles had increased central pallor, with decreased density of lymphocytes and increased numbers of histiocytes (presumed early germinal centers). The remainder of this bird tissues examined were unremarkable or had insignificant changes.

The other two birds that died acutely at 7 or 14dpi were in treatment group GBb8. Tissue cysts were seen in the lungs and brain of bird # 1208 (14dpi) and the brain of bird # 1206 (7dpi) (Figure VI-11 d). No tissue cysts were seen in the birds that survived until the end of the experiment. The lung tissues of this group (GBb8) had frequent, random, multifocal to coalescing inflammatory infiltrates of macrophages, lymphocytes, plasma cells, and few heterophils mixed with few areas of necrosis that primarily affected air capillary walls. Parabronchial walls and interparabronchial septa were expanded by proteinaceous material and a similar inflammatory infiltrate. In the brain, perivascular lymphocytic inflammation, gliosis, including activated microglia, and rare areas of necrosis were the most prominent changes. Myocardium of a single bird in this group had a focal aggregate of macrophages and few lymphocytes mixed with scant myocardial necrosis. The rest of tissues had minor or insignificant changes.

Birds in treatment group GBb5 had minor or insignificant findings in most of the tissues, except for one bird (#1225) that had a single subpial tissue cyst in the brain, without associated tissue reaction (Figure VI-11 e). In the lung, few parabronchi were segmentally to circumferentially expanded by sheets of macrophages, multinucleated giant cells, few

heterophils, lymphocytes, and plasma cells, which effaced architecture, minimally extending into the lumina (Figure VI-11 f). Rare air capillaries were filled with fibrin. Birds in GTk5 had minor or no significant changes, apart from infiltration by few macrophages and lymphocytes with minor necrosis in brain, kidney, bursa of Fabricius and sometimes lungs. Only one bird (#1212) had a single tissue cyst in the brain, without associated tissue reaction.

5. Discussion:

The present study aimed to investigate the seroconversion, feed conversion rate, weight gain pattern, and *T. gondii* tissue tropism as a function of parasite dose and virulence over the period of a conventional fattening cycle in turkeys. To achieve this aim, we intraperitoneally infected 25 domestic white turkeys (*Meleagris gallapavo*) with two different doses and strains of *T. gondii* and compared them to uninfected control birds. Infecting turkeys parenterally with *T. gondii* tachyzoites has less biohazard concern than using the environmentally resistant oocyst stage of the parasite. It also avoids the intestinal barrier, which ensures the maximum pathologic effect of the parasite (Zoller et al., 2013). We used turkeys because they are an important intermediate host of *T. gondii* and can harbor the parasite cyst in their tissues (Bangoura et al., 2013; Zoller et al., 2013). Recently, there is a shift toward consuming poultry meat over beef in the United States (Daniel et al., 2011). Also, turkeys are easy-to-handle lab animal models, and studies on birds and lab animals may help to better understand the disease progress in other animals and humans (Maksimov et al., 2018).

Domestic turkeys in this experiment were kept for a total of 122 days (about 17 weeks) to simulate the commercial fattening cycle in turkeys raised for human consumption, which lasts up to 16 weeks in female turkeys (Krautwald-Junghanns et al., 2009). Also, there is limited data on

the persistence or distribution of *T. gondii* tissue cysts in turkey meat after this period. Our results show that turkeys are generally resistant to *T. gondii* infection, and high doses of the parasite are needed to cause clinical signs (Dubey et al., 1993a). These results agree with previous studies, which documented no clinical signs in turkeys injected with up to $3x10^7$ *T. gondii* tachyzoites intramuscularly (Zoller et al., 2013) or given 10^5 oocysts orally (Dubey et al., 1993a). In this study, all the infected birds remained subclinical throughout the experiment, except for three birds in the high dose groups (10^8). One bird in GBb8 group died one week after the infection due to bleeding consequences. Data on the effect of toxoplasmosis on coagulation parameters is lacking, but it is possible that *T. gondii* may have been associated with coagulopathy in this bird. Platelets play a role in intracellular *T. gondii* growth inhibition in vitro (Chumpitazi et al., 1998), and a human case of *Toxoplasma* positive kidney transplant died after rapid decrease in the platelet count, prothrombin index, and fibrinogen (Segall et al., 2006). Humans infected with malaria, a closely related apicomplexan protozoa, had a significant thrombocytopenia compared to uninfected humans (Kotepui et al., 2014). Further studies addressing the effect of *T. gondii* on the coagulation profiles is warranted.

The other two birds that died were lethargic and in poor nutritional condition with reduced appetite and had respiratory distress before death or euthanasia. *Toxoplasma* infection is mostly subclinical in turkeys but clinical cases in wild turkeys were previously documented (Quist et al., 1995; Howerth and Rodenroth, 1985). In our experiment, the birds with clinical signs were infected with high doses of *T. gondii* tachyzoites. However, the survival of the remaining birds in these groups until the end of the experiment suggests that some birds are resistant to a high dose of *T. gondii*. Tachyzoites were injected intraperitoneally, bypassing the intestinal barrier, which would be experienced in the natural oral route of infection with oocysts

(Zoller et al., 2013). This suggests that turkeys display clinical signs under extreme conditions of infection, but further research is needed with oocyst infections to confirm this association.

Feed conversion rate (FCR) was related to *T. gondii* dose and strain used in the first three weeks after the infection while birds were housed in Petersime battery cages. Birds were moved to floor pens on 22dpi due to increased body size and the floor pen construction enabled turkeys to feed from adjacent pen feeder, negating ability to continue collecting meaningful FCR data (Figure VI-2). When a virulent *T. gondii* strain was injected at a dose of 10^8 (GBb8), birds had the highest FCR of 7.4, indicating that on average birds ingested 7.4 kg of food to produce 1 kg of meat. It should be put into account that we did not calculate the amount of food that was dropped on the ground or on the bottom of the cages. However, that was a very small amount that does not exceed few milligrams for each cage. When the same dose was used for the avirulent *T. gondii* strain (GTk8), FCR was moderately increased (2.7) compared to control group (1.9). On a large production scale, the increase in FCR over the controls can lead to substantial economical losses for producers. FCR can be affected by numerous factors including appetite, digestibility, livability, behavior and underlying diseases (Emmerson, 1997). Subclinical diseases, including toxoplasmosis, can cause substantial economical losses in large scale production farms due to failure to achieve the desired production in addition to the public health risk of consuming infected low standard meat (Skinner et al., 2010). Not only did birds in treatment group GBb8 have the higher FCR, but also significantly lower weight gain at 14dpi compared to control groups. This indicates that birds maintained a good appetite but were unable to adequately gain weight. Emaciation was previously documented in cases of clinical toxoplasmosis in wild turkeys (Quist et al., 1995; Howerth and Rodenroth, 1985).

The MAT has proven useful to detect antibody titers against *T. gondii* in turkeys (Dubey et al., 1993a) and chickens (Dubey et al., 2016). It is also a simple, low cost and effective test for detecting *T. gondii* seroprevalence in various mammals and birds (Dubey, 2010b). We tested the birds using MAT before the experiment (0dpi) to confirm they were not accidently infected with *T. gondii* prior to the experimental infection. We used a single 98-well plate to test all serum samples collected from individual birds throughout the experiment to avoid variation due to the testing conditions. All birds seroconverted after *T. gondii* infection except for two birds (seroconversion rate is 92%), one bird in GBb5 and the other in GTk5. Furthermore, we were unable to detect the *T. gondii* DNA in any tissues collected from these seronegative birds by qPCR. One person performed all the intraperitoneal injections and we also inoculated two cell culture flasks with 200ul of the tachyzoites solution following return from the animal infection facility to verify tachyzoite viability throughout the turkey inoculation process. The tachyzoites were able to invade the cells and multiply efficiently indicating live organisms were inoculated into the turkeys. The reason that these two birds did not seroconvert may be attributed to their individual immune system and further research is needed to understand this relationship.

Birds develop a good humoral immune response after *T. gondii* infection (Dubey et al., 1993a,b; Maksimov et al., 2018). Birds infected with high dose of *T. gondii* tachyzoites (10^8) in GBb8 seroconverted one week earlier (7dpi) and had significantly higher titers compared to other groups at this time point. Birds in GTk8 reached the antibody titer peak at 21dpi which is a week earlier than GTk5 and GBb5. Maksimov et al. (2018) reported earlier antibody peak at 5 weeks post infection in turkeys infected with clonal type I and II strains compared to 7 weeks in groups infected with the less virulent clonal type III strains of *T. gondii*. Birds develop antibodies in response to *T. gondii* infection that is dependent on the infectious dose and strain of the

parasite; however, we should be careful when comparing *T. gondii* antibody titers from different studies because of the different testing methods used as well as the difference in the infection route, stage, and strain of the parasite (Maksimov et al., 2018).

Although, it is thought that the parasite disseminates to the tissues after reaching the blood stream regardless of the infection route, it is hard to predict a specific pattern of *T. gondii* tissue cyst distribution in the various organs (Zoller et al., 2013). The parasite can infect any nucleated cell in the intermediate host tissues, but it has a preference for the neural and muscular tissues (Dubey et al., 1998). Although there is no significant difference found between the parenteral and oral route of infection in the total number of infected tissues, it has been found in turkeys that brain is most frequently infected if orally infected with oocyst compared to breast muscle and liver in intramuscular infections (Bangoura et al., 2013). Brain was the most frequently infected tissue in naturally and oocyst experimentally infected turkeys (Sarkari et al., 2014; Bangoura et al., 2013). Heart was also the most frequently infected tissue in oocyst experimentally infected turkeys (Dubey et al., 1993a). Our study agrees with these findings given brain (18/25, 72%) and heart (10/25, 40%) were the most frequently infected tissues followed by bursa (5/24, 20.8%) and lungs (5/25, 20%). However, Zoller et al. (2013) found brain to be the less frequently infected tissue while liver, breast muscle and heart were most frequently infected in intramuscularly experimentally infected turkeys. Dubey et al. (1993a) found a similar distribution using the mice bioassay on tissues from oocyst infected turkeys. He did not isolate the parasite from the brain or liver tissues but isolated it from heart and skeletal muscles. It should be noted that most studies select for specific tissues to test because of the inability to test each single tissue in the bird. Also, differences in the DNA extraction method, *T. gondii* genes targeted and amount of tissue samples relative to the selected organ size are important factors to

consider when comparing different studies. However, in our study *T. gondii* tissue cysts persisted for at least 95dpi in the infected organs.

We were able to detect *T. gondii* DNA in 25% (19/76) of the late euthanized (95dpi) bird tissues which is higher than the percentage in early euthanized birds (10/77, 13%). Previous studies were able to detect the parasite DNA in turkey tissues up to 9 or 12 weeks after *T. gondii* oocyst ingestion or intramuscular injection of tachyzoites, respectively (Dubey et al., 1993a; Zoller et al., 2013). The parasite was detected 100dpi in red legged partridges (*Alectoris rufa*) fed *T. gondii* oocysts at different doses (Martinez-Carrasco et al., 2005). A previous study showed no significant difference in frequency of *T. gondii* DNA positive tissues between early and late points of tissue examination (Bangoura et al., 2013); however, the early time point in this case was 6-8 weeks which is 2-4 weeks later than our early point of euthanasia. The detection of a higher percentage of infected tissues in late euthanized birds in our study may be attributed to the size or number of the tissue cyst in the 95dpi birds compared to 31dpi (Dubey et al., 1998). It is possible that the peak of acute clinical signs and parasite distribution in turkeys occurs at 14 dpi and not 7dpi because we detected the parasite in each single tissue tested in birds that died at 14dpi but we detected it in only 5 tissues out of 7 tested tissues in the bird that died 7dpi. Further research is needed with a larger sample size to investigate the peak of parasitemia in turkeys.

It is interesting that the two birds that died 14dpi in our study had the highest concentration of the tachyzoites in their lung tissues (607,302.9 and 604,447.8 tachyzoites/mg tissue) based on qPCR. Both birds showed respiratory distress before death or euthanasia. Bird #1221, which had focal necrotic lesions in the lung, also had a very high concentration of the parasite in the pancreas (9,496.8 tachyzoites/mg tissue) followed by bursa of Fabricius tissue (3,350.9 tachyzoites/mg tissue). While bird (#1208) had the highest concentration of the

parasites in lung tissue (607,302.9 tachyzoites/mg tissue) followed by brain (584.1 tachyzoites/mg tissue) and bursa (373.4 tachyzoites/mg tissue). Occasional protozoal cysts were seen in the lungs and pancreases of these two birds on histological examination and necrosis, accompanied by infiltration of macrophages, lymphocytes, plasma cells, and few heterophils, was prominent. Severe pneumonia with areas of consolidation in lung tissues, necrosis and monocytic cell infiltration were reported previously in clinical toxoplasmosis in wild turkeys with similar lesions in the pancreas (Quist et al., 1995; Howerth & Rodenroth, 1985).

Bursa of Fabricius, a primary lymphoid organ in birds, plays a major role in lymphocyte amplification and differentiation (Fellah et al., 2014). *Toxoplasma gondii* was previously detected in H&E stained bursa of Fabricius from experimentally infected red-legged partridge (*Alectoris rufa*) (Martinez-Carrasco et al., 2005). There is scant data available on the effect of *T. gondii* on the lymphoid organs in birds and further research is warranted given the bursa of Fabricius was the third most frequently *T. gondii* infected organ in our present study.

We observed a relationship between the dose of infection and the percent of the infected tissues. The higher dose groups, regardless of the strain, had the higher percentage of the qPCR positive tissues (Table VI-3), while the low dose groups had a lower percentage of positive tissues. Zoller et al. (2013) found no relation between the dose and the number of infected tissues after intramuscular injection of turkeys with tachyzoites. Kaneto et al. (1997) reported a dose dependent pattern in chickens with more tissue infected in high dose groups which was also reported by Bangoura et al. (2013) in *T. gondii* oocyst experimentally infected turkeys. No *T. gondii* DNA-positive tissues were reported in turkeys infected orally with low dose of *T. gondii* oocysts. Interestingly, in our low dose infection groups five birds had all seven tissues qPCR-negative.

In conclusion, turkeys are an important *T. gondii* intermediate host. They are considered naturally resistant but still can be infected and harbor *T. gondii* in their tissues. These results are specifically important from a public health point of view due to the recent increase in consumption of organically raised or otherwise outdoor raised poultry. *Toxoplasma* infections had a substantial influence on FCR which may represent a major economic issue on large scale production. The effect of *T. gondii* infection on survival rates, FCR, body weight, *T. gondii* antibody titers, frequency of infected tissues and gross and histological lesions is dose dependent and higher doses tend to have a more prominent effect. Our findings set a foundation for future work on avian and mammal experimental infections with various *T. gondii* genotypes and doses and given the increase practice of outdoor raised livestock and consumptive uses of wildlife, continual experimental infection of *T. gondii* in wild and domestic animals should be pursued.

6. Appendix VI:

Table VI-1. Experimental infection of domestic turkeys with two strains and doses of *Toxoplasma gondii*. Strains and doses used and the number of birds in each treatment group is shown below.

Group ID**	Strain and dose of *T. gondii*	N	Number of birds euthanized at 31 dpi.	Number of birds euthanized 95 dpi (End of experiment)
GBb5 (bird no. 1201 to 1205 and 1222 to 1225)	TgBbUs1 (Virulent *T. gondii* strain), $1X10^5$ tachyzoites,	9	5	4
GBb8 (Bird no. 1206 to 1208)	TgBbUs1 (Virulent *T. gondii* strain), $1X10^8$ tachyzoites	3	0*	1
GTk5 (Bird no. 1209 to 1217)	TgTkTn5 (Less virulent *T. gondii* strain), $1X10^5$ tachyzoites	9	5	4
GTk8 (Bird no. 1218 to 1221)	TgTkTn5(Less virulent *T. gondii* strain), $1X10^8$ tachyzoites	4	1†	2
Control	Sterile PBS	10	6	4

*One bird died at 7dpi and one bird was euthanized at 14 dpi due to poor condition.
†One bird died at 14dpi
**GBb8 is infected with 10^8 virulent *T. gondii* strain, GBb5 is infected with 10^5 virulent *T. gondii* strain, GTk5 is infected with 10^5 less virulent *T. gondii* strain, GTk8 is infected with 10^8 less virulent *T. gondii* strain, and control group is injected with sterile PBS.

Table VI-2. Feed conversion rate (FCR) of the various *Toxoplasma gondii*-infected treatment and control groups of domestic turkeys

Group ID**	Strain and dose of *T. gondii*	Total number of birds	Feed conversion ratio (FCR)*
GBb5	TgBbUs1, $1X10^5$ tachyzoites	9	2.2
GBb8	TgBbUs1, $1X10^8$ tachyzoites	3	7.4
GTk5	TgTkTn5, $1X10^5$ tachyzoites	9	2.2
GTk8	TgTkTn5, $1X10^8$ tachyzoites	4	2.7
Control	Sterile PBS	10	1.9

*Feed consumed ÷ weight gained in first three weeks post infection.
** GBb8 is infected with 10^8 virulent *T. gondii* strain, GBb5 is infected with 10^5 virulent *T. gondii* strain, GTk5 is infected with 10^5 less virulent *T. gondii* strain, GTk8 is infected with 10^8 less virulent *T. gondii* strain, and control group is injected with sterile PBS.

Table VI-3. Count and percent of *Toxoplasma gondii* DNA positive tissues determined by qPCR in the various domestic turkey treatment groups.

Group**	**Tissues with detected *T. gondii* DNA/Tissue with no DNA detected**	**Percent of infected tissues per group**
GBb5	6/63	9.5%
GBb8	13/21	61.9%
GTk5	12/62	19.4%
GTk8	17/28	60.7%
Control	0/35	0%
Total	48/209†	23%*

*Results increase to 27.6% when calculations consist of tissues with detected *T. gondii* DNA from infected birds only (exclude the five birds in control group).

† One bird was missing bursa tissue.

** GBb8 is infected with 10^8 virulent *T. gondii* strain, GBb5 is infected with 10^5 virulent *T. gondii* strain, GTk5 is infected with 10^5 less virulent *T. gondii* strain, GTk8 is infected with 10^8 less virulent *T. gondii* strain, and control group is injected with sterile PBS.

Table VI-4. Frequency and percentage of qPCR positive tissues from *Toxoplasma gondii* infected domestic turkeys

Tissue	*Toxoplasma gondii* DNA Positive tissue samples/Total number of tissues tested from infected birds	Percent
Brain	18/25	72%
Heart	10/25	40%
Bursa	5/24*	20.8%
Lung	5/25	20%
Pancreas	4/25	16%
Breast muscle	3/25	12%
Liver	3/25	12%

*One bird was missing the bursa tissue.

Table VI-5. Medians, maximum, and minimum of *Toxoplasma gondii* tachyzoites concentrations per mg of heart and brain tissues from experimentally infected domestic turkeys.

	Brain			Heart		
Groups*	Median	Maximum	Minimum	Median	Maximum	Minimum
GBb5	2.57	8.75	1.10	NI	NI	NI
GBb8	37.85	584.11	10.91	337.35	397.19	277.51
GTk5	13.84	72.26	2.20	4.87	9.33	2.81
GTk8	265.13	687.13	3.62	23.76	53.75	1.84

NI= not included. GBb5 was excluded from the analysis on heart tissue because all heart tissues of this group were negative by qPCR

* GBb8 is infected with 10^8 virulent *T. gondii* strain, GBb5 is infected with 10^5 virulent *T. gondii* strain, GTk5 is infected with 10^5 less virulent *T. gondii* strain, GTk8 is infected with 10^8 less virulent *T. gondii* strain, and control group is injected with sterile PBS.

Table S-VI-1. Means and standard deviations of the weight (kg) for various treatment groups of domestic turkeys infected with *Toxoplasma gondii* or saline (controls)

Group†	**day 0 pi**	**day7 pi**	**day 14 pi**	**day 21 pi**	**day 29 pi**	**day 36 pi**	**day 42 pi**	**day 56pi**	**day70 pi**	**day 95pi**
GBb5	0.96±0.08	1.44±0.12	2.11±0.13	2.83±0.19	3.58±0.23	4.36±0.30	5.16±0.36	7.07±0.44	9.04±0.56	12.12±0.61
GBb8	0.87±0.11	1.19±0.15	1.27±0.63	2.30*	2.84*	3.55*	4.1*	5.8*	7.18*	10.15*
GTk5	0.96±0.10	1.46±0.17	2.11±0.22	2.86±0.25	3.47±0.28	4.18±0.22	4.93±0.24	6.86±0.25	8.69±0.35	11.94±0.55
GTk8	1.00±0.12	1.43±0.23	2.07±0.27	2.80±0.35	3.48±0.42	4.26±0.66	5.08±0.77	6.91±0.95	8.89±1.10	11.96±0.66
Control	0.93±0.11	1.42±0.16	2.19±0.27	2.86±0.25	3.50±0.29	4.30±0.46	5.09±0.53	6.98±0.49	8.97±0.67	12.18±0.57

*values for one bird of the group due to death or euthanasia of the rest of the group individuals.

† GBb8 is infected with 10^8 virulent *T. gondii* strain, GBb5 is infected with 10^5 virulent *T. gondii* strain, GTk5 is infected with 10^5 less virulent *T. gondii* strain, GTk8 is infected with 10^8 less virulent *T. gondii* strain, and control group is injected with sterile PBS.

Table S-VI-2. Concentration of *Toxoplasma gondii* tachyzoites in 1mg tissue in various bird tissues.

Group*	Bird ID	Heart	Brain	Lung	Liver	Breast muscle	pancreas	Bursa
GBb5	1201	0	0	0	0	0	0	0
GBb5	1202	0	1.1	0	0	0	0	0
GBb5	1203	0	1.1	0	0	0	0	0
GBb5	1204	0	2.1	0	0	0	0	0
GBb5	1205	0	4.4	0	0	0	0	0
GBb5	1222	0	0	0	0	0	0	0
GBb5	1223	0	0	0	0	0	0	0
GBb5	1224	0	3.1	0	0	0	0	0
GBb5	1225	0	8.7	0	0	0	0	0
GBb8	1206	397.2	37.8	0	1.1	0	17.2	5.0
GBb8	1207	0	10.9	0	0	0	0	0
GBb8	1208	277.5	584.1	607302.9	136.3	87.4	13.3	373.4
GTk5	1209	0	0	1.0	0	0	0	0
GTk5	1210	6.0	0	4.2	0	0	0	0
GTk5	1211	0	2.3	0	0	0	0	0
GTk5	1212	9.3	72.3	0	0	0	0	missing
GTk5	1213	0	0	0	0	0	0	0
GTk5	1214	0	2.2	0	0	0	0	0
GTk5	1215	0	0	0	0	0	0	0

Table S-VI-2 (continued)

Group	Bird ID	Heart	Brain	Lung	Liver	Breast muscle	pancreas	Bursa
GTk5	1216	3.8	26.5	0	0	0	0	0
GTk5	1217	2.8	13.8	0	0	0	0	1.1
GTk8	1218	53.7	3.6	0	0	0	0	1.5
GTk8	1219	1.8	258.8	0	0	2.9	25.5	0
GTk8	1220	28.1	687.1	97.8	0	0	0	0
GTk8	1221	19.4	271.4	604447.8	37.9	326.5	9496.8	3350.9

* GBb8 is infected with 10^8 virulent *T. gondii* strain, GBb5 is infected with 10^5 virulent *T. gondii* strain, GTk5 is infected with 10^5 less virulent *T. gondii* strain, GTk8 is infected with 10^8 less virulent *T. gondii* strain, and control group is injected with sterile PBS.

CHAPTER VII

Conclusion.

Toxoplasma gondii is an intracellular protozoan parasite with an unusually large host range, occurring in numerous mammals and birds (Tenter et al., 2000). Although, toxoplasmosis is a major disease in various bird species which acts as an intermediate host, information about disease prevalence is still rare (Dubey, 2002). One of the major causes is that diagnosis of the disease is complicated as it localizes in numerous tissues in intermediate hosts (Dubey, 2010b). In the present study we documented *T. gondii* infection in 27 species of wild birds, isolated the parasite from one red shouldered hawk (*Buteo lineatus*) and experimentally infected domestic turkey with different doses and strains of *T. gondii* to track the progress of the infection in life birds to better understand the parasite pathogenesis.

Toxoplasmosis is considered a subclinical disease in many bird species. This fact combined with the wide host range including game birds, represents a potential public health risk. We documented *T. gondii* infection in various game birds tested from hunter killed birds sampled from three avian orders (Galliformes, Columbiformes and Anseriformes). Our results represent a safety concern if these birds are not handled and cooked properly. More efforts are required to study the parasite more intensively in wild birds and to educate the public and hunters on the potential zoonotic risk of improperly prepared game meat.

Detection of the parasite in migratory birds raises the question about how involved these birds are in the introduction of the parasite to new areas especially with continuous climate changes and global warming. Migratory geese have been recently suspected in the transmission of the zoonotic parasite *Toxoplasma gondii* to arctic foxes and polar bears in feline free environments (Sandstrom et al., 2013). Investigating toxoplasmosis in more migratory bird species combined with genotyping data is important to understand the epidemiology of *T. gondii*.

Testing various birds with different feeding habits and habitats for *T. gondii* exposure is crucial for our understanding of the parasite transmission dynamics. Ground feeders such as Galliformes and Columbiformes represent an excellent tool to study the environmental contamination with oocysts (Lindsay et al., 1994). We also documented the prevalence of *T. gondii* in Anseriformes and Charadriiforms and these results serve as a sentinel for contamination of water bodies in the tested areas. Cabezon et al. (2016) reported freshwater resources as a source of *T. gondii* infections in gulls. Further research is needed to investigate the source of infection of these birds such as testing water, soil, mollusks and crustaceans and to test other animals and marine mammals in the proximity.

We have proven experimentally that increasing doses of infection with *T. gondii* tachyzoites in combination with increasing strain virulence leads to a decrease in survival rate and weight gain and increase in feed conversion rate in infected turkeys (*Meleagris gallapavo)*. We tested sera collected from experimentally infected turkeys with modified agglutination test and it has been proven useful in tracking the seroconversion and antibody titers in turkeys. Seroconversion started earlier and antibody titers were significantly higher in the group infected with the higher dose of virulent *T. gondii* tachyzoites (10^8 tachyzoites /ml PBS). Although turkeys are considered resistant to *T. gondii* infection (Zoller et al., 2013; Dubey et al., 1993a), we proved that clinical toxoplasmosis can occur if birds were infected with high doses of the parasite and it is accompanied by gross and histological changes in spleen and lungs.

Although we tested a diverse species of birds for *T. gondii* exposure, there are many aspects that still need to be addressed. Further research is still needed investigate the prevalence of *T.*

gondii in the wildlife of the U.S. and to obtain a better understanding of the parasite life cycle, wildlife population impacts, and transmission dynamics.

LIST OF REFERENCES

Adamska, M. (2018). Molecular detection of *Toxoplasma gondii* in natural surface water bodies in Poland. Journal of Water and Health, 16(4), 657–660.

Ajioka, J. W., & Morrissette, N. S. (2009). A century of *Toxoplasma* research. Int J Parasitol, 39(8), 859-860.

Alsop, F. J. (2006). Smithsonian Birds of North America. NY: DK Publishing.

Ammar, S., Purple, K., Gerhold, R. *Toxoplasma gondii* prevalence in hunter-killed Mourning doves (*Zenaida macroura*) and Rock pigeons (*Columba livia*) from East Tennessee. J Wildl Dis*,* accepted.

Aramini, J. J., Stephen, C., Dubey, J. P., Engelstoft, C., Schwantje, H., & Ribble, C. S. (1999). Potential Contamination of Drinking Water with *Toxoplasma gondii* Oocysts. Epidemiology and Infection, 122(2), 305–315.

Aubert, D., Terrier, M., Dumetre, A., Barrat, J., & Villena, I. (2008). Prevalence of *Toxoplasma gondii* in raptors from France. J Wildl Dis, 44(1), 172–173.

Bangoura, B., Zoller, B., Koethe, M., Ludewig, M., Pott, S., Fehlhaber, K., Straubinger, R. K., & Daugschies, A. (2013). Experimental *Toxoplasma gondii* oocyst infections in turkeys (*Meleagris gallopavo*). Vet Parasitol*, 196*(3-4), 272-277.

Barros, L. D., Taroda, A., Zulpo, D. L., Cunha, I. A. L., Sammi, A. S., Cardim, S. T., Miura, A.C., Su, C., Machado, R. Z., Vidotto, O., & Garcia, J.L. (2014). Genetic characterization of *Toxoplasma gondii* isolates from eared doves (*Zenaida auriculata*) in Brazil. Rev Bras Parasitol Vet 23:443-448.

Bartova, E., Dvorakova, H., Barta, J., Sedlak, K., & Literak, I. (2004). Susceptibility of the domestic duck (*Anas platyrhynchos*) to experimental infection with *Toxoplasma gondii* oocysts. Avian Pathol*, 33*(2), 153-157.

Bartova, E., Sedlak, K., & Literak, I. (2009). Serologic survey for toxoplasmosis in domestic birds from the Czech Republic. *Avian Pathol, 38*(4), 317-320.

Brandao, G. P., Ferreira, A. M., Melo, M. N., & Vitor, R. W. (2006). Characterization of *Toxoplasma gondii* from domestic animals from Minas Gerais, Brazil. *Parasite, 13*(2), 143-149.

Burg, J., Grover, C., Pouletty, P., & Boothroyd, J. (1989). Direct and Sensitive Detection of a Pathogenic Protozoan, *Toxoplasma gondii*, by Polymerase Chain Reaction. Journal of Clinical Microbiology, 27(8), 1787-1792.

Burridge, M. J., Bigler, W. J., Forrester, D. J., & Hennemann, J. M. (1979). Serologic survey for *Toxoplasma gondii* in wild animals in Florida. J Am Vet Med Assoc*,* 175(9), 964-967.

Cabezon, O., Cerda-Cuellar, M., Morera, V., Garcia-Bocanegra, I., Gonzalez-Solis, J., Napp, S., Ribas, M. P., Blanch-Lazaro, B., Fernandez-Aguilar, X., Antilles, N., Lopez-Soria, S., Lorca-Oro, C., Dubey, J. P.& Almeria, S. (2016). *Toxoplasma gondii* infection in seagull chicks is related to the consumption of freshwater food resources. PLoS One, 11(3), e0150249.

Casagrande, R. A., Pena, H. F., Cabral, A. D., Rolim, V. M., de Oliveira, L. G., Boabaid, F. M., Wouters, A. T., Wouters, F., Cruz, C. E., & Driemeier, D. (2015). Fatal systemic toxoplasmosis in Valley quail (*Callipepla californica*). Int J Parasitol Parasites Wildl, 4(2), 264-267.

Casartelli-Alves, L., Boechat, V. C., Macedo-Couto, R., Ferreira, L. C., Nicolau, J. L., Neves, L. B., Millar, P. R., Vicente, R. T., Oliveira, R. V., Muniz, A. G., Bonna, I. C., Amendoeira, M. R., Silva, R. C., Langoni, H., Schubach, T. M., & Menezes, R. C. (2014). Sensitivity and specificity of serological tests, histopathology and immunohistochemistry for detection of *Toxoplasma gondii* infection in domestic chickens. Vet Parasitol, 204(3-4), 346-351.

Chumpitazi, B. F., Simon, J., Polack, B., Peyron, F., Picot, S., Ricard, J., & Ambroise-Thomas, P. (1998). Human platelet inhibition of *Toxoplasma gondii* growth. Clin Exp Immunol, 111(2), 325-333.

Commodaro, A. G., Belfort, R. N., Rizzo, L. V., Muccioli, C., Silveira, C., Burnier, M. N., Jr., & Belfort, R., Jr. (2009). Ocular toxoplasmosis: an update and review of the literature. Mem Inst Oswaldo Cruz, 104(2), 345-350.

Cong, W., Huang, S. Y., Zhou, D. H., Zhang, X. X., Zhang, N. Z., Zhao, Q., & Zhu, X. Q. (2013). Prevalence and genetic characterization of *Toxoplasma gondii* in house sparrows (*Passer domesticus*) in Lanzhou, China. Korean J Parasitol, 51(3), 363-367.

Conrad, P. A., Miller, M. A., Kreuder, C., James, E. R., Mazet, J., Dabritz, H., Jessup, D. A., Gulland, F., & Grigg, M. E. (2005). Transmission of *Toxoplasma*: clues from the study of sea otters as sentinels of *Toxoplasma gondii* flow into the marine environment. Int J Parasitol, 35(11-12), 1155-1168.

Contini, C., Seraceni, S., Cultrera, R., Incorvaia, C., Sebastiani, A., & Picot, S. (2005). Evaluation of a Real-time PCR-based assay using the lightcycler system for detection of *Toxoplasma gondii* bradyzoite genes in blood specimens from patients with toxoplasmic retinochoroiditis. *Int J Parasitol, 35*(3), 275-283.

Cook, A. J., Gilbert, R. E., Buffolano, W., Zufferey, J., Petersen, E., Jenum, P. A., Foulon, W., Semprini, A. E. & Dunn, D. T. (2000). Sources of *Toxoplasma* infection in pregnant women: European multicentre case-control study. European Research Network on Congenital Toxoplasmosis. BMJ, 321(7254), 142-147.

da Silva, A.V., & Langoni, H. (2001). The detection of *Toxoplasma gondii* by comparing cytology, histopathology, bioassay in mice, and the polymerase chain reaction (PCR). Veterinary Parasitology, 97(3):191–198.

Daniel, C. R., Cross, A. J., Koebnick, C., & Sinha, R. (2011). Trends in meat consumption in the USA. Public Health Nutr, 14(4), 575-583.

Darwich, L., Cabezon, O., Echeverria, I., Pabon, M., Marco, I., Molina-López, R., Alarcia-Alejos, O., López-Gatius, F., Lavin, S., &Almeria, S. (2012). Presence of *Toxoplasma gondii* and *Neospora caninum* DNA in the brain of wild birds. Vet Parasitol., 183(3-4):377-81.

Desmonts, G., & Couvreur, J. (1974). Congenital toxoplasmosis. A prospective study of 378 pregnancies. *N Engl J Med, 290*(20), 1110-1116.

Desmonts, G., & Remington, J. S. (1980). Direct agglutination test for diagnosis of *Toxoplasma* infection: method for increasing sensitivity and specificity. J Clin Microbiol, 11(6), 562-568.

Dobrowolski, J. M., & Sibley, L. D. (1996). *Toxoplasma* invasion of mammalian cells is powered by the actin cytoskeleton of the parasite. Cell, 84(6), 933-939.

Dubey, J. P. (1988). Long term persistence of *Toxoplasma gondii* in tissues of pigs inoculated with *T. gondii* oocysts and effect of freezing on viability of tissue cysts in pork. Am J Vet Res 49:910-913.

Dubey, J. P. (1996). *Toxoplasma gondii*. In S. Baron (Ed.), Medical Microbiology (fourth ed.). Galveston (TX): University of Texas Medical Branch at Galveston.

Dubey, J. P. (1997). Bradyzoite-induced murine toxoplasmosis: stage conversion, pathogenesis, and tissue cyst formation in mice fed bradyzoites of different strains of *Toxoplasma gondii.* J Eukaryot Microbiol, 44(6), 592-602.

Dubey, J. P. (1998a). Refinement of pepsin digestion method for isolation of *Toxoplasma gondii* from infected tissues. Veterinary Parasitology, 74(1), 75–77.

Dubey, J. P. (1998b). *Toxoplasma gondii* oocyst survival under defined temperatures. J Parasitol, 84(4), 862-865.

Dubey, J. P. (2002). A review of toxoplasmosis in wild birds. Veterinary Parasitology, 106(2), 121–153.

Dubey, J. P. (2004). Toxoplasmosis - a waterborne zoonosis. Vet Parasitol, 126(1-2), 57-72.

Dubey, J. P. (2008). *Toxoplasma*. In: Parasitic Diseases of Wild Birds. Atkinson CT, Thomas NJ, Hunter DB, editors. Wiley-Blackwell, Ames, Iowa, pp. 204-224.

Dubey, J. P. (2010a). *Toxoplasma gondii* infections in chickens (*Gallus domesticus*): prevalence, clinical disease, diagnosis and public health significance. Zoonoses Public Health, 57(1), 60-73.

Dubey, J. P. (2010b). Toxoplasmosis of animals and humans, 2nd Ed. CRC Press, Boca Raton, FL.

Dubey, J. P., & Desmonts, G. (1987). Serological responses of equids fed Toxoplasma gondii oocysts. Equine Vet J, 19(4), 337-339.

Dubey, J. P., & Frenkel, J. K. (1972). Cyst-induced toxoplasmosis in cats. J Protozool, 19(1), 155-177.

Dubey, J. P., & Jones, J. L. (2008). *Toxoplasma gondii* infection in humans and animals in the United States. Int J Parasitol*, 38*(11), 1257-1278.

Dubey, J. P., Andrews, C. D., Lind, P., Kwok, O. C., Thulliez, P., & Lunney, J. K. (1996). Antibody responses measured by various serologic tests in pigs orally inoculated with low numbers of *Toxoplasma gondii* oocysts. Am J Vet Res, 57(12), 1733-1737.

Dubey, J. P., Andrews, C. D., Thulliez, P., Lind, P., & Kwok, O. C. (1997). Long-term humoral antibody responses by various serologic tests in pigs orally inoculated with oocysts of four strains of *Toxoplasma gondii*. Vet Parasitol, 68(1-2), 41-50.

Dubey, J. P., Camargo, M. E., Ruff, M. D., Wilkins, G. C., Shen, S. K., Kwok, O. C., & Thulliez, P. (1993a). Experimental toxoplasmosis in turkeys. J Parasitol, 79(6), 949-952.

Dubey, J. P., Cortés-Vecino, J.A., Vargas-Duarte, J.J, Sundar, N., Velmurugan, G.V., Bandini, L.M., Polo, L.J., Zambrano, L., Mora, L.E., Kwok, O.C.H., Smith, T. & Su, C. (2007). Prevalence of *Toxoplasma gondii* in dogs from Colombia, South America and genetic characterization of *T. gondii* isolates. Veterinary Parasitology 145, 45-50.

Dubey, J. P., Felix, T. A., & Kwok, O. C. (2010). Serological and parasitological prevalence of *Toxoplasma gondii* in wild birds from Colorado. J Parasitol, 96(5), 937-939.

Dubey, J. P., Garner, M. W., Willette, M. M., Batey, K. L., & Gardiner, C. H. (2001). Disseminated toxoplasmosis in magpie geese (*Anseranas semipalmata*) with large numbers of tissue cysts in livers. J Parasitol, 87(1), 219-223.

Dubey, J. P., Gennari, S. M., Labruna, M. B., Camargo, L. M., Vianna, M. C., Marcet, P. L., & Lehmann, T. (2006). Characterization of *Toxoplasma gondii* isolates in free-range chickens from Amazon, Brazil. J Parasitol, 92(1), 36-40.

Dubey, J. P., Laurin, E., & Kwowk, O. C. (2016). Validation of the modified agglutination test for the detection of *Toxoplasma gondii* in free-range chickens by using cat and mouse bioassay. Parasitology, 143(3), 314-319.

Dubey, J. P., Lindsay, D. S., & Speer, C. A. (1998). Structures of *Toxoplasma gondii* tachyzoites, bradyzoites, and sporozoites and biology and development of tissue cysts. Clin Microbiol Rev, 11(2), 267-299.

Dubey, J. P., Miller, N. L., & Frenkel, J. K. (1970). The *Toxoplasma gondii* oocyst from cat feces. J Exp Med, 132(4), 636-662.

Dubey, J. P., Porter, S. L., Tseng, F., Shen, S. K., & Thulliez, P. (1992). Induced Toxoplasmosis in Owls. Journal of Zoo and Wildlife Medicine, 23(1), 98–102.

Dubey, J. P., Ruff, M. D., Camargo, M. E., Shen, S. K., Wilkins, G. L., Kwok, O. C., & Thulliez, P. (1993b). Serologic and parasitologic responses of domestic chickens after oral inoculation with *Toxoplasma gondii* oocysts. Am J Vet Res, 54(10), 1668-1672.

Dubey, J. P., Verma, S. K., Calero-Bernal, R., Cassinelli, A. B., Kwok, O. C., Van Why, K., Su, C., & Humphreys, J. G. (2015). Isolation and Genetic Characterization of *Toxoplasma gondii* from Black Bears (*Ursus americanus*), Bobcats (*Lynx rufus*), and Feral Cats (*Felis catus*) from Pennsylvania. J Eukaryot Microbiol, 62(3), 410-415.

Dumetre, A., & Darde, M. L. (2003). How to detect *Toxoplasma gondii* oocysts in environmental samples? FEMS Microbiol Rev, 27(5), 651-661.

Edvinsson, B., Lappalainen, M., & Evengard, B. (2006). Real-time PCR targeting a 529bp repeat element for diagnosis of toxoplasmosis. Clin Microbiol Iinfect, 12, 131-136.

Edwards, J. F., & Dubey, J. P. (2013). *Toxoplasma gondii* abortion storm in sheep on a Texas farm and isolation of mouse virulent atypical genotype *T. gondii* from an aborted lamb from a chronically infected ewe. Vet Parasitol, 192(1-3), 129-136.

El-Massry, A., Mahdy, O. A., El-Ghaysh, A., & Dubey, J. P. (2000). Prevalence of *Toxoplasma gondii* antibodies in sera of turkeys, chickens, and ducks from Egypt. J Parasitol*, 86*(3), 627-628.

Emmerson, D. A. (1997). Commercial approaches to genetic selection for growth and feed conversion in domestic poultry. Poult Sci, 76(8), 1121-1125.

Fellah, J. S., Jaffredo, T., Nagy, N., & Dunon, D. (2014). Development of the Avian Immune System. In K. A. Schat, B. Kaspers, & P. Kaiser (Eds.), Avian Immunology (pp. 45-63): Academic Press.

Ferreira, F. C., Jr., Donatti, R. V., Marques, M. V., Ecco, R., Preis, I. S., Shivaprasad, H. L., Vilela, D. A., & Martins, N. R. (2012). Fatal toxoplasmosis in a vinaceous Amazon parrot (*Amazona vinacea*). Avian Dis, 56(4), 774-777.

Fischer, J. R., Stallknecht, D. E., Luttrell, P., Dhondt, A. A., & Converse, K. A. (1997). Mycoplasmal conjunctivitis in wild songbirds: the spread of a new contagious disease in a mobile host population. Emerg Infect Dis, 3(1), 69-72.

Frenkel, J. K. (1981). False-negative serologic tests for *Toxoplasma* in birds. J Parasitol, 67(6), 952-953.

Frenkel, J. K., Dubey, J. P. & Miller, N. L. (1970). *Toxoplasma gondii* in cats: fecal stages identified as coccidian oocysts. Science. 167, 893–896.

Frenkel, J. K., Ruiz, A., & Chinchilla, M. (1975). Soil Survival of *Toxoplasma* Oocysts in Kansas and Costa Rica. The American Journal of Tropical Medicine and Hygiene, 24(3), 439–443.

Gazzonis, A. L., Zanzani, S. A., Santoro, A., Veronesi, F., Olivieri, E., Villa, L., Lubian, E., Lovati, S., Bottura, F., Epis, S., & Manfredi, M. T. (2018). *Toxoplasma gondii* infection in raptors from Italy: Seroepidemiology and risk factors analysis. Comp Immunol Microbiol Infect Dis, 60, 42–45.

Geissler, P.H., Dolton, D.D., Field, R., Coon, R. A., Perciva, H. F., Hayne, D. F., Soileau, L.D., George, R. R., Dunks, J. H., & Bunnell, S. D. (1987). Mourning dove nesting: Seasonal patterns and effects of September hunting. U.S. Fish Wildl Serv Resour Publ 168:33.

Geng, R., Zhang, X., Ou, W., Sun, H., Lei, F., Gao, W., & Wang, H. (2009). Diet and prey consumption of breeding Common Kestrel (*Falco tinnunculus*) in Northeast China. Progress in Natural Science, 19(11), 1501–1507.

Gennari, S. M., Raso, T. de F., Guida, F. J. V., Pena, H. F. J., Soares, H. S., & Dubey, J. P. (2017). Occurrence of antibodies to *Toxoplasma gondii* in scavenging black vultures (*Coragyps atratus*) in Brazil. Brazilian Journal of Veterinary Research and Animal Science, 54(2), 197–199.

Gerhold, R. W. & Yabsley, M. J. (2007). Toxoplasmosis in a Red-Bellied Woodpecker (*Melanerpes carolinus*). Avian Dis, 51(4), 992-994.

Gerhold, R. W., Saraf, P., Chapman, A., Zou, X., Hickling, G., Stiver, W. H., Houston, A., Souza, M. & Su, C. (2017). *Toxoplasma gondii* seroprevalence and genotype diversity in select wildlife species from the southeastern United States. Parasit Vectors, 10(1), 508.

Gilot-Fromont, E., Lélu, M., Dardé, M.-L., Richomme, C., Aubert, D., Afonso, E., Mercier, A. Gotteland, C. & Villena, I. (2012). The Life Cycle of *Toxoplasma gondii* in the Natural Environment. Toxoplasmosis - Recent Advances. Djurkovic-Djakovic O., Editor, InTech, p. 3–36.

Godoi, F. S., Nishi, S. M., Pena, H. F., & Gennari, S. M. (2010). *Toxoplasma gondii*: diagnosis of experimental and natural infection in pigeons (*Columba livia*) by serological, biological and molecular techniques. Rev Bras Parasitol Vet, 19(4), 238-243.

Guha, R., Miley, L., Aspiri, M., & Dhamija, R. (2017). Congenital Toxoplasmosis. Pediatr Neurol, 70, 81-82.

Häkkinen, I. (1978). Diet of the Osprey (*Pandion haliaetus)* in Finland. Ornis Scandinavica (Scandinavian Journal of Ornithology), 9(1), 111–116.

Happe, S., Fischer, A., Heese, C., Reichelt, D., Gruneberg, U., Freund, M., Kloska, S., Evers, S., & Husstedt, I. W. (2002). HIV-associated cerebral toxoplasmosis: review and retrospective analysis of 36 patients. Nervenarzt, 73(12), 1174-1178.

Hartley, W. J., & Dubey, J. P. (1991). Fatal toxoplasmosis in some native Australian birds. J Vet Diagn Invest 3:167-169.

Heidt, G. A., Rucker, R. A., Kennedy, M. L., & Baeyens, M. E. (1988). Hematology, intestinal parasites, and selected disease antibodies from a population of bobcats (*Felis rufus*) in central Arkansas. J Wildl Dis, 24(1), 180-183.

Hill, D. E., Chirukandoth, S., Dubey, J. P., Lunney, J. K., & Gamble, H. R. (2006). Comparison of detection methods for *Toxoplasma gondii* in naturally and experimentally infected swine. Vet Parasitol, 141(1-2), 9-17.

Hill, D., & Dubey, J. P. (2002). *Toxoplasma gondii*: Transmission, diagnosis and prevention. Clinical Microbiology and Infection, 8(10), 634–640.

Hill, D., Coss, C., Dubey, J. P., Wroblewski, K., Sautter, M., Hosten, T., Munoz-Zanzi, C., Mui, E., Withers, S., Boyer, K., Hermes, G., Coyne, J., Jagdis, F., Burnett, A., McLeod, P., Morton, H., Robinson, D., & McLeod, R. (2011). Identification of a sporozoite-specific antigen from *Toxoplasma gondii*. J Parasitol, 97(2), 328-337.

History of the Wild Turkey in America. (n.d.) Retrieved from: https://www.turkeyhunting.com/history-wild-turkey-america/

Hollings, T., Jones, M., Mooney, N., & McCallum, H. (2013). Wildlife disease ecology in changing landscapes: Mesopredator release and toxoplasmosis. Int J Parasitol Parasites Wildl, 2, 110-118.

Homan, W. L., Vercammen, M., De Braekeleer, J. & Verschueren, H. (2000): Identification of a 200- to 300-fold repetitive 529 bp DNA fragment in *Toxoplasma gondii*, and its use for diagnostic and quantitative PCR.Int J Parasitol 30, 1: 69-75.

Hotop, A., Buschtons, S., Bangoura, B., Zoller, B., Koethe, M., Spekker-Bosker, K., Hotop, S. K., Tenter, A. M., Daubener, W., Straubinger, R. K., & Gross, U. (2014). Humoral immune responses in chickens and turkeys after infection with *Toxoplasma gondii* by using recombinant antigens. Parasitol Res, 113(4), 1473-1480.

Howe, L., Hunter, S., Burrows, E., & Roe, W. (2014). Four cases of fatal toxoplasmosis in three species of endemic New Zealand birds. Avian Dis, 58(1), 171-175.

Howerth, E. W., & Rodenroth, N. (1985). Fatal systemic toxoplasmosis in a wild turkey. J Wildl Dis, 21(4), 446-449.

Howerth, E. W., Rich, G., Dubey, J. P., & Yogasundram, K. (1991). Fatal toxoplasmosis in a red lory (Eos bornea). Avian Dis, 35(3), 642-646.

Ivović, V., Vujanić, M., Živković, T., Klun, I., & Djurković-Djaković, O. (2012). Molecular Detection and Genotyping of *Toxoplasma gondii* from Clinical Samples. In toxoplasmosis recent advances, 103-120.

Jauregui, L. H., Higgins, J., Zarlenga, D., Dubey, J. P., & Lunney, J. K. (2001). Development of a real-time PCR assay for detection of *Toxoplasma gondii* in pig and mouse tissues. J Clin Microbiol, 39(6), 2065-2071.

Jiang, T., Shwab, E. K., Martin, R. M., Gerhold, R. W., Rosenthal, B. M., Dubey, J. P., & Su, C. (2018). A partition of *Toxoplasma gondii* genotypes across spatial gradients and among host species, and decreased parasite diversity towards areas of human settlement in North America. Int J Parasitol, 48(8), 611-619.

Johnson, C. K., Tinker, M. T., Estes, J. A., Conrad, P. A., Staedler, M., Miller, M. A., Jessup, D. A., & Mazet, J. A. (2009). Prey choice and habitat use drive sea otter pathogen exposure in a resource-limited coastal system. Proc Natl Acad Sci U S A, 106(7), 2242-2247.

Jokelainen, P., & Vikoren, T. (2014). Acute fatal toxoplasmosis in a Great Spotted Woodpecker (*Dendrocopos major*). J Wildl Dis, 50(1), 117-120.

Jourdain, E., Gauthier-Clerc, M., Bicout, D. J., & Sabatier, P. (2007). Bird migration routes and risk for pathogen dispersion into western Mediterranean wetlands. Emerg Infect Dis, 13(3), 365-372.

Kaneto, C. N., Costa, A. J., Paulillo, A. C., Moraes, F. R., Murakami, T. O., & Meireles, M. V. (1997). Experimental toxoplasmosis in broiler chicks. Vet Parasitol, 69(3-4), 203-210.

Kijlstra, A., & Jongert, E. (2009). *Toxoplasma*-safe meat: close to reality? Trends Parasitol, 25(1), 18-22.

Kim, K., & Weiss, L. M. (2008). *Toxoplasma*: the next 100years. Microbes Infect, 10(9), 978-984.

Kirkpatrick, C. E., Colvin, B. A., & Dubey, J. P. (1990). *Toxoplasma gondii* antibodies in common barn owls (*Tyto alba*) and pigeons (*Columba livia*) in New Jersey. Vet Parasitol 36:177-180.

Kotepui, M., Phunphuech, B., Phiwklam, N., Chupeerach, C., & Duangmano, S. (2014). Effect of malarial infection on haematological parameters in population near Thailand-Myanmar border. Malar J, 13, 218.

Krautwald-Junghanns, M. E., Ellerich, R., Bohme, J., Cramer, K., DellaVolpe, A., Mitterer-Istyagin, H., Ludewig, M., Fehlhaber, K., Schuster, E., Berk, J., Aldehoff, D., Fulhorst, D., Kruse, W., Dressel, A., Noack, U., & Bartels, T. (2009). Examination of rearing standards and health status in turkeys in Germany. Berl Munch Tierarztl Wochenschr, 122(7-8), 271-283.

Lass, A., Pietkiewicz, H., Modzelewska, E., Dumetre, A., Szostakowska, B., & Myjak, P. (2009). Detection of *Toxoplasma gondii* oocysts in environmental soil samples using molecular methods. Eur J Clin Microbiol Infect Dis, 28(6), 599-605.

Lin, M. H., Chen, T. C., Kuo, T. T., Tseng, C. C., & Tseng, C. P. (2000). Real-time PCR for quantitative detection of *Toxoplasma gondii*. J Clin Microbiol, 38(11), 4121-4125.

Lindsay, D., & Dubey, J. (2009). Long-term survival of *Toxoplasma gondii* sporulated oocysts in seawater. J Parasitol, 95(4), 1019-1020.

Lindsay, D., Dubey, J. P., & Blagburn, B. L. (1991). *Toxoplasma gondii* Infections in Red-Tailed Hawks Inoculated Orally with Tissue Cysts. The Journal of Parasitology, 77(2), 322–325.

Lindsay, D., Smith, P., & Blagburn, B. (1994). Prevalence and Isolation of *Toxoplasma gondii* from Wild Turkeys in Alabama. J. Helminthol. Soc. Wash, 61(1), 115-117.

Lindsay, D., Smith, P., Hoerr, F., & Blagburn, B. (1993). Prevalence of encysted *Toxoplasma gondii* in raptors from Alabama. J Parasitol, 79(6), 870–873.

Liu, Q., Wang, Z.-D., Huang, S.-Y., & Zhu, X.-Q. (2015). Diagnosis of toxoplasmosis and typing of *Toxoplasma gondii*. Parasites & Vectors, 8(1).

Love, D., Kwok, O. C., Verma, S. K., Dubey, J. P., & Bellah, J. (2016). Antibody Prevalence and Isolation of Viable *Toxoplasma gondii* from Raptors in the Southeastern USA. J Wildl Dis, 52(3), 653–656.

Maksimov, P., Basso, W., Zerweck, J., Schutkowski, M., Reimer, U., Maksimov, A., Conraths., F. J. & Schares, G. (2018). Analysis of *Toxoplasma gondii* clonal type-specific antibody reactions in experimentally infected turkeys and chickens. Int J Parasitol, 48(11), 845-856.

Mancianti, F., Nardoni, S., Mugnaini, L., & Poli, A. (2013). *Toxoplasma gondii* in waterfowl: the first detection of this parasite in Anas crecca and Anas clypeata from Italy. J Parasitol, 99(3), 561-563.

Martinez-Carrasco, C., Bernabe, A., Ortiz, J. M., & Alonso, F. D. (2005). Experimental toxoplasmosis in red-legged partridges (*Alectoris rufa*) fed *Toxoplasma gondii* oocysts. Vet Parasitol, 130(1-2), 55-60.

Martorelli Di Genova, B., Wilson, S. K., Dubey, J. P., & Knoll, L. J. (2019). Intestinal delta-6-desaturase activity determines host range for *Toxoplasma* sexual reproduction. PLoS Biol, 17(8), e3000364.

Massie, G. N., Ware, M. W., Villegas, E. N., & Black, M. W. (2010). Uptake and transmission of *Toxoplasma gondii* oocysts by migratory, filter-feeding fish. Vet Parasitol, 169(3-4), 296-303.

Mazzillo, F. F., Shapiro, K., & Silver, M. W. (2013). A new pathogen transmission mechanism in the ocean: the case of sea otter exposure to the land-parasite *Toxoplasma gondii*. PLoS One, 8(12), e82477.

Mead, P. S., Slutsker, L., Dietz, V., McCaig, L. F., Bresee, J. S., Shapiro, C., Griffin, P. M., & Tauxe, R. V. (1999). Food-related illness and death in the United States. Emerging Infectious Diseases, 5(5), 607–625.

Miao, Q., Han, J. Q., Xiang, X., Yuan, F. Z., Liu, Y. Z., Duan, G.,Zhu, X., & Zou, F. C. (2014). Prevalence of antibody to *Toxoplasma gondii* in black-headed gulls (*Chroicocephalus* ridibundus), Dianchi Lake, China. J Wildl Dis, 50(3), 717-719.

Miller, M. A., Gardner, I. A., Kreuder, C., Paradies, D. M., Worcester, K. R., Jessup, D. A., Dodd, E., Harris, M. D., Ames, J. A., Packham, A. E., & Conrad, P. A. (2002a). Coastal freshwater runoff is a risk factor for *Toxoplasma gondii* infection of southern sea otters (*Enhydra lutris nereis*). International Journal for Parasitology, 32(8), 997-1006.

Miller, M. A., Gardner, I. A., Packham, A., Mazet, J. K., Hanni, K. D., Jessup, D., Estes, J., Jameson, R., Dodd, E., Barr, B. C., Lowenstine, L. J., Gulland, F. M., & Conrad, P. A. (2002b). Evaluation of an indirect fluorescent antibody test (IFAT) for demonstration of antibodies to *Toxoplasma gondii* in the sea otter (*Enhydra lutris*). J Parasitol, 88(3), 594-599.

Montoya, J. G., & Liesenfeld, O. (2004). Toxoplasmosis. Lancet, 363(9425), 1965-1976.

Mucker, E. M., Dubey, J. P., Lovallo, M. J., & Humphreys, J. G. (2006). Seroprevalence of antibodies to *Toxoplasma gondii* in the Pennsylvania bobcat (*Lynx rufus rufus*). J Wildl Dis, 42(1), 188-191.

Nicolle, C., & Manceaux, L. (1908). Sur une infection á corps de Leishman (ou organismes voisons) du gondi. CR Acad Sci, 147-763.

Nicolle, C., & Manceaux, L. (1909). Sur un protozoaire nouveau du gondi. CR Acad Sci, 148-369.

Nuwer, R. (2013). Feral Cats Kill Billions of Small Critters Each Year. Retrived from https://www.smithsonianmag.com/science-nature/feral-cats-kill-billions-of-small-critters-each-year-7814590/

Pena, H. F., Gennari, S. M., Dubey, J. P., & Su, C. (2008). Population structure and mouse-virulence of *Toxoplasma gondii* in Brazil. Int J Parasitol, 38(5), 561-569.

Poole, A. F. (2019). Ospreys: The Revival of a Global Raptor. JHU Press.

Prestrud, K. W., Asbakk, K., Fuglei, E., Mork, T., Stien, A., Ropstad, E., Tryland, M., Gabrielsen, G. W., Lydersen, C., Kovacs, K. M., Loonen, M. J., Sagerup, K., & Oksanen, A. (2007). Serosurvey for *Toxoplasma gondii* in arctic foxes and possible sources of infection in the high Arctic of Svalbard. Vet Parasitol, 150(1-2), 6-12.

Quist, C. F., Dubey, J. P., Luttrell, M. P., & Davidson, W. R. (1995). Toxoplasmosis in wild turkeys: a case report and serologic survey. J Wildl Dis, 31(2), 255-258.

Reischl, U., Bretagne, S., Kruger, D., Ernault, P., Costa, J. M. (2003). Comparison of two DNA targets for the diagnosis of Toxoplasmosis by real-time PCR using fluorescence resonance energy transfer hybridization probes. BMC Infect Dis 3, 7.

Rico-Torres, C. P., Del Viento-Camacho, A., Caballero-Ortega, H., Besné-Mérida, A., Luna-Pastén, H., Correa, D., & Palma-García, J. M. (2015). First isolation of *Toxoplasma gondii* from cats of Colima, Mexico: Tissue distribution and genetic characterization. Veterinary Parasitology, 209(1–2), 125–128.

Rigoulet, J., Hennache, A., Lagourette, P., George, C., Longeart, L., Le Net, J., & Dubey, J. (2014). Toxoplasmosis in a bar-shouldered dove (*Geopelia humeralis*) from the Zoo of Clères, France. Parasite 21:62.

Rodriguez, J. B., & Szajnman, S. H. (2012). New antibacterials for the treatment of toxoplasmosis; a patent review. Expert Opin Ther Pat, 22(3), 311-333.

Roggenbuck, M., Bærholm Schnell, I., Blom, N., Bælum, J., Bertelsen, M. F., Sicheritz-Pontén, T., Sørensen, J., Gilbert, T., Graves, G., & Hansen, L. H. (2014). The microbiome of New World vultures. Nature Communications, 5(1).

Ruiz, A., & Frenkel, J. K. (1980). Intermediate and transport hosts of *Toxoplasma gondii* in Costa Rica. Am J Trop Med Hyg, 29(6), 1161-1166.

Ruiz, A., Frenkel, J. K., & Cerdas, L. (1973). Isolation of *Toxoplasma* from soil. J Parasitol, 59(1), 204-206.

Sandstrom, C. A., Buma, A. G., Hoye, B. J., Prop, J., van der Jeugd, H., Voslamber, B., Madsen, J., & Loonen, M. J. (2013). Latitudinal variability in the seroprevalence of antibodies against *Toxoplasma gondii* in non-migrant and Arctic migratory geese. Vet Parasitol, 194(1), 9-15.

Sarkari, B., Asgari, Q., Bagherian, N., Ashkani Esfahani, S., Kalantari, M., Mohammadpour, I., Ashrafmansori, M., Amerinia, M., & Sabet Sarvestani, F. (2014). Molecular and Serological Evaluation of *Toxoplasma gondii* Infection in Reared Turkeys in Fars Province, Iran. Jundishapur J Microbiol, 7(7), e11598.

Scallan, E., Hoekstra, R. M., Angulo, F. J., Tauxe, R. V., Widdowson, M. A., Roy, S. L., Jones. J. L., & Griffin, P. M. (2011). Foodborne illness acquired in the United States - major pathogens. Emerg Infect Dis, 17(1), 7-15.

Schares, G., Koethe, M., Bangoura, B., Geuthner, A. C., Randau, F., Ludewig, M., & Van der Giessen, J. (2018). *Toxoplasma gondii* infections in chickens: performance of various antibody detection techniques in serum and meat juice relative to bioassay and DNA detection methods. Int J Parasitol, 48(9-10), 751-762.

Segall, L., Moal, M. C., Doucet, L., Kergoat, N., & Bourbigot, B. (2006). Toxoplasmosis-associated hemophagocytic syndrome in renal transplantation. Transpl Int, 19(1), 78-80.

Shwab, E. K., Saraf, P., Zhu, X. Q., Zhou, D. H., McFerrin, B. M., Ajzenberg, D., Schares, G., Hammond-Aryee, K., van Helden, P., Higgins, S. A., Gerhold, R. W., Rosenthal, B. M., Zhao, X., Dubey, J. P. & Su, C. (2018). Human impact on the diversity and virulence of the ubiquitous zoonotic parasite *Toxoplasma gondii*. Proc Natl Acad Sci U S A, 115(29), E6956-E6963.

Shwab, E. K., Zhu, X. Q., Majumdar, D., Pena, H. F., Gennari, S. M., Dubey, J. P., & Su, C. (2014). Geographical patterns of *Toxoplasma gondii* genetic diversity revealed by multilocus PCR-RFLP genotyping. Parasitology, 141(4), 453-461.

Skinner, J. T., Bauer, S., Young, V., Pauling, G., & Wilson, J. (2010). An economic analysis of the impact of subclinical (mild) necrotic enteritis in broiler chickens. Avian Dis, 54(4), 1237-1240.

Speer, C. A., & Dubey, J. P. (1998). Ultrastructure of early stages of infections in mice fed *Toxoplasma gondii* oocysts. Parasitology, 116(1), 35-42.

Splendore, A. (1908). Un nuovo parassita deconigli incontrato nelle lesioni anatomiche d'une malattia che ricorda in molti punti il Kala-azar dell'uomo. Nota preliminare pel, Rev Soc Sci Sao Paulo, 3, 109–112.

Su, C., Shwab, E. K., Zhou, P., Zhu, X. Q., & Dubey, J. P. (2010). Moving towards an integrated approach to molecular detection and identification of *Toxoplasma gondii.* Parasitology, 137(1), 1–11.

Su, C., Zhang, X., & Dubey, J. P. (2006). Genotyping of *Toxoplasma gondii* by multilocus PCR-RFLP markers: a high resolution and simple method for identification of parasites. Int J Parasitol 36, 7: 841-848.

Switaj, K., Master, A., Skrzypczak, M. & Zaborowski, P. (2005). Recent trends in molecular diagnosis for *Toxoplasma gondii* infections. Clin Microbiol Infect., 11(3): 170-176.

Szabo, K. A., Mense, M. G., Lipscomb, T. P., Felix, K. J., & Dubey, J. P. (2004). Fatal toxoplasmosis in a bald eagle (*Haliaeetus leucocephalus*). J Parasitol, 90(4), 907-908.

Tammam, A. E., Haridy, M. A., Abdellah, A. H., Ahmed, S. R., Fayed, H. M., & Alsammani, M. A. (2013). Seroepidemiology of *Toxoplasma gondii* infection in women with first trimester spontaneous miscarriage in qena governorate, Egypt. J Clin Diagn Res, 7(12), 2870-2873.

Tennessee Wildlife Resources Agency website. (n.d.). Retrived from https://www.tn.gov/twra.html

Tenter, A. M., Heckeroth, A. R., & Weiss, L. M. (2000). *Toxoplasma gondii*: from animals to humans. Int J Parasitol, 30(12-13), 1217-1258.

The Cornell lab of ornithology, retrived from https://www.birds.cornell.edu/home/

Tomikel, J., Shepps, V. C., Pennsylvania, Bureau of, T., & Geologic, S. (1967). The geography and geology of Erie County, Pennsylvania. Harrisburg [Pa.]: Pennsylvania, Bureau of Topographic and Geologic Survey.

Udonsom, R., Buddhirongawatr, R., & Sukthana, Y. (2010). Is Sabin-Feldman dye test using *T. gondii* tachyzoites from animal inoculation still the best method for detecting *Toxoplasma gondii* antibodies? Southeast Asian J Trop Med Public Health, 41(5), 1059-1064.

Uterak, I., Hejlicek, K., Nezval, J., & Folk, C. (1992). Incidence of *Toxoplasma gondii* in populations of wild birds in the Czech Republic. Avian Pathol, 21(4), 659-665.

Verma, S. K., Calero-Bernal, R., Cerqueira-Cezar, C. K., Kwok, O. C., Dudley, M., Jiang, T., Su, C., Hill, D., & Dubey, J. P. (2016). Toxoplasmosis in geese and detection of two new atypical *Toxoplasma gondii* strains from naturally infected Canada geese (*Branta canadensis*). Parasitol Res, 115(5), 1767-1772.

Vitaliano, S. N., Mineo, T. W., Andre, M. R., Machado, R. Z., Mineo, J. R., & Werther, K. (2010). Experimental infection of crested caracara (*Caracara plancus*) with *Toxoplasma gondii* simulating natural conditions. Vet Parasitol, 172(1-2), 71-75.

Vollaire, M. R., Radecki, S. V., & Lappin, M. R. (2005). Seroprevalence of *Toxoplasma gondii* antibodies in clinically ill cats in the United States. Am J Vet Res, 66(5), 874-877.

Waite, D. W., & Taylor, M. (2015). Exploring the avian gut microbiota: Current trends and future directions. Frontiers in Microbiology, 6.

Wallace, G. D. (1973). Intermediate and transport hosts in the natural history of *Toxoplasma gondii*. American Journal of Tropical Medicine and Hygiene, 22(4), 456–464.

Wang, M., Meng, P., Ye, Q., Pu, Y., Yang, X., Luo, J., Zhang, N., & Zhang, D. (2014a). Detection of *Toxoplasma gondii* oocysts in soils in Northwestern China using a new semi-nested PCR assay. BMC Veterinary Research, 10.

Wang, S., Zhao, G., Wang, W., Xie, Q., Zhang, M., Yuan, C., Hassan, I. A., Liu, X., Xu, L., Yan, R., Song, X., & Li, X. (2014b). Pathogenicity of two *Toxoplasma gondii* strains in chickens of different ages infected via intraperitoneal injection. Avian Pathol, 43(1), 91-95.

Wilkins, M. J., Bartlett, P. C., Frawley, B., O'Brien, D. J., Miller, C. E., & Boulton, M. L. (2003). *Mycobacterium bovis* (bovine TB) exposure as a recreational risk for hunters: results of a Michigan Hunter Survey, 2001. The International Journal of Tuberculosis and Lung Disease, 7(10), 1001-1009.

Work, T. M., Massey, J. G., Lindsay, D., & Dubey, J. P. (2002). Toxoplasmosis in three species of native and introduced Hawaiian birds. J Parasitol, 88(5), 1040-1042.

Work, T. M., Massey, J. G., Rideout, B. A., Gardiner, C. H., Ledig, D. B., Kwok, O. C., & Dubey, J. P. (2000). Fatal toxoplasmosis in free-ranging endangered 'Alala from Hawaii. J Wildl Dis, 36(2), 205-212.

Worth, A. R., Lymbery, A. J., & Thompson, R. C. (2013). Adaptive host manipulation by *Toxoplasma gondii:* fact or fiction? Trends Parasitol, 29(4), 150-155.

Yilmaz, S. M., & Hopkins, S. H. (1972). Effects of different conditions on duration of infectivity of *Toxoplasma gondii* oocysts. J Parasitol, 58(5), 938-939.

Yu, L., Shen, J., Su, C., & Sundermann, C. A. (2013). Genetic characterization of *Toxoplasma gondii* in wildlife from Alabama, USA. Parasitology Research, 112(3), 1333–1336.

Zoller, B., Koethe, M., Ludewig, M., Pott, S., Daugschies, A., Straubinger, R. K., Fehlhaber, K., & Bangoura, B. (2013). Tissue tropism of *Toxoplasma gondii* in turkeys (*Meleagris gallopavo*) after parenteral infection. Parasitol Res, 112(5), 1841-1847.

VITA

Sawsan Ibrahim Ammar was born in Egypt. She earned her Bachelor of Veterinary Sciences degree from Sadat City University, Menofia, Egypt in 2008 and ranked the first of her classmates. She received her Master's of Clinical Pathology degree in 2012 from Sadat City University, Menofia, Egypt working on *Mycobacterium bovis* in buffaloes. Sawsan secured a competitive scholarship offered by the Egyptian ministry of Higher Education and started her Ph.D. in 2015 in Dr. Richard Gerhold's Molecular Parasitology lab at the University of Tennessee Knoxville, USA. Sawsan enjoys research on infectious zoonotic diseases.