



University of Tennessee, Knoxville

## TRACE: Tennessee Research and Creative Exchange

---

Chancellor's Honors Program Projects

Supervised Undergraduate Student Research  
and Creative Work

---

5-2011

### Skeletal Analysis of the West Site (40DV12)

Courtney L. Cox

University of Tennessee, ccox37@utk.edu

Follow this and additional works at: [https://trace.tennessee.edu/utk\\_chanhonoproj](https://trace.tennessee.edu/utk_chanhonoproj)

---

#### Recommended Citation

Cox, Courtney L., "Skeletal Analysis of the West Site (40DV12)" (2011). *Chancellor's Honors Program Projects*.

[https://trace.tennessee.edu/utk\\_chanhonoproj/1446](https://trace.tennessee.edu/utk_chanhonoproj/1446)

This Dissertation/Thesis is brought to you for free and open access by the Supervised Undergraduate Student Research and Creative Work at TRACE: Tennessee Research and Creative Exchange. It has been accepted for inclusion in Chancellor's Honors Program Projects by an authorized administrator of TRACE: Tennessee Research and Creative Exchange. For more information, please contact [trace@utk.edu](mailto:trace@utk.edu).



**Skeletal Analysis of the West Site (40DV12)**

**A Senior Honors Thesis**

Courtney Cox

May 2011



## **Abstract**

This study reports the findings of a skeletal analysis of the West site, a Middle Cumberland site located outside Nashville. The Middle Cumberland culture is a regional variation of Mississippian culture found in the Southeast. The West site is smaller than the most commonly studied Middle Cumberland sites, and this preliminary research suggests it may be different in aspects other than just size. Skeletal indications of subsistence, nutritional stress, pathological conditions, and trauma are discussed and compared to other Mississippian sites in the area. The presence of enamel hypoplasias is used to evaluate nutritional stress. Evidence for subsistence strategy is drawn from carious lesions and the presence of auditory exostoses, a pathological condition associated with aquatic activities. Cranial modification is documented in several individuals. This site is notable for showing a lack of trauma among skeletons, as well as a high prevalence of subadult burials.

## **Introduction**

The purpose of this study is to document and analyze the skeletal remains from the West site (40DV12), a small Mississippian period cemetery belonging to the Middle Cumberland culture. The analysis of skeletal remains, even though fragmentary, can elucidate possible environmental stressors, pathological conditions, and population demographics. These are analyzed and compared to other Mississippian sites in the Middle Cumberland region.



Most of the skeletal remains associated with the West Site are fragmentary, and so the characteristics examined here have been chosen to maximize the amount of comparative data. Teeth are generally well preserved, and so dental caries, abscesses, and hypoplasias were used as indicators of nutritional stress. These are less common than expected at the West site, given the known prevalence documented at other Middle Cumberland sites (Powell, 1991; Berryman, 1981). General signs of trauma reflecting interpersonal violence are examined as well, given increased incidence of violence evidenced at other later Mississippian locations (e.g., the Middle Mississippian Orendorf site; Steadman, 2008). The presence of auditory exostoses is discussed as a possible indication of an aquatic subsistence strategy. In addition to examination of these traits, a selection of metric measurements were taken as possible though the very small sample size does not permit further, meaningful analysis of these dimensions.

The West site is small, but it provides an insight into the historically underappreciated homestead lifestyle of the Mississippian period (Rogers, 1995). It is unclear if the average person interacted regularly with ceremonial centers or if smaller sites represent the norm for Middle Cumberland groups (Pluckhahn, 2010). This skeletal population paints a different picture than those from larger sites and congregation centers. The results of this study suggest that the West site represents a subset of the Middle Cumberland population focused more on aquatic subsistence than its neighbors. Both the similarities and the differences between Middle Cumberland sites provide information on the extent of cultural connectivity in this small region, a common focus of Mississippian period research (Blitz, 2010).



## **The Mississippian Period in the Southeast**

The emergence of the Mississippian period is characterized by rapid changes in many aspects of daily life as well as large-scale cultural reorganizations in the Southeast. Woodland peoples built earthen mounds and grew small amounts of food, but these practices were greatly expanded and intensified by Mississippian peoples (Kelly et al., 2007). Corn, beans, and squash were grown in large quantities, and they were heavily relied upon for subsistence. Land and food resources became more centrally controlled in response to the increased reliance on agriculture. Regional social centers grew in importance and size, adding complexities to regional and interpersonal relationships. Greater sedentism and social hierarchies occurred concurrently with the increased reliance on agriculture-based subsistence (Blitz, 2010). Several cultural centers have been identified. Two of the largest, Cahokia and Moundville, are thought to represent the height of Mississippian development (Muller, 1997). These large mound complexes demonstrate a high degree of social organization and are thought to have wide ranges of influence in Southeastern Mississippian cultures.

Ceremony was engrained in most elements of life at large cultural center, but ceremony is observed in smaller homestead sites as well (Pluckhahn, 2010). Elaborate art was incorporated in ceramics, structures, and burials. Art works also became more stylized, probably as part of the complex ceremonies that were performed at ceremonial centers, and possibly within smaller communities. Some lithic artifacts even took on a more ceremonial purpose, evidenced by their huge size and nonfunctional appearance (Marceaux and Dye, 2007). Anthropomorphic figurines and animal effigy ceramics are



common at Southeastern Mississippian sites. Shell was used to make gorgets, jewelry, and as a temper for ceramics (Sullivan, 2007). Variations in art across the Southeast may indicate different cultural groups, or this variation could serve to identify smaller communities within one cultural group.

In addition to changes in political economics, ceremony, and subsistence, there is evidence for intensification in violence in the Southeast during the Mississippian period (Smith, 2003). This was possibly related to competition between regional chiefdoms (Sullivan, 2007). Skeletal remains from this period show signs of scalping and traumatic fractures. Violence is often inferred from the shift to fortified settlements with palisades encircling the habitation areas, crops, and cemeteries (Smith, 2003).

### **The Middle Cumberland Culture**

The West site belongs to the Middle Cumberland culture, an isolated manifestation of Mississippian culture centered in the Nashville Basin area of Tennessee. The Middle Cumberland culture was initially identified by the type of stone box grave found in the area, and in the past it was called “the stone grave race” and “Gordon people” (Ferguson, 1972). Ferguson suggested a regional occupation from A.D. 1200-1700, but Ian Brown revised this to A.D. 1050-1600 (Ferguson, 1972; Brown, 1981). Kevin Smith further restricted the Middle Cumberland to A.D. 1050-1450 and divided it into the Dowd and Thruston regional phases. Small, dispersed groups typify the Dowd phase (A.D. 1050-1250), while the Thruston phase (A.D. 1250-1450) shows an increase in larger, fortified towns with palisades (Moore et al., 2006; Smith, 1992). The settlements in the Cumberland River Valley were quickly abandoned at the end of the Thruston phase, so no accounts exist from the European contact period. Several theories have been put forward concerning this rapid



disappearance—dietary stress, disease, warfare, and overpopulation are commonly cited (Berryman, 1981; Eisenberg, 1991; Moore et al., 2006). The reasons for such a rapid disappearance may never be understood, but the multitude of Middle Cumberland sites can together give an indication of subsistence and lifestyle in the absence of ethnographic accounts.

The Middle Cumberland Culture is still most readily identified by extensive stone box cemeteries. Stone box graves are found through the Southeast and in the lower Midwest, but they are highly variable in size, shape, and construction material. Those in the Middle Cumberland are long and narrow with flat capstones to accommodate extended burials. They are most commonly constructed from the limestone slabs found in the area, but they can be made from slate, shale, bark, and many other materials (Brown, 1981). The graves could be more accurately described as “stone-lined,” because they are assembled inside a previously prepared excavated grave. Several slabs of limestone line the edges, but the floor of the grave is usually left bare. The grave is sealed with large slabs of limestone after the burial, and it is recovered with dirt. The boxes range from haphazard construction with a bare floor to well made and precise walls with a shell floor. Dowd (1972) suggests that the quality of the stone box may be a status marker, but regional variation in available material accounts for at least some of the differences in construction. Some sites show evidence that the graves were reopened long after the original burial event so the boxes could be “reused.” The remains of the first individual could be pushed to one end to make room for a second individual (Brown 1981). This specific suite of characteristics seems to be unique to the Middle Cumberland Valley.



### **The West Site (40DV12)**

The West site is located in Davidson County, Tennessee on the Cumberland River (Figure 1). The village associated with the site lied along the Cumberland River, though it was never extensively excavated. The cemetery was located about 400 feet north of the village, which was nestled in a bend in Tidwell's Branch, a small stream forming the northern site boundary. One radiocarbon date of A.D. 1360 supports the assumption that the site was Late Mississippian, Thurston regional phase (Wright et al., 1973; Smith, 1992). John Dowd excavated the West site beginning in 1967, and a basic site report was published in 1972.

The cemetery represents a portion of the site described as the "toe" by Dowd (1972), and it is enclosed by the Cumberland River and the tree line. The habitation portion of the West site is not the focus of Dowd's site report or any subsequent research on the site. The burials are arranged linearly in clusters as well as scattered throughout the "toe" area of the site (Figure 2). The diversity in mortuary practices is shown by the placement, construction, and composition (number of individuals, sex, etc.) of the burials, which vary independently.



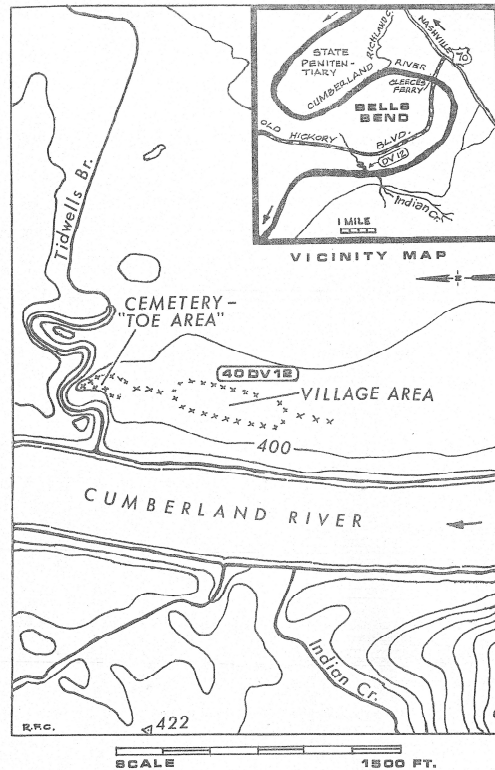


FIGURE 2. Location of West Site.

**Figure 1.** (From Dowd, 1972)

Dowd excavated the remains of 82 individuals, including men, women, and juveniles, as well as one dog. His original report lists 50 known burials, but only the material from 31 of these burials was donated to The University of Tennessee; 15 of the burials contained the remains of one individual while the other 16 burials had remains from at least two individuals. The University of Tennessee's collection contains the partial skeletal remains of 46 individuals, with teeth and cranial fragments being the most common elements. A paper written in 1973 by Wright, Stout, and Bass and the 1972 site report are the only existing pieces of literature that specifically describe the mortuary sample from the West site. Wright (1973) established a basic biological profile and



described some pathological conditions for each individual, and osteometric data for the more complete individuals can be found in this report.

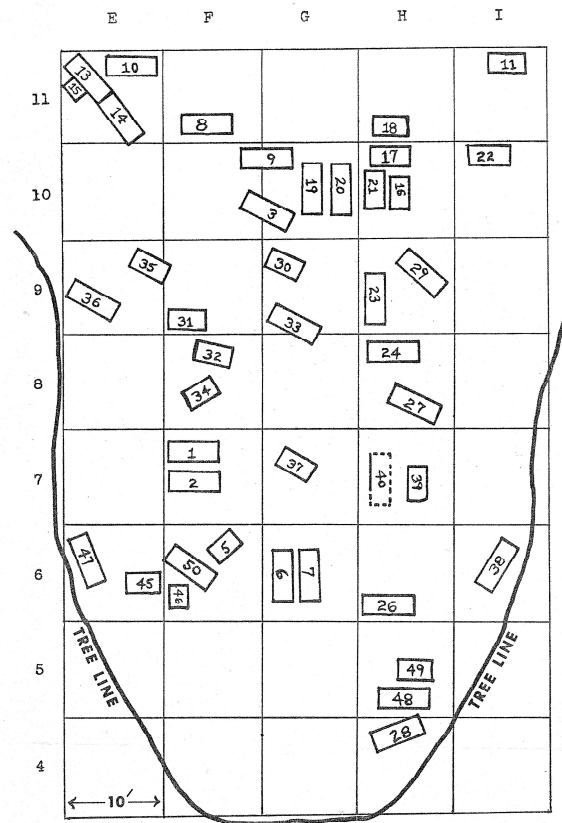


FIGURE 3. Main Cemetery ("Toe" Area) of West Site.

**Figure 2.** (From Dowd, 1972)

This study expands on these previous studies by describing skeletal traits associated with the cultural changes summarized above among individuals from other Middle and Late Mississippian sites. As noted, stresses associated with intensification of agriculture, sedentism, and violence are associated with the Mississippian period, but very little or no indication of these cultural elements can be seen at the West Site. Temporally, this site is perfectly situated in the Late Mississippian, but its geographic isolation may



have led to differences in patterns of adoption of Mississippian culture and broader regional trends. Alternatively, the isolation may have been intended as a protective measure from the violence in the area.

A detailed description of some of the traits examined, as well as site specific demography follows. Appendix A contains detailed descriptions of each individual, with specific focus on sex, age, pathological conditions, and anomalous traits. Appendix B lists the most pertinent information from Appendix A.

### **Site Demographics**

This skeletal collection is well suited for demographic analysis because the cemetery was completely excavated and well documented. The length of occupation is unclear, but this cemetery does not represent a single burial event. Some of the graves were reopened and reused after the first individual decomposed enough for the skeletal material to be piled at one end. Age estimations are based on dental formation, eruption, or wear whenever possible because of the possible effects of malnutrition on long bone formation and length. Sex estimation is based on cranial morphology and size as well as metric data when possible.

Not all of the burials were loaned to the University of Tennessee, but in consultation with Wright et al. (1973) and Dowd (1972), there is not an apparent bias in the age or sex of the individuals available. The property owners had excavated some burials before John Dowd, and these early excavations were not loaned to the University of Tennessee, but Dowd lent all the burials he excavated. The 1972 report published by John Dowd was instrumental in verifying the integrity of the collection.



The primary method of age estimation is dental formation and eruption for subadults. Dental wear was an important age indicator for adult individuals because of the lack of postcranial material. Aging skeletons based on dental wear is problematic, as the rate of wear is idiosyncratic and varies among individuals due to status, subsistence, and biological factors, but without more complete skeletal remains, this method was chosen for aging individuals within the site. In order to develop an understanding of wear patterns for this site, a comparison was made between the dental wear patterns of several securely aged individuals from the site. For some of the adults, only a generalized age estimation of young, middle, or old was possible, but in most cases enough evidence could be compiled to suggest decadal age ranges. This method is the least accurate for older individuals, but this is not a significant concern for this study since none of the individuals are older than 40-50. In addition to dental indicators, cranial suture closure was used as a secondary indicator.

The 46 individuals available for analysis suggest that this population had a high subadult mortality rate. This may be a result of sampling bias, given the incomplete site representation and possible missing burials, or may be regarded as a general trend for modeling the site. Only 18 (33%) individuals reached adulthood, and 27 (61%) individuals are younger than 10. The raw demographic data for adults is reported in Table 1, and these data, reported as percentages, are compared with two other Middle Cumberland sites (Ganier and Arnold Village) in Table 2. Figure 3 shows the data from Table 2 graphically. These comparisons show that the proportion of subadults at the West Site is greater than the percentage found at other Middle Cumberland sites, a trend that is significantly different based on a chi-square test ( $\chi^2 = 22.39$ ;  $df = 10$ ;  $p < 0.05$ ).



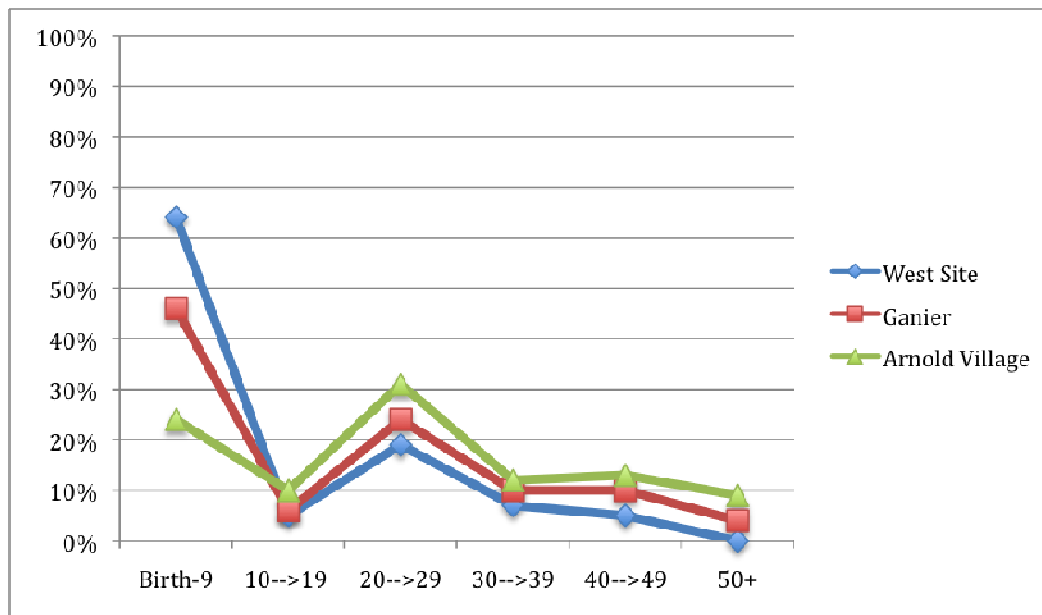
AGE GROUP	MALE	FEMALE	SEX INDETERMINATE	TOTAL
10-19	1	1	0	2
20-29	6	0	0	6
30-39	1	2	0	3
40-50+	1	1	0	2
Indeterminate	2	1	2	5
<b>TOTAL</b>	<b>11</b>	<b>5</b>	<b>2</b>	<b>18</b>

**Table 1.** Age at death of adults by sex

SITE	B-9	10-19	20-29	30-39	40-49	50+	TOTAL
West	68% (n=27)	5% (n=2)	15% (n=6)	8% (n=3)	5% (n=2)	0% (n=0)	100% (n=40)
Ganier	46% (n=31)	6% (n=4)	24% (n=16)	10% (n=7)	10% (n=7)	4% (n=3)	100% (n=68)
Arnold Village	24% (n=16)	10% (n=7)	31% (n=21)	12% (n=8)	13% (n=9)	9% (n=6)	100% (n=67)

**Table 2.** Age at death at selected Middle Cumberland sites  
(Ganier and Arnold Village data from Ward, 1972)





**Figure 3.** Graph of demographic site composition for three Middle Cumberland sites

### Dental Pathological Conditions

Dental pathology is a useful indicator of overall health because the dentition is highly susceptible to environmental stresses. The direct contact that teeth have with food makes them helpful in determining diet and general subsistence strategy. Dental development is relatively stable, even in times of stress, but nutritional stress during development can leave linear enamel hypoplasias on teeth. The dentition is important in archaeological contexts because it is durable and usually the best-preserved skeletal element.

The two pathological conditions observed in this population are carious lesions and enamel hypoplasia. These conditions can offer different information concerning the lives of the people from the West site. Dental caries are caused by bacterial growth on the teeth that break down the enamel. They have been linked to diets with high sugar intake and agriculture-based subsistence (Powell, 1991). Linear enamel hypoplasias are defects in the



enamel that are visible on the exterior surfaces of the dentition (Goodman and Rose, 1990). They are caused by nutritional stress during tooth formation, and their specific location and severity can be useful in determining the timing and duration of the nutritional stress event. Both of these conditions are common at other Mississippian sites in the Middle Cumberland region (Berryman, 1981; Goodman et al., 1984).

Dental caries and enamel hypoplasias are present in the population from the West Site but not in high frequencies, when compared to contemporary sites. 36 individuals in the collection had dentition available for analysis; 42% (15) of these have at least one carious lesion. Only 4 individuals (1.1%) have either large or multiple caries. Dental hypoplasias are present on 3 individuals. One adult female has a large abscess. In comparison, caries prevalence is 60% at the Lake George Site, and is 18.7% at Moundville (Listi, 2010; Powell, 1991). This relatively low prevalence of dental disease could suggest that the West Site was not inhabited by intensive agriculturalists. The lack of evidence of nutritional stress may also indicate that this population was utilizing aquatic resources from the Cumberland River.


### **Auditory Exostosis**

An auditory exostosis is a bony growth in the external auditory meatus (EAM). It is associated with prolonged exposure to cold water. Auditory exostoses are often bilateral and symmetrical, as opposed to osteomata, which usually appear on only one side. In modern populations this condition is most common in scuba divers, swimmers, and surfers, but in studies of prehistoric populations it has been correlated with aquatic, especially marine, subsistence strategies (Kennedy, 1986). This condition requires



prolonged exposure to cold water that is unlikely unless an individual is deliberately diving under water repeatedly for a prolonged period of time.

Two of the adult males from the West Site have bilateral auditory exostoses, and one adult female shows a milder presentation of the condition. There are 8 individuals complete enough for analysis that do not have the condition, but only one of these without auditory exostoses is an adult. The auditory exostoses in this population are extensive, and in one case extend across the entire EAM. The presence and large size of auditory exostoses in the population from the West Site supports the suggestion that aquatic resources were an important dietary staple. Shell artifacts were recovered with some of the burials, and one adult was buried in a grave with a shell floor. The mussel shells were each laid out in the same orientation and formed a solid floor (Dowd, 1972). This skeletal sample size is too small to formulate conclusions of subsistence strategy, but this research indicates that future studies of the Middle Cumberland culture should consider this condition.



**Figure 4.** Auditory Exostosis of Individual 28A



## **Cranial Modification**

The cranial modification in this collection is noteworthy because of its location and severity. The average presentation is flattening of the right lambdoidal region, extending onto the right parietal. The occipital is relatively unaffected. The left side of the cranium expands out, adding to the overall asymmetry of the cranium. One individual also shows some signs of frontal flattening, but the lambdoidal modification is much more significant. While only four individuals exhibit cranial modification, this is all of the crania complete enough for evaluation. Berryman (1975) reports frontal and occipital cranial modification of most crania from the Averbuch site, a Middle Cumberland site outside Nashville, but Berryman does not describe the extent of the modification. The West and Averbuch sites are contemporary and are only about 5 miles apart, so it is possible that they represent the same group or have some cultural interaction.

## **Trauma**

The West Site collection contains no indication of trauma, violence, or warfare. The lack of evidence for trauma is notable because it is commonly reported at other Middle Cumberland sites nearby, such as Averbuch (Berryman, 1981). At Orendorf, a Middle Mississippian site in Illinois, 9% of the entire population has warfare related trauma, including scalping, decapitation, blunt force trauma, and projectile point injuries (Steadman 2008). The prevalence of traumatic injuries at sites around the West Site and the lack of these injuries in this population may indicate that this site represents a variant of Middle Cumberland culture. The isolated location of the West Site may have been an intentional attempt to avoid the violence in the area.



## **Conclusion**

The West Site is a small Mississippian period cemetery, representative of the Middle Cumberland culture. Stone box burials are found across the Southeast, but this particular type of stone box burial is restricted to the Middle Cumberland region. The late Mississippian period is usually characterized by the intensification of maize agriculture. The West Site gives little evidence that this was the case for this population. Dental carious lesions, a common indicator of agricultural subsistence, are rare. The low prevalence of enamel hypoplasias may suggest that this population experienced less nutritional stress than other populations in the area.

Coupled with the lack of evidence for agriculture and nutritional stress, are several pieces of evidence for aquatic subsistence. The West Site is located along the Cumberland River, and mussel shells are found in association with some of the burials. Also, auditory exostosis, a pathological condition often associated with marine subsistence in South American groups is observed in this population (Kennedy 1986). The presence of auditory exostoses alone suggests intensive exploitation of the nearby aquatic resources. The distinct cranial modification seen in this population may be further suggestive of some degree of cultural isolation from other Middle Cumberland sites. Though the West site is small, its unique combination of characteristics illustrates a different way of life than is commonly seen in other, contemporary Southeastern Mississippian period sites.



## Appendix A

### Individual 14A

This individual is an adult male, represented by a left femur that was broken postmortem near midshaft and just below the lesser trochanter. It had previously been reconstructed, and available measurements are listed in Appendix B.

### Individual 16A

This individual is an infant represented by loose teeth, some mandibular fragments, and three long bone shaft fragments.

### Individual 16B

This is an adult of indeterminate sex, represented by the entire left patella and a coronoid process of the mandible.

### Individual 17A

This individual is an infant represented by two mandibular fragments with complete deciduous dentition. The incisors exhibit less shoveling than most individuals from this population.

### Individual 19A

This individual is a young adult female. The permanent dentition is complete and free of caries, but there is some evidence of linear enamel hypoplasia on the maxillary dentition. The maxillary lateral incisors are extremely shoveled, but the central incisors are only mildly shoveled.

### Individual 19B

This individual is child younger than 10 based on the dentition. There is a large carie on the occlusal surface of the left m<sub>2</sub>.

### Individual 19C

This adult male is represented by a mandible with complete dentition. There is an enamel pearl on the distal portion of the right M<sub>3</sub>.

### Individual 19D

This is a young child represented by two mandibular fragments with complete deciduous dentition.

### Individual 20A

This is a young adult male who is represented by a fragment of the right maxilla, the entire left maxilla with the left zygomatic, and the mandible. There is a supernumerary tooth behind the left PM<sup>2</sup>.

### Individual 20C

This individual is an infant represented only by loose teeth.



#### Individual 23A

This individual is a middle-aged adult male represented by a nearly complete cranium and mandible plus the medial and distal portions of the left fibula. There is one carious lesion on the occlusal surface of the right M<sup>2</sup>. There is a lesion on the distal portion of the diaphysis of the fibula that is swollen, irregular, and pitted. The right lambdoidal region is flattened, with the flattening extending onto the right parietal. The left parietal “bulges” out in the area corresponding the flattening on the right side. The left lambdoidal suture is complex with several wormian bones while the right lambdoidal suture is more simple and lacks wormian bones.

#### Individual 23C

This individual is a younger adult male represented by the cranium minus the left side of the face. There are no caries or evidence of dental hypoplasia. There is a supernumerary tooth below the right I<sub>1</sub>. The right lambdoidal/parietal region is flattened causing an overall asymmetry of the posterior cranium. There is possibly some frontal flattening as well. The left lambdoidal suture has 1 wormian bone, and the right has 5; there is also an ossicle at lambda. Endocranially, the meningeal grooves and sulci are deep and unusually well-defined, especially on the left side. Near the sagittal sulcus, there are about 12 large foramina (~.5cm diameter). This individual exhibits large bilateral auditory exostoses on the anterior edge of the EAM.

#### Individual 23D

This individual is an adult female represented by a partial cranium and mandible. There are small caries along the CEJ of all maxillary and mandibular molars. An abscess above the left M<sup>1</sup> may have infected the left sinus, which is pitted and shows evidence of bone regeneration. There are two wormian bones in the right lambdoidal suture.

#### Individual 26A

This individual is an older child represented by the mandible and loose teeth. The maxillary permanent incisors show slight indications of dental hypoplasia. The incisors are shoveled.

#### Individual 27A

This individual is a middle-aged female represented by a complete mandible minus the coronoid processes. The right M<sub>2</sub> was lost premortem with complete bone resorption. A carious lesion is present on the occlusal surface of the right M<sub>3</sub>.

#### Individual 28A

This individual is a young adult male represented by a nearly complete cranium and a complete mandible. The right lambdoidal region is flattened more extensively than is typical of this population. There are 2 ossicles at lambda and many wormian bones. Bilateral auditory exostoses are present but asymmetrical with the left exostosis being slightly larger. There is evidence for porotic hyperostosis near lambda, but partial fragmentation of the occipital prohibits a clear picture of the area. The left M<sub>3</sub> has a large enamel bud growing from the distal root surface.



#### Individual 28B

This individual is a young adult male represented by cranial fragments, loose teeth, and both femora. The distal epiphyses have not completely united with the femoral diaphysis, and the right epiphysis is missing. There is a small carious lesion on the occlusal surface of the left M<sub>1</sub>. The incisors are shovel-shaped.

#### Individual 29A

This individual is an adult female represented by both complete femora. There are no apparent pathological conditions.

#### Individual 29B

This individual is an adult male represented by the complete right and left femora, which are free of pathological conditions.

#### Individual 30A

This individual is an infant represented by loose teeth, cranial fragments, several long bone shafts, and four rib fragments. The permanent incisors are visible, and they are shovel-shaped.

#### Individual 30B

This individual is an infant represented by cranial and facial fragments and several loose teeth. There is only slight shovel-shaping of the incisors, and there is one carious lesion of the occlusal surface of the left m<sub>2</sub>.

#### Individual 32A

This individual is a fragmentary but remarkably complete young child, maybe the most complete of the collection. Both femora, tibiae, radii, ulnae, and humeri are all present and complete. Fragments of the ilium and ischium, left and right, are present. The mandible is intact and has the complete deciduous dentition. There are clear indications of cranial modification, but the fragmentary nature of the cranium obstructs the true shape.

#### Individual 33A

This individual is an adult male represented by the left femur and tibia. There are no signs of pathological conditions.

#### Individual 34B

This individual is an infant represented by mandibular fragments, a partial left femur, and several loose teeth.

#### Individual 35A

This individual is a younger child represented by the mandible and deciduous molars. There is one maxillary fragment and some loose teeth. The incisors are shovel-shaped.

#### Individual 35B



This individual is a child represented by loose teeth and cranial fragments. There is one carious lesion on right m<sup>1</sup>.

#### Individual 37A

This individual is an older child represented by loose teeth a two maxillary fragments. There are no carious lesions.

#### Individual 38A

This individual is a middle-aged adult male represented by right and left mandibular fragments, loose teeth, and the left femur minus the greater trochanter and condyles.

#### Individual 42A

This individual is an infant represented by a mandibular fragment and some loose deciduous teeth. The left maxillary deciduous dentition from the central incisor to the second molar. The petrous portions are present and were examined, but they lack auditory exostoses.

#### Individual 43A

This individual is an older child represented by a skull that had been reconstructed previous to this study. There are several anomalies on the crania and mandible. The pattern of cranial modification that is typical of this population is clearly visible in this individual. The mandible is very square and flares out sharply; this may be related to the cranial modification because it is not symmetrical. The palatine suture is asymmetrical, with the right side being more anterior. A very large inca bone and one wormian bone are present. Also, this individual has a mild presentation of cribra orbitalia.

#### Individual 44A

This individual is a child represented by the mandible and complete deciduous dentition. There is one carious lesion on each deciduous m<sub>1</sub>.

#### Individual 45A

This individual is an infant represented by the mandible and maxilla with complete deciduous dentition. The incisors are very shovel-shaped. Fragments of the femora and tibiae are also present.

#### Individual 45B

This individual is an older infant represented by the mandible and maxilla, some facial bones, and several long bone diaphyseal fragments.

#### Individual 46A

#### Individual 47A

This is an older child represented by cranial fragments, the alveolar portion of the maxilla, and a nearly complete mandible. All teeth are also present, either still in place or loose. There is an enamel bud on the root at the CEJ of the distal portion of the right M<sub>1</sub>. The maxillary incisors are very shovel-shaped, and there is one carious lesion on the occlusal surface of right M<sup>1</sup>.



#### Individual 48A

This individual is an adult female represented by the mandible, maxilla, right zygomatic, and most of the adult dentition. The left M<sub>1</sub> was lost postmortem. There is a large carious lesion on the left M<sub>3</sub>. The maxillary incisors are shovel-shaped.

#### Individual 48B

This individual is a young child represented by loose teeth without any indication of a pathological condition.

#### Individual 48C

This individual is an older child represented by a left mandibular fragment and maxillary dentition. The incisors are deeply shovel-shaped, and there are no dental pathological conditions.

#### Individual 49A

This individual is an infant represented by loose teeth and some cranial fragments. There is one carious lesion on the lingual surface of the right i<sub>2</sub>.

#### Individual 49B

This individual is a young child represented by cranial fragments and several isolated teeth.

#### Individual 50A

This individual is a young child represented by a right mandibular fragment and loose teeth, both deciduous and unerupted permanent.

#### Individual 50B

This individual is a middle aged male. One carious lesion is present on the right M<sub>2</sub>. There is a clear linear enamel hypoplasia on both mandibular canines.



## Appendix B

INDIVIDUAL	SEX	AGE	DENTAL CARIES	ENAMEL HYPOPLASIA	AUDITORY EXOSTOSIS	CRANIAL MODIFICATION
14A	Male?	Adult	N/A	N/A	N/A	N/A
16A	Indeter	B-9	0	No	N/A	N/A
16B	Indeter	Adult	N/A	N/A	N/A	N/A
17A	Indeter	B-9	0	No	N/A	N/A
19A	Female	10-19	0	Yes	N/A	N/A
19B	Indeter	B-9	1	No	N/A	N/A
19C	Male	40-49	0	No	N/A	N/A
19D	Indeter	B-9	0	No	N/A	N/A
20A	Male	20-29	0	No	N/A	N/A
20C	Indeter	B-9	0	No	N/A	N/A
23A	Male	30-39	1	No	N/A	Yes
23C	Male	20-29	0	Yes	Severe	Yes
23D	Female	40-49	6	No	Mild	N/A
26A	Indeter	B-9	0	No	N/A	N/A
27A	Female	30-39	2	No	N/A	N/A
27B	Indeter	B-9	0	No	N/A	N/A
28A	Male	20-29	0	No	Severe	Yes
28B	Male	10-19	1	No	No	N/A
29A	Female	Adult	N/A	N/A	N/A	N/A
29B	Male	Adult	N/A	N/A	N/A	N/A
30A	Indeter	B-9	N/A	N/A	N/A	N/A
30B	Indeter	B-9	1	No	N/A	N/A
32A	Indeter	B-9	0	No	No	Possible
33A	Male	20-29	N/A	N/A	N/A	N/A
34B	Indeter	B-9	N/A	N/A	N/A	N/A
35A	Indeter	B-9	0	No	N/A	N/A
35B	Indeter	B-9	1	No	No	N/A



37A	Indeter	B-9	0	No	N/A	N/A
38A	Male	20-29	0	No	N/A	N/A
42A	Indeter	B-9	0	No	No	N/A
43A	Indeter	B-9	0	No	No	Yes
44A	Indeter	B-9	2	No	N/A	N/A
45A	Indeter	B-9	0	No	N/A	N/A
45B	Indeter	B-9	0	No	N/A	N/A
46A	Indeter	B-9	N/A	N/A	N/A	N/A
47A	Indeter	B-9	1	No	No	N/A
47B	Indeter	B-9	3	No	N/A	N/A
48A	Female	30-39	1	No	N/A	N/A
48B	Indeter	B-9	0	No	N/A	N/A
48C	Indeter	B-9	0	No	N/A	N/A
49A	Indeter	B-9	1	No	No	N/A
49B	Indeter	B-9	N/A	N/A	N/A	N/A
50A	Indeter	B-9	0	No	N/A	N/A
50B	Male	20-29	1	Yes	N/A	N/A
No Provenience	Male	20-29	1	No	N/A	N/A
No Provenience	Indeter	Adult	N/A	N/A	N/A	N/A



## Works Cited

- Armstrong GJ and van Gerven DP. 2003. A century of skeletal biology and paleopathology: contrasts, contradictions, and conflicts. *American Anthropologist* 105: 53–64.
- Berryman HE. 1975. *A multivariate study of three prehistoric Tennessee skeletal populations: Mouse Creek, Dallas, and Middle Cumberland*. Unpublished Master's Thesis, Department of Anthropology, University of Tennessee, Knoxville.
- Berryman HE. 1981. *The Averbuch skeletal series: A study of biological and social stress at a Late Mississippian period site from Middle Tennessee*. Unpublished Ph.D. dissertation, Department of Anthropology, University of Tennessee, Knoxville.
- Blitz JH. 2010. New perspectives in Mississippian archaeology. *Journal of Archaeological Research* 18:1-19.
- Boyd CC and Boyd DC. 1991. A multidimensional investigation of biocultural relationships among three late prehistoric societies in Tennessee. *American Antiquity* 56(1): 75-88.
- Broster J. 1972. The Garnier Site: A Later Mississippian Village on the Cumberland River: In: (RB Ferguson, ed.) *The Middle Cumberland Culture*. Publications in Anthropology No. 3. Vanderbilt University, Nashville, pp. 52-78.
- Brown I. 1981. A Study of Stone Box Graves in Eastern North America. *Tennessee Anthropologist* 6(1):1-26.
- Del Papa MC and Perez SI. 2007. The influence of artificial cranial vault deformation on the expression of cranial nonmetric traits: its importance in the study of evolutionary relationships. *American Journal of Physical Anthropology* 134:251–262
- Dorsey GA. 1897. Wormian Bones in Artificially Deformed Kwakiutl Crania. *American Anthropologist* 10:169-173.
- Dowd J. 1972. *The West site: A Stone Box Cemetery in Middle Tennessee*. Tennessee Archaeological Society, Miscellaneous Paper No. 10. Nashville.
- Eisenberg, LE. 1991. Mississippian Cultural Terminations in Middle Tennessee: What the Bioarchaeological Evidence Can Tell Us. In: (Powell ML, Bridges PS, Mires AMW, eds.) *What mean these bones? Studies in Southeastern Bioarchaeology*. Tuscaloosa, AL: The University of Alabama Press, pp. 70-88.
- Ferguson R. 1972. Arnold Village Site Excavations of 1965-1966. In (RB Ferguson, ed.) *The Middle Cumberland Culture*. Publications in Anthropology No. 3. Vanderbilt University, Nashville, pp. 2-49.



- Goodman AH and Rose JC. 1990. Assessment of systemic physiological perturbations from dental enamel hypoplasias and associated histological structures. *Yearbook of Physical Anthropology* 33:59-110.
- Goodman AH, Armelagos GJ, and Rose JC. 1984. The chronological distribution of enamel hypoplasias from prehistoric Dickson Mounds population. *American Journal of Physical Anthropology* 65:259-266.
- Kelly JE, Brown JA, Hamlin JM, Kelly LS, Kozuch L, Parker K, and Nest JV. 2007. Mound 34: The context for the early evidence of the Southeastern ceremonial complex at Cahokia. In: (King A, ed) *Southeastern Ceremonial Complex: Chronology, Content, Context*. Tuscaloosa, AL: The University of Alabama Press., pp. 57-87
- Kennedy GE. 1986. The relationship between auditory exostoses and cold water: a latitudinal analysis. *American Journal of Physical Anthropology* 71:401-415.
- Marceaux S and Dye DH. 2007. Hightower anthropomorphic marine shell gorgets and Duck River sword-form flint bifaces: Middle Mississippian ritual regalia in the Douthen Appalachians. In: (King A, ed) *Southeastern Ceremonial Complex: Chronology, Content, Context*. Tuscaloosa, AL: The University of Alabama Press, pp. 165-184.
- Milner GR. 1984 Social and temporal implications of variation among American bottom Mississippian cemeteries. *American Antiquity* 49:468-488
- Moore MC, Breitburg E, Smith KE and Trubitt MA. 2006. One hundred years of archaeology at Gordontown: A fortified Mississippian town in middle Tennessee. *Southeastern Archaeology* 25(1)
- Muller J. 1997. *Mississippian Political Economy*. New York: Plenum Press.
- Pluckhahn TJ. 2010. Household archaeology in the Southeastern United States: History, trends, and challenges. *Journal of Archaeological Research* 18:331-338.
- Powell ML. 1991. Ranked status and health in the Mississippian chiefdom at Moundville. In: (Powell ML, Bridges PS, Mires AMW, eds.) *What mean these bones? Studies in Southeastern Bioarchaeology*. Tuscaloosa, AL: The University of Alabama Press, pp. 22-51.
- Rogers JD. 1995. The archaeological analysis of domestic organization. In: (Rogers JD and Smith BD, ed) *Mississippian Communities and Households*. Tuscaloosa, AL: The University of Alabama Press, pp. 7-31
- Smith K. 1992. *The Middle Cumberland Region: Mississippian Archaeology in North Central Tennessee*. Unpublished Ph.D. Dissertation, Vanderbilt University, Nashville.
- Smith MO 2003. Beyond palisades: The nature and frequency of late prehistoric deliberate violent trauma in the Chickamauga Reservoir of East Tennessee. *American Journal of Physical Anthropology* 121: 303-318
- Steadman DW. 2008. Warfare related trauma at Orendorf, a Middle Mississippian site in west-central Illinois. *American Journal of Physical Anthropology* 136:51-56.
- Sullivan LP. 2007. Shell gorgets, time, and the Southeastern ceremonial complex in Southeastern Tennessee. In: (King A, ed) *Southeastern Ceremonial Complex: Chronology, Content, Context*. Tuscaloosa, AL: The University of Alabama Press, pp. 88-106.
- Ward, J. 1971. A comparative study of the Arnold and Garnier populations based on osteological observations. In (RB Ferguson, ed) *The Middle Cumberland Culture*. Publications in Anthropology No. 3. Vanderbilt University, Nashville, pp. 81-96.



Wright MHM, Stout DC, Bass WM. 1973. Skeletal material from the West Site, 40DV12 Davidson County, Tennessee. *Tennessee Archaeologist* 29(1): 12-49.