University of Tennessee, Knoxville
Trace: Tennessee Research and Creative Exchange

Biomedical and Diagnostic Sciences Publications and Other Works

Biomedical and Diagnostic Sciences

1-1-2006

Histologic assessment and grading of the exocrine pancreas in the dog

Shelley Newman
University of Tennessee-Knoxville

J M. Steiner

K Woosley

D A. Williams

Follow this and additional works at: http://trace.tennessee.edu/utk_compmedpubs

Recommended Citation
Shelley Newman, J M. Steiner, K Woosley, D A. Williams, and L Barton. "Histologic assessment and grading of the exocrine pancreas in the dog" Journal of Veterinary Diagnostic Investigation 18 (2006): 115-118.

This Article is brought to you for free and open access by the Biomedical and Diagnostic Sciences at Trace: Tennessee Research and Creative Exchange. It has been accepted for inclusion in Biomedical and Diagnostic Sciences Publications and Other Works by an authorized administrator of Trace: Tennessee Research and Creative Exchange. For more information, please contact trace@utk.edu.

J Vet Diagn Invest 18:115–118 (2006)

Histologic assessment and grading of the exocrine pancreas in the dog

S. J. Newman,[1] J. M. Steiner, K. Woosley, D. A. Williams, L. Barton

Abstract. Histologic grading schemes for canine inflammatory conditions are sparse, and in the case of the canine pancreas, have not been previously described. In a previous study, we determined that histologic lesions of the exocrine pancreas occurred much more frequently than gross lesions. The intention of the current study was to develop a histologic grading scheme for nonneoplastic lesions following extensive assessment of the exocrine pancreas from dogs presented for necropsy examination. The parameters of the proposed scheme include neutrophilic inflammation, lymphocytic inflammation, pancreatic necrosis, pancreatic fat necrosis, edema, fibrosis, atrophy, and hyperplastic nodules. In this case series, the most common lesion was pancreatic hyperplastic nodules (80.2%), followed by lymphocytic inflammation (52.5%), fibrosis (49.5%), atrophy (46.5%), neutrophilic inflammation (31.7%), pancreatic fat necrosis (25.7%), pancreatic necrosis (16.8%), and edema (9.9%). Only 8 of the 101 animals had no evidence of any of the lesions in any of the sections examined. Fibrosis, atrophy, and/or lymphocytic infiltration most commonly accompanied nodules. Neutrophilic inflammation, when present, was often associated with necrosis (pancreatic necrosis, pancreatic fat necrosis, or both) and occasionally with hyperplastic nodules. The utilization of a grading scheme for exocrine pancreatic lesions will be useful in advancing the classification of exocrine pancreatic disease in the dog, which may lead to multicenter studies of exocrine pancreatic disorders in the dog and in other species.

Key words: Canine; hyperplasia; inflammation; pancreas; pancreatitis.

Pancreatitis in dogs remains a significant and inadequately understood cause of morbidity and mortality.[9] Accurate classification of pancreatitis in dogs is important not only for appropriate therapy of specific cases but also for the study of pancreatitis through multicenter trials. Histologic grading schemes for canine inflammatory conditions are sparse and, in the case of the canine pancreas, have not been previously described. Previous work by the authors determined that histologic lesions of pancreatic inflammation and/or necrosis occur more frequently in the dog than suspected from either the clinical history or from grossly recognizable lesions, and that these lesions do not localize to any particular region of the pancreas.[6] This supports the contention that lesions of the exocrine pancreas could be easily overlooked at the time of exploratory laparotomy or during necropsy. A comprehensive assessment of pancreatic lesions in a large number of dogs presented for necropsy was required to characterize the type and extent of lesions and to formulate a grading scheme. It is hoped that the following scheme can easily be adopted by pathologists and can ultimately form the basis for multi-institutional studies on canine exocrine pancreatic disease.

A total of 101 pancreata were collected consecutively from dogs presented for necropsy examination to the Pathology Department at the Animal Medical Center (AMC), New York, New York. Study animals included those with clinical signs compatible with primary pancreatic disease (such as vomiting, anorexia, and abdominal pain) and those without. Inclusion criteria consisted of having owner consent for necropsy examination and having the pancreas removed in its entirety within 6 hours of death. Fixation of the pancreas in 10% buffered formalin within this 6-hour period minimized postmortem degeneration/autolysis of the pancreatic tissue.[6] The right limb of the pancreas was identified with a suture at the time of removal.[6] Pancreata were sectioned every 2 cm, beginning at the tip of the right limb as described previously by these authors (Fig. 1).[6] Each transverse section was numbered so that the approximate location within the pancreas could be determined. These were then routinely processed, stained with hematoxylin and eosin (HE), and assessed with light microscopy by a single pathologist (SJN).[6]

The histologic parameters of interest for characterization of lesions and development of a grading system are defined below. Neutrophilic inflammation was defined as the presence of neutrophils within the pancreatic parenchyma, peripancreatic adipose tissue, or both (Fig. 2). Lymphocytic inflammation was defined as the presence of variable numbers of lymphocytes and/or plasma cells within the pancreatic parenchyma, inter-

From the Department of Pathology, College of Veterinary Medicine, University of Tennessee, Knoxville, TN, 37996-4542 (Newman); Gastrointestinal Laboratory, Texas A&M University, College Station, TX (Steiner, Williams); Department of Medicine, Animal Medical Center (AMC), New York, NY, 10021-8314 (Woosley, Barton). Current address (Woosley): Katonah-Bedford Veterinary Center, Bedford Hills, NY 10507.

[1]Corresponding Author: Dr. Shelley Newman, Department of Pathology, College of Veterinary Medicine, University of Tennessee, 2407 River Drive, Knoxville, TN 37996-4542.

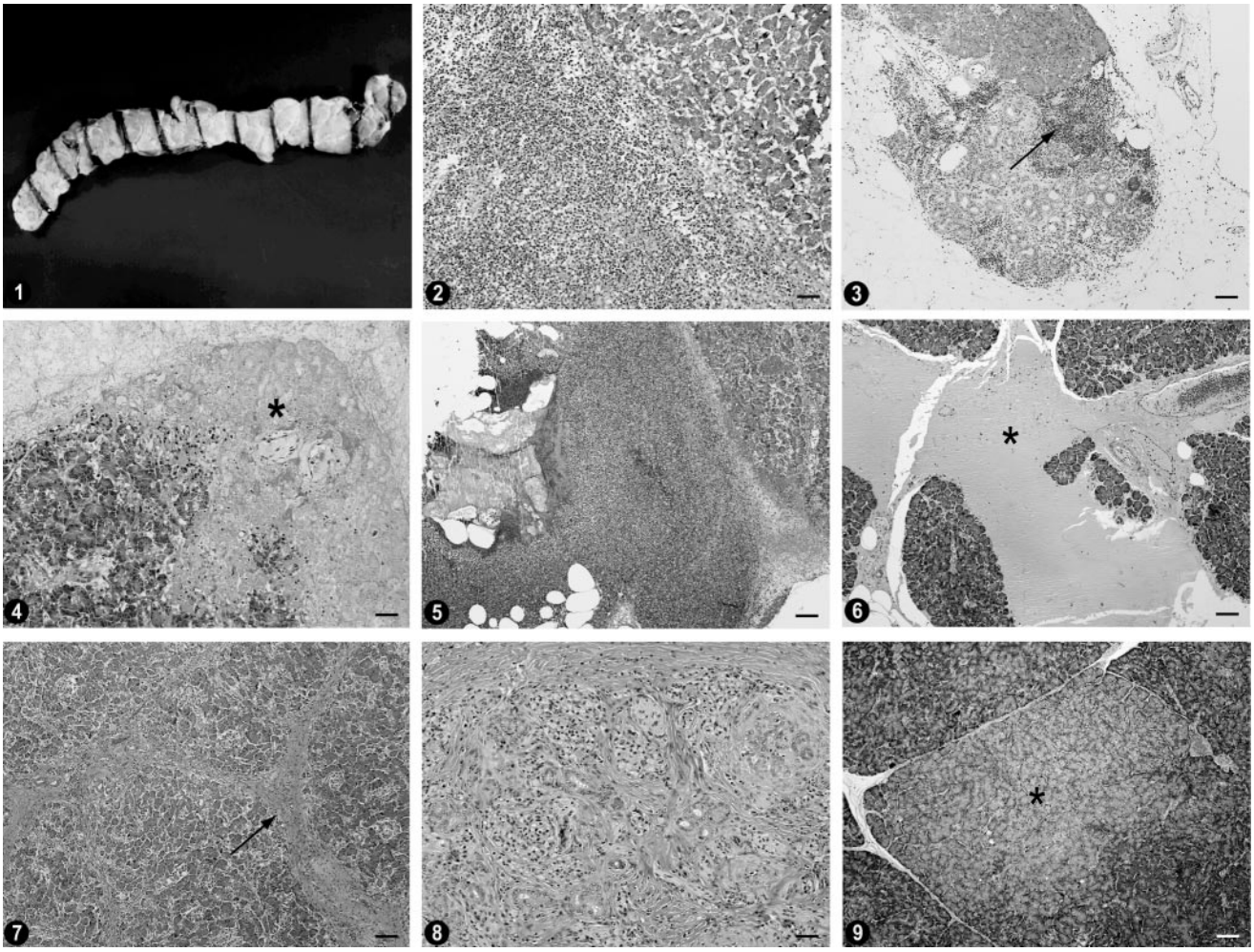

Figure 1. Pancreas; canine. Gross kodachrome with painted grid lines to demonstrate the 2-cm trimming technique used.
Figure 2. Pancreas; canine, 43495 P8. Example of grade III neutrophilic inflammation—hematoxylin and eosin (HE). Bar = 150 μm.
Figure 3. Pancreas; canine, 43968 P1. Example of grade II lymphocytic inflammation (arrow; HE). There is accompanying fibrosis and lobular atrophy and mild edema. Bar = 225 μm.
Figure 4. Pancreas; canine, 44480 P1. Example of grade III necrosis (asterisk; HE). Bar = 150 μm.
Figure 5. Pancreas; canine, 43953 P11. Example of grade II peripancreatic necrosis (HE). Bar = 225 μm.
Figure 6. Pancreas; canine, 43940 P8. Example of grade II edema (asterisk; HE). Bar = 150 μm.
Figure 7. Pancreas; canine, 43765, P12. Example of grade II fibrosis (arrow; HE). Bar = 150 μm.
Figure 8. Pancreas; canine, 44032 P1, 43940 P1. Example of grade II atrophy (HE). There is accompanying fibrosis. Bar = 100 μm.
Figure 9. Pancreas; canine,45324 P4. Example of grade II nodular hyperplasia (asterisk; HE). Bar = 225 μm.

stitium, or both (Fig. 3). Pancreatic necrosis was defined as coagulation necrosis of the pancreatic parenchyma (Fig. 4). Pancreatic fat necrosis was defined as foci of saponification in the small remnants of peripancreatic adipose tissue not removed at the time of trimming (Fig. 5). Edema was defined as an expansion of the interstitium by lightly eosinophilic proteinaceous fluid (Fig. 6). Fibrosis was defined as the presence of increased quantities of mature fibrous connective tissue that expanded the interstitium or replaced portions of the acinar tissue (Fig. 7). Masson trichrome staining was performed on any equivocal cases and fibrous connective tissue was recognized as intense blue-staining material. Atrophy was defined as a reduction in size of a pancreatic lobule or lobe, whereby individual cells were fewer in number and smaller than normal (Fig. 8). Occasionally, atrophic epithelial cells were diffusely vacuolated. Finally, hyperplastic nodules were defined as areas in which there were increased numbers of variably sized, well-differentiated exocrine pancreatic epithelial cells that were variably demarcated and/or encapsulated from the surrounding pancreatic parenchyma (Fig. 9).

The individual light microscopic slides were assessed for all of the above-identified parameters and subsequently graded based on the absence of (0) or presence and severity (1, 2, or 3) of the specific lesion in the section. Severity scores, for each section, were

Table 1. Number of dogs with pancreatic lesions in each grade category.

Histologic parameter	Grade 1	Grade 2	Grade 3	Total	Mean frequency score	Mean cumulative score
Neutrophilic inflammation	18	10	4	32	41.2 ± 30.1	0.59 ± 0.6
Lymphocytic inflammation	52	0	1	53	34.8 ± 33.4	0.36 ± 0.38
Pancreatic necrosis	10	5	2	17	26.4 ± 24.1	0.37 ± 0.48
Fat necrosis	14	9	3	26	43 ± 27.3	0.6 ± 0.5
Edema	9	1	0	10	30.1 ± 21.8	0.31 ± 0.23
Fibrosis	41	7	2	50	44.2 ± 34.2	0.53 ± 0.54
Atrophy	38	8	1	47	41.5 ± 32.4	0.49 ± 0.49
Nodules	52	24	5	81	73.5 ± 31.3	0.9 ± 0.59

defined as grade 1 (<10% of the section affected), 2 (10–40% of the section affected) and 3 (>40% of the section affected). Additionally, a mean cumulative severity score was assigned based on the number of sections and the severity score of each section (mean cumulative score; MCS = Σ score of single sections/number of sections). An MCS of >0.0 but less than or equal to 1.0 was considered mild, an MCS of >1.0 but equal or less than 2.0 was considered moderate, and an MCS of >2.0 was considered severe.

Also, the mean frequency score (MFS = [number of slides that showed the particular lesion/total number of slide examined] × 100) was determined for each pathologic parameter. Finally, an overall inflammatory disease activity index and overall inflammatory disease chronicity index was calculated for each pancreas. The disease activity index (AI) was calculated from $AI = (MCS_{neutrophilic\ inflammation} + MCS_{lymphocytic\ inflammation} + MCS_{pancreaticnecrosis} + MCS_{peripancreaticnecrosis} + MCS_{pancreatic\ edema})/5$, with a maximum AI of 3.0. An AI of >0.0 but less than or equal to 1.0 was considered mild, an AI of >1.0 but equal or less than 2.0 was considered moderate, and an AI of >2.0 was considered severe. The parameters comprising this index were of currently active processes involving necrosis or inflammation. The disease chronicity index (CI) was calculated from $CI = (MCS_{fibrosis} + MCS_{atrophy})/2$, with a maximum CI of 3.0. The parameters comprising this index represented varying degrees of severity of processes considered to be more indicative of a chronic ongoing or previously resolved pancreatic lesion. Similarly, a CI of >0.0 but less than or equal to 1.0 was considered evidence of a mild change of some duration, a CI of >1.0 but equal or less than 2.0 was considered evidence of a moderate change of some duration, and a CI of >2.0 was considered evidence of a severe change of some duration.

The number of dogs with lesions of each type and severity, as well as mean cumulative and frequency scores, are displayed in Table 1. In this case series, the most common lesion was pancreatic hyperplastic nodules (80.2%), followed by lymphocytic inflammation (52.5%), fibrosis (49.5%), atrophy (46.5%), neutrophilic inflammation (31.7%), pancreatic fat necrosis (25.7%), pancreatic necrosis (16.8%), and edema (9.9%). Fibrosis, atrophy, and/or lymphocytic infiltration most commonly accompanied nodules. Neutrophilic inflammation, when present, was often associated with necrosis (pancreatic necrosis, pancreatic fat necrosis, or both) and occasionally with hyperplastic nodules.

Lymphocytic infiltrates varied in severity and, in the most severe cases, were associated with the periductular interstitium and occasionally formed small nodular/follicular structures. Mature connective tissue was seen principally in the periductular interstitium and less commonly associated with parenchymal damage. Only in the more severe cases did the fibrous connective tissue encroach on pancreatic parenchyma. Occasionally, fibrous connective tissue partially encapsulated foci of exocrine nodular hyperplasia. Masson trichrome stains failed to identify significant increases in fibrous connective tissue in association with focal atrophic lobules. Pancreatic and peripancreatic necrosis occurred concurrently in 12 cases (approximately 10% of sections), and in 5 cases, pancreatic necrosis (3 dogs with grade I and two dogs with grade II) occurred in the absence of peripancreatic alterations. Rarely, both locations for necrosis were seen in the same tissue section (total number of sections that showed pancreatic necrosis and peripancreatic fat necrosis = 29). Edema was a mild change and the least common alteration.

Fifteen animals had only 1 type of lesion, 15 had 2 types of lesions, 23 had 3 types of lesions, 17 had 4 types of lesions, 10 had 5 types of lesions, 7 had 6 types of lesions, 6 had 7 types of lesions, and none had all 8 types of pancreatic lesions. Only 8 of the 101 animals had no evidence of any of the lesions in any of the sections examined. Thus, most of the dogs had 3–4 different types of lesions.

AIs ranged from 0.0 to 1.2, with 70 of 101 (69.3%) pancreata having a score >0.0, but only 2 pancreata showing moderate lesions, and no pancreas showing severe lesions. This suggests that the majority of the pancreas submissions showed active lesions, although mild. CIs ranged from 0.0 to 2.2, with 68 of 101 (67.3%) pancreata having a score of >0.0 but only 4

pancreata showing signs of moderate chronicity, and only 1 pancreas showing signs of severe chronicity. This similarly suggests that the majority of pancreas submissions showed lesions of some duration and of slightly greater severity. A total of 11 pancreata had a CI >0.0 but an AI of 0.0.

The variety of pancreatic lesions identified in this series of cases was broad, extensive, and somewhat unexpected. The random distribution of histologic pancreatic lesions documented previously[6] would preclude their identification without a thorough search. Undoubtedly, the extensive sectioning at 2-cm intervals allowed us to detect a higher incidence of lesions than might be expected from clinical parameters and which might otherwise go undetected by gross examination alone or by evaluation of a single histologic section alone (as is the standard practice in most diagnostic facilities). While examination of predetermined standard sites within a pancreas could be used for grading, the differences in canine pancreatic size make consistency and repeatability of sampling location difficult. Although large dogs had more pancreatic sections examined, the MCS and MFS attempted to decrease the significance of pancreatic size by a comparison of means. The number of examined pancreatic slides ranged from 5 for the smallest dog up to 31 for the largest dog.

Pancreatic nodules were the most commonly noted pancreatic change. We have published previously that these nodules were not associated with prior injury but that their frequency increased with advancing age.[7] Additionally, these are apparently not preneoplastic changes but rather represent an idiopathic hyperplasia.[4] When they occurred in combination with other pathologic processes, fibrosis, atrophy, and lymphocytic inflammation were the most common type of lesions. Less frequently, hyperplastic nodules occurred concurrently with necrosis and neutrophilic inflammation.

The most common inflammatory lesion, lymphocytic inflammation, was mild in most cases. This could help explain why histologic lesions may be more prevalent than clinical signs of pancreatic inflammation. Lymphocytic inflammation was closely followed by fibrosis and atrophy as the most common changes. Pancreatic fibrosis has been determined to be an incidental necropsy finding in dogs with normal digestive function.[3] Fibrosis may indicate previous inflammatory episodes and resolved disease. Pancreatic fat necrosis was usually accompanied by neutrophilic infiltration. Hence, necrosis and neutrophilic inflammation occurred at similar rates. Edema, though mild, was by far the least common lesion noted but occasionally occurred concurrently with acute neutrophilic inflammation. The previously documented progression from edema to fibrin deposition and leukocyte infiltration was not noted in this study.[1,2]

Atrophy, when present, was mild; the majority of the sections in which atrophy was detected were assigned a grade of I. Breeds (German Shepherds and Rough-Coated Collies) predisposed to pancreatic acinar atrophy (PAA) were not represented in this study and the characteristic lesions of PAA were also not apparent.[8,10] Exocrine pancreatic insufficiency can be the end result of chronic pancreatic inflammation.[5]

This case series demonstrates that histologic changes in the canine pancreas are common. Although the clinical significance of these lesions still needs to be determined, the utilization of a grading scheme for exocrine pancreatic lesions will permit better characterization of exocrine pancreatic disease in the dog and will facilitate multicenter studies of exocrine pancreatic disorders in the dog and other species.

Acknowledgements. We wish to acknowledge the Morris Animal Foundation for financial support of this project. Ms. Teresa Jennings provided excellent graphic assistance.

References

1. Anderson NV: 1972, Pancreatitis in dogs. Vet Clin North Am 2:79–97.
2. Cotran RS, Kumar V, Collins T: 1999, Neoplasia. *In:* Pathologic basis of disease, ed. Cotran RS, Kumar V, Collins T, 6th ed., pp. 260–327. W.B. Saunders, Philadlephia, PA.
3. Jubb KVF: 1993, The pancreas. *In:* Pathology of domestic animals, ed. Jubb KVF, Kennedy PC, Palmer N, 4th ed., pp. 407–424. Academic Press, Inc., New York, NY.
4. Kircher DH, Nielsen SW: 1976, Tumors of the pancreas. Bull WHO 53:195–202.
5. MacLachlan NJ, Cullen JM: 2001, Liver, biliary system and exocrine pancreas. *In:* Special veterinary pathology, ed. McGavin MD, Carlton WW, Zachary JF, 3rd ed., pp. 81–124. The CV Mosby Co., Inc., Kansas, MO.
6. Newman SJ, Steiner J, Woosley K, et al.: 2004, Localization of pancreatic inflammation and necrosis in dogs. J Vet Int Med 18(4):488–493.
7. Newman SJ, Steiner J, Woosley K, et al.: 2005, Correlation of age and incidence of pancreatic exocrine nodular hyperplasia in the dog. Vet Pathol 42:510–513.
8. Watson PJ: 2003, Exocrine pancreatic insufficiency as an end stage of pancreatitis in four dogs. J Small Anim Pract 44(7): 306–312.
9. Watson P: 2005, New research into pancreatitis in dogs. J Small Anim Pract 46(7):362–363.
10. Wiberg ME, Saair SAM, Westermarck E: 1999, Exocrine pancreatic atrophy in German Shepherd dogs and Rough Coated collies: an end result of lymphocytic pancreatitis. Vet Pathol 36: 530–541.