University of Tennessee, Knoxville
Trace: Tennessee Research and Creative Exchange

Biomedical and Diagnostic Sciences Publications and Other Works

Biomedical and Diagnostic Sciences

1-1-2007

# Imaging diagnosis - canine thoracic mesothelimoa

R L. Echandi

F Morandi

Shelley Newman
*University of Tennessee-Knoxville*

A Holford

Follow this and additional works at: http://trace.tennessee.edu/utk_compmedpubs

Recommended Citation
R L. Echandi, F Morandi, Shelley Newman, and A Holford. "Imaging diagnosis - canine thoracic mesothelimoa" Veterinary Radiology & Ultrasound 48.3 (2007): 243-245.

This Article is brought to you for free and open access by the Biomedical and Diagnostic Sciences at Trace: Tennessee Research and Creative Exchange. It has been accepted for inclusion in Biomedical and Diagnostic Sciences Publications and Other Works by an authorized administrator of Trace: Tennessee Research and Creative Exchange. For more information, please contact trace@utk.edu.

# IMAGING DIAGNOSIS—CANINE THORACIC MESOTHELIOMA

RITA L. ECHANDI, FEDERICA MORANDI, SHELLEY J. NEWMAN, AMY HOLFORD

**A 12-year-old neutered female Pembroke Welsh Corgi had a 2-month history of a progressive, productive cough nonresponsive to therapy. Mild pleural effusion, right middle lung lobe collapse, and multiple subpleural nodular lesions were detected in thoracic radiographs and computed tomography (CT) images. Histopathologic diagnosis of the pleural nodules was mesothelioma. Mesothelioma should be considered in patients where pleural masses are detected in radiographs or CT images.** *Veterinary Radiology & Ultrasound, Vol. 48, No. 3, 2007, pp 243–245.*

**Key words: computed tomography, dog, mesothelioma, thorax.**

## Signalment and History

A 12-YEAR-OLD neutered female Pembroke Welsh Corgi had a 2-month history of a progressive, productive cough which was nonresponsive to standard medical therapy. Thoracic radiographs were made at the referral practice, and a mediastinal mass, pleural effusion, and megaesophagus were suspected. These radiographs were not available for review at the time of referral. Samples of the pleural effusion and suspected mediastinal mass obtained by the referring veterinarian were submitted to a clinical pathologist, but they were nondiagnostic. The dog was then referred to the University of Tennessee College of Veterinary Medicine for further diagnostics.

## Physical Examination and Minimum Database

The patient was panting, yet no auscultable lung sounds were present within the right ventral aspect of the thorax. No other clinical or laboratory abnormalities were detected.

## Imaging

In thoracic radiographs there was an alveolar pattern at the level of the right middle lung and a small volume of pleural fluid. Two nodular opacities were noted in a subpleural location at the level of the left seventh rib and intercostal space (Fig. 1). Additionally, three areas of increased focal extrapleural opacity were noted along the left cranial thoracic wall (Fig. 1). All these lesions were not associated with costochondral junctions. This latter finding was confirmed by observing thoracic movement under fluoroscopic examination: the extrapleural nodular lesions were noted to move with the thoracic wall and did not change in size and shape with a change in patient recumbency. Based on the bilateral mild pleural effusion and suspected subpleural lesions, neoplasia or granulomatous processes were the primary considerations. Additional considerations for the alveolar pattern included chronic bacterial pneumonia, foreign body pneumonia, inflammation, or atelectasis.

The day after radiography, computed tomography (CT) was performed using a fourth generation scanner*. The aims were to define the extent of the subpleural and right middle lung lobe lesions, and to possibly obtain fine needle aspirates via CT guidance. Contiguous transverse CT images were acquired at 4 mm collimation, 125 mA, 130 kV, and edge-enhancing algorithm; the patient was in sternal recumbency. A severe alveolar pattern was present in the right middle lung lobe, with no evidence of volume loss. There was no evidence of a foreign body. There was also moderate bilateral pleural effusion. There were multifocal areas of soft tissue thickening along the left lateral and ventral body wall which were not associated with costochondral junctions (Fig. 2). Additional smaller areas of subpleural thickening and indentation were identified within the right cranial hemithorax, in the area of the right cranial and middle lung lobes. No evidence of lymphadenopathy was present. The patient was repositioned to right recumbency and a limited scan of the area of most severe subpleural thickening was obtained: despite the change in recumbency, the appearance of this lesion did not change (Fig. 3). A 22-gauge $1\frac{1}{2}$in. needle was then used to obtain CT-guided aspirates of the larger left-sided extrapleural lesion (approximately 5 mm in thickness). After the procedure, there was no immediate evidence of

From the Department of Small Animal Clinical Sciences (Echandi, Morandi, Holford) and the Department of Pathobiology, The University of Tennessee College of Veterinary Medicine (UT-CVM), Knoxville, TN 37996 (Newman).

Address correspondence and reprint requests to Federica Morandi, Department of Clinical Sciences, University of Tennessee, Veterinary Teaching Hospital, Knoxville, TN 37996. E-mail: fmorandi@utk.edu

Received July 7, 2006; accepted for publication September 19, 2006.
doi: 10.1111/j.1740-8261.2007.00236.x

*CT IQ Xtra Picker International, Cleveland, OH.

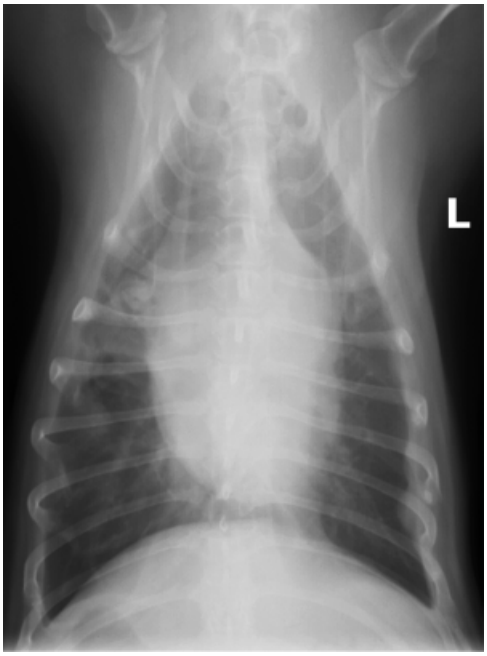


FIG. 1. Ventrodorsal view of the thorax. There is a focal alveolar pattern associated with the right middle lung lobe. In addition, there is retraction of the right cranial and middle lobe, indicating a small volume of pleural fluid. There are multiple extrapleural lesions evident along the caudal and medial aspects of the left, third, fifth, seventh, and eigth ribs.

complications. Based on the presence of bilateral pleural effusion with multiple subpleural lesions, a neoplastic process, most likely mesothelioma, was considered. Differentials for the changes associated with the right middle lung included neoplastic or infectious/inflammatory processes, however progressive atelectasis could not be ruled out.

## Diagnosis and Outcome

Cytologic evaluation of the pleural nodules was not diagnostic. Based on the history and CT findings, exploratory thoracotomy was recommended. Upon opening the thoracic cavity at the right fifth intercostal space, 250 ml of a clear, yellowish pleural fluid was suctioned. Several white nodules were distributed over the pleura and pericardium. A right middle lobectomy and a window pericardectomy were performed. The myocardium of the right auricle appeared thickened. Intraoperative impression smears of the pleural nodules were consistent with neoplasia of uncertain cell type, with differentials including mesothelioma, carcinoma, and plasma cell tumor. Samples of a pleural mass and pericardium were obtained for histopathologic evaluation.

Tissues were stained with hematoxylin and eosin. The changes associated with the right middle lobe were consistent with atelectasis with accompanying mild to moderate type II pneumocyte hyperplasia, bronchiolar hyperplasia, and alveolar histiocytosis. Pleural and pericardial samples were characterized by multifocal to coalescing regions of architectural obliteration and replacement by numerous polygonal cells with moderate anisokaryosis and anisocytosis, condensed basophilic, round to oval nuclei, and moderate lightly amphophilic cytoplasm. Cells occasionally formed small to intermediate-sized papillary projections, pseudorosettes, clefts, and acinar type structures. The mitotic rate was 1–2 per high-power field. There was also a prominent fibrous connective tissue stroma present within and surrounding the nodules. This appearance was most consistent with a diagnosis of mesothelioma.

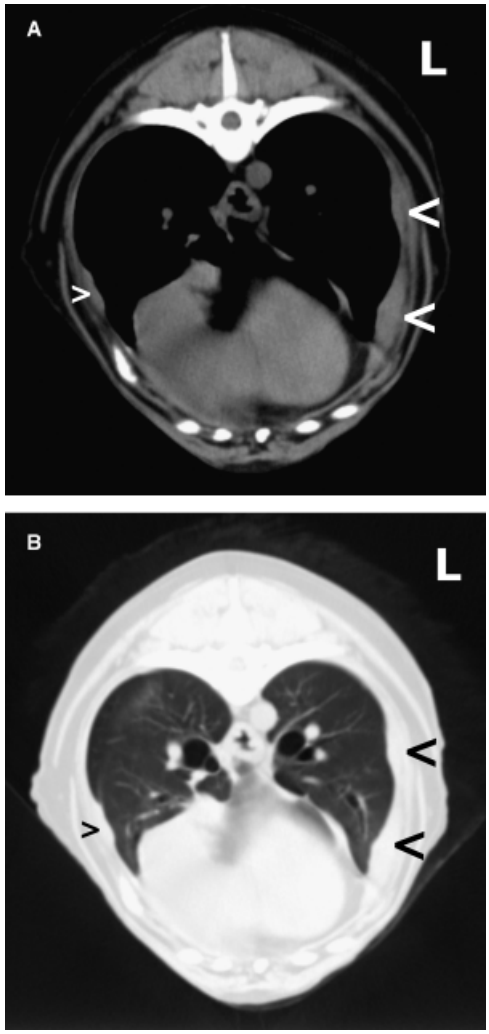


FIG. 2. The 4 mm × 4 mm transverse computed tomographic images of the thorax at the level of T7 in a soft tissue (A) window width: 350, window level: 50 and lung window (B) window width: 1200, window level: −500. There is irregularity and thickening of the parietal pleura, more severe on the left side (large arrowheads), but also visible along the right ventral thoracic wall (small arrowhead).

Sections of the pleural mass were processed for immunohistochemical staining with antibodies against vimentin and cytokeratin. While the mesothelial lining cells

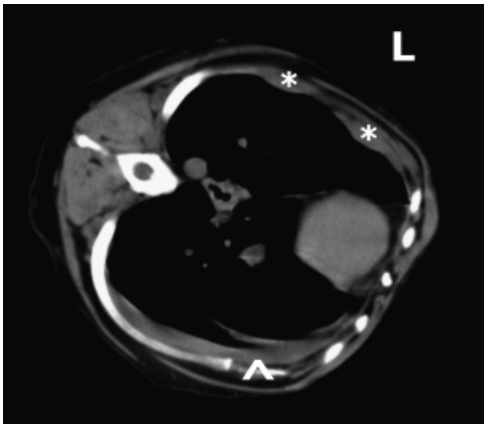


FIG. 3. The 4 mm × 4 mm computed tomographic transverse image of the thorax displayed in a soft tissue window (window width: 350, window level: 50) with the dog in right lateral recumbency. The image is obtained approximately at the same level as Fig. 2. Notice the unchanged appearance of the left-sided extrapleural lesions (asterisks). Pleural fluid is visible on the right side (arrowhead), with a fissure line separating the right middle and right caudal lobes.

(hyperplastic) and foci of neoplastic polygonal to spindle cells within nodular foci in the tissue deep to the surface stained strongly positive for cytokeratin, for the most part these same cells were vimentin negative. Vimentin positivity was strong for the surrounding fibroblasts and blood vessels which made assessment of any one cell for dual staining difficult. The neoplastic cells were predominantly cytokeratin positive.

Based on the combined histologic and immunohistochemistry results, the fact that not all mesotheliomas are dual staining,[1] the lack of tumor emboli within vessels, the lack of pulmonary nodules on CT evaluation and lack of neoplasia of the right middle lobe, as well as absence of clinical signs other than those referable to the respiratory tract, mesothelioma remained the primary differential diagnosis. Atelectasis of the right middle lobe was likely a result of the pleural effusion. The dog was euthanized approximately 2 months after surgery due to progressive respiratory distress; a necropsy was not performed.

## Discussion

Mesothelioma is a rare neoplasm of dogs and cats affecting the epithelial lining of a coelomic cavity. Malignant mesothelioma can metastasize by lymphatic routes or by transplantation. Mesothelial tumors occur most often in older animals, although in cattle and sheep, newborn or young animals are affected.[2] Exposure to asbestos may be an important contributing factor to mesothelioma in dogs and risk factors have include owners with an asbestos-related occupation or hobby, an urban residence and use of flea repellents.[3]

There are three histologic types of mesotheliomas: epithelial, fibrous (sarcomatous), and biphasic (mixed).[2] The epithelial form, which resembles carcinoma and adenocarcinoma, is the most common in small animals.[4] Mesotheliomas occur as diffuse nodular masses covering surfaces of a body cavity. Extensive effusion occurs secondary to exudation from the tumor surface or secondary to obstructed lymphatics.[4] Tachypnea, dyspnea, and a distended abdomen are common clinical presentations. Pericardial effusion can also occur.

Additional diagnostics, such as echocardiography and abdominal sonography, can be performed to locate lesions, the identification of which may be dependent on lesion size and amount of associated effusion. The tumor often adheres to epithelial surfaces and a mass lesion may not be observed.[4] In this dog, the presence of only mild pleural effusion and the use of CT allowed clear identification of the pleural nodules. In humans, contrast-enhanced helical CT is the imaging modality of choice for the evaluation of malignant pleural mesothelioma. The pleural lining enhances strongly with malignant mesothelioma or inflammatory pleural disease, allowing differentiation between thickened pleura, effusion or underlying collapsed lung.[5] In addition, the pleura often has delayed enhancement compared with pulmonary parenchyma at 45 s, allowing more accurate lesion detection.[5] In this report, a postcontrast CT scan was not performed, as the pleural lesion were visible due to the relatively small amount of pleural fluid present. Placing the patient in right lateral recumbency confirmed the presence of pleural nodules because pleural fluid would usually change in appearance and position.

ACKNOWLEDGMENT

The authors wish to thank Dr. Cheryl Cross for her initial assessment of the histopathology specimens.

REFERENCES

1. McDonough SP, MacLachlan NJ, Tobias AH. Canine pericardial mesothelioma. Vet Pathol 1992;29:256–260.

2. Head KW, Else RW, Dubielzig RR. Tumors of the alimentary tract. In: Meuten DJ (ed): Tumors in domestic animals, 4th ed. Iowa, USA: Iowa State Press, 2002;401–481.

3. Glickman LT, Domanski LM, Maguire TG, Dubielzig RR, Churg A. Mesothelioma in pet dogs associated with exposure of their owner's to asbestos. Environ Res 1983;32:305–313.

4. Garrett LD, MacEwen EG. Mesothelioma. In: Withrow SJ, MacEwen EG (eds): Small animal clinical oncology, 3rd ed. Philadelphia: W.B. Saunders Company, 2001;656–660.

5. Benamore RE, O'Doherty MJ, Entwisle JJ. Use of imaging in the management of malignant pleural mesothelioma. Clin Radiol 2005;60:1237–1247.